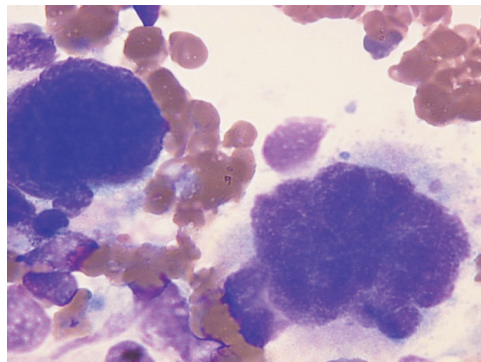


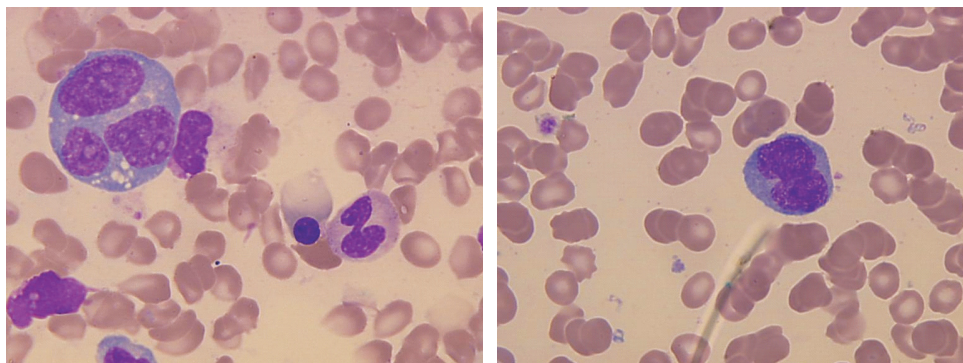
## A Case with Pancytopenia: The Role of Cytomorphology

*Lugyanti Sukrisman, Nadia A. Mulansari, Aru W. Sudoyo*

Department of Internal Medicine, Faculty of Medicine, University of Indonesia - Cipto Mangunkusumo Hospital. Jl. Diponegoro no. 71, Jakarta 10430, Indonesia. Correspondence mail: nadiasalim.md@gmail.com



**Figure 1.** Abnormal megakaryocytes in marrow of patient



**Figure 2.** Leucocyte with multilobulated nuclei, a characteristic finding in MDS

A 63-year old lady presented with prolonged fever, frequent abdominal pain and a history of melena. Physical findings revealed an anemic appearance and splenomegaly. She was treated by the gastroenterologist and subsequently referred to the hematologist as the peripheral blood count revealed pancytopenia with a hemoglobin level of 6.5 g/dl, WBC 4000/uL and a platelet count of 50.000 /uL. No blast cells were found. Patient subsequently underwent a marrow aspiration.

Cytomorphology assessment of the marrow specimen revealed the presence of abnormal megakaryocytes and leukocytes (see figures)

which was in accordance with dyshematopoiesis, and the diagnosis of MDS (myelodysplastic syndrome) was established.

The patient was then started on thalidomide 100 mg daily. There was no significant complications nor side-effects and after almost 2 years her hemoglobin level is now normal (between 12 and 14 g/dl), a dramatic reversal of her condition.

Myelodysplastic syndromes are a very heterogenous group of myeloid disorders characterized by peripheral blood cytopenias, occurring frequently in older people, especially males and usually present as cytopenia. This

is why further evaluation of bone marrow and biopsy in cytopenia – especially in elderly patients - is very important, the reasons being, firstly, aplastic anemia and MDS have a common pancytopenia appearance, but very different treatment approaches; secondly, where the treatment of aplastic anemia is uncertain at best, early detection and treatment (in this case thalidomide) of MDS can result in a favorable outcome.