

CASE REPORT

Hemoperitoneum Caused by Spontaneous Rupture of Hepatocellular Carcinoma

**Nata P. Hardjo Lugito, Andree Kurniawan, Rizki Yaruntradhani,
Andhika Rachman**

Department of Internal Medicine, Faculty of Medicine Universitas Indonesia – Cipto Mangunkusumo Hospital, Jakarta, Indonesia.

Correspondence mail:

Department of Internal Medicine, Faculty of Medicine Universitas Indonesia – Cipto Mangunkusumo Hospital, Jl. Diponegoro 71, Jakarta 10430, Indonesia. email: nata_pratama_hl@yahoo.com.

ABSTRAK

Kami melaporkan seorang pasien pria berusia 46 tahun yang datang ke unit gawat darurat dengan keluhan utama nyeri perut 1 hari sebelum masuk rumah sakit. Tidak ada riwayat trauma abdomen. Pasien sering mengeluhkan gangguan perut dalam 5 tahun terakhir. Pada pemeriksaan fisik, tampak penurunan kesadaran, syok, konjungtiva pucat, distensi abdomen disertai nyeri di seluruh abdomen pada pemeriksaan palpasi dan tidak ditemukan bising usus. Pemeriksaan laboratorium menunjukkan anemia, leukositosis, kadar amilase dan lipase normal. Pemeriksaan FAST (focus assisted sonography on trauma) menunjukkan adanya asites masif. Pasien menjalani laparotomi eksplorasi dan kemudian ditemukan darah pada rongga abdomen, hepar bernodul dan tumor hepar dengan perdarahan aktif. Selama dirawat di rumah sakit, pasien mengalami pemulihan dan kemudian pasien pulang.

Pada kasus abdomen akut, ruptur spontan karsinoma hepatoselular/hepatocellular carcinoma (HCC) merupakan salah satu diagnosis banding yang perlu dipertimbangkan mengingat tingginya insidens HCC di Asia Tenggara, khususnya di Indonesia. Konfirmasi diagnosis pada kasus peritonitis umum membutuhkan pemeriksaan CT scan abdomen dan ultrasonografi untuk menyingkirkan kemungkinan ruptur HCC.

Kata kunci: hemoperitoneum, ruptur karsinoma hepatoselular.

ABSTRACT

We are reporting a male, 46 years old came to emergency unit with a chief complaint of abdominal tenderness since 1 day prior to admission. No history of abdominal trauma. He often felt abdominal discomfort for the last 5 years. Physical examination revealed decreased consciousness, shock, pale conjunctiva, distended abdomen, with tenderness of the whole abdomen on palpation, and no bowel movement. Laboratory examination found anemia, leucocytosis, normal amilase and lipase. FAST (focus assisted Sonography on trauma) found massive ascites. Patient underwent cito laparotomic exploration that found blood on abdominal cavity, nodular liver, and actively bleeding tumour of liver. During hospitalization, patient recovered and discharged.

In the case of acute abdomen, spontaneous ruptured hepatocellular carcinoma (HCC) is one of differential diagnosis, considering high incidence of HCC in South East Asia, especially Indonesia. Confirming diagnosis of generalized peritonitis requires abdominal CT scan and ultrasonography, to rule out ruptured HCC.

Key words: hemoperitoneum, ruptured hepatocellular carcinoma.

INTRODUCTION

Hepatocellular carcinoma (HCC), previously known as hepatoma is the most common primary liver malignancy in Africa and Asia Pacific, with the incidence of 20 to 30 cases per 100,000 person year and higher in South East Asia.¹ Spontaneous rupture is acute complication with high mortality rate. Its incidence reached 8–26% in Asia and 3% in United Kingdom.^{1,2} Mean age of patients with ruptured was 75–79 years old.¹

Diagnosis was made based on symptoms and signs, imaging examination and bloody ascites fluid. Imaging examination of choice is abdominal CT scan strengthen with Doppler ultrasonography, but with low sensitivity. Management of ruptured HCC are resuscitation of hypovolemic shock, bleeding control and management of HCC.^{1,2} There are many methods of bleeding control, but patients with poor condition are not suitable to these methods, making artery embolization as an effective and safe choice until the patients are stable to undergo surgery or radiofrequency ablation to manage ruptured HCC.²

This case report is about male, 46 years old admitted to emergency unit of Cipto Mangunkusumo Hospital with symptom of abdominal tenderness and sign of acute abdomen since 1 day prior to admission, that was suspected generalized peritonitis caused by perforated viscous (stomach) with hypovolemic shock. Laparotomic exploration found 3000 cc of blood within abdominal cavity with liver that was nodular and a tumour that bled actively. A packing dressing was installed on the tumour. Patient's condition was recovered during hospitalization.

CASE ILLUSTRATION

Male, 46 years old came to emergency unit of Cipto Mangunkusumo Hospital with a chief complaint of abdominal tenderness 1 day prior to admission. Tenderness was continuous, increased with movement and getting worse. Two days prior to admission he felt epigastric discomfort that worsen and spread to the whole abdomen. Patient felt nausea but did not vomit, nor experienced diarrhea, but he could not defecate since 2 days prior to admission. He did

not have fever, no history of abdominal trauma. He often felt abdominal discomfort for the last 5 years, there was no history of analgesic drugs nor herbal medicines.

Physical examination revealed somnolent consciousness, blood pressure of 80/50 mmHg, pulse 110 per minute, weak, regular, breathing 40 per minute, temperature 36°C. Conjunctiva was pale. Abdomen was distended, with no venectation; there was tenderness of the whole abdomen on palpation, with no bowel movement. On rectal toucher sphincter tonus was good, ampula was not collapsed, smooth mucosae, no mass, and there was faeces on gloves with no blood. No palmar erythema on extremities.

Laboratory examination found hemoglobin 8.7 g/dL, hematocrite 25%, leucocyte 20,200/ μ L, platelet 130,000/ μ L. Urea 29 mg/dL, creatinine 2.8 mg/dL. SGOT 35 IU/L, SGPT 14 IU/L, albumine 3.5 g/L, blood glucose 465 mg/dL, sodium 139 mEq/L, potassium 3.1 mEq/L, chloride 104 mEq/L. Amilase 24 mg/dL, lipase 26 mg/dL. On blood gas analysis pH 7.291, pCO₂ 21.2 mmHg, pO₂ 157.1 mmHg, HCO₃⁻ 10.3 mEq/L, saturation O₂ 99.2%. PT 14.5 seconds (12.5 seconds), APTT 42.4 seconds (31.1 seconds), fibrinogen 128 mg/dL, D-Dimer 0.1. Chest radiology was normal. FAST (focus assisted Sonography on trauma) ultrasonography found a large amount of free fluid on di hepatorenal and splenorenal space, between intestine and perivesical space, with no debris nor fibrin within the fluid suggesting of massive ascites.

Based on data collection, the diagnosis was general peritonitis suspected caused by perforated viscous (stomach) with hypovolemic shock. Patient undergone cito laparotomic exploration. When peritoneum was incised, there was blood on abdominal cavity of about 3,000 cc. On exploration, the liver was nodular on segmen 3, 4, 7 with active bleeding from tumour on segmen 1. Packing dressing was installed on the tumour because bleeding did not stop with stitching. On the next day patient was relaparotomized to remove the packing. At that time, bleeding had stopped.

Post operation, patient was admitted to ICU (intensive care unit) for 8 days. After patient

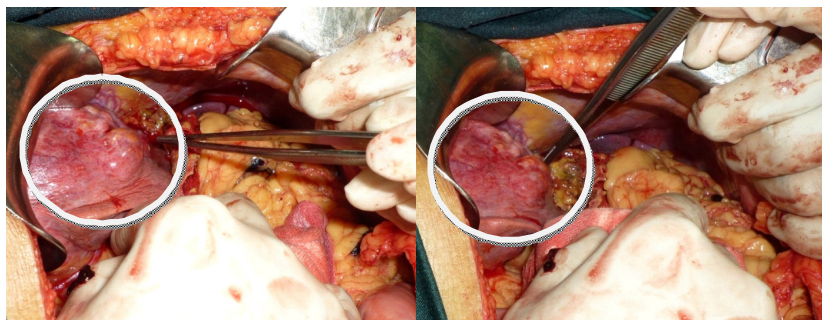


Figure 1. Hepatocellular carcinoma nodules on segmen 1 found intraoperative

recovered and stable, he was moved to internal medicine ward and prepared to discharge from hospital.

DISCUSSION

Hepatocellular carcinoma (HCC) is the most common primary liver malignancy in Africa and Asia Pacific.¹ Cholangio-hepatocellular carcinoma (CHH) is a seldom variant that histologically resembles HCC and cholangiocarcinoma. CHH behaviour resembles HCC but tends to be more aggressive and more advanced on diagnosis. Spontaneous rupture was not rare and usually happened without warning with fatal consequences.¹ Spontaneous rupture is acute complication with high mortality rate.

Mechanisms of spontaneous rupture was not clear. Some hypothesis stated the role of rapid growth of the tumour, venous hypertension, trauma or compression by diaphragm that related to breathing movement, coagulopathy and thrombocytopenia.²

Rapid growth caused the tumour to exceed vascular supply, causing necrosis with intra tumour bleeding. HCC is a vascular tumour with its main supply from hepatic artery, causing high intra tumour pressure that can dissect. The bridging of hepatic capsule caused intra peritoneal bleeding. This is the most common excepted hypothesis at present.

Venous hypertension, invasion or thrombosis, coagulopathy and thrombocytopenia increased risk of rupture. Other factors that contributed was the large size of tumour, located peripherally and extra hepatic extension.^{2,3} Rupture of tumour within the liver can be asymptomatic or causing

pain, on the other hand peripherally located tumour caused hemoperitoneum with peritonitis and hemodynamic instability.² A study by Bassi et al. found that tumor size did not correlate with severity of the hemoperitoneum.⁴ This patient had multiple tumour with high possibility of necrosis and were located peripherally. Coagulopathy and thrombocytopenia seems to play minor role in this patient.

Diagnosis of ruptured HCC was made based on symptoms and signs, imaging examination and bloody ascites fluid. Main symptoms was abdominal tenderness, acute blood loss and shock. Other symptoms and signs were distended abdomen, hypotension, abdominal tenderness and tachycardia. Imaging examination of choice was abdominal CT scan. But sensitivity of imaging was still low, a study showed CT scan and ultrasonography can only diagnose 13% ruptured HCC patients. The use of ultrasonography can increased sensitivity. The presence of ascites, extravasation of contrast and tumour contour defect support ruptured HCC. Enucleated sign on helical CT scan was more specific of ruptured HCC. Bloody ascites diagnosed with paracentesis, but not routinely done. Bloody ascites occurred on 33% HCC patients without rupture, possibly caused by oozing bleeding due to portal hypertension. On acute hemoperitoneum, erythrocyte count can exceed $1 \times 10^6/\text{mm}^3$ with hematocryte exceeding 3%.^{1,2} This patient only undergone FAST (Focus Assisted Sonography on Trauma) ultrasonography that found massive ascites. No symptoms, signs nor history of chronic liver disease nor HCC found, making it difficult to choose imaging modality to confirm etiology

of peritonitis. The etiology of peritonitis was found on laparotomic exploration, which is hemoperitoneum caused by ruptured HCC.

Management of ruptured HCC are resuscitation of hypovolemic shock, bleeding control and management of HCC.^{1,2} In 1960–1980, resection with tumour excision was the main method. There were many procedures such as perihepatic packing, plication of bleeding tumour with suture, alcohol injection, hepatic artery ligation and liver resection. Patients with poor condition are not suitable for these methods. Artery embolization as an effective and safe choice until patients stabilized to undergo surgery or radiofrequency ablation to manage ruptured HCC.² Transarterial Embolization (TAE) is a palliative procedure that was done when liver function was compromised such as Child Pugh C or multifocal or bilobar HCC. Radiofrequency ablation can also be done to manage ruptured HCC.² Other study concludes that any lesion should be considered for surgery

if a low-risk curative resection is possible in a Child A-B patient, if necessary and possible this intervention may be delayed.⁴ **Figure 2** describe algorithm of management patient with spontaneous ruptured HCC.^{6,7} This patient undergone perihepatic packing dressing because the rupture was found on laparotomy, instead of TAE.

Survival time and survival rate in patient with ruptured HCC was short. A study compared management with TAE and conservative therapy showed survival time of 244.8 days vs. 13.1 days. Survival rate with conservative therapy on day 7 was 59.4%; day 14 was 37.5%; day 30 was 6.3%; and with TAE on 3 months was 56.3%; 12 months 23.4%; 24 months 15.6%. Factors related to short term mortality (less than 3 weeks) were poor liver function and incompatibility to TAE therapy. In patients with TAE therapy that survived, independent factor of long term survival (more than 3 weeks) was tumour size smaller than 7 cm.⁷

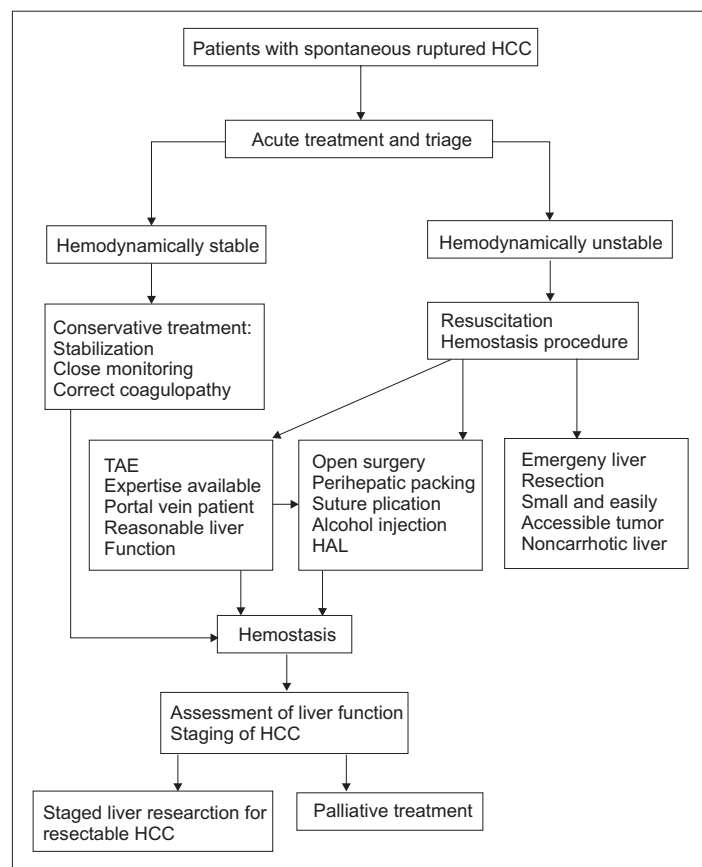


Figure 2. Management algorithm of spontaneous rupture of HCC.⁶

CONCLUSION

This case report a male, 46 years old with generalized peritonitis suspected caused by perforated viscous (stomach) with complication of hypovolemic shock. After laparotomic explaration, blood was found within abdominal cavity, from bleeding tumour on segmen 1 and nodular liver on segmen 3, 4, and 7, indicating a spontaneous ruptured HCC. Packing dressing was done, continued with packing removal on the next days. After laparotomy patient recovered and discharged in good condition.

In the case of acute abdomen, spontaneous ruptured HCC was one of differential diagnosis, considering high incidence of HCC in South East Asia, especially Indonesia. Confirmation diagnosis of generalized peritonitis requires abdominal CT scan and ultrasonography, making a more precise diagnosis and management.

REFERENCES

1. Paracha SJ, Jalihal A, Telisinghe PU, Chong VH. Haemoperitoneum secondary to spontaneous rupture of liver tumour. *Brunei Int Med J.* 2011;7(3):181-5.
2. Buczkowski AJ, Kim PTW, Ho SG, et.al. Multidisciplinary management of ruptured hepatocellular carcinoma. *J Gastrointest Surg.* 2006;10:379-86.
3. Reso A, Ball CG, Sutherland FR, Bathe O, Dixon E. Rupture and intra-peritoneal bleeding of a hepatocellular carcinoma after a transarterial chemoembolization procedure: a case report. *Cases J.* 2009;2:68-70.
4. Bassi N, Caratozzolo E, Bonariol L, et al. Management of ruptured hepatocellular carcinoma: Implications for therapy. *World J Gastroenterol.* 2010;16(10):1221-5.
5. Keller D, Capozza T, Gable E. Ruptured hepatoma With hemorrhagic ascites. *Clin Gastroenterol Hepatol.* 2009;7:32-41.
6. Lai ECH, Lau WY. Spontaneous rupture of hepatocellular carcinoma. A systematic review. *Arch Surg.* 2006;141:191-8.
7. Kirikoshi H, Saito S, Yoneda M, et al. Outcomes and factors influencing survival in cirrhotic cases with spontaneous rupture of hepatocellular carcinoma: a multicenter study. *BMC Gastroenterol.* 2009;9:29.