

Immunoreactivity of CD99 and Melan-A in ovarian fibromas and fibrothecomas.

Dimosthenis Miliaras, Soutana Meditskou, Theodora Papamitsou

Laboratory of Histology and Embryology, Medical School, Aristotle University, Thessaloniki, Greece

ABSTRACT: Sex cord-stromal tumors comprise a group of ovarian neoplasms with different as well as overlapping histological, immunohistochemical and clinical characteristics. Various antibodies have been recently used in order to define the immunoprofile of each category, including CD99 and Melan-A. The reason we have undertaken this investigation is because fibromas/fibrothecomas is the least studied category within this group. In this study paraffin sections from 26 ovarian fibromas/fibrothecomas were immunostained for CD99 and Melan-A. Immunohistochemical reaction was evaluated in a 0 to 3 scale. Nine tumors (34.6%) were positive to CD99: 6 with +2 reaction, and 3 with +1 reaction. All tumors were negative to Melan-A. We conclude that in contrast to what is already known from the limited literature regarding the immunoprofile of ovarian fibromas/fibrothecomas, some of these tumors may present a weak to moderate reaction to CD99, as other tumors within this group.

Key Words: Ovary, Fibroma, Fibrothecoma, CD99, Melan-A.

INTRODUCTION

Sex cord-stromal tumors comprise a group of ovarian neoplasms with different as well as overlapping histological, immunohistochemical and clinical characteristics. Various antibodies have been recently used in order to define the immunoprofile of each category, including CD99 and Melan-A.

CD99 (Cluster of Differentiation 99) also known as MIC2 or single-chain type-1 glycoprotein is a human protein encoded by the CD99 gene. It is a cell surface glycoprotein involved in leukocyte migration, T-cell adhesion, ganglioside GM1 and transmembrane protein transport, and T-cell death by a caspase-independent pathway¹. In addition, the encoded protein may have the ability to rearrange the actin cytoskeleton and may also act as an oncosuppressor in osteosarcoma. Cyclophilin A binds to CD99 and may act as a signaling regulator of CD99². This gene is found in the pseudoautosomal region of chromosomes X and Y and escapes X-chromosome inactivation. Two tran-

script variants encoding different isoforms have been found for this gene.

The MART-1 / Melan-A antigen is specific for the melanocyte lineage, found in normal skin, the retina, and melanocytes. It is thus useful as a marker for melanocytic tumors (melanomas) with the caveat that it is normally found in benign nevi as well³. MART-1 / Melan-A is a putative 18 kDa transmembrane protein consisting of 118 amino acids. It has a single transmembrane domain. The Melan-A/MART-1 antigen is also expressed in Leydig cells, adrenal tissue, and steroid-secreting tumors⁴.

The reason we have undertaken this investigation is because fibromas/fibrothecomas is the least studied category within this group.

MATERIAL AND METHODS

Our study includes 26 consecutive cases diagnosed as ovarian fibromas or fibrothecomas during the last six years. For each case hematoxylin and eosin-stained slides were evaluated to confirm the original diagno-




Figure 1. Fibroma with moderate positivity to CD99 antibody. (DAB, hematoxylin, 100X).

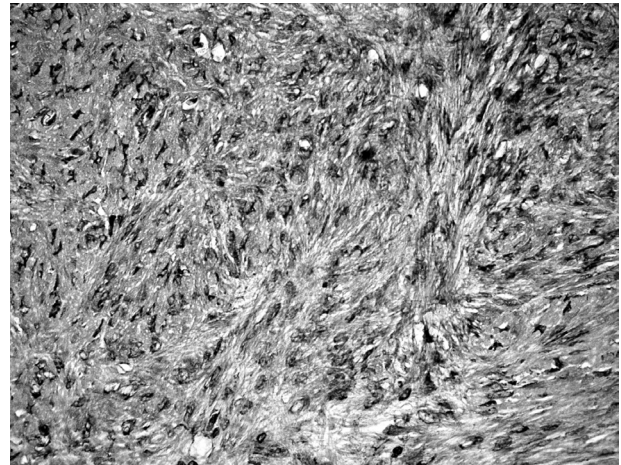


Figure 2. Many fibroma cells present immunoreactivity to CD99 (DAB, hematoxylin, 400X).

sis. Tumors were classified as fibromas or fibrothecomas (unclassified tumors of thecoma-fibroma group according to WHO, 2003⁵) using standard criteria (WHO, 2003⁵). Immunohistochemical detection of CD99 and Melan-A was performed on formalin-fixed, paraffin-embedded tissue sections, 3- μ m in thickness. High temperature antigen unmasking in electric pressure cooker, and TrilogyTM solution (Cell Marque, Rocklin, CA, USA) pretreatment preceded the main procedure. A standardised automated (Nexes, Ventana, Tuscon, AZ, USA), streptavidin-biotin method (I-VIEW Paraffin DAB, Ventana) followed the application of the monoclonal antibodies. The latter were directed against CD99 (clone HO36-1.1, Novocastra, Newcastle, UK) with a dilution of 1:50, and Melan-A (clone A103, Dako, Glostrup, Denmark) with a dilution of 1:50. An adult granulosa tumor with diffuse 3+ positivity for CD99, and a malignant melanoma with diffuse 3+ positivity for Melan-A were used as positive controls. A negative control for immunostaining was carried out by replacing the primary antibody with non-immune rabbit serum. The intensity of staining was graded as either absent, weak, moderate or strong (0 to 3 scale).

RESULTS

Fourteen tumors were regarded as ovarian fibromas, while the rest 12 as fibrothecomas. One fibroma was bilateral. Nine tumors (34.6%) were positive to CD99,

while all tumors were negative to Melan-A. More specifically 8/14 (57,14%) fibromas, and 1/12 (8,33%) fibrothecomas were CD99-positive. Six out of the eight CD99-positive fibromas presented 2+ score (figures 1 and 2), and the remaining two had 1+ staining score. The single positive fibrothecoma presented 1+ staining reaction.

DISCUSSION

Fibromas are stromal tumors of the ovary composed of spindle, oval or round cells producing collagen⁵. They account for 4% of all ovarian tumors, and they are most common in the middle age. Fibromas may be found incidentally, but when large may present with no-specific signs and symptoms of a pelvic mass. Ten to fifteen percent of fibromas larger than 10 cm may be accompanied by ascites and/or pleural effusion (Meigs syndrome). Ovarian fibromas are considered benign neoplasms. However, rare cellular fibromas may recur in the pelvis or upper abdomen, sometimes after a long interval. Fibromas have some common features with thecomas, and in essence these two categories form a continuous spectrum of stromal ovarian tumors that includes those composed entirely of fibroblasts producing collagen (fibromas), those containing predominantly theca cells (thecomas), and in between fibrothecomas that contain both components in various proportions.

Many immunohistochemical markers have been

previously studied in various types of ovarian sex cord-stromal tumors⁶⁻¹⁰. The limited literature for these tumors shows that sensitivity for sex cord-stromal lineage may vary between markers, while some markers may not be as sensitive in some types of sex cord-stromal tumors compared with other tumors in this spectrum of neoplasms. In the largest published series, Zhao et al reported that SF-1 is the most sensitive sex cord-stromal marker among the most common types of sex cord-stromal tumors⁶. The most informative sex cord-stromal markers for the distinction from nonsex cord-stromal tumors are considered to be inhibin, calretinin, SF-1, and WT1. Melan-A expression seems to be restricted to the Leydig cell component

of these tumors. In addition, Zhao et al noted that utility of immunohistochemistry for the diagnosis of fibroma/fibrothecoma is somewhat limited, and also that CD99 is negative in these tumors. In contrast to the findings of this large series, we found that some of fibromas/fibrothecomas are CD99-positive. Most impressively this positivity concerns more than half of the pure fibromas. We conclude that CD99, which is widely present in various other tumors, may be frequently expressed in ovarian fibromas, especially the ones with pure fibromatous histology. This finding has to be confirmed from other studies, since this category of tumors is the least tested within the sex cord-stromal tumors group.

Ανοσοϊστοχημική αντίδραση του CD99 και Melan-A στα ινώματα και τα ινοθηκώματα της ωοθήκης.

Δημοσθένης Μηλιαράς, Σουλτάνα Μεδίτσκου, Θεοδώρα Παπαμήτσου

Εργαστήριο Ιστολογίας-Εμβρυολογίας, Ιατρική Σχολή, Αριστοτέλειο Πανεπιστήμιο Θεσσαλονίκης

ΠΕΡΙΛΗΨΗ: Οι όγκοι γεννητικής ταινίας-στρώματος αποτελούν μία ομάδα νεοπλασμάτων της ωοθήκης με διαφορετικά, αλλά και αλληλεπικαλυπτόμενα ιστολογικά, ανοσοϊστοχημικά και κλινικά χαρακτηριστικά. Διάφορα αντισώματα έχουν χρησιμοποιηθεί πρόσφατα προκειμένου να καθορισθεί ο ανοσοφαινότυπος της κάθε κατηγορίας, συμπεριλαμβανομένων των CD99 και Melan-A. Ο λόγος που διενεργήσαμε αυτή τη μελέτη ήταν ότι τα ινώματα και τα ινοθηκώματα είναι η λιγότερο μελετημένη κατηγορία μέσα σε αυτή την ομάδα. Στην εργασία μας περιλαμβάνονται 26 ινώματα και ινοθηκώματα, τα οποία υποβλήθηκαν σε ανοσοϊστοχημική διερεύνηση με CD99 και Melan-A. Η ανοσοϊστοχημική αντίδραση αξιολογήθηκε σε κλίμακα από 0 έως 3. Εννέα όγκοι (34,6%) ήταν θετικοί στο CD99, έξι με αντίδραση +2 και τρεις με αντίδραση +1. Όλοι οι όγκοι ήταν αρνητικοί στο Melan-A. Συμπεραίνουμε ότι σε αντίθεση με ότι είναι γνωστό από την περιορισμένη βιβλιογραφία για τον ανοσοφαινότυπο των ινομάτων και ινοθηκωμάτων της ωοθήκης, μερικά από αυτά εμφανίζουν μία ήπια έως μέτρια θετική αντίδραση στο CD99.

Λέξεις Κλειδιά: Ωοθήκη, Ίνωμα, Ινοθήκωμα, CD99, Melan-A.

REFERENCES

1. Yoon SS, Jung KI, Choi YL, Choi EY, Lee IS, Park SH, et al. Engagement of CD99 triggers the exocytic transport of ganglioside GM1 and the reorganization of actin cytoskeleton. *FEBS Lett* 2003; 540:217-22.
2. Kim HJ, Chong KH, Kang SW, Lee JR, Kim JY, Hahn MJ, et al. Identification of cyclophilin A as a CD99-binding protein by yeast two-hybrid screening. *Immunol Lett* 2004; 95:155-9.
3. Jungbluth AA, Busam KJ, Gerald WL, Stockert E, Coplan KA, Iversen K, et al. A103: An anti-melan-a monoclonal antibody for the detection of malignant melanoma in paraffin-embedded tissues. *Am J Surg Pathol* 1998; 22:595-602.
4. Busam KJ, Iversen K, Coplan KA, Old LJ, Stockert E, Chen YT, et al. Immunoreactivity for A103, an antibody to melan-A (Mart-1), in adrenocortical and other steroid tumors. *Am J Surg Pathol* 1998; 22:57-63.
5. Tavassoli FA, Mooney E, Gersell DJ, McCluggage WG, Konishi I, Fujii S, et al. Sex cord-stromal tumours. In Tavassoli FA, Devilee P, eds. *World Health Organization Classification of Tumours: Pathology and Genetics of Tumours of the Breast and Female Genital Organs*. Lyon: IARC Press, 2003: 146-61.
6. Zhao C, Vinh TN, McManus K, Dabbs D, Barner R, Vang R. Identification of the most sensitive and robust immunohistochemical markers in different categories of ovarian sex cord-stromal tumors. *Am J Surg Pathol* 2009; 33:354-66.
7. Yao DX, Soslow RA, Hedvat CV, Leitao M, Baergen RN. Melan-A (A103) and inhibin expression in ovarian neoplasms. *Appl Immunohistochem Mol Morphol* 2003; 11:244-9.
8. Hildebrandt RH, Rouse RV, Longacre TA. Value of inhibin in the identification of granulosa cell tumors of the ovary. *Hum Pathol* 1997; 28:1387-95.
9. Matias-Guiu X, Pons C, Prat J. Müllerian inhibiting substance, alpha-inhibin, and CD99 expression in sex cord-stromal tumors and endometrioid ovarian carcinomas resembling sex cord-stromal tumors. *Hum Pathol* 1998; 29:840-5.
10. Choi YL, Kim HS, Ahn G. Immunoexpression of inhibin alpha subunit, inhibin/activin betaA subunit and CD99 in ovarian tumors. *Arch Pathol Lab Med* 2000; 124:563-9.