

Decompression sickness related to breath-hold diving: A case report.

Styliani Stefanidou, Theodosios Melekos, Maria Kotsiou, Theodore Mesimeris

Hyperbaric Medicine Department, "St. Paul" Gen. Hospital, Thessaloniki, Greece

ABSTRACT: Despite the increasing diving activity, the risk of suffering from decompression sickness after breath-hold diving is often not acknowledged.

This case shows that repetitive breath-hold dives, particularly the deep ones with short time of surface intervals, may trigger the appearance of decompression sickness that usually involves the central nervous system.

Key Words: Decompression sickness, Breath-hold diving.

INTRODUCTION

Decompression sickness is a clinical syndrome which varies in severity and is caused by rapid reduction of the ambient pressure. During the descent stage of a dive the pressure of the inhaled mix of gases is raised progressively in relation to the depth. This results in the increase of the partial pressure of the inhaled gases, oxygen and nitrogen, in the alveoli. Consequently there is a continuously increase in the diffusion of nitrogen from the alveoli to the blood and thence due to the difference in pressure to the tissues¹.

On the contrary during the ascent from the bottom to the surface the difference in pressure of nitrogen causes a different direction of diffusion due to the decrease of the ambient pressure. In a case of a rapid ascent, there is not adequate time for the progressive removal of the excess of nitrogen and as the pressure is not any longer applied to the tissues the dissolved gas may form bubbles intra- or extratissular.

The amount of bubbles varies according to the tissue where they are formed and thus there is a great spectrum of manifestations of decompression sickness from the absence of symptoms to a multisystem severe clinical syndrome.

It is also note worthy that the central nervous system, particularly the spinal cord, is very vulnerable to

decompression sickness and this form of decompression sickness is considered as the most serious one. This severe clinical symptomatology is imposed by the bubbles concentration in its venous complexes and the presence of lipoids (myelin), which is a tissue with high solubility of nitrogen^{2,3}.

The possibility of decompression sickness occurrence increases proportional to the duration and the depth of the dive. For that reason it was considered that decompression sickness could only occur during scuba diving (with the use of breathing apparatus) and never during breath-hold diving.

A relatively rare clinical syndrome which was first recognized in 1960 is Taravana syndrome. In this syndrome decompression sickness occurs after extended breath-hold diving.

CASE REPORT

Male, of Italian origin, aged 35, was referred to our Hyperbaric Medicine and Diving Department due to neurological symptoms after breath- hold diving.

The patient, who is a professional skipper and free diving record- seeker, has practiced breath- hold diving for 2.5 hours the previous day. He performed approximately 15 dives at 45meters depth with a 5 minutes recuperation time on the surface between the

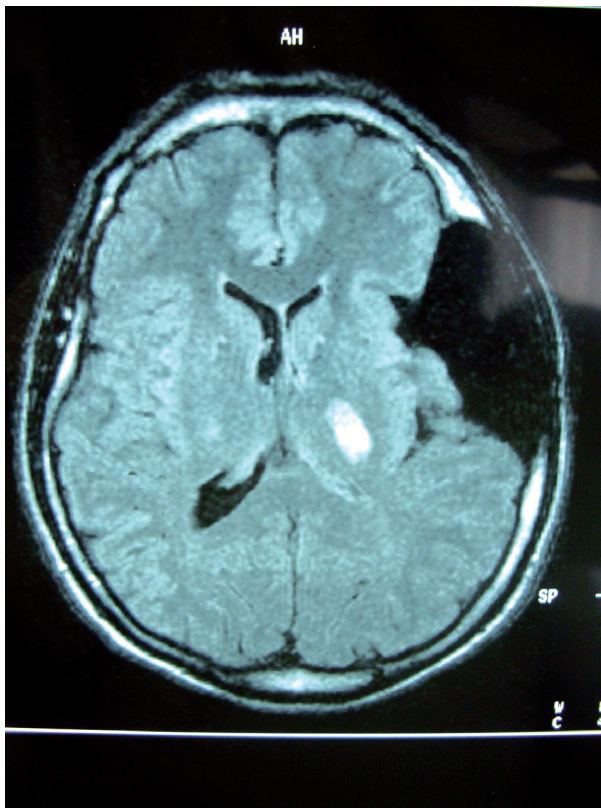


Figure 1. MRI on the arrival.

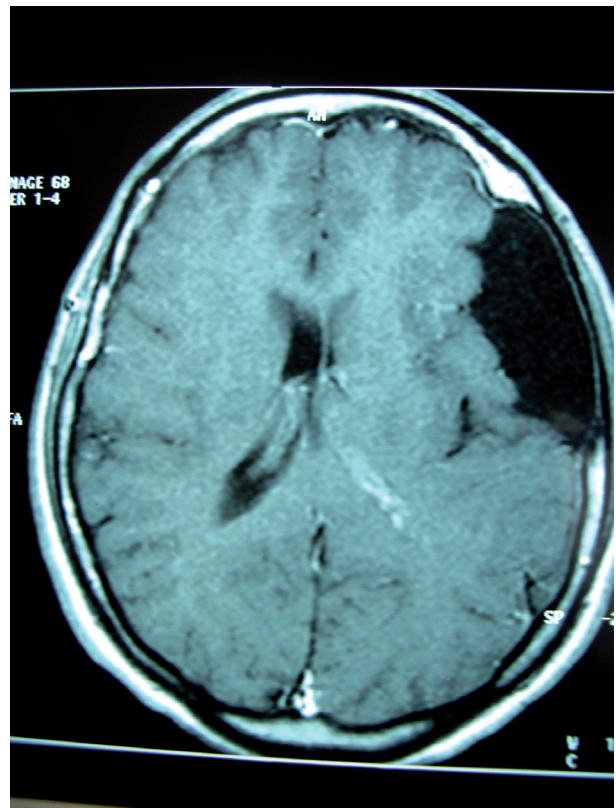


Figure 2. MRI after the treatment.

dives. Immediately after his last dive he presented acute headache of the right parietotemporal area and right paresis as well as paresthesia of the right part of the body.

Initially he was transferred to the local hospital where during the clinical examination decrease in muscular strength and tone of the right arm and leg (Barre' positive) were observed, while the findings from the laboratory tests were normal.

A CT scan of the brain was also performed and an extended low density's area at the left temporal area of the brain was apparent.

Despite the treatment with corticosteroids (2gr Dexamethasone bolus) and mannitol (200cc), the patient presented further deterioration of his neurological status and he was transferred to our Department.

Neurological assessment consisted of good level of consciousness and communication, moderate paresis of facial nerve (VII), paresthesia of the right part of the body, right paresis, body balance disturbance and inability to walk without support. Romberg test was positive whereas the tendon reflexes were normal.

The findings from the clinical examination and the history of the patient imposed the syndrome of decompression sickness type II (neurological). He was submitted to the proper therapeutic approach according to the modified decompression table Comex 30. Hyperbaric session was also combined with the proper complimentary therapy (infusions, corticosteroids and vasodilators). The patient during the session appeared gradually remission of the symptoms and an improvement in his clinical status.

The next day a brain MRI was performed which revealed acute ischemic lesions at the left basal nuclei and a large arachnoid cyst at the left parietotemporal area (Figure 1) (afterwards the patient reported that the cyst pre-existed). The brain ischemic lesions suggested multiple cerebral infarctions.

Although he was recommended to undergo a transesophageal echocardiography for investigation of the possibility of atrial septal defect he refused.

Thirteen further hyperbaric sessions were performed and the patient gradually presented full recovery.

He underwent a second brain MRI after 7 days which showed significant decrease of the size of the ischemic lesions, (Figure 2).

DISCUSSION

Decompression sickness is thought to be related to scuba than to breath-hold diving. On the other hand in the diving medical literature an increasing number of cases of decompression sickness after breath-hold diving has been reported during the last years⁴⁻⁹. The clinical symptomatology in those cases involved mainly the central nervous system⁶⁻⁹. In favor of this view magnetic resonance images of breath-hold divers showed multiple cerebral infarcts corresponding to their neurological symptoms^{6,7}.

During the breath-hold diving the nitrogen partial pressure in the lungs increases according to the environmental pressure of the dive's depth. The tissular nitrogen amount is proportional to the diffused gas from the lungs and consequently the deeper dives are associated with more nitrogen upload. If the surface interval is inadequate to eliminate this tissular nitrogen, then it will accumulate with repeated dives¹⁰.

This overload of tissues with nitrogen may result in the formation of nitrogen bubbles. The presence of bubbles triggers a cascade of biochemical and biological reactions which lead to:

1. microcirculatory disturbances, endothelial dis-

ruption, increase of capillary permeability, tissue edema and lesions mostly ischemic ones

2. activation of the leukocytes, platelets aggregation, activation of complementary system and other defense mechanisms of the body³.

The clinical status is very severe in case of bubble arterialization. Atrial septal defect (functional or after forceful Valsava maneuvers) or lung shunts may contribute to "paradoxical" cerebral embolism⁸.

The greater depth, longer bottom time, quicker ascent rate and mainly the short duration of surface intervals are considered as the main factors of appearance of decompression sickness after breath-hold diving^{4,5}. Although the mechanisms of brain damage in breath-hold diving are unclear, the same factors affect the severity of the neurological status according to the literature⁹.

It should also be noted that breath-hold maneuvers induce hypoxia, hypercapnia and various cardiovascular responses typically leading to increase in peripheral resistance and mean arterial pressure, decrease in heart rate and cardiac arrhythmias that deteriorate the clinical status of the diver¹⁰.

In conclusion, decompression sickness is a very rare but possible clinical status when a diver presents symptoms, especially neurological ones, after breath-hold diving. Immediate medical attention from doctors with relevant experience should be provided.

Καταδυτική νόσος μετά από ελεύθερη κατάδυση: Περιγραφή περιστατικού.

Στυλιανή Στεφανίδου, Θεοδόσιος Μελέκος, Μαρία Κώτσιου, Θεόδωρος Μεσημέρης

Μονάδα Υπερβαρικής και Καταδυτικής Ιατρικής, Γ.Ν. Άγιος Πάυλος, Θεσσαλονίκη

ΠΕΡΙΛΗΨΗ Παρά την αυξανόμενη καταδυτική δραστηριότητα ο κίνδυνος εμφάνισης καταδυτικής νόσου μετά από επαναλαμβανόμενες ελεύθερες καταδύσεις συχνά υποεκτιμάται.

Αυτό το περιστατικό καταδεικνύει ότι οι επαναλαμβανόμενες ελεύθερες καταδύσεις, ιδιαίτερα σε μεγάλο βάθος και με μικρά μεσοδιαστήματα επιφανείας, μπορούν να επάγουν καταδυτική νόσο, που χαρακτηριστικά εκδηλώνεται με συμπτώματα από το κεντρικό νευρικό σύστημα.

Λέξεις Κλειδιά: Καταδυτική νόσος, Ελεύθερη κατάδυση.

REFERENCES

1. Mesimeris T. Decompression sickness. *Hippokratia* 2000;4(1):14-18.
2. Moon R, Gorman D. Decompression sickness. In: Neuman T, Thom S. *Physiology and Medicine of Hyperbaric Oxygen Therapy*. 1sted. Philadelphia, Saunders Elsevier, 2008:283-321.
3. Hardy K. The physics of Hyperbaric Oxygen Therapy. In: Neuman T, Thom S. *Physiology and Medicine of Hyperbaric Oxygen Therapy*. 1sted. Philadelphia, Saunders Elsevier, 2008:57-65.
4. Schipke JD, Gams E, Kallweit O. Decompression sickness following breath-hold diving. *Res Sports Med* 2006;14(3):163-178.
5. Lemaitre F, Fahlman A, Gardette B, Kohshi K. Decompression sickness in breath-hold diving: a review. *J Sports Sci* 2009;27(14):1519-1534.
6. Tamaki H, Kohsi K, Sajima S, Takeyama J, Nakamura T, Ando H, et al. Repetitive breath-hold diving causes serious brain injury. *Undersea Hyperb Med* 2010;37(1):7-11.
7. Kohsi K, Katoh T, Abe H, Okudera T. Neurological accidents caused by repetitive breath-hold dives: two cases report. *J Neurol Sci* 2000;178(1):66-69.
8. Gempp E, Blatteau JE. Neurological disorders after repetitive breath-hold diving. *Aviat Space Environ Med* 2006;77(9):971-973.
9. Tamaki H, Kohsi K, Ishitake T, Wong RM. A survey of neurological decompression illness in commercial breath-hold divers (Ama) of Japan. *Undersea Hyperb Med* 2010;37(4):209-217.
10. Edmonds C. Breath-hold diving. In: Edmond C, Lowry C, Penfather J, Walker R. *Diving and subaquatic medicine*. 4thed. London, Arnold, 2002:615-618.