

Ascending septic pylephlebitis with liver abscess development due to appendicitis in an 11-months old infant.

Ioannis Patoulas, Katerina Prodromou, Thomas Feidantsis, Magdalini Mitroudi, Ignatios Kallergis, Georgios Koutsoumis

1st Department of Pediatric Surgery department, Aristotle University of Thessaloniki

ABSTRACT: The development of septic ascending pylephlebitis secondary to gangrenous appendicitis resulting in the development of liver abscess is a rare complication especially in infancy. In this study we refer to an infant 11 months old with the above clinical entity treated successfully in our clinic. Due to this rare occasion, we reviewed recent literature, aiming at the consolidation of clinical and prognostic parameters.

Key Words: Gangrenous appendicitis, Septic pylephlebitis ascending, Liver abscess.

INTRODUCTION

Inflammation of the appendix is the most common surgical disease in childhood¹. Appendicitis rarely occurs in the neonatal period and infancy and it is often diagnosed with delay². In the USA 80000 children undergo appendectomy per year and one third of them present to the hospital with perforation of the inflamed appendix, thus increasing the possibility of developing complications in 58% of cases³.

Ascending septic pylephlebitis with septic clots in the portal vein, stem or branch, such as the superior mesenteric vein, occurs in 0.05% of cases with acute appendicitis and 3% of cases with peritonitis due to rupture of the inflamed appendix⁴. The first description of a liver abscess development caused by inflammation of the appendix followed by septic pylephlebitis was made in 1898 by Dieulafoy⁵ and the first published study was by Ochner in 1938⁶.

This case report refers to an 11 months old female infant who presented with acute abdomen due to appendicitis and was later on diagnosed with ascending septic pylephlebitis. She developed 2 abscesses in the right lobe of the liver. Based on current literature this

complication in correlation with the young age of our patient appears to be very rare.

CASE REPORT

An 11 months-old female infant was admitted to our department with acute abdomen. She had a disease free personal history and her pre- and postnatal periods were uneventful. The onset of the disease was a week prior to admission with fever, abdominal pain, anorexia, drowsiness and diarrhea. After fluid resuscitation an abdominal ultrasound was performed which revealed the presence of a rigid tubular lesion near the right iliac fossa and enlarged mesenteric lymph nodes. Also a small amount of fluid was present (Figure 1). At laparotomy we found: a) the appendix with evidence of inflammation, b) periappendiceal slobbery exudate (sent for cultivation) and c) isolated, enlarged mesenteric lymph nodes. (Figures 2, 3). Appendectomy was performed and a nasogastric tube into the stomach was inserted. The cultivation of peritoneal fluid revealed E.coli. She was administered cefuroxime 50 mg/KWB in 2 doses daily, amikacin 15 mg/ KWB in 2 doses daily and metronidazole 24mg/ KWB in 3 doses daily. The patient was febrile dur-



Figure 1. Ultrasound imaging of the rigid tubular lesion corresponding to the appendix.

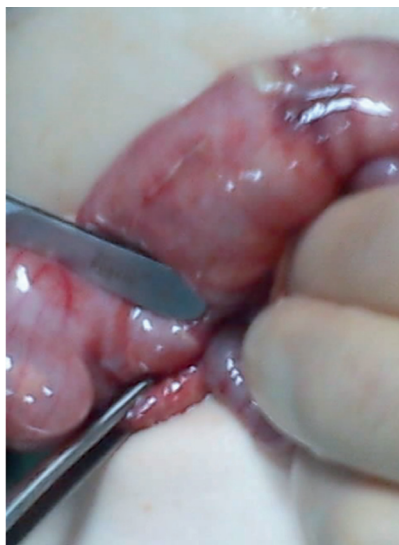

Figure 2. Inflamed appendix at laparotomy.

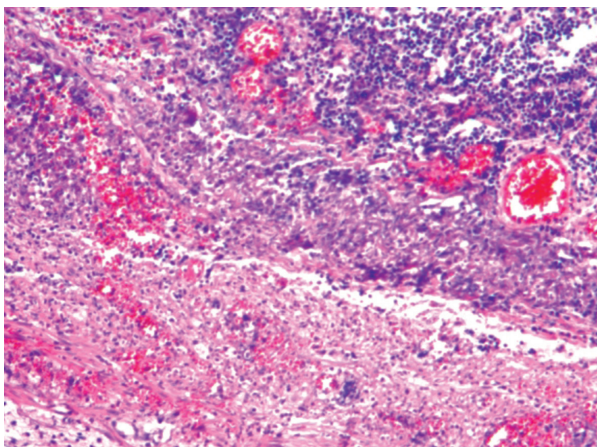


Figure 3. Histopathologic image of appendicitis.

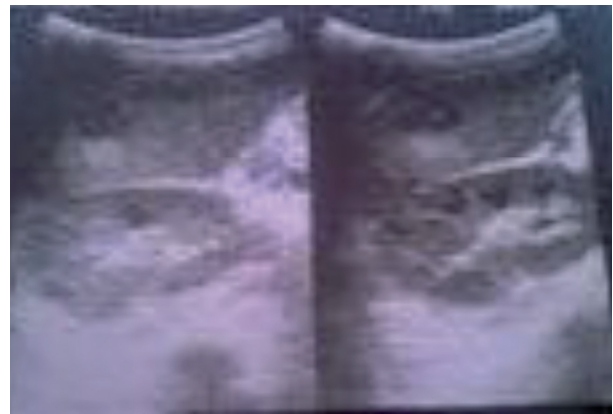


Figure 4. Ultrasound imaging of the largest liver abscess, 1,7 cm in diameter.

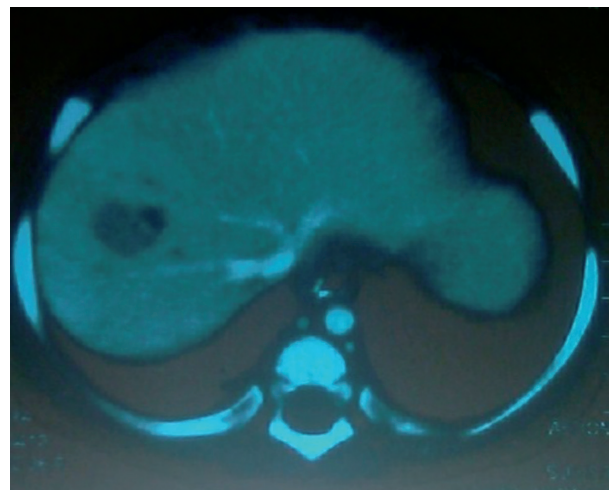


Figure 5. CT scan of the abdomen: a) two liver abscesses and b) septic thrombus into the stem of the portal vein.

ing the first two postoperative days (up to 38.5° C) and had abdominal distention and sparse intestinal sounds. On the second postoperative day white blood cell count was 4000/ml with a lymphocyte type, hematocrit was 24.8% (transfusion of 150 ml of blood was performed) and platelet count was 78000/ml. Liver enzymes were affected and CRP remained elevated (24 mg/dl vs 30 mg/dl preoperatively). During the third postoperative day a small abscess in the right lobe of the liver was detected by ultrasonography. Abdominal CT scan revealed 2 abscesses in the right lobe of the liver, the largest of maximum diameter 1.7 cm and the presence of septic thrombus in the stem of

Table 1. Blood test results during post-operative follow-up.

POD** BTR *	OP ***	1 st	2 nd	3 rd	4 th	5 th	8 th	17 th
WBC μ L	21000	11100	4700	3800	4000	2700	7400	7900
NE %	85.8	66.4	47.7	51.9	15	11	19	24
LY %	8.7	8.7	38.4	29.9	54	85	73	62.1
HCT %	31.4	28.3	23	34.4	34.3	32.7	33.8	32
Hb g/dl	10.5	9.3	8	11.4	11.4	11.3	11.2	10.6
PLT μ L	223000	174000	78000	220000	339000	250000	665000	458000
SGOT U/L	71	121	128	62	57	63	44	72
SGPT U/L	32	92	100	62	44	37	32	31
CRP mg/dl	30	25	24.4	15.5	12.3	11	7	0.7
PT sec				12.6				
Aptt sec				38.2				
Fib g/L				4.6				
Tot bil mg/dl	0.7			0.68		0.71		

* BTR: Blood Test Results

** PO: Post-Operative Days

*** OP: Operation Day (pre-operative blood test results)

the portal vein, without obstruction of the blood flow (Figures 4, 5). The cefuroxime dosage was increased and meropenem (100 mg / KWB / in 3 doses daily) was added. The young patient started to show clinical improvement on the 5th postoperative day and on the 8th postoperative day body temperature was normal. Laboratory results are shown on Table 1.

The abdominal ultrasound was repeated: a) on the 6th postoperative day: there was no thrombus in the stem or the branches of the portal vein and the largest liver abscess was 1.2 cm in diameter b) on the 12th postoperative day: no altered findings and c) on the 18th postoperative day: the largest abscess showed regression (diameter was 7.5 mm). After a follow up period of 3 months portal hypertension has not de-

veloped. In addition, the infant underwent tests for excluding underlying immune system indeficiency including:

- Measurement of serum immunoglobulins.
- Definition of immunophenotype of T / B lymphocytes and phagocytes.
- Definition of serum C1, C2, C3 and C4 levels.

Except for a slight increase in IgG count, all results were within normal limits. The presence of neutropenia led to further investigation of the phagocytic function as judged by the MFI index and DHR assay by flow cytometry: the results were also within normal limits.

DISCUSSION

Septic ascending pylephlebitis may develop after pancreatitis, cholecystitis, inflammatory bowel disease or other intra-abdominal inflammation, such as appendicitis⁷. A serious infection of an organ which has venous drainage to the portal vein or is in close anatomic relation to the portal vein can be complicated by ascending pylephlebitis^{7,8}. The incidence of liver abscesses developing after ascending pylephlebitis due to intraabdominal sepsis is 3-25/100.000 admissions of pediatric patients⁹. This is a very serious complication, even today, with mortality rates extending to 32%¹⁰. Less than 10% of all liver abscesses are secondary to appendicitis⁷. Muorah M and colleagues (2006) describe the treatment of 15 patients with liver abscesses due to intraabdominal infection¹². In this study one 13-year old patient presented with ruptured appendicitis. After literature review, we found no references of patients with liver abscesses due to appendicitis and ascending septic pylephlebitis, aged less than or equal to 11 months

The most common organisms that are responsible for liver abscess secondary to appendicitis are *E.coli* (as in our case), *Bacteroides fragilis*, *Proteus mirabilis*, *Klebsiella pneumoniae*, *Enterobacter* strains and various streptococci^{7,9}.

Disorders of the innate immunity, particularly neutrophil disorders, should be excluded in all cases, even when there is no suggestive history. Our patient was tested for the possibility of predisposing immune deficiency¹¹] and all results were within normal limits.

The clinical findings of this complication are not specific and diagnosis often delayed⁷. The most commonly reported symptoms are fever, nausea, diarrhea and abdominal pain located in the upper abdomen and the right costal margin¹³. Findings also include prominent jaundice, sensitivity to palpation of the liver, hepatomegaly and splenomegaly⁷. In our case there were no clinical signs of improvement after operation, fever insisted, abdominal flatulence was present, restlessness and diarrhea continued. The patient never developed jaundice.

High-resolution computed tomography is considered to be the most appropriate method for the diagnosis of septic ascending pylephlebitis^{7,12,13}. Monitoring the evolution of the septic thrombus and 2 liver

abscesses was possible with the use of ultrasound and Doppler ultrasonography. On the fifth postoperative day the ultrasound scan showed no septic clot within the portal vein and the abscesses were diminishing- the largest one had a diameter of 1,2 cm (compared to 1,7 cm in the first scan).

As part of the therapeutic strategy, since the septic cause had already been removed, we insisted on intravenous administration of broad spectrum antibiotics (meropenem, amikacin and metronidazole). The infant had rapid clinical response: the body temperature was normal on the seventh postoperative day and CRP levels decreased gradually. After 2 weeks of intravenous administration, the antimicrobial therapy was continued by oral administration of second generation cephalosporin for 6 weeks. The requisite time, estimated through similar-based studies but mainly empirically, ranges from 3-4 to 6-8 weeks^{9,13}. The normalization of CRP is a criterion that could be used for evaluating the duration period of administering peros antibiotic therapy^{9,12}. In our case, CRP was normalized by the 17th postoperative day. Image guided (by CT or US) percutaneous drainage of the abscesses was not required, because of their small diameter. Based on current literature this approach is indicated when -despite antimicrobial therapy- the septic condition remains and liver abscesses have large diameters (3, 5-4 cm) without showing decrease in their size^{9,13}. Antithrombotic therapy was not used, because of limited experience of anticoagulants in this age group and early imaging disappearance of the thrombus (on the 6th postoperative day, 3 days after diagnosis of pylephlebitis). Anticoagulant therapy is recommended in cases of persisting sepsis despite administration of antimicrobial therapy and when a septic thrombus extending to the branches of the portal vein is present^{7,12,14}. Intestinal ischemia and necrosis due to extension of the septic thrombus into the superior mesenteric vein reaches up to 5% of cases⁷. Removal of the septic clot using a Fogarty catheter inserted through the ileocolic vein has been described⁸. There is no experience in this therapeutic approach in infants.

Portal hypertension may develop 2-9 months after the development of pylephlebitis (average period 3 months) therefore our patient is still monitored for this potential complication¹².

In conclusion, ascending pylephlebitis with liver abscess development after appendicitis is a rare disorder in childhood and infancy but should be suspected and diagnosed promptly using appropriate investiga-

tion. Therapeutic approach varies but there is little experience in this age group. Awareness of portal venous thrombosis and portal hypertension development is essential.

Ανιούσα σηπτική πυλαιοφλεβίτιδα με ανάπτυξη ηπατικών αποστημάτων λόγω γαγγραινώδους σκωληκοειδίτιδας σε κορίτσι 11 μηνών (παρουσίαση περιστατικού).

Ιωάννης Πατουλιάς, Κατερίνα Προδρόμου, Θωμάς Φειδάντσης, Μαγδαληνή Μητρούδη, Ιγνάτιος Καλλέργης, Γεώργιος Κουτσούμης

Α' κλινική χειρουργικής παιδών του Α.Π.Θ. Ν. Γ. Νοσοκομείο «Γ. Γεννηματάς»

ΠΕΡΙΛΗΨΗ: Η ανάπτυξη ανιούσας σηπτικής πυλαιοφλεβίτιδας απότοκος γαγγραινώδους σκωληκοειδίτιδας με συνέπεια την ανάπτυξη ηπατικών αποστημάτων, αποτελεί σπανιότατη επιπλοκή ιδιαίτερα στη βρεφική ηλικία. Στην παρούσα μελέτη αναφερόμαστε σε βρέφος 11 μηνών με τη παραπάνω κλινική σημειολογία που αντιμετωπίστηκε επιτυχώς στη κλινική μας. Με αφορμή αυτή τη σπανιότατη οντότητα επιχειρήσαμε αναδρομή στην πρόσφατη βιβλιογραφία, στοχεύοντας στην κωδικοποίηση των κλινικών και προγνωστικών παραμέτρων.

Λέξεις Κλειδιά: Γαγγραινώδης σκωληκοειδίτιδα, Ανιούσα σηπτική πυλαιοφλεβίτιδα, Ηπατικό απόστημα.

REFERENCES

1. Henry M, Walker M, Silverman B et al. Risk factors for the development of abdominal abscess following operation for perforated appendicitis in children. Arch. Surg. 2007; 142:236-41.
2. Laohapensang M. Acute abdomen in infancy and childhood. Siraraj Medical J. 2006; 58:821-5.
3. David IB, Buck JR, Filler RM. Rational use of antibiotics for perforated appendicitis in childhood. J. Pediatr.Surg. 1982; 17:494-500.
4. Yu JS, Bennett WF, Bova JG. CT of superior mesenteric vein thrombosis complicating periappendiceal abscess. J Comput Assist Tomogr. 1993; 17:309-12.
5. Dieulafoy: Le foie appendiculaire absces du foie consecutifs a l'appendicite. Semaine Med. 1898; 18:449.
6. Ochsner A, DeBakey M, Murray S. Pyogenic abscess of the liver. Am. J. Surg. 1938; XL:292-319.
7. Chang N, Tang L, Keller K et al. Pylephlebitis, portal-mesenteric thrombosis and multiple liver abscess owing to perforated appendicitis. J. Pediatr. Surg. 2001; 36:19-21.
8. Nashimori H, Ezoe E, Ura H et al. Septic thrombophlebitis of the portal and superior mesenteric veins as a complication of appendicitis: report of case. Surg. Today. 2004; 34:173-6.
9. Sharma MP, Kumar A. Liver abscess in children. Indian J. Pediatr. 2006; 73:813-7.
10. Schwartz ME, Miller CM. Acquired portal occlusion or thrombosis. In Haubrich WS, Schaffner F, Berk JE, eds. Bockus gastroenterology. Vol 35th. Philadelphia: WBSaunders. 1995; 2384-6.
11. Ferreira MA, Pereira FE, Musso C et al. Pyogenic liver abscess in children: some observations in the Espirito Santo State Brasil. Arq. Gastroenterol. 1997; 34:49-54.
12. Muorah M, Hinds R, Verma A, Yu D, Samyn M et al. Liver abscess in children: a single center experience in the developed world. J. Pediatr. Gastroenterol. Nutrition. 2006; 42:201-6.
13. Byun JL, Bae SH, Park SW. A case of pyogenic liver abscess in a 10-year-old girl. Korean J. Pediatr. 2010; 53:666-8.
14. Howard K, Baldassano R, Harty P et al. Ruptured retrocecal appendicitis in an adolescent presenting as portal-mesenteric thrombosis and pylephlebitis. J. Pediatr. Gastroenterol. Nutr. 1998; 27:584-8.