

## Weil's disease and abdominal compartment syndrome

Kostas Tsalis MD, Ioanna Kirou MD, Nikolaos Sapidis MD,  
Dimitrios Botsios MD, Dimitrios Betsis MD

*4<sup>th</sup> Surgical Department, Aristotle University of Thessaloniki, «G. Papanikolaou» General Hospital,  
Exohi, Thessaloniki 57010, Greece*

**ABSTRACT:** *Purpose:* To report a rare complication of Weil's disease.

*Report of case:* A 47-years-old man was referred to ICU of our hospital in shock. The clinical findings and the serological tests established the diagnosis of Weil's disease. After the patient became haemodynamic stable, underwent a cholecystectomy for acute acalculous cholecystitis, while ten days later he developed abdominal compartment syndrome (ACS). The later, was successfully managed surgically, with decompression laparotomy, placement of a 3 lit TPN (Total Parenteral Nutrition) bag to cover the viscera and gradual closure of the abdomen by tying the tension sutures each time more tight. The patient returned home after two months of hospitalization, in a good general condition.

*Conclusion:* Patients with Weil's disease seem to be susceptible to the development of ACS. The clinicians must be always suspicious for the possibility of its occurrence, in order to have an early diagnosis and a therapeutic surgical intervention.

*Key Words:* Weil's disease, Abdominal compartment syndrome, Decompression laparotomy.

### INTRODUCTION

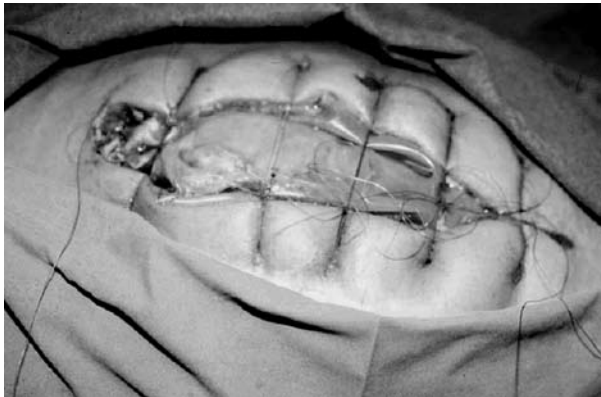
Weil's disease is the representative severe form of Leptospirosis. Case fatality for this syndrome has been reported to be over 10%, which is attributed to a large number of complications that have been reported to accompany it<sup>1</sup>.

We, herein, present a rare complication of Weil's syndrome that was managed surgically to our Unit.

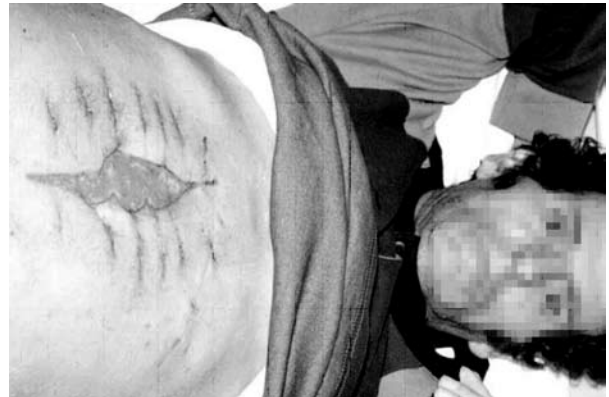### CASE REPORT

A 47-years-old man was referred to ICU of our hospital in shock. The man was icteric and suffered from acute renal failure (serum creatinine: 5,1mg/dl), adult respiratory distress syndrome (ARDS) and thrombocytopenia (20.000/mm<sup>3</sup>). The patient's history revealed fever, chills, headache and myalgia since a week, while clinical examination showed jaundice, abdominal pain, and bleeding diatheses. Four days after his initial admission, the patient became haemodynamic stable with large volume resuscitation, transfusions, mechanical ventilation and continuous arteriove-

nous hemodialysis. The clinical presentation and the serological tests established the diagnosis of Weil's disease, while the laboratory findings were: Hct:28%, WBC:12950/mm<sup>3</sup>, urea:230mg/dl, creatinine:5,7mg/dl, Total bilirubine:24,2 mg/dl. Exacerbation of the abdominal pain leads to ultrasonography (US) of the abdomen, which revealed acute acalculous cholecystitis. The patient underwent an open cholecystectomy and returned to ICU. Ten days later, there was an aggravation regarding his respiratory and renal function, while the intra-abdominal pressure (IAP) measurement showed the development of abdominal compartment syndrome (ACS, IAP: 40mmHg). The man underwent a decompression laparotomy during which serosanguineous fluid into the peritoneal cavity and hemorrhagic infiltration of the retroperitoneal space were found. After the intra-abdominal fluids were drained, the abdomen left open with a 3 lit TPN (Total parenteral Nutrition) bag covering the viscera. In particular, the TPN bag was cut to size and applied to the wound edges while, tension sutures (prolene



**Image 1.** Tension sutures after retying.



**Image 2.** The patient before his discharge from the hospital.

0.0) were put to the abdomen walls. As abdominal distension was reversed, the loosened sutures were untied and tied again more tightly, enabling the closing up of the abdominal walls (Image 1) and resulting to the final healing of the wound without the need of a secondary operation (Image 2). Two weeks later the IAP was 4mmHg. The man returned home two months after his initial admission, in a good general condition.

### DISCUSSION

Weil's disease is a syndrome that represents the severe clinical manifestation of leptospirosis, characterized by jaundice, renal failure and haemorrhage with a variable clinical course. It can be rapidly become fatal and the mortality rate range from 5% to 15%<sup>2</sup>.

In the line of the biphasic clinical presentation of leptospirosis, this syndrome become apparent in the second, immune phase, which is associated with localization of leptospire within the tissues and a broad range of complications<sup>2</sup>. In contrast, the first, septicemic phase of the disease is characterized by a subclinical course or mild, non-specific symptoms which often are underestimated or even misdiagnosed<sup>2,3</sup>. It has been reported that the initiation of antibiotic therapy at this early phase provides great benefit, as it can attenuate the progress of the disease to the second stage<sup>4,5</sup>. Therefore, the timely diagnosis followed by the appropriate medical intervention is essential in order to avoid severe complications, even lethal, and in most cases is depending on a high index of suspicion among clinicians.

The complications that have been reported to associate with Weil's syndrome reveal the multisystemic nature of the disease, and include hepatic and renal impairment, hemorrhage, vascular collapse, respiratory, cardiac, myoskeletal, ocular complaints and many other pathologic entities<sup>2,4</sup>. To our knowledge, Weil's disease has never been associated with abdominal compartment syndrome (ACS). Abdominal compartment syndrome is defined the sustained increase of intra-abdominal pressure (IAP>20 mmHg), that adversely affects the circulation and threatens the function and viability of the tissues. Among conditions that have been reported to predispose to ACS are diseases of abdominopelvic region that require surgery, complex abdominal surgery and the large-volume resuscitation<sup>6-8</sup>. Patients with Weil's disease, experience multiorgan dysfunction and excessive loss of fluids due to a diffuse vasculitis characterized by endothelial damage and increased vascular permeability<sup>4</sup>. In the line of the multiorgan dysfunction, a rare complication of the disease is the acalculous cholecystitis, which when receiving necroticizing characteristics becomes a surgical emergency<sup>4</sup>. The aggressive resuscitation to these critical ill patients, in addition to an urgent surgical intervention seem to comprise crucial contributors for the development of ACS (present case). The latter may aggravate the function of the already suffered organs, resulting in irreversible conditions. There are many options regarding the ACS management<sup>9</sup>. We used a technique that comprises a modification of these methods, and employs a clear plastic, non-adherent sheet such as

the TPN bag, applied to the abdominal cavity over the viscera. In addition, with the use of appropriate sutures which were gradually tightened as IAP was reduced, we had the optimal result (closure of the abdomen) without the need of a second surgical intervention which may hinder the recovery course of these critical ill patients.

To our opinion these patients are susceptible to this kind of complication and the clinicians must be always suspicious for the possibility of its existence, in order to have an early diagnosis and a therapeutic surgical intervention.

## Νόσος του Weil και σύνδρομο κοιλιακού διαμερισματος

Κώστας Τσαλής, Ιωάννα Ε. Κύρου, Νικόλαος Σαπίδης,  
Δημήτριος Μπότσιος, Δημήτριος Μπέτσης

*Δ' Χειρουργική Κλινική Αριστοτελείου Πανεπιστημίου Θεσσαλονίκης, Νοσοκομείο «Γ. Παπανικολάου»*

**ΠΕΡΙΛΗΨΗ:** Σκοπός της μελέτης: Να παρουσιάσουμε μία σπάνια επιπλοκή της νόσου του Weil.

**Παρουσίαση περιστατικού:** Άνδρας 47 χρονών προσεκομίσθη στη μονάδα εντατικής θεραπείας (ΜΕΘ) του νοσοκομείου μας σε κατάσταση shock. Εκ των κλινικών ευρημάτων και των αποτελεσμάτων των ορολογικών εξετάσεων διεγνώσθη βαριά μορφή Λεπτοσπείρωσης (σύνδρομο Weil). Κατά τη διάρκεια της νοσηλείας του στη ΜΕΘ, ο ασθενής εμφάνισε οξεία αλιθιασική χολοκυστίτιδα για την οποία και υπεβλήθη σε χολοκυστεκτομή. Τη 10<sup>η</sup> μετεγχειρητική ημέρα, παρουσίασε ενδοκοιλιακή υπέρταση και σύνδρομο κοιλιακού διαμερισματος, το οποίο αντιμετωπίσθη χειρουργικά, με λαπαροτομία αποσυμπίεσης και παραμονή ανοικτού του κοιλιακού τραύματος. Για την κάλυψη των ενδοκοιλιακών σπλάγχων χρησιμοποιήθηκε διανογής σάκος ολικής παρεντερικής διατροφής (3 λίτρων) ο οποίος καθλώθηκε στα χείλη του χειρουργικού τραύματος. Ακολούθησε σταδιακή σύγκλιση των κοιλιακών τοιχωμάτων μετά την υποχώρηση της ενδοκοιλιακής υπέρτασης. Μετά από δύο μήνες νοσηλείας, ο ασθενής εξήλθε σε καλή γενική κατάσταση.

**Συμπέρασμα:** Οι ασθενείς με σύνδρομο Weil, φαίνεται να είναι επιρρεπείς στην ανάπτυξη συνδρόμου κοιλιακού διαμερισματος. Θα πρέπει να υπάρχει υψηλός δείκτης υποψίας, προκειμένου να επιτευχθεί έγκαιρη διάγνωση και κατά συνέπεια σωστή θεραπευτική παρέμβαση.

**Λέξεις Κλειδιά:** Νόσος του Weil, Σύνδρομο κοιλιακού διαμερισματος, Λαπαροτομία αποσυμπίεσης.

## REFERENCES

1. Ko AI, Galvao Reis M, Ribeiro Dourado CM, et al. Urban epidemic of severe leptospirosis in Brazil. Salvador Leptospirosis Study Group. *Lancet* 1999, 354: 820-825.
2. Levett PN. Leptospirosis. *Clinical Microbiology Reviews* 2001, 14:296-326.
3. McBride JA, Athanazio DA, Mitermayer G R, Ko AI. Leptospirosis. *Curr Opin Infect Dis* 2005, 18:376-386.
4. Plank R, Dean D. Overview of the epidemiology, microbiology, and pathogenesis of *Leptospira* spp. in humans. *Microbes and Infection* 2000: 1265-1276.
5. WHO. Human leptospirosis: guidance for diagnosis, surveillance and control. Malta: World Health Organization, 2003.
6. Sugrue M. Abdominal compartment syndrome. *Curr Opin Crit Care* 2005, 11:333-338.
7. Kirkpatrick AW, Balogh Zsolt, Ball CG, et al. The Secondary Abdominal Compartment Syndrome: Iatrogenic or Unavoidable? *The American College of Surgeons* 2006, 202:668-679.

8. Vegar-Brozovic V, Stoic-Brezak J. Pathophysiology of Abdominal Compartment Syndrome. *Transplant Proceedings* 2006, 38:833-835.
9. Moore AFK, Hargest R, Martin M, Delicata RJ. Intra-abdominal hypertension and the abdominal compartment syndrome. *Br J Surg* 2004, 91:1102-1110.