

Use of Thrombolytic Therapy for Complicated Pleural Effusions

Lauren E. Sterner
Lauren.Sterner@lvhn.org

Kelly M. Wanamaker MD
Lehigh Valley Health Network, Kelly.Wanamaker@lvhn.org

Katherine M. Penetar DNP, CRNP
Lehigh Valley Health Network, Katherine_M.Penetar@lvhn.org

Sanjay M. Mehta MD
Lehigh Valley Health Network, Sanjay_M.Mehta@lvhn.org

Follow this and additional works at: <https://scholarlyworks.lvhn.org/research-scholars-posters>

Published In/Presented At

Sterner, L. Wanamaker, K. Penetar, K. Mehta, S. (2019, August). *Use of Thrombolytic Therapy for Complicated Pleural Effusions*. Poster Presented at: LVHN Research Scholar Program Poster Session, Lehigh Valley Health Network, Allentown, PA.

This Poster is brought to you for free and open access by LVHN Scholarly Works. It has been accepted for inclusion in LVHN Scholarly Works by an authorized administrator. For more information, please contact LibraryServices@lvhn.org.

Use of Thrombolytic Therapy for Complicated Pleural Effusions

Lauren Sterner, Kelly M. Wanamaker, MD, Katherine M. Penetar DNP, CRNP, Sanjay M. Mehta, MD

Department of Cardiothoracic Surgery

Lehigh Valley Health Network, Allentown, Pennsylvania

BACKGROUND

- A complicated pleural effusion is defined as an accumulation of pleural fluid with fibrin deposits and a non-elastic pleural membrane peel.¹
- Treatment remains controversial; traditionally, surgical decortication has been the mainstay, however there are contraindications and an associated high morbidity.²
- Intrapleural thrombolytic therapy offers an alternative to surgical intervention and alteplase has been shown to be an effective treatment.³

Primary Objective: To determine the efficacy of intrapleural alteplase therapy in treatment of complex pleural effusion. Successful treatment is defined as resolutions or near resolutions in chest radiographs.

Secondary Objective: To compare the length of hospital stay between traditional surgical treatment and that of intrapleural thrombolytic therapy.

METHODS

Retrospective chart review on adult admissions with a complicated pleural effusion treated with either thrombolytic therapy, pigtail tube, or surgical decortication from January 2016 to May 2019.

The following information was collected: age, sex, etiology of pleural effusion, treatment, dosages of alteplase, success of treatments, complications and length of stay.

Descriptive statistics were used to evaluate the primary and secondary objectives and to summarize the details of each encounter.

OUTCOMES

- 98 patients total; 70 male, 28 female.
- 32 (32.7%) were treated with thrombolytic therapy and resulted in full resolution in 84.4% of cases (27 out of 32 patients).
- Five patients had an incomplete response to alteplase treatment, four of which required video-assisted thoracic surgery (VATS). The one patient was not a surgical candidate and received antibiotic therapy.

Figure 1. Pleural effusion etiology for those with full resolution after thrombolytic therapy treatment.

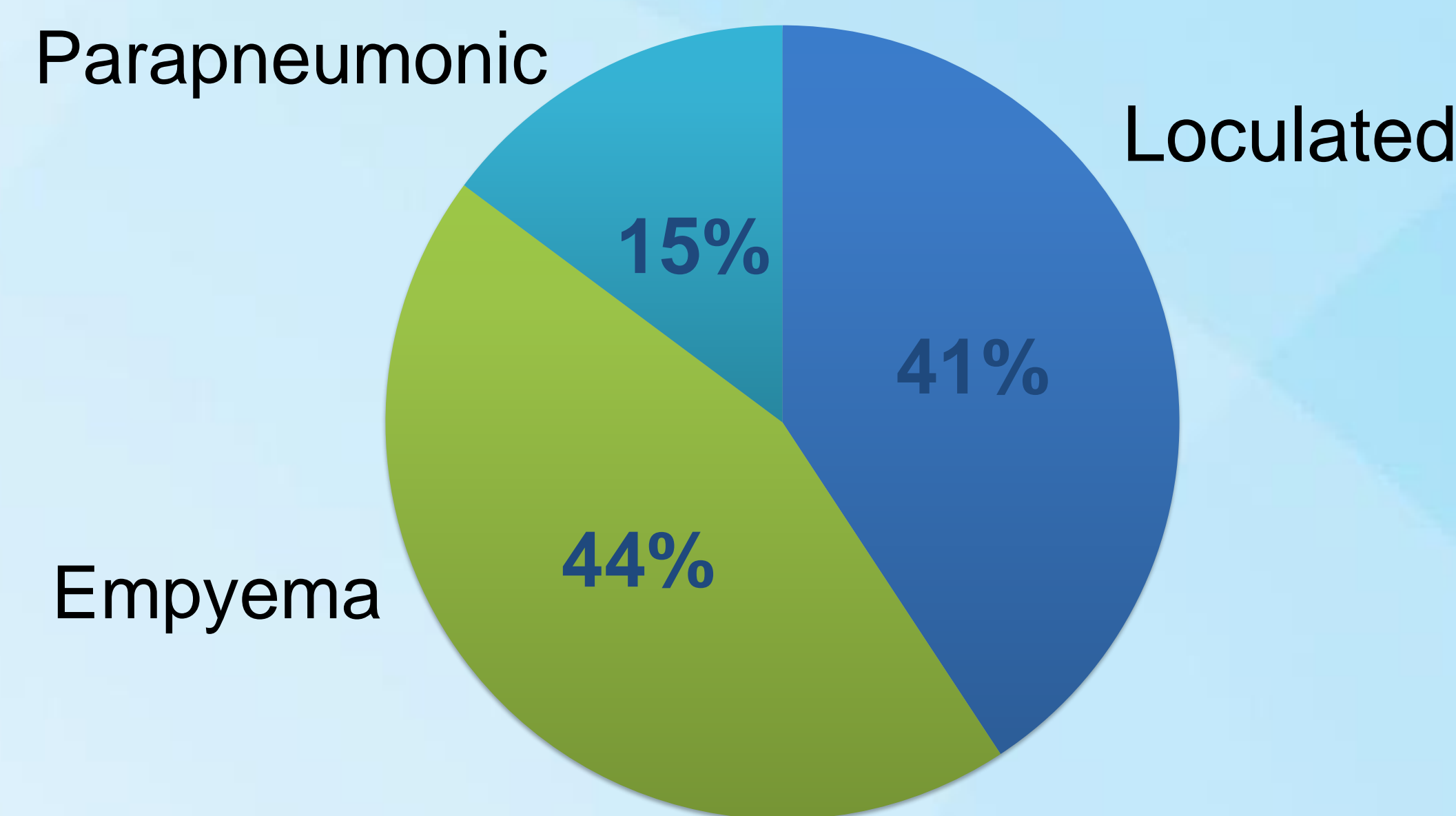



Figure 2. Average doses of alteplase based off the outcome of the thrombolytic therapy.



RESULTS

Table 1. Comparison of Thrombolytic Therapy to Surgical Intervention.

	N (%) Md (IQR)
Incidence of Full Resolution	
Alteplase therapy	27 (84.4%)
Surgical intervention	32 (96.7%)
Complications	
Alteplase therapy	
Bleeding	0 (0%)
Sepsis	2 (6.25%)
Respiratory failure	2 (12.5%)
Other	4 (6.25%)
Surgical intervention	
Bleeding	1 (3.03%)
Sepsis	5 (15.2%)
Respiratory failure	2 (3.03%)
Other	1 (3.03%)
Length of stay	
Alteplase therapy	6.5 (9.5)
Surgical intervention	8 (9)

CONCLUSIONS

- Overall, surgical intervention resulted in more cases of complete resolution, but had a longer length of stay.
- Those who had incomplete resolution of the effusion after thrombolytic therapy received less dosages of alteplase and dornase compared to those that did.
- Alteplase therapy proves a good treatment option for most cases of complex fluid collection and in those in which surgery is contraindicated or those looking to avoid surgery.
- Implementing a standard protocol of alteplase and dornase dosing combined with earlier intervention would optimize cases of complete resolution observed on imaging.

1. Walker, C., Shirk, M., Tschampel, M., & Visconti, J. (2003). Intrapleural Alteplase in a Patient with Complicated Pleural Effusion. *The Annals of Pharmacology*, 37, 376-379. doi:10.1345/aph.1C248

2. Piccolo, F., Popwicz, N., Wong, D., & Lee, Y. (2015). Intrapleural tissue plasminogen activator and deoxyribonuclease therapy for pleural infection. *Journal of Thoracic Disease*, 7(6), 999-1008. doi:10.3978/j.issn.2072-1439.2015.01.30

3. Ben-Or, S., Feins, R., Veeramachaneni, N., & Haithcock, B. (2011). Effectiveness and Risks Associated With Intrapleural Alteplase by Means of Tube Thoracostomy. *The Society of Thoracic Surgeons*, 4th ser., 860-864. doi:10.1016/j.athoracsur.2010.10.082