

# Over-the-Scope Clip Defect Closure Following Endoscopic Mucosal Resection Throughout the Gastrointestinal Tract: A Case Series

Kyle Kreitman DO

*Lehigh Valley Health Network, Kyle.Kreitman@lvhn.org*

Patrick Hickey DO

*Lehigh Valley Health Network, Patrick.Hickey@lvhn.org*

Shashin Shah MD

*Lehigh Valley Health Network, Shashin.Shah@lvhn.org*

Hiral N. Shah MD

*Lehigh Valley Health Network, hiral\_n.shah@lvhn.org*

Follow this and additional works at: <https://scholarlyworks.lvhn.org/medicine>



Part of the [Gastroenterology Commons](#)

---

## Published In/Presented At

Kreitman, K. Hickey, P. Shah, S. Shah, H. (2018, October 8). *Over-the-Scope Clip Defect Closure Following Endoscopic Mucosal Resection Throughout the Gastrointestinal Tract: A Case Series*. Poster Presented at: (ACG) American College of Gastroenterology Annual Meeting, Philadelphia, PA.

This Poster is brought to you for free and open access by LVHN Scholarly Works. It has been accepted for inclusion in LVHN Scholarly Works by an authorized administrator. For more information, please contact [LibraryServices@lvhn.org](mailto:LibraryServices@lvhn.org).

# Over-the-Scope Clip Defect Closure Following Endoscopic Mucosal Resection Throughout the Gastrointestinal Tract: A Case Series

Kyle Kreitman, DO, Patrick Hickey, DO, Shashin Shah, MD, Hiral Shah, MD  
Lehigh Valley Health Network, Allentown, Pa.

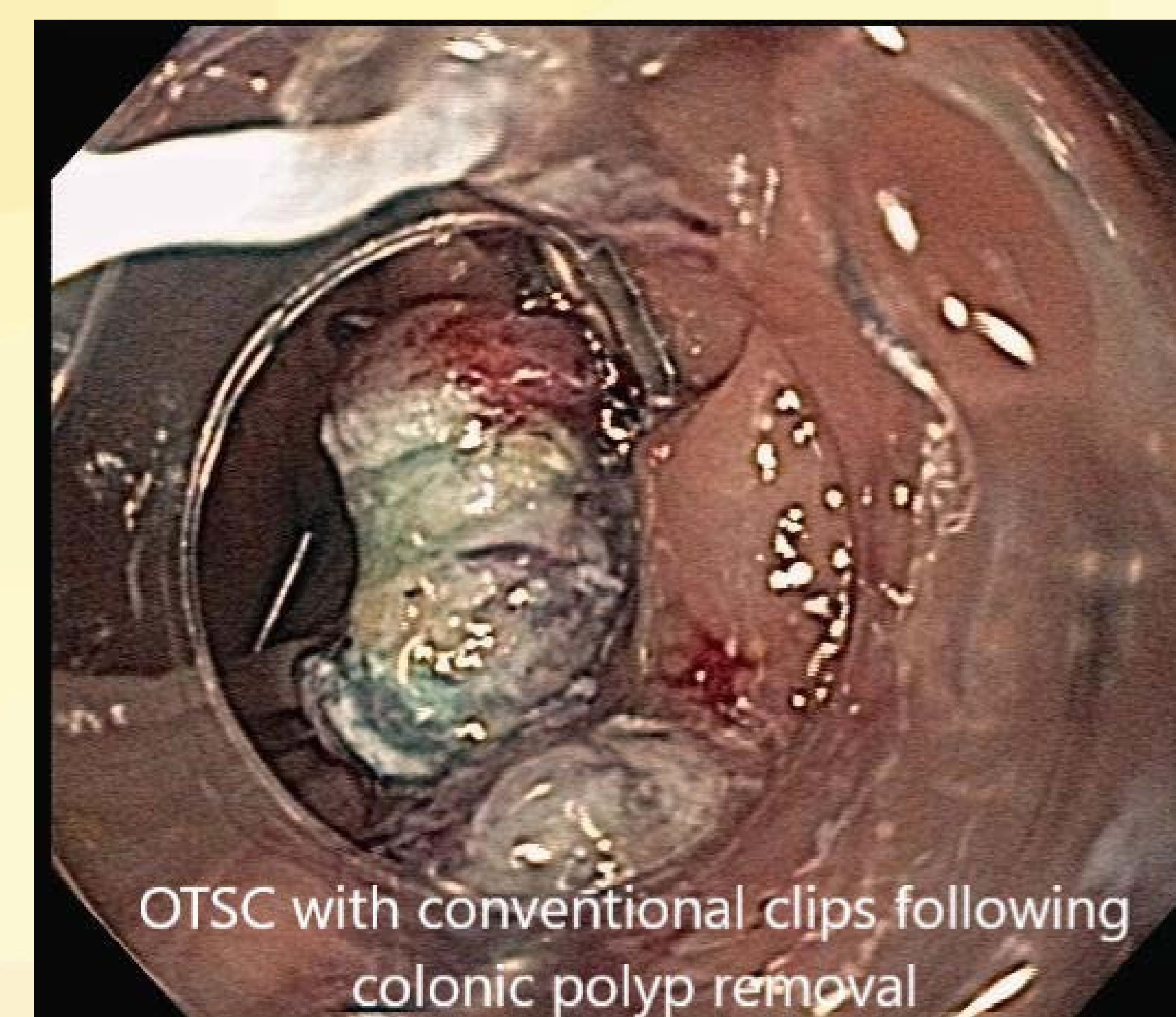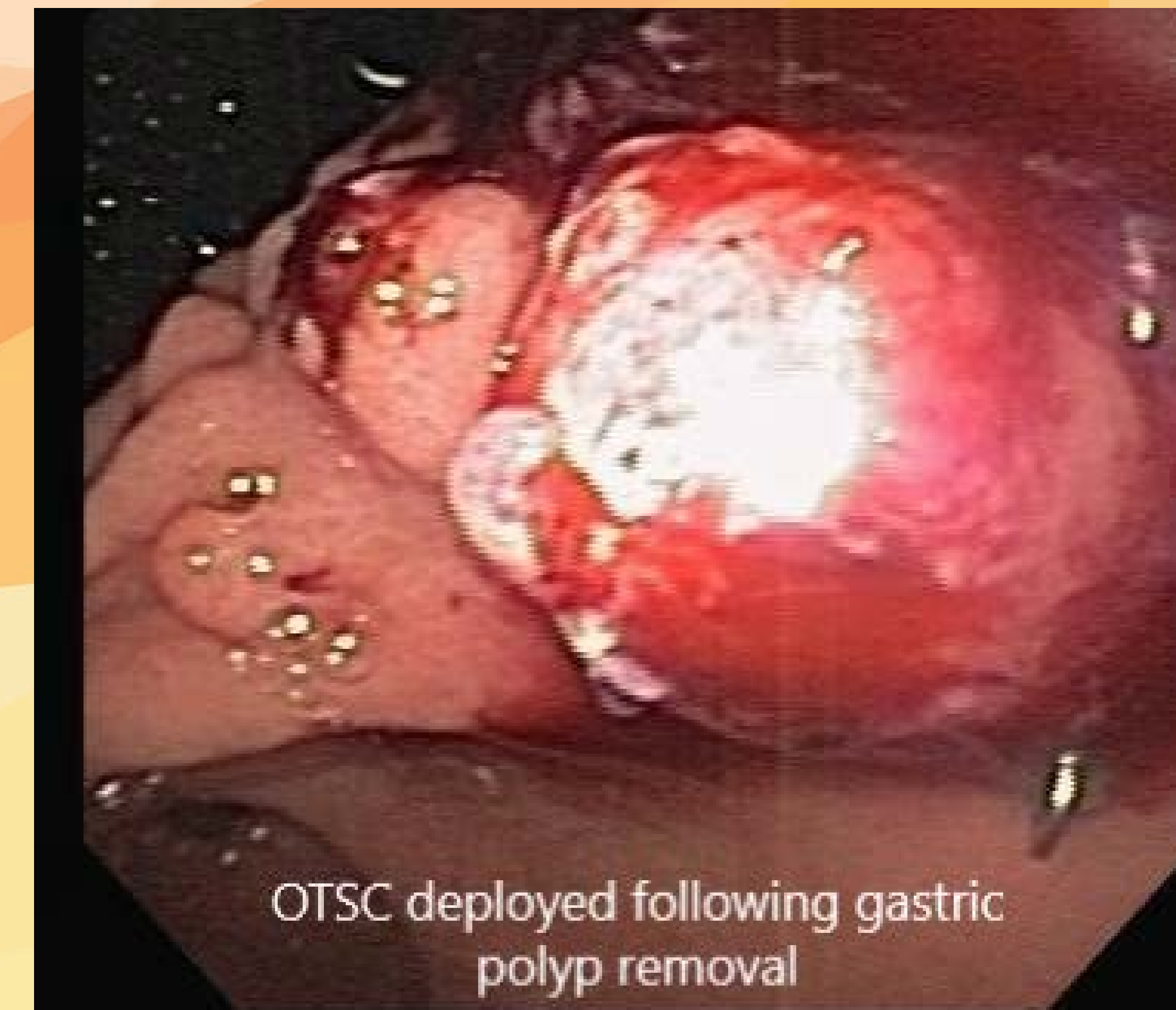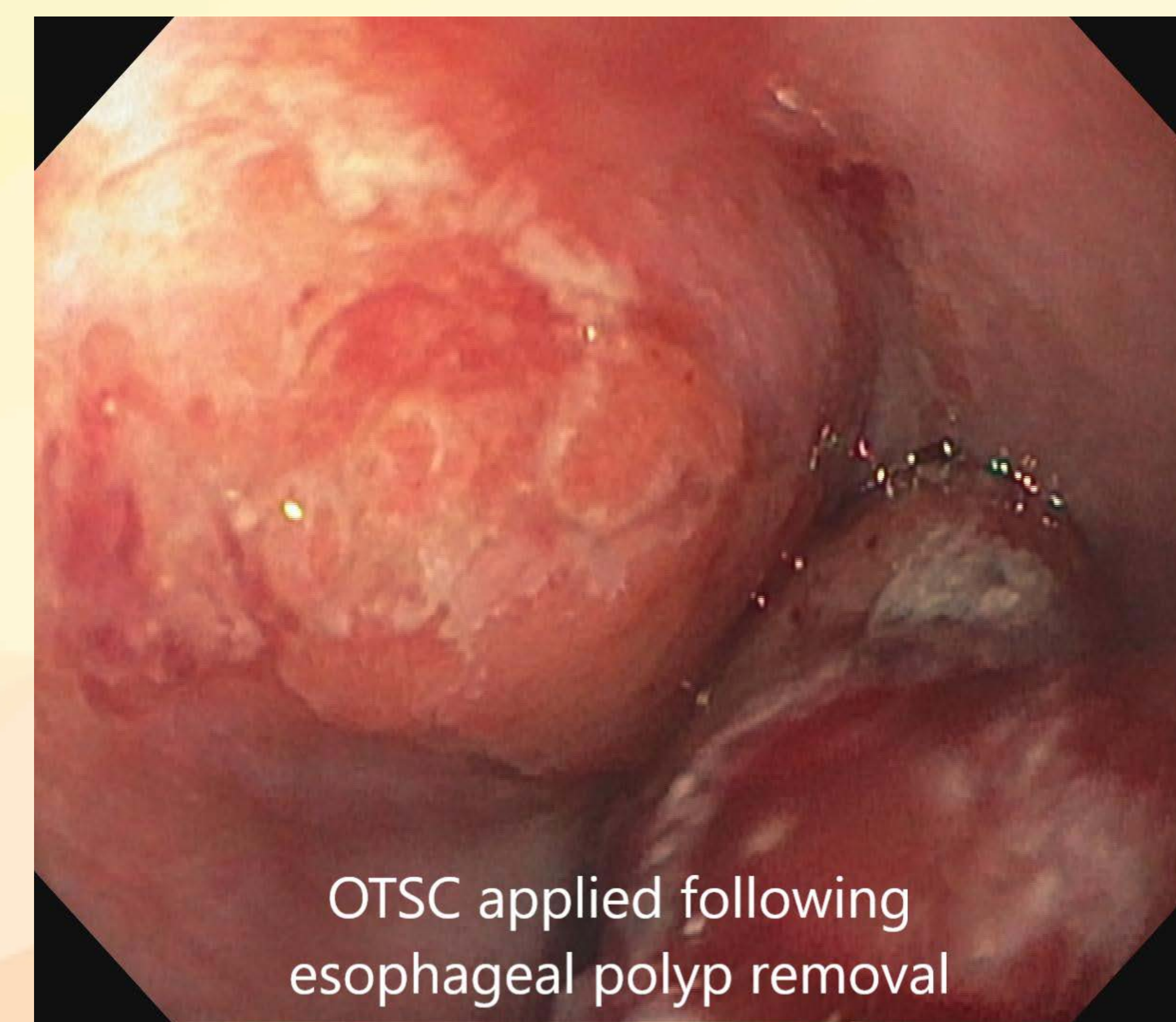
## INTRODUCTION

The **Over-the-Scope Clip (OTSC)** is an endoscopic tool which provides more strength and better tissue capture than alternative clipping methods. It is approved for use in acute gastrointestinal bleeding, full thickness wall closure, compression/approximation of tissue, and management of complications after endoscopic interventions. The purpose of this case series is to review 4 cases in which OTSC was used after endoscopic mucosal resection (EMR) of lesions in the esophagus, stomach, small bowel, and colon.

## CASE PRESENTATION

A 74-year-old female with history of benign colon polyps was referred for EGD due to ongoing anemia. This revealed a mucosal polypoid mass in the distal esophagus. An Endoloop was deployed and the polyp resected with snare cautery. There was significant bleeding after EMR and Epinephrine was injected for hemostasis. An OTSC was successfully deployed to prevent further bleeding.

A 84-year-old male with history of gastric ulcers was referred for EGD for symptomatic anemia. This revealed multiple gastric fundic gland polyps, one of which was a 2cm hemorrhagic appearing polyp along the lesser curvature (the source of their anemia). This was resected in piecemeal fashion using EMR. An OTSC was deployed at the post polypectomy site to reduce the risk of bleeding.



A 66-year-old female with history of peptic ulcer disease presented for follow-up EGD after previous biopsy of a 17mm mucosal based duodenal polyp in the 2nd portion of the duodenum (path tubular adenoma). The polyp was resected using snare cautery en-block with margins cleared. No endoscopic evidence of residual polyp was noted. An OTSC was placed to reduce post polypectomy bleeding.

A 57-year-old male presented for follow-up EMR of a 15 mm flat (Paris type 2a/2c) polyp in the ascending colon. A stiff snare was used for successful EMR. Exact approximation was difficult due to the angulation of the resection thus not allowing standard endoclip deployment. An OTSC device loaded on the colonoscope was used to close the defect.

## DISCUSSION

All four patients tolerated their procedure well and with no complications.

This series describes the safe and effective use of OTSC for managing hemostasis. None of the patients had post procedure bleeding. The final case demonstrated that OTSC allows for primary closure following EMR in difficult angulations. The success in this series shows the promising utility of OTSC and an adjunct to conventional methods for hemostasis and closure.