

Duodenal Varices: A Rare Cause of Gastrointestinal Bleeding.

Anam Malik MD

Lehigh Valley Health Network, Anam.Malik@lvhn.org

Abdul Aleem MD

Lehigh Valley Health Network, fnu_abdul.aleem@lvhn.org

Eric Nellis MD

Lehigh Valley Health Network, eric.nellis@lvhn.org

Hiral N. Shah MD

Lehigh Valley Health Network, hiral_n.shah@lvhn.org

Follow this and additional works at: <https://scholarlyworks.lvhn.org/medicine>



Part of the [Gastroenterology Commons](#), [Internal Medicine Commons](#), and the [Medical Sciences Commons](#)

Published In/Presented At

Malik, A. Aleem, A. Nellis, E. Shah, H. (2017, October 14-16). *Duodenal Varices: A Rare Cause of Gastrointestinal Bleeding*. Poster Presented at: World Congress of Gastroenterology at ACG2017 meeting. Orlando, Florida.

This Poster is brought to you for free and open access by LVHN Scholarly Works. It has been accepted for inclusion in LVHN Scholarly Works by an authorized administrator. For more information, please contact LibraryServices@lvhn.org.

Duodenal Varices: A Rare Cause of Gastrointestinal Bleeding

Anam Malik MD¹, Abdul Aleem MD¹, Eric Nellis MD² and Hiral N Shah MD²

¹Department of Internal Medicine, ²Department of Gastroenterology, Lehigh Valley Health Network, Allentown, Pennsylvania

INTRODUCTION

- Portal hypertension is a manifestation of chronic liver diseases with cirrhosis being the most common etiological factor.
- Portal hypertension causes increased pressure in the portal vein resulting in development of ascites, encephalopathy, thrombocytopenia and varices usually across the esophagus and stomach.
- Duodenal varices are a relatively rare complication of portal hypertension accounting for 0.4% of all cases.
- Approximately 25% of patients with duodenal varices also have associated esophageal varices
- Duodenal varices usually occur in the duodenal bulb and the second portion of the duodenum.
- The prognosis in patients with duodenal varices is very poor with a mortality rate of 40% owing to the high vascularity of the duodenum which can cause profuse bleeding.

CASE PRESENTATION

- A 60 year-old female with known diagnosis of alcoholic cirrhosis was admitted with complaints of intermittent hematochezia and melena of three days duration.
- Physical exam was suggestive of a significantly distended abdomen with tenderness in all four abdominal quadrants.
- Initial laboratory values noted a hemoglobin (Hb) of 7 g/dl and she received one unit of packed red blood cells (pRBCs).
- Computed Tomography (CT) Abdomen showed cirrhosis with numerous prominent gastroesophageal varices, a large degree of ascites, and mild mural thickening involving the majority of the small bowel.
- Esophagogastroduodenoscopy (EGD) showed duodenal varices in the second portion of the duodenum with stigmata (cherry red spots), grade 2 distal esophageal varices without stigmata both of which were treated with band ligation.
- Post EGD, patient's Hb remained stable at 8.6g/dl with subsequent resolution of her hematochezia and melena.
- Patient is closely being followed up as an outpatient with serial Hb monitoring and surveillance endoscopy.

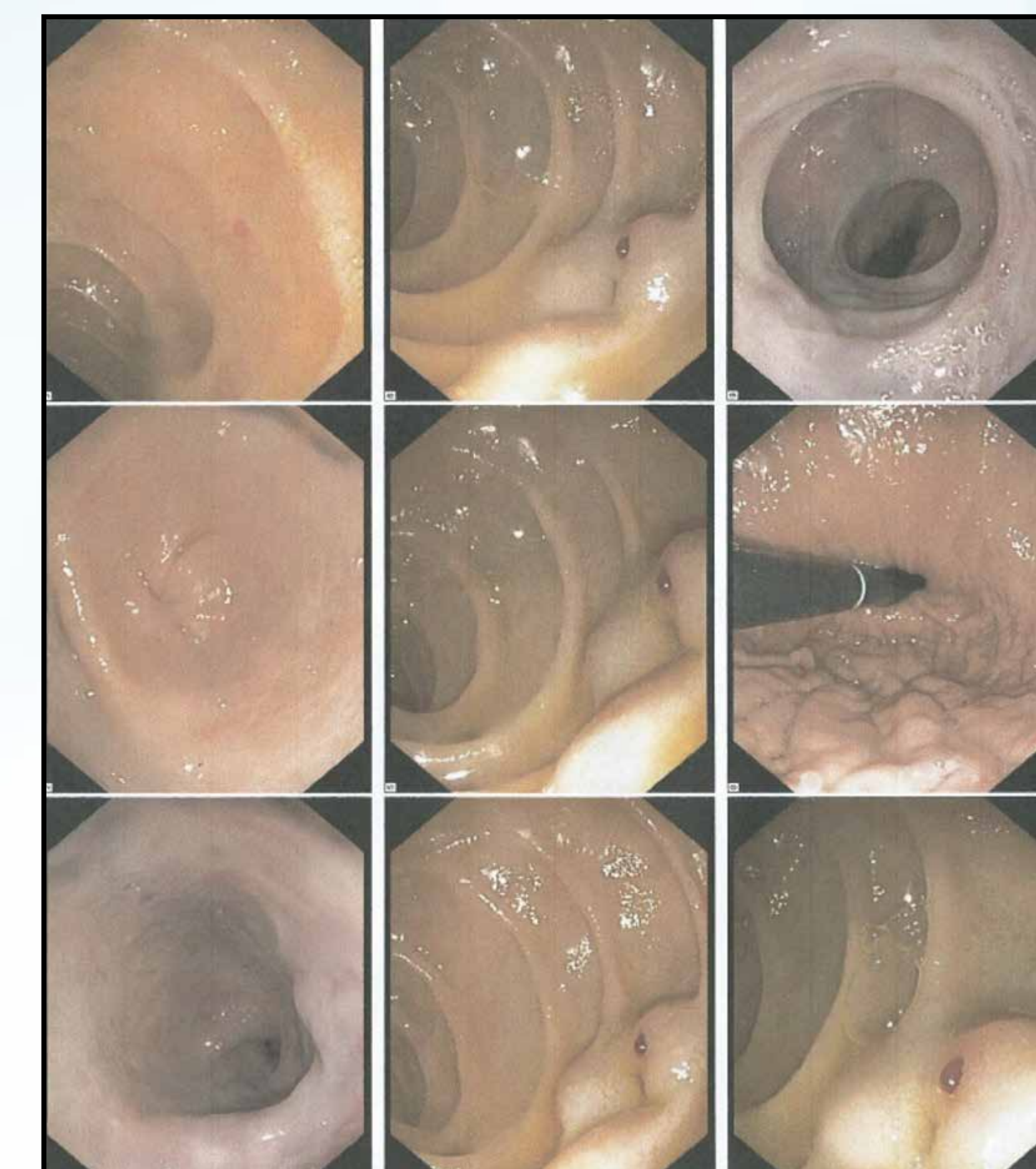


Figure 1: TEXT

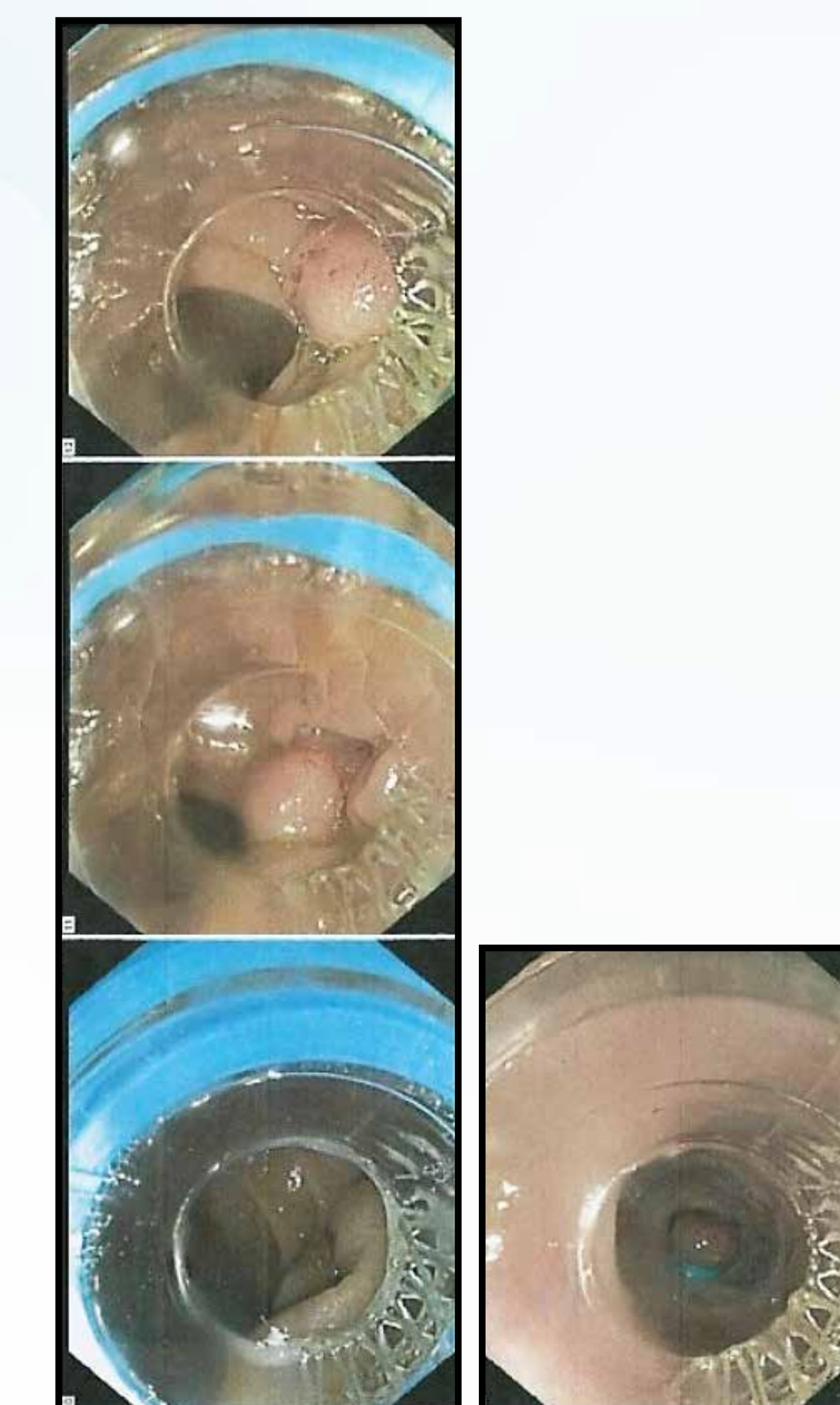


Figure 2: TEXT

DISCUSSION

- The optimal management of duodenal varices remains unclear owing to the rare occurrence of this complication.
- Endoscopic intervention with band ligation is considered to be the first line therapy for duodenal varices.
- Current literature review have also supported the use of secondary interventional procedures like transjugular intrahepatic portosystemic shunting (TIPS), balloon occluded retrograde transvenous obliteration band ligation(B-RTO), sclerosant injection therapy and liquid adhesive techniques.
- Surgical procedures such as duodenectomy and gastro-duodenectomy are indicated if the aforementioned minimally invasive treatments have failed or were ineffective.
- Our case illustrates the importance of close monitoring of this rare condition considering that there have been no clinical trials to compare the efficacy of one treatment modality over the other.

References:

1. Naseemuddin M, Shoreibah M, Underwood E, Peter S. An Uncommon and Challenging Case of Duodenal Variceal Bleeding. *ACG Case Rep J.* 2016;3(4):e138.
2. Nabeel M. A, Ziv J. H. Diagnosis and management of ectopic varices. *Gastrointestinal Intervention*, Volume 1, Issue 1, Pages 3-10.
3. Okoli A, Raymond P, Ammannagari N, Merrell N. Isolated duodenal varices as the initial presentation of hepatocellular carcinoma. *BMJ Case Rep.* 2013;2013.

© 2017 Lehigh Valley Health Network

610-402-CARE LVHN.org