

The Non-Healing Ileocecal Ulcer.

Kyle Kreitman DO

Lehigh Valley Health Network, Kyle.Kreitman@lvhn.org

Patrick Hickey DO

Lehigh Valley Health Network, Patrick.Hickey@lvhn.org

Paola Blanco MD

Lehigh Valley Health Network, Paola_G.Blanco@lvhn.org

Hiral N. Shah MD

Lehigh Valley Health Network, hiral_n.shah@lvhn.org

Follow this and additional works at: <https://scholarlyworks.lvhn.org/medicine>



Part of the [Gastroenterology Commons](#), and the [Internal Medicine Commons](#)

Published In/Presented At

Kreitman, K. Hickey, P. Blanco, P. Shah, H. (2018, May). *The Non-Healing Ileocecal Ulcer*. Poster Presented at: POMA Clinical Assembly, King of Prussia, PA.

This Poster is brought to you for free and open access by LVHN Scholarly Works. It has been accepted for inclusion in LVHN Scholarly Works by an authorized administrator. For more information, please contact LibraryServices@lvhn.org.

The Non-Healing Ileocecal Ulcer

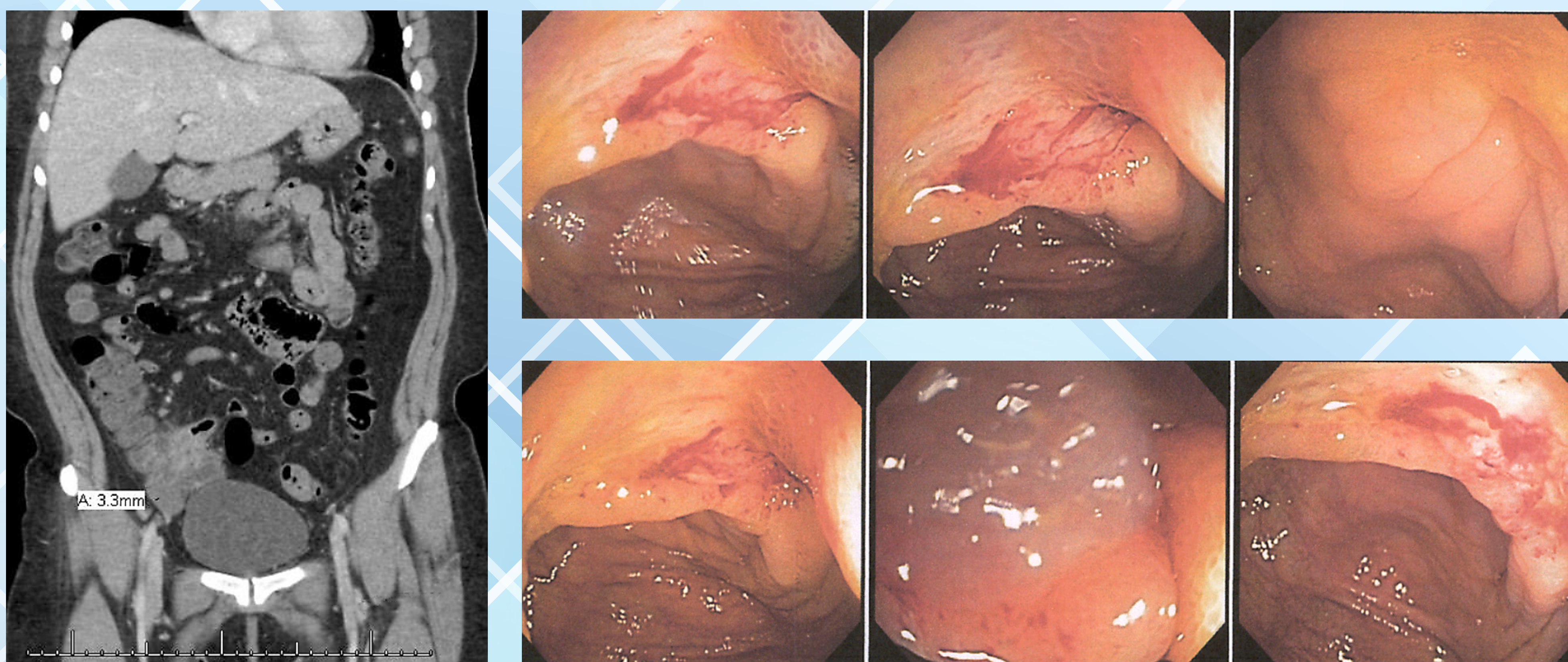
K. Kreitman, DO*, P. Hickey DO*, P. Blanco, MD**, H Shah, MD**

*Department of Medicine, Lehigh Valley Health Network, Allentown, Pa.

**Eastern Pennsylvania Gastroenterology and Liver Specialist, Allentown, Pa.

INTRODUCTION

Behcet's disease is a rare vasculitic disorder characterized by recurrent oral aphthous ulcers, genital ulcers, and uveitis. Terminal ileocecal involvement is seen in less than 50% of patients with symptoms including abdominal pain, diarrhea, and bleeding. Due to its infrequency, GI involvement can make it difficult to differentiate it from IBD, in particular Crohn's.



Ileocecal valve thickening noted on initial CT scan.

Colonoscopy reveals solitary ileocecal ulcer (20 mm with no active bleeding)

METHODS

A female with a history of Behcet's presented with complaints of sharp episodic RLQ pain, abdominal distention and diarrhea. She was prescribed mycophenolic acid for episodic presence of oral and vaginal ulcers due to her Behcet's. All diagnostic testing was normal.

A year later, she presented again with severe RLQ pain. A CT showed appendicular and ileocecal valve wall thickening suspicious for acute appendicitis. Due to the location, an EGD/colonoscopy was performed to rule out IBD, and results were normal. She was told to continue acid suppression medication and an appendectomy was performed.

RESULTS

Throughout the year, her abdominal pain persisted and repeat CTs and colonoscopies showed cecum wall thickening and persistent ulceration. Biopsies were negative for IBD and showed focal inflammation. Given her lack of response to immunosuppression, local resection for definitive therapy is planned.

CONCLUSION

Despite the rarity of intestinal involvement in Behcet's, it should be considered in the differential of abdominal pain. Distinguishing IBD, particularly Crohn's, from Behcet's is made difficult by similarities in symptoms and clinical findings. In patients with Behcet's and complaints of abdominal pain, intestinal involvement should be suspected to avoid unneeded diagnostic testing and treatments.

REFERENCES

¹ Cheon, J.H., and W.H. Kim. "An Update on the Diagnosis, Treatment, and Prognosis of Intestinal Behçet's Disease." *Current Opinion in Rheumatology*. U.S. National Library of Medicine, Jan. 2015. Web. 18 Apr. 2017.

² "Clinical Manifestations and Diagnosis of Behçet's Syndrome." *Clinical Manifestations and Diagnosis of Behçet's Syndrome*. N.p., n.d. Web. 18 Apr. 2017.

³ Jung, Yoon Suk, Jae Hee Cheon, Soo Jung Park, Sung Pil Hong, Tae Il Kim, and Won Ho Kim. "Clinical Course of Intestinal Behçet's Disease During the First Five Years." *SpringerLink*. Springer US, 17 Aug. 2012. Web. 18 Apr. 2017.

⁴ Skef, Wasseem, Matthew J. Hamilton, and Thurayya Arayssi. "Gastrointestinal Behçet's Disease: A Review." *World Journal of Gastroenterology : WJG*. Baishideng Publishing Group Inc, 07 Apr. 2015. Web. 18 Apr. 2017.