

Lehigh Valley Health Network LVHN Scholarly Works

Department of Medicine

Central Hypoventilation: A Rare Complication of Wallenberg Syndrome

Keithan Sivakumar MD, MBA

Lehigh Valley Health Network, Keithan.Sivakumar@lvhn.org

Manveer Garcha

Lehigh Valley Health Network, Manveer.Garcha@lvhn.org

Dev Mehta

Lehigh Valley Health Network, Dev.Mehta@lvhn.org

Megan Leary MD

Lehigh Valley Health Network, Megan_C.Leary@lvhn.org

Hussam A. Yacoub MD

Lehigh Valley Health Network, hussam_a.yacoub@lvhn.org

Follow this and additional works at: <https://scholarlyworks.lvhn.org/medicine>

 Part of the [Neurology Commons](#)

Published In/Presented At

Sivakumar, K. Garcha, M. Mehta, D. Leary, M. Yacoub, H. A. (2018). Central Hypoventilation: A Rare Complication of Wallenberg Syndrome. *Case Reports in Neurological Medicine*.

This Article is brought to you for free and open access by LVHN Scholarly Works. It has been accepted for inclusion in LVHN Scholarly Works by an authorized administrator. For more information, please contact LibraryServices@lvhn.org.

Case Report

Central Hypoventilation: A Rare Complication of Wallenberg Syndrome

Keithan Sivakumar,¹ Manveer Garcha,¹ Dev Mehta,¹
Megan C. Leary,^{1,2} and Hussam A. Yacoub ^{1,2}

¹Lehigh Valley Physician Group-Neurology, Lehigh Valley Health Network, Allentown, PA, USA

²Morsani College of Medicine, University of South Florida, Tampa, FL, USA

Correspondence should be addressed to Hussam A. Yacoub; hyacoub123@yahoo.com

Received 15 December 2017; Accepted 19 February 2018; Published 21 March 2018

Academic Editor: Peter Berlit

Copyright © 2018 Keithan Sivakumar et al. This is an open access article distributed under the Creative Commons Attribution License, which permits unrestricted use, distribution, and reproduction in any medium, provided the original work is properly cited.

Central alveolar hypoventilation disorders denote conditions resulting from underlying neurologic disorders affecting the sensors, the central controller, or the integration of those signals leading to insufficient ventilation and reduction in partial pressures of oxygen. We report a patient who presented with a left lateral medullary ischemic stroke after aneurysm repair who subsequently developed a rare complication of CAH. Increased awareness of this condition's clinical manifestations is crucial to make an accurate diagnosis and understand its complications and prognosis.

1. Introduction

Central alveolar hypoventilation (CAH) disorders arise from improper signal integration of the central respiratory drive center in the lower brainstem, which can be due to congenital or acquired neurologic dysfunction. These disorders can lead to hypercarbia, hypoxia, and insufficient ventilation. The disorder typically presents in sleep alone but in severe cases can present during sleep and arousal states.

Acquired central hypoventilation typically occurs due to traumatic, ischemic, or inflammatory injuries to the brainstem. The term “Ondine’s curse” was first used by Severinhaus and Mitchell [1] to describe patients who were able to breathe voluntarily after undergoing bilateral spinothalamic tract cordotomies but subsequently became apneic during sleep. This loss of reflex breathing was determined to be due to poor ventilatory responsiveness to inhaled carbon dioxide. Unilateral lesions rarely cause hypoventilation.

Brainstem infarctions and ischemia can lead to CAH [2–4]. Central hypoventilation and apnea can occur secondary to watershed infarcts in the fetal and neonatal tegmentum [4]. Brainstem tumors including gliomas and acoustic neuromas can lead to central hypoventilation [5, 6]. Brainstem

tumors in children often manifest with sleepiness due to compression [7], which can improve with resection of the tumor [5]. Paraneoplastic and viral encephalitis as well as bulbar polio can result in central hypoventilation. Ventilatory management is typically supportive and outcome is variable and unpredictable [8–11].

2. Case Presentation

A 62-year-old woman with no significant medical history experienced an acute onset of vertigo after abruptly turning her head to the left. The symptoms resolved within 24 hours. Computed tomography (CT) of the head and CT angiography of the head and neck revealed an unruptured 11.7-millimeter wide-necked left posterior inferior cerebellar artery (PICA) aneurysm that was subsequently confirmed with conventional cerebral angiography. She was taken to the operating room where she subsequently had the aneurysm clipped. Intraoperatively, the patient developed profound bleeding due to loss of local hemostasis. As a result, the patient had an episode of pulseless electrical activity, followed by resuscitation and consequent sacrifice of the left vertebral artery.

Postoperatively, the patient remained intubated due to several episodes of prolonged apnea mainly during sleep, having often to be “reminded” to breathe. Initial physical examination was significant for left eye ptosis and meiosis, subtle right gaze preference, and left-sided weakness and ataxia. Noncontrast magnetic resonance imaging of the brain demonstrated increased T1 signal in the left inferior cerebellum and medulla in the PICA vascular distribution. It was noted that, during sleep when on the same ventilator settings as those during wakefulness, the patient became acidotic and was retaining carbon dioxide (CO₂), with a partial pressure of CO₂ (PaCO₂) of 76 millimeters of mercury, while breathing only at the set rate and not initiating her own breaths. During wakefulness, the patient was able to maintain ventilation, evident by normal PaCO₂. Over the course of stay in the intensive care unit, the patient was maintained on different modes of assisted ventilators and eventually continuous positive airway pressure. Consequently, the apneic episodes progressively became shorter until the patient recovered spontaneously before discharge to an acute rehabilitation facility.

3. Discussion

CAH syndrome, also known as “Ondine’s curse,” is an exceedingly uncommon disorder categorized by failure of respiratory mechanisms while asleep [8]. Patients with this condition have no difficulties during wakefulness but have persistent apnea during sleep [9, 10].

Congenital CAH is very common in the neonatal period and has been reported in preterm infants. Neonatal CAH occurs in infants who suffer birth asphyxia or metabolic insults. The pathogenesis of CAH in the neonatal period is thought to be related to delayed synaptogenesis associated with genetic diseases or certain cerebral malformations [12]. Many have discussed certain congenital malformations or chromosomopathies involved in the congenital form of CAH, including a PHOX2B mutation first documented in 2009 by Lee et al. [13] or abnormal development of the neural crest as a result of the RET-GDNF signaling pathway [8, 14].

There are numerous etiologies of this pathological conundrum which include infectious, malignant, upper cervical cord injury, various degenerative diseases, demyelinating diseases, mitochondrial disease, and ischemia [15–18]. Furthermore, brainstem involvement in ischemic infarctions and dysregulation of the autonomic control of breathing have been infrequently described [18, 19]. Synaptic failure in the nucleus solitarius indeed can occur with metabolic or hypoxic/ischemic insults, followed by recovery of those neurons that were rendered nonfunctional for a transitory period without neuronal loss.

Among the various aberrant ventilatory patterns, CAH is the pattern that allows for the most accurate localization of the lesion, typically in the lower brainstem involving the lateral medulla. This lesion can cause selective interruption of the anterolateral medullocervical pathway, a descendent pathway normally responsible for autonomic breathing control [4].

In the case presented above, the patient had a lesion in the left lateral medulla, which produced many of the classic symptoms of Wallenberg syndrome: ipsilateral arm and leg ataxia, Horner’s syndrome, facial weakness, and contralateral arm and leg sensory disturbance. The presumed central hypoventilation was related to compression and swelling of the medulla, affecting both the ventral and dorsal respiratory groups of the autonomic breathing center.

Laboratory criteria for the diagnosis of CAH are not well established [8–10, 20]. Some authors propose that prolonged and persistent periods of apnea associated with desaturation and hypercapnia during nonrapid eye movement sleep should be demonstrated for diagnosis. Other diagnostic criteria include (a) normal pulmonary and mediastinal anatomy, (b) normalization of partial pressure of oxygen through voluntary breathing when awake, and (c) precipitation of alveolar hypoventilation with diminished voluntary control (i.e., sleep). The clinical picture and location of the ischemic lesion in the case presented here support the diagnosis of CAH [21].

Both pharmacological and supportive treatments have been proposed for CAH. The goal is to activate the remaining respiratory nuclei through induction of metabolic acidosis. Pharmacological agents such as trazodone, acetazolamide, medroxyprogesterone, protriptyline, clomipramine, and caffeine have been used [22, 23]. Supportive measures include the use of a diaphragmatic pacemaker, with a reported success rate of 50–70% in some series [9].

In patients with acquired CAH, spontaneous recovery without the need of a pacemaker, as was the case in our patient, is frequent. These patients usually respond well to tracheostomy and nocturnal-assisted ventilation leading to spontaneous recovery [24]. Death related to CAH usually occurs during sleep, presumably due to complete apnea, which can be alleviated if adequately ventilated [24]. Prognosis is variable and depends on the specific location of the lesion, and recovery is usually unpredictable.

The term Ondine’s curse is more commonly used to describe cases of congenital CAH but can be applied to acquired cases due to trauma, ischemia, or inflammation [18]. The patient in the case discussed here developed CAH secondary to bleeding complications during aneurysm repair. Unlike other reported cases, CAH in our patient was related to compression and swelling of the medulla, subsequently affecting both the ventral (pre-Bötzinger nucleus and vagus nucleus ambiguus) and dorsal (nucleus tractus solitarius) respiratory groups of the autonomic breathing center [1].

This case extends our knowledge of CAH and increases awareness of its etiologies, diagnosis, and complications.

Conflicts of Interest


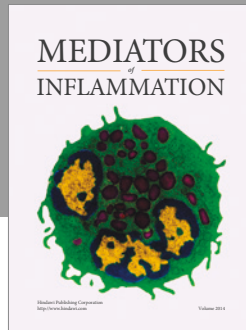
The authors declare that they have no conflicts of interest.

Acknowledgments

The authors are grateful to Jacqueline Grove for contributions to editing and manuscript preparation.

References

- [1] S. Zaidi, J. Gandhi, N. L. Smith, and S. A. Khan, "Congenital central hypoventilation syndrome: An overview of etiopathogenesis, associated pathologies, clinical presentation, and management," *Autonomic Neuroscience*, 2017.
- [2] J. G. Heckmann and S. Ernst, "Central alveolar hypoventilation (ondine's curse) caused by megadolichobasilar artery," *Journal of Stroke and Cerebrovascular Diseases*, vol. 23, no. 2, pp. 390–392, 2014.
- [3] A. Smyth and M. Riley, "Chronic respiratory failure: An unusual cause and treatment," *Thorax*, vol. 57, no. 9, pp. 835–836, 2002.
- [4] H. B. Sarnat, "Watershed infarcts in the fetal and neonatal brainstem. An aetiology of central hypoventilation, dysphagia, Möbius syndrome and micrognathia," *European Journal of Paediatric Neurology*, vol. 8, no. 2, pp. 71–87, 2004.
- [5] D. K. P. Lee, G. W. Wahl, A. J. Swinburne, and A. J. Fedullo, "Recurrent acoustic neuroma presenting as central alveolar hypoventilation," *CHEST*, vol. 105, no. 3, pp. 949–950, 1994.
- [6] S. H. L. Hui, Y. K. Wing, W. Poon, Y. L. Chan, and T. A. Buckley, "Alveolar hypoventilation syndrome in brainstem glioma with improvement after surgical resection," *CHEST*, vol. 118, no. 1, Article ID 39038, pp. 266–268, 2000.
- [7] G. M. Rosen, A. E. Bendel, J. P. Neglia, C. L. Moertel, and M. Mahowald, "Sleep in children with neoplasms of the central nervous system: case review of 14 children," *Pediatrics*, vol. 112, no. 1, pp. e46–54, 2003.
- [8] V. Attali, C. Straus, M. Pottier et al., "Normal sleep on mechanical ventilation in adult patients with congenital central alveolar hypoventilation (Ondine's curse syndrome)," *Orphanet Journal of Rare Diseases*, vol. 12, no. 1, pp. 1–5, 2017.
- [9] T. S. Olson, G. E. Woodson, and G. P. Heldt, "Upper Airway Function in Ondine's Curse," *Archives of Otolaryngology–Head and Neck Surgery*, vol. 118, no. 3, pp. 310–312, 1992.
- [10] D. Gozal, "Congenital central hypoventilation syndrome: An update," *Pediatric Pulmonology*, vol. 26, no. 4, pp. 273–282, 1998.
- [11] M. Nakajima, K. Katsura, Y. Hashimoto, T. Terasaki, and M. Uchino, "A case of Ondine's curse associated with a medullary tumor [in Japanese]," *Rinsho Shinkeigaku*, vol. 40, pp. 811–815, 2000.
- [12] H. B. Sarnat and L. Flores-Sarnat, "Synaptogenesis and myelination in the nucleus/tractus solitarius: Potential role in apnea of prematurity, congenital central hypoventilation, and sudden infant death syndrome," *Journal of Child Neurology*, vol. 31, no. 6, pp. 722–732, 2015.
- [13] P. Lee, Y.-N. Su, C.-J. Yu, P.-C. Yang, and H.-D. Wu, "PHOX2B mutation-confirmed congenital central hypoventilation syndrome in a chinese family," *CHEST*, vol. 135, no. 2, pp. 537–544, 2009.
- [14] J. L. Pedroso, R. F. Baiense, A. P. Scalzaretto, P. B. Neto, A. F. T. Teixeira De Gois, and M. E. Ferraz, "Ondine's curse after brainstem infarction," *Neurology India*, vol. 57, no. 2, pp. 206–207, 2009.
- [15] M. F. Beal, E. P. Richardson, R. Brandstetter, E. T. Hedley-Whyte, and F. H. Hochberg, "Localized brainstem ischemic damage and ondine's curse after near-drowning," *Neurology*, vol. 33, no. 6, pp. 717–721, 1983.
- [16] M. Sadler, C. M. Wiles, N. Stoodley, S. J. Linnane, and A. P. Smith, "Ondine's curse in a woman with Leber's hereditary optic neuropathy," *Journal of Neurology, Neurosurgery & Psychiatry*, vol. 73, no. 3, pp. 347–348, 2002.
- [17] J. Kraus, J. Heckmann, A. Druschky, F. Erbguth, and B. Neundörfer, "Ondine's curse in association with diabetes insipidus following transient vertebrobasilar ischemia," *Clinical Neurology and Neurosurgery*, vol. 101, no. 3, pp. 196–198, 1999.
- [18] G. Juan, M. Ramón, M. A. Ciscar et al., "Acute respiratory insufficiency as initial manifestation of brainstem lesion [in Spanish]," *Archivos de Bronconeumología*, vol. 35, pp. 560–563, 1999.
- [19] M. Victor and A. H. Ropper, *Adams and Victor's Principles of Neurology*, McGraw-Hill, New York, NY, USA, 7th edition, 2001.
- [20] J. Bogousslavsky, R. Khurana, J. P. Deruaz et al., "Respiratory failure and unilateral caudal brainstem infarction," *Annals of Neurology*, vol. 28, no. 5, pp. 668–673, 1990.
- [21] A. F. Haerer, *DeJong's the Neurologic Examination*, Lippincott Williams & Wilkins, Philadelphia, PA, USA, 5th edition, 1992.
- [22] J. A. Stankiewicz and J. Pazevic, "Acquired Ondine's Curse," *Otolaryngology—Head and Neck Surgery*, vol. 101, no. 5, pp. 611–613, 2016.
- [23] F. Bullemer, S. Heindl, and O. Karg, "Ondine's curse in adults," *Pneumologie*, vol. 53, no. 2, pp. S91–S92, 1999.
- [24] L. Tremoureux, M. Raux, A. L. Hudson, A. Ranohavimparany, C. Straus, and T. Similowski, "Does the supplementary motor area keep patients with Ondine's curse syndrome breathing while awake?" *PLoS ONE*, vol. 9, no. 1, Article ID e84534, 2014.



Hindawi
Submit your manuscripts at
<https://www.hindawi.com>

