

Cannabis-Induced Hypersensitivity Pneumonitis: A Case Report

Matthew J. Miles DO

Lehigh Valley Health Network, Matthew.Miles@lvhn.org

Andres Zirlinger MD

Lehigh Valley Health Network, Andres.Zirlinger@lvhn.org

Follow this and additional works at: <http://scholarlyworks.lvhn.org/medicine>



Part of the [Medical Sciences Commons](#)

Published In/Presented At

Miles, M., Zirlinger, A. (2015, May 20). *Cannabis-Induced Hypersensitivity Pneumonitis: A Case Report*. Poster presented at: American Thoracic Society International Conference, Denver, CO.

This Poster is brought to you for free and open access by LVHN Scholarly Works. It has been accepted for inclusion in LVHN Scholarly Works by an authorized administrator. For more information, please contact LibraryServices@lvhn.org.

Cannabis-Induced Hypersensitivity Pneumonitis: A Case Report

Matthew J. Miles, DO and Andres Zirlinger, MD

Lehigh Valley Health Network, Allentown, Pennsylvania

Introduction

Hypersensitivity pneumonitis is a complex syndrome caused by an inflammatory mediated reaction in the lungs due to an external antigen.^{1,2} The more common antigens include molds, fungal spores, bacteria and yeasts.³ There have been few publications recommending diagnostic criteria, however, they have not been validated.² Diagnosing hypersensitivity pneumonitis relies on several clinic features including: patient's history (cough, wheezing, weight loss, smoking history), physical exam (fever, crackles on pulmonary exam and digital clubbing) identifying microbiologic and environment exposures, bronchoalveolar lavage (BAL) (lymphocytosis), computerized tomography (CT) scan (ground-glass opacifications), histopathology (non-caseating granulomas).³

Hypersensitivity pneumonitis can be treated with systemic corticosteroids and removal of the offending antigen.¹⁻³ However, even with treatment, patients with hypersensitivity pneumonitis can develop chronic lung conditions such as pulmonary fibrosis and emphysema.²

Case Report

A 64 year old male presented with worsening dyspnea, five pound weight loss, night sweats and dry cough for two weeks. He denied chest pain, fever or sick contacts. The patient was a former tobacco smoker, quitting 50 years prior to admission. He had a history of asthma with a recent admission for presumed asthma exacerbation which responded well to a short course of oral steroids. On admission his oxygen saturation was 92% while breathing room air; physical exam was essentially normal except for bibasilar crackles. White cell count, liver and kidney function were normal. The initial chest X-ray showed bibasilar interstitial infiltrates (Figure 1) so he was started on antibiotics for presumed hospital acquired pneumonia. One day after admission he developed hypoxic respiratory failure secondary to acute respiratory distress syndrome (ARDS) which required invasive mechanical ventilation. A CT scan of the chest revealed bilateral ground-glass opacities (Figure 2). A bronchoscopy did not reveal any abnormalities of the airways. Thus, he underwent a video-assisted thoracoscopic biopsy of the lung. The cultures and stains from the biopsy were negative for organisms; pathology revealed patchy areas of consolidation presented by a pattern of organizing pneumonia mixed with multiple, poorly formed non-caseating granulomas consistent with hypersensitivity pneumonitis.

The patient was started on corticosteroids daily and was extubated two days after treatment. After extubation, the patient's daughter mentioned that the patient had been regularly smoking a significant amount of cannabis, but did not want anyone to find out.

The patient's symptoms completely resolved after 8 weeks of corticosteroid therapy and cannabis cessation. A confirmation CT scan showed resolution of bilateral ground-glass opacities after 10 weeks of medical therapy (Figure 3). The patient continued to be asymptomatic 22 weeks after cessation of steroids and cannabis use.

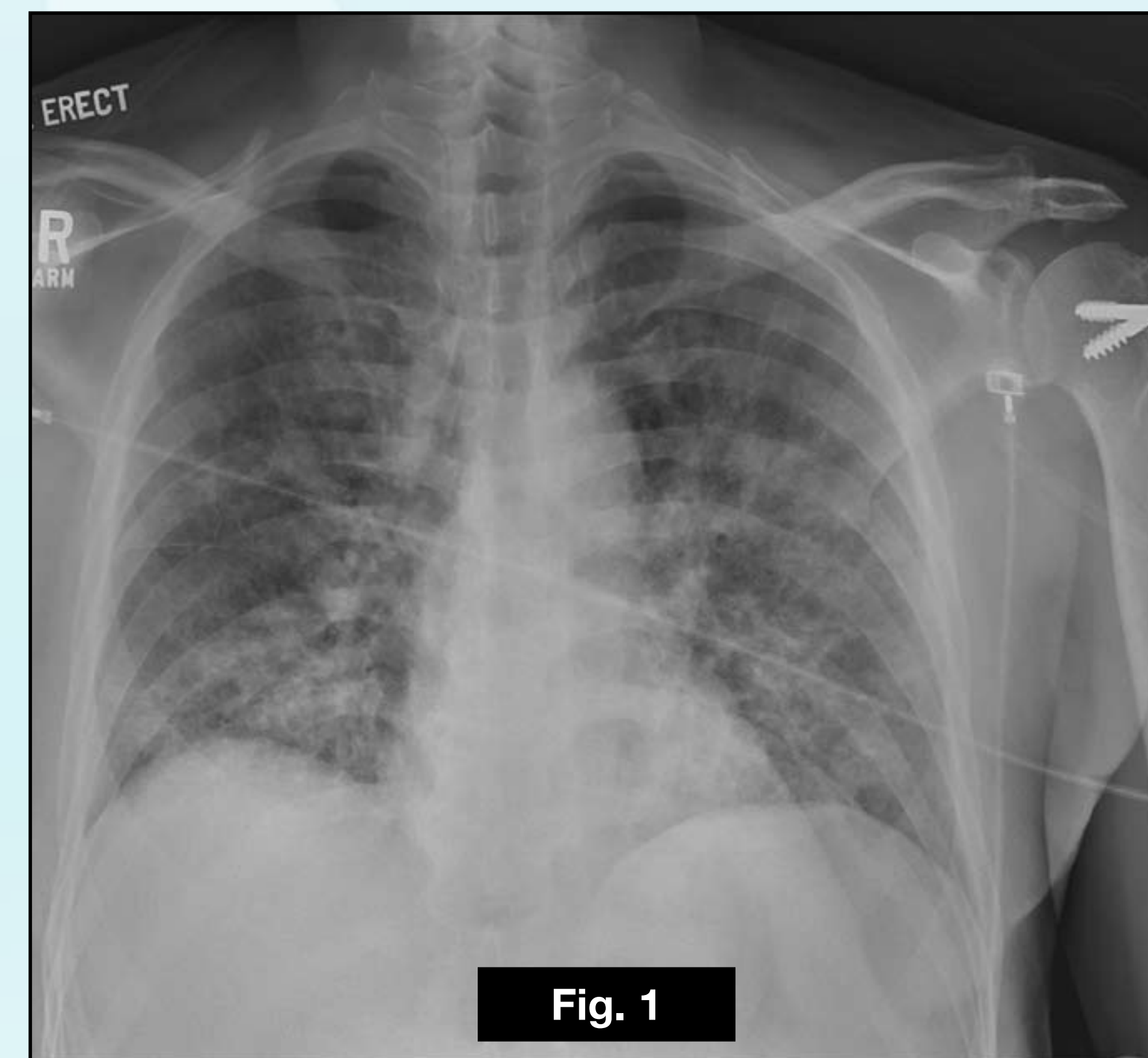


Figure 1: Initial chest X-ray showing bibasilar interstitial infiltrates.

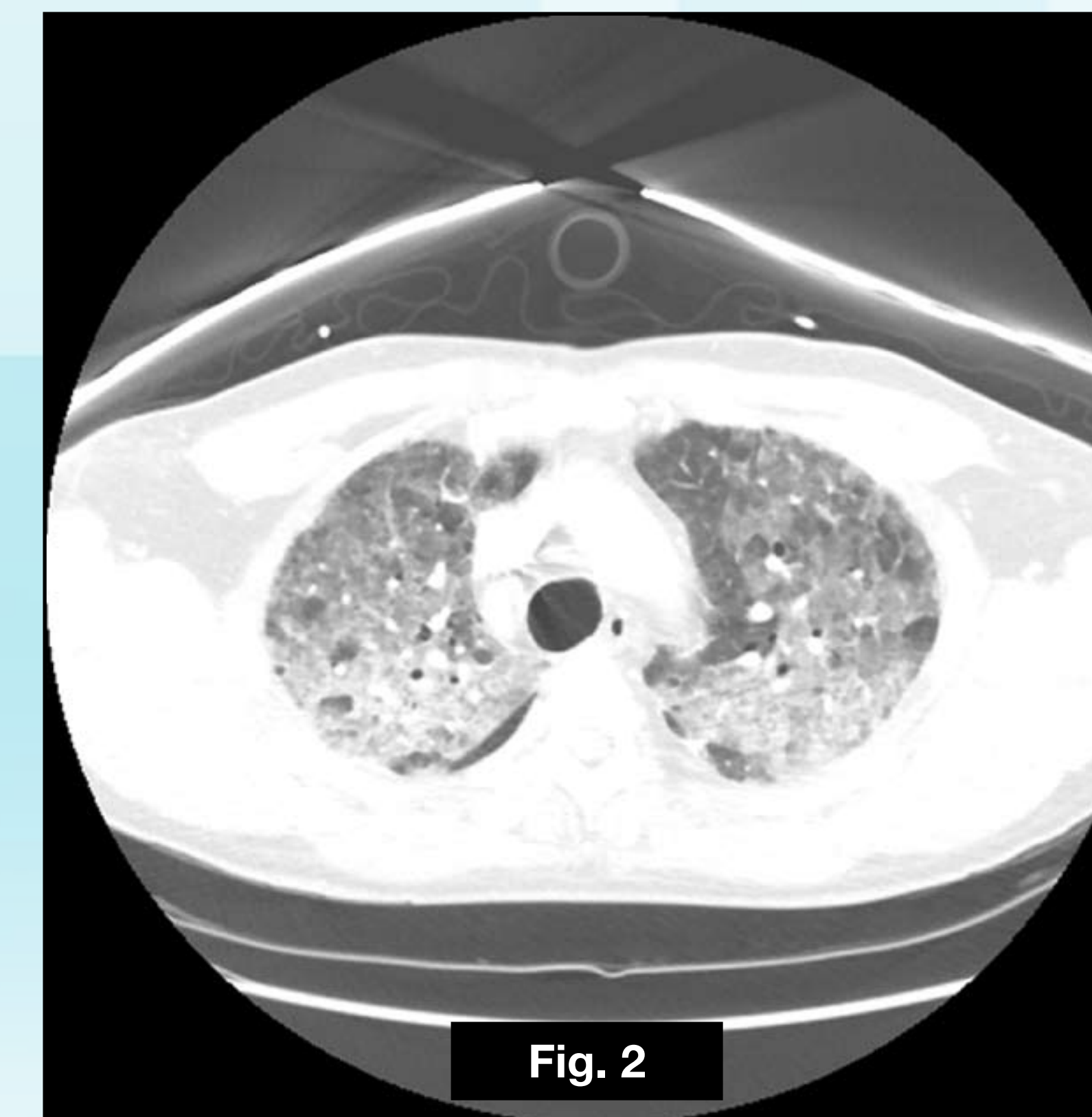


Figure 2: Initial CT of Chest showing bilateral ground-glass opacities.

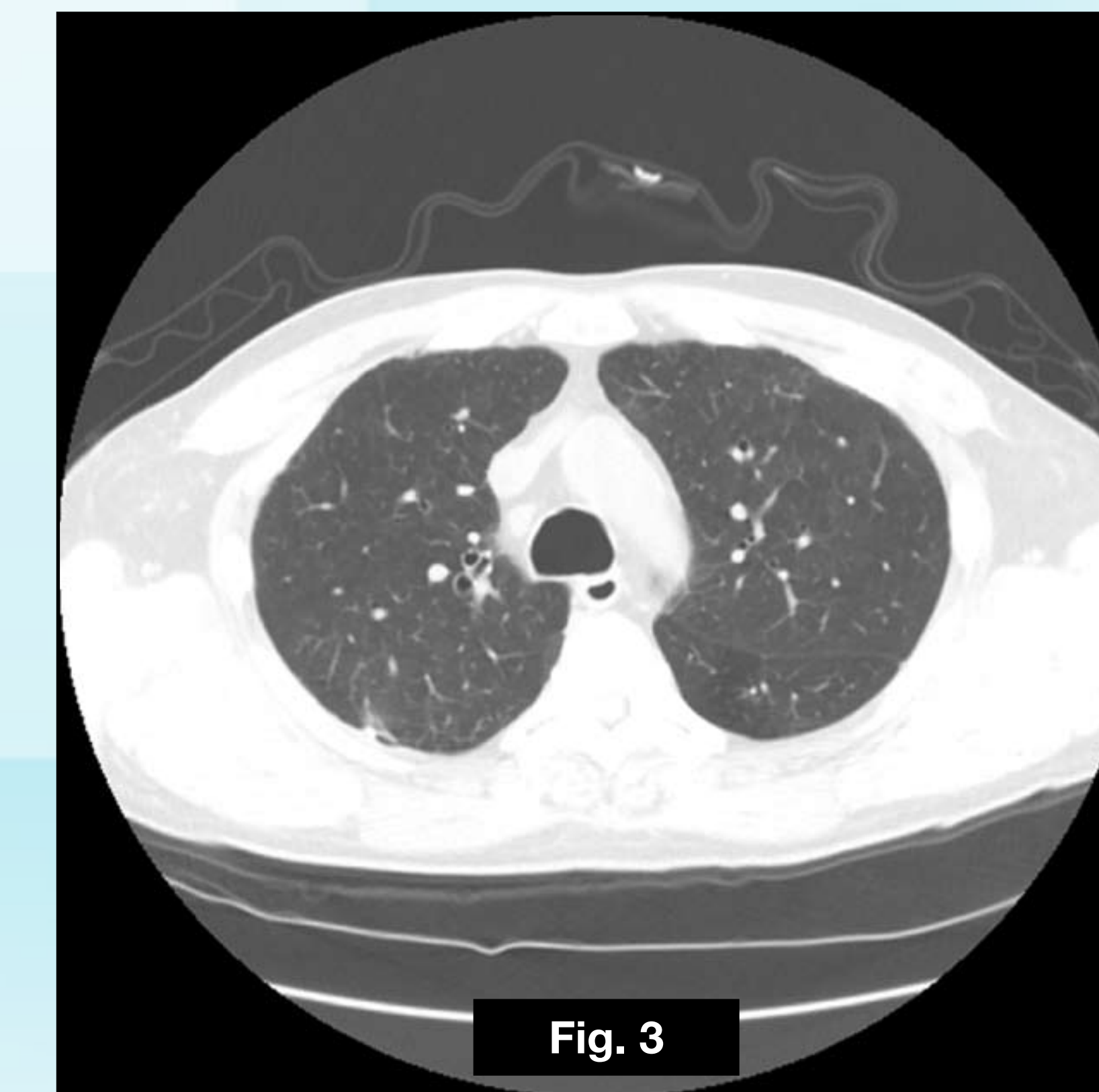

Figure 3: CT of Chest showing resolution of bilateral ground-glass opacities after 10 weeks.

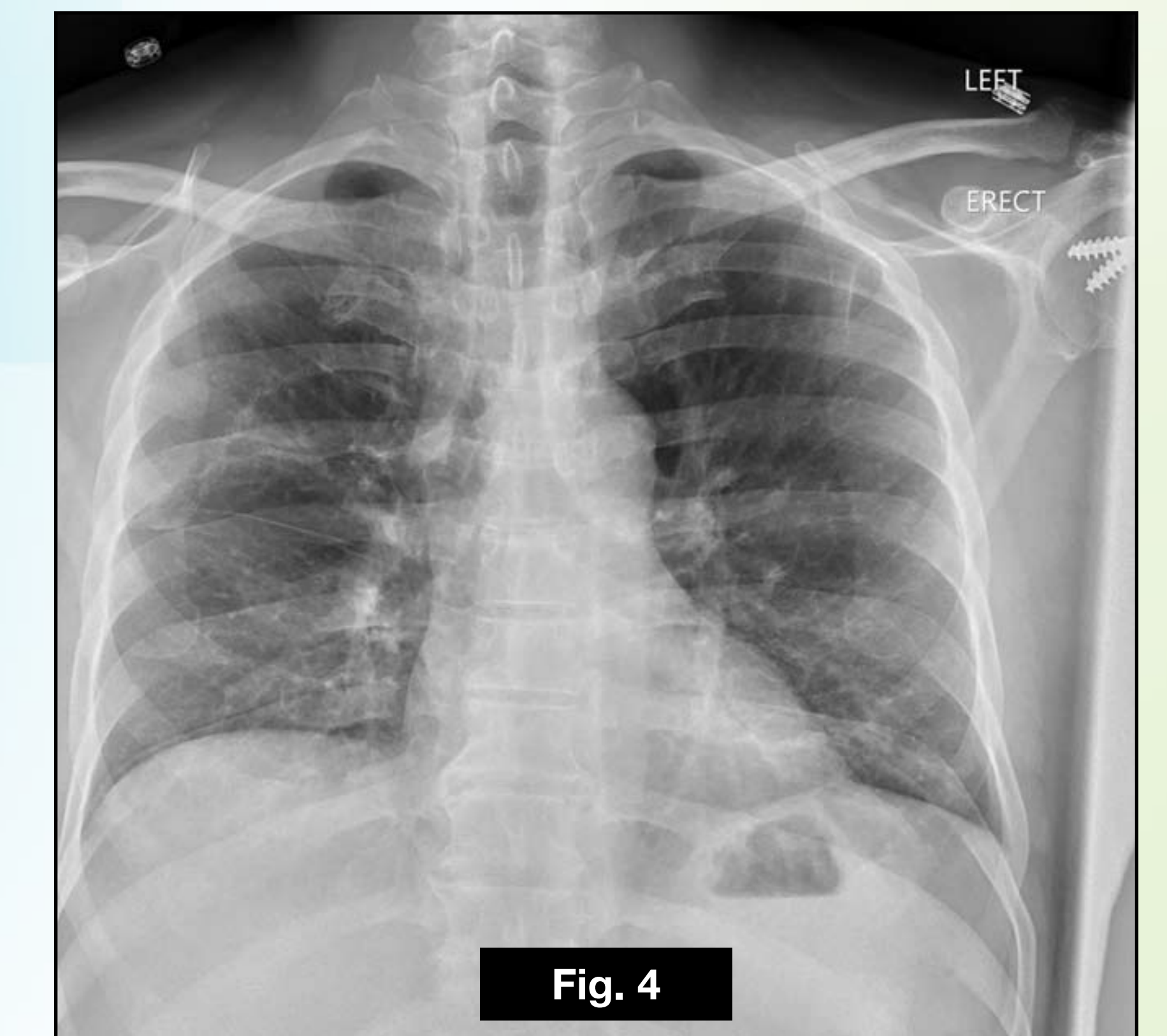


Figure 4: Chest X-ray showing improvement of bibasilar interstitial infiltrates after 12 weeks.

Discussion

- The patient's history, physical exam findings, CT scan and biopsy are all supportive of the diagnosis hypersensitivity pneumonitis.
- The clinical improvement and the resolution of CT findings after oral steroids and cannabis cessation confirms the diagnosis.
- Multiple studies citing that cannabis can be contaminated with fungus and lead to diseases such as invasive and allergic bronchopulmonary aspergillosis. Bacteria linked to hypersensitivity pneumonitis have also been recovered from cannabis samples. Unfortunately, a sample of the patient's suspected contaminated cannabis was not able to be obtained. The patient lives in a suburban area and denied any other exposures known to cause hypersensitivity pneumonitis.
- Specific antibodies were not tested for since hypersensitivity cannot be ruled in or out based on antibody testing.
- To our knowledge, this is the first case report of cannabis smoking induced hypersensitivity pneumonitis.
- Cannabis use is increasing in the United States with an estimated 54% of the population using cannabis at least once before the age of 21.
- It is important to consider hypersensitivity pneumonitis in patients that smoke cannabis and present with dyspnea and cough.

REFERENCES:

1. Girard M, Lacasse Y, Cormier Y. Hypersensitivity pneumonitis. *Allergy*. 2009;64(3):322-334. doi: 10.1111/j.1398-9995.2009.01949.x.
2. Lacasse Y, Girard M, Cormier Y. Recent advances in hypersensitivity pneumonitis. *CHEST Journal*. 2012;142(1):208-217. doi: 10.1378/chest.11-2479.
3. Lacasse Y. - Clinical diagnosis of hypersensitivity pneumonitis. - *Am J Respir Crit Care Med*. 2003(- 8):- 952. doi: - 10.1164/rccm.200301-137OC.
4. Ismail T, McSharry C, Boyd G. Extrinsic allergic alveolitis. *Respirology*. 2006;11(3):262-268. doi: 10.1111/j.1440-1843.2006.00839.x.
5. Kagen S, Kurup V, Sohnle P, and Fink J. Marijuana smoking and fungal sensitization. - *Journal of Allergy and Clinical Immunology*. 1983(- 4):- 389. doi: - 10.1016/0091-6749(83)90067-2.
6. Szyper-Kravitz M, Lang R, Manor Y, and Lahav M. - Early invasive pulmonary aspergillosis in a leukemia patient linked to aspergillus contaminated marijuana smoking. - *Leuk Lymphoma*. 2001(- 6):- 1433. doi: - 10.3109/1042819010909776
7. Wilson KC, Saukkonen JJ. Acute respiratory failure from abused substances. *Journal of Intensive Care Medicine*. 2004;19(4):183-193. doi: 10.1177/0885066604263918.
8. Degenhardt L, Chiu W, Sampson N, et al. - Toward a global view of alcohol, tobacco, cannabis, and cocaine use: Findings from the WHO world mental health surveys. - *PLoS Med*. 2008 5(7):- e141. doi: 10.1371/journal.pmed.0050141.

© 2015 Lehigh Valley Health Network

A PASSION FOR BETTER MEDICINE.™

610-402-CARE LVHN.org