

Adenomyomatous Hyperplasia of the Ampulla of Vater Masquerading as Malignancy: A Case Series

Patrick Hickey DO

Lehigh Valley Health Network, Patrick.Hickey@lvhn.org

Saba Ahmad MD

Lehigh Valley Health Network, Saba.Ahmad@lvhn.org

Matthew Sullivan DO

Lehigh Valley Health Network, Matthew.Sullivan@lvhn.org

Miriam L. Enriquez MD

Lehigh Valley Health Network, Miriam_L.Enriquez@lvhn.org

Jeffrey Brodsky MD

Lehigh Valley Health Network, Jeffrey_T.Brodsky@lvhn.org

See next page for additional authors

Follow this and additional works at: <http://scholarlyworks.lvhn.org/medicine>



Part of the [Gastroenterology Commons](#), [Medical Sciences Commons](#), [Other Medical Specialties Commons](#), and the [Surgery Commons](#)

Published In/Presented At

Hickey, P., Ahmad, S., Sullivan, M., Enriquez, M., Brodsky, J. & Shah, H. (2014, October 17). *Adenomyomatous Hyperplasia of the Ampulla of Vater Masquerading as Malignancy: A Case Series*. Poster session presented at the American College of Gastroenterology Annual Scientific Meeting, Philadelphia, PA.

This Poster is brought to you for free and open access by LVHN Scholarly Works. It has been accepted for inclusion in LVHN Scholarly Works by an authorized administrator. For more information, please contact LibraryServices@lvhn.org.

Authors

Patrick Hickey DO, Saba Ahmad MD, Matthew Sullivan DO, Miriam L. Enriquez MD, Jeffrey Brodsky MD, and Hiral Shah MD

Adenomyomatous Hyperplasia of the Ampulla of Vater Masquerading as Malignancy: A Case Series

Patrick Hickey DO, Saba Ahmad MD, Matthew Sullivan DO, Miriam Enriquez MD, Jeffrey Brodsky MD and Hiral Shah MD
Lehigh Valley Health Network, Allentown, PA

Background

- **Definition:** Adenomyomas are benign lesions likely composed of heterotopic pancreatic tissue rarely seen in the ampulla of Vater
- **Patient Presentation:** Biliary obstruction, abnormal liver tests, imaging abnormalities, and/or incidental discovery
- Endoscopic sampling of the papilla may show epithelial cell atypia suggesting dysplasia
- Patients often undergo invasive surgical resection for presumed malignancy
- **Case Series:** Two patients that underwent surgery for distal common bile duct (CBD) brushings with malignant cytology, but final surgical pathology diagnosing adenomyomatous hyperplasia (AH)

Discussion

- Although uncommon, AH should be considered in the differential of CBD dilatation
- Brush cytology may be suggestive of dysplasia and lead to surgical resection
- Histology will show multiple lobules of glands in the muscle layers of the ampulla and hypertrophy of the sphincter of Oddi
- Gastroenterologists, surgeons, and pathologists should be aware of AH of the ampulla of Vater as a rare benign clinical entity which may mimic a pancreaticobiliary malignancy

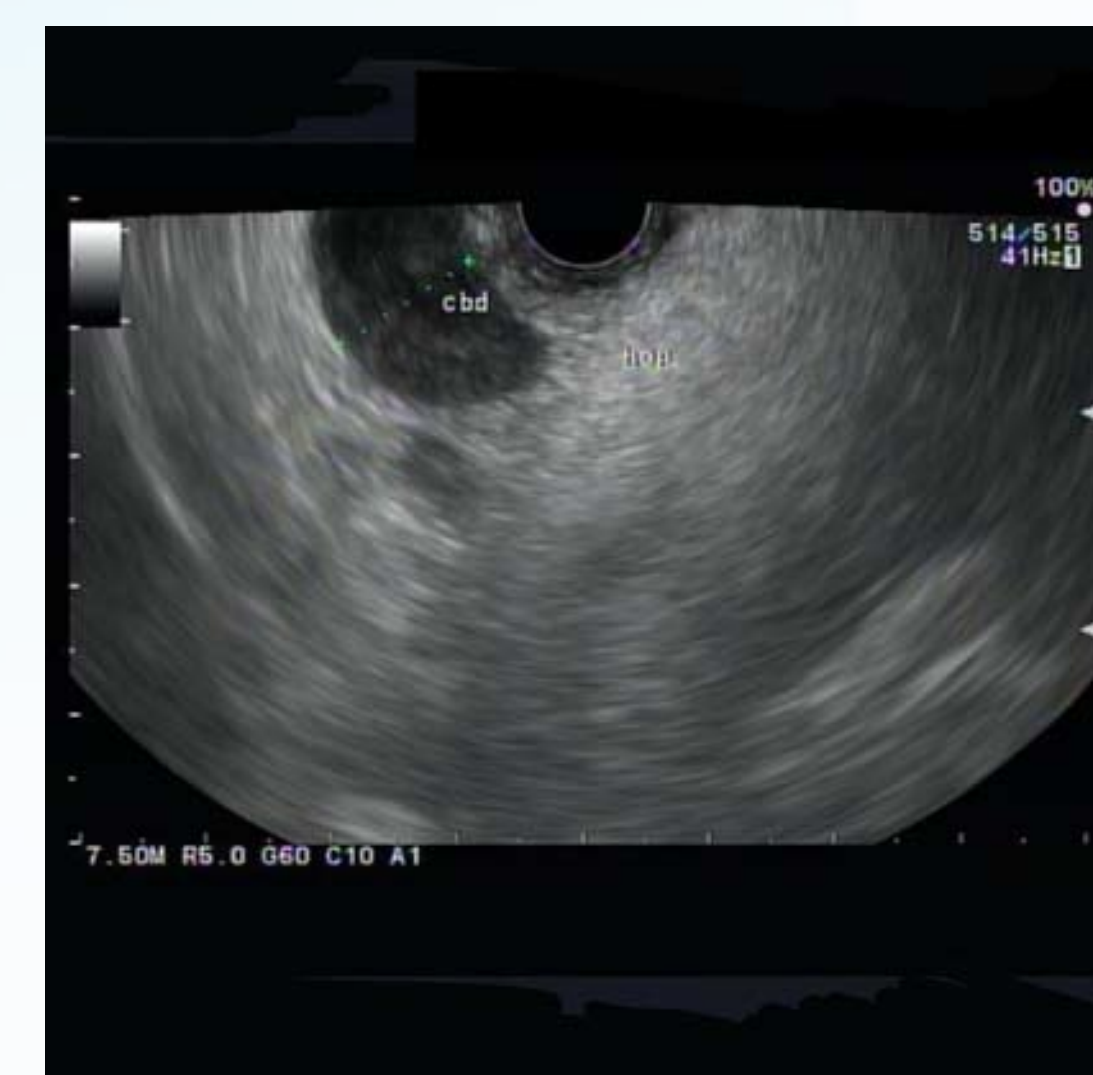References:

- 1 Choi Y, Kim M, Park S, et al. Clinical, pathological, and immunohistochemical features of adenomyoma in the ampulla of vater. *The Korean Journal Of Gastroenterology = Taehan Sohwagi Hakhoe Chi*. December 2013;62(6):352-358.
- 2 Handra-Luca A, Terris B, Couvelard A, Bonte H, Flejou J. Adenomyoma and adenomyomatous hyperplasia of the Vaterian system: clinical, pathological, and new immunohistochemical features of 13 cases. *Modern Pathology: An Official Journal Of The United States And Canadian Academy Of Pathology, Inc*. June 2003;16(6):530-536.
- 3 Kumari N, Vij M. Adenomyoma of ampulla: a rare cause of obstructive jaundice. *Journal Of Surgical Case Reports*. August 1, 2011;2011(8):6.

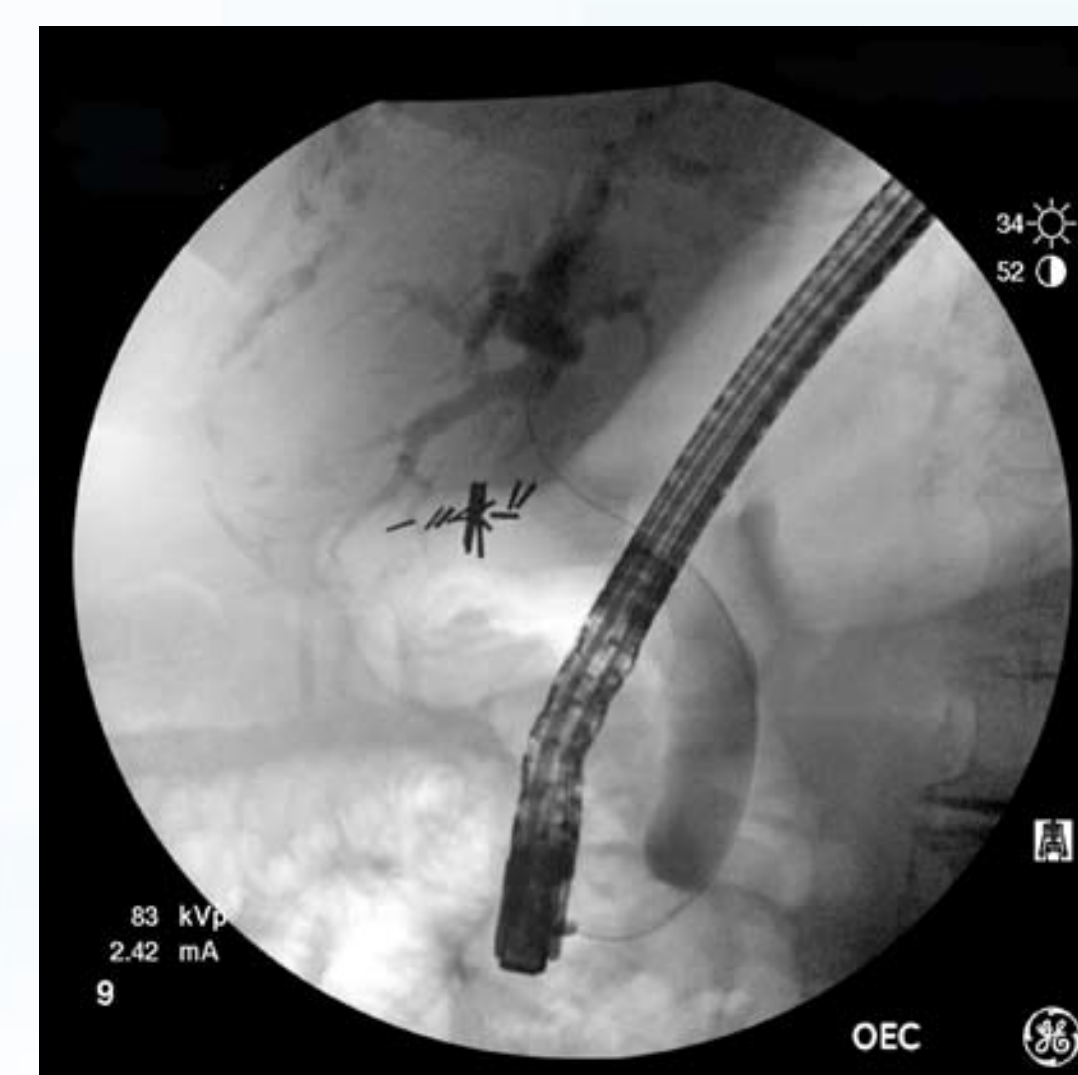Case Presentation

Patient 1

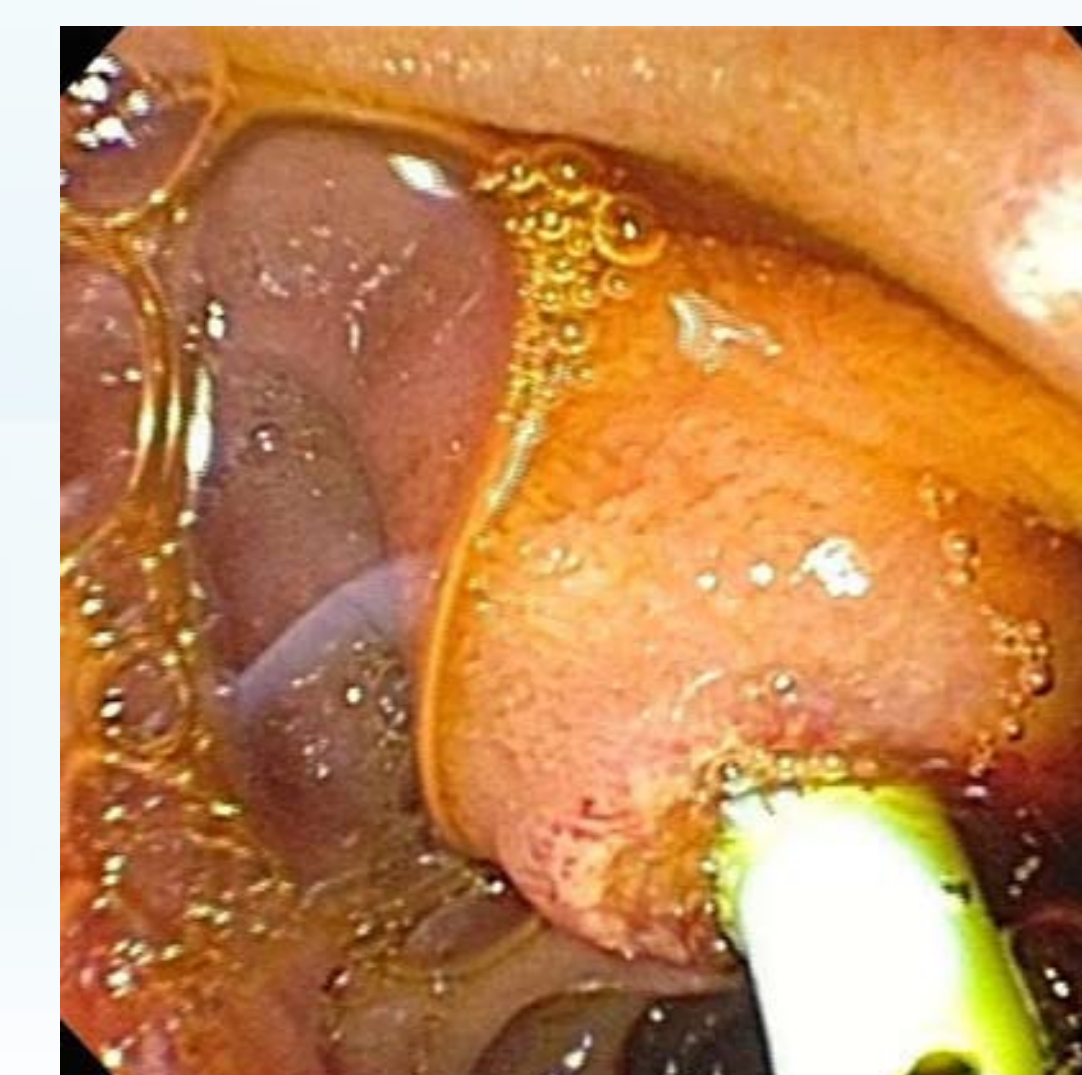
- A 74 year-old female with a history of cholecystectomy presents with recent colonic surgery complicated by an intra-abdominal abscess
- CT imaging: incidental dilatation of the CBD without pancreatic mass
- Endoscopic ultrasound (EUS) and endoscopic retrograde cholangiopancreatography (ERCP):
 - Dilatation of the CBD to 18 mm down to the ampulla and pancreatic duct prominence of 3.5 mm by EUS
 - Cholangiogram: significant upstream CBD dilation and a 1 cm stricture of the distal CBD
- Patient underwent sphincterotomy, cytology brushings of the distal CBD, and biliary stent placement
- Brush cytology: malignant adenocarcinoma
- Patient underwent pancreaticoduodenectomy
- Final surgical pathology: AH of the ampulla of Vater and incidental focal low-grade pancreatic intraepithelial neoplasia
- Post-operative course has been uneventful and she is doing well



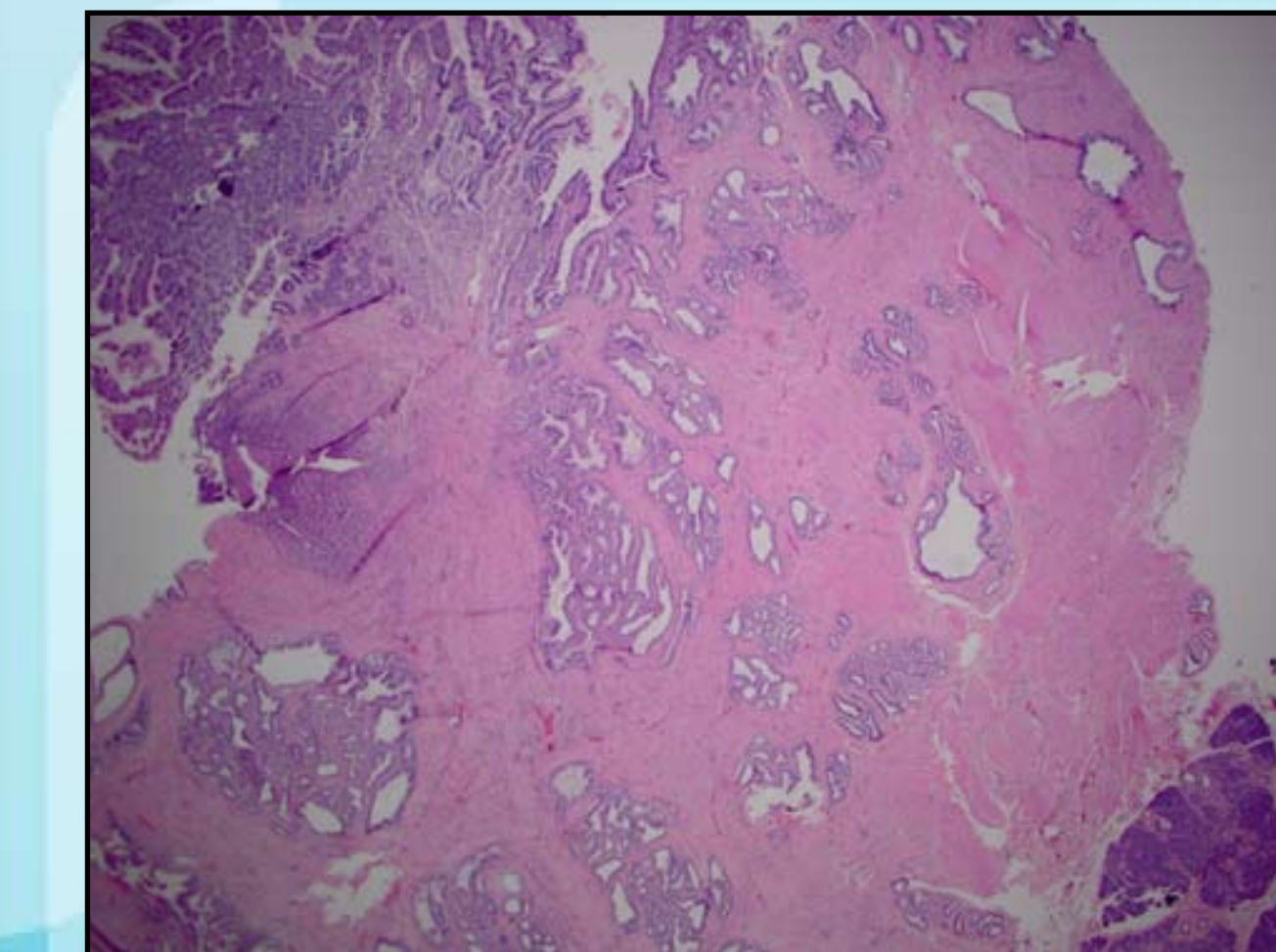
Endoscopic ultrasound showing significant common bile duct dilatation



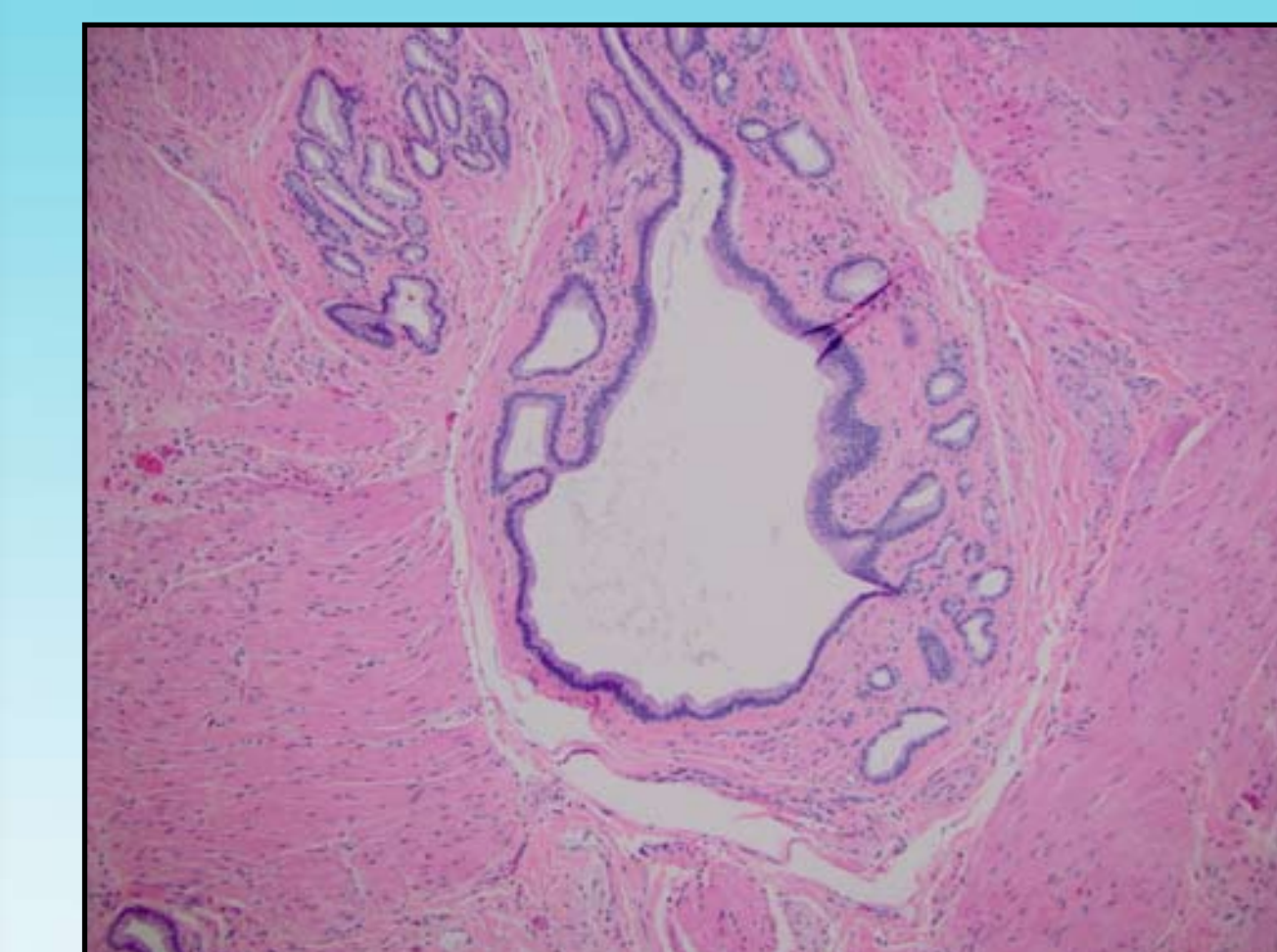
Cholangiogram performed during ERCP showing significant dilatation of the biliary system prior to intervention with a stent



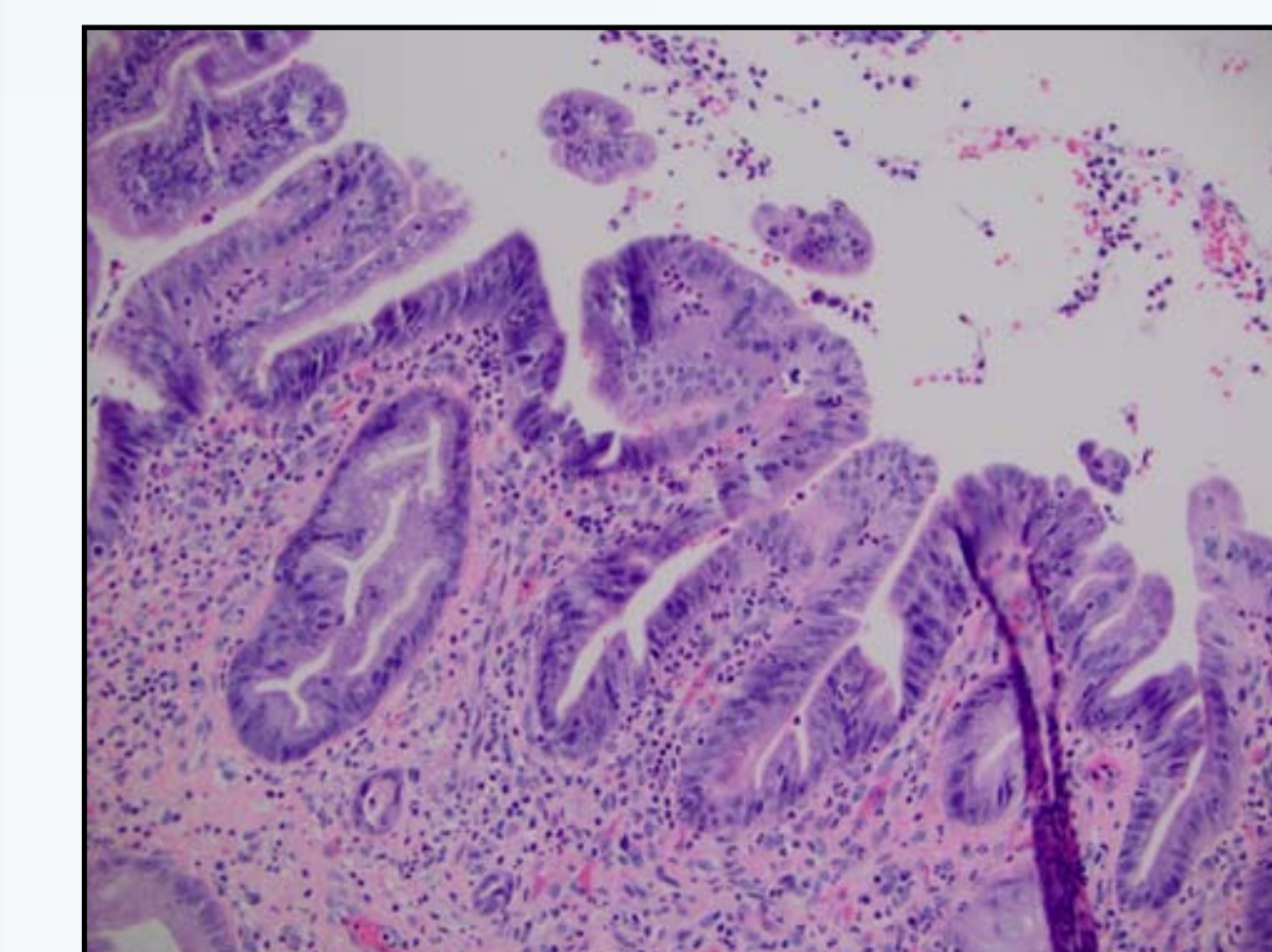
View of prominent ampulla of Vater through a duodenoscope after endoscopic intervention with biliary stent



Histopathology Specimen After Pancreaticoduodenectomy
Orifice of papilla showing features of adenomatous hyperplasia: hyperplastic glandular lobules interspersed among smooth muscle bundles. Ampullary duodenal mucosa present at upper left corner, pancreas present at lower left corner. H and E, 20x



Histopathology Specimen After Pancreaticoduodenectomy
Benign glandular lobule with cystic dilatation, surrounded by smooth muscle bundles. H and E, 100x

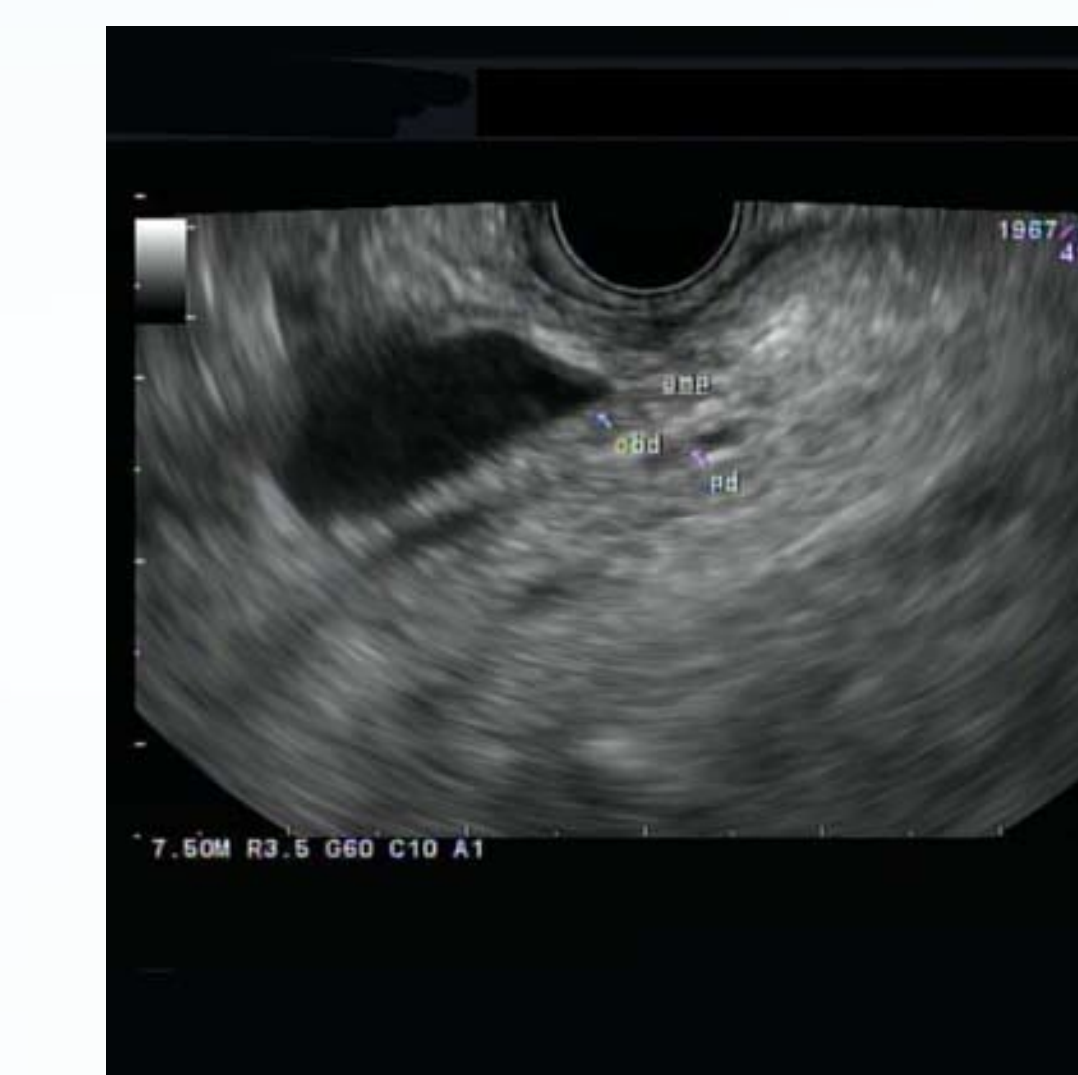

Histopathology Specimen After Pancreaticoduodenectomy
Dilated bile duct showing reactive epithelial atypia and acute inflammation. H and E, 200x

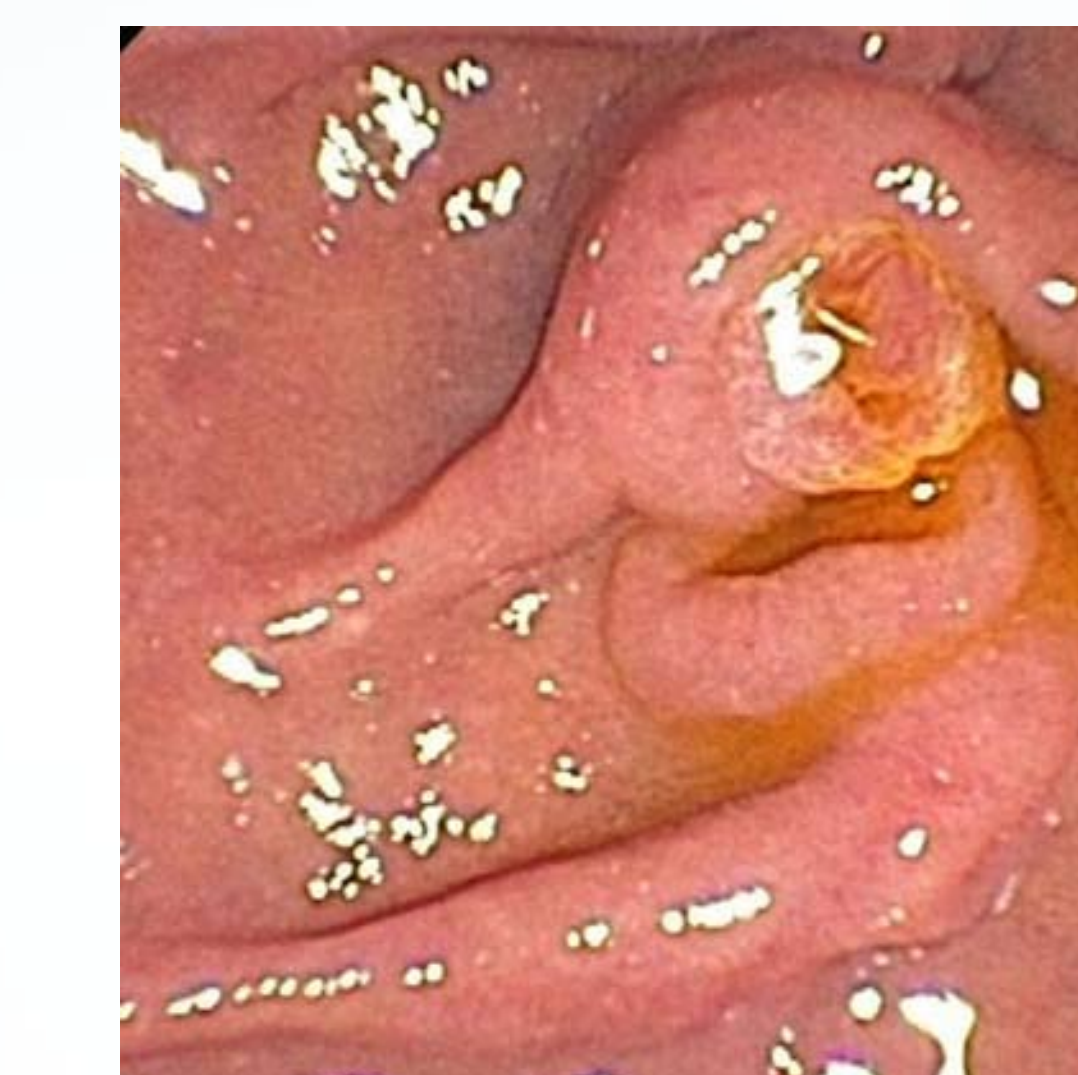Case Presentation

Patient 2

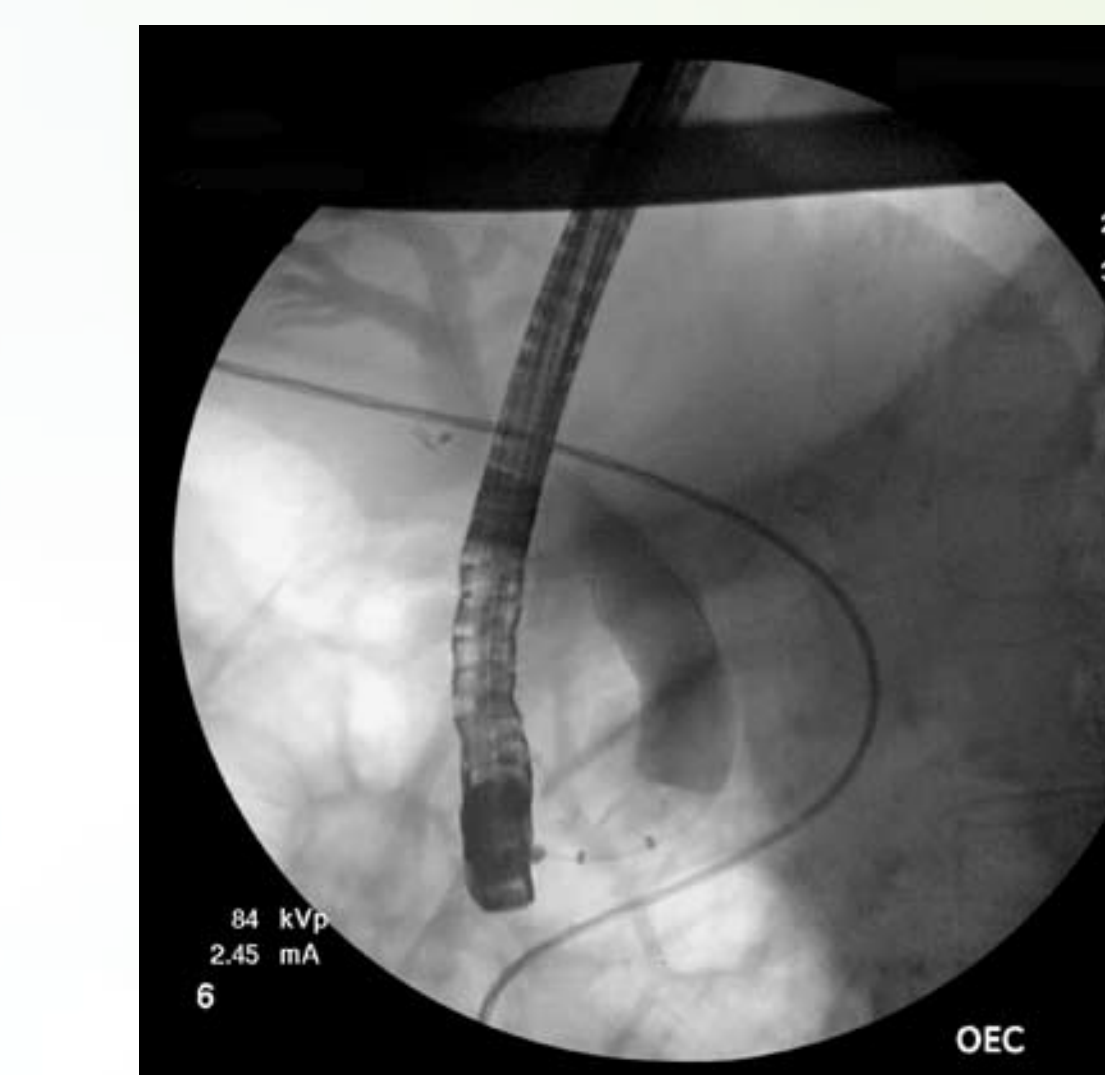
- A 73 year-old female with a history of cervical carcinoma, chronic kidney disease, and cholecystectomy presents with epigastric pain, back pain, dark urine, and weight loss
- MRCP: CBD dilatation to 20 mm
- EUS and ERCP showed:
 - CBD dilatation to 20 mm (10 mm in the distal CBD) and a prominent pancreatic duct (3 mm)
 - Cholangiogram: shelf in the CBD with abrupt tapering in the distal CBD
- Patient underwent sphincterotomy, cytology brushings of the distal CBD, and biliary stenting
- Brush cytology: distal CBD high-grade biliary intraepithelial neoplasia; adenocarcinoma could not be excluded
- Patient underwent pancreaticoduodenectomy
- Final surgical pathology: features of AH of the ampulla of Vater without carcinoma
- Her course has been uneventful after post-operative recovery



EUS: significant common bile duct dilatation with suggestion of abrupt taper



View of prominent ampulla of Vater through a duodenoscope prior to ERCP



Cholangiogram performed during ERCP showing significant dilatation of the intrahepatic and extrahepatic biliary system prior to intervention with a stent

© 2014 Lehigh Valley Health Network