


Contents lists available at ScienceDirect

The Journal of Foot & Ankle Surgery

journal homepage: www.jfas.org

Functional Medium-Term Results After Autologous Matrix-Induced Chondrogenesis for Osteochondral Lesions of the Talus: A 5-Year Prospective Cohort Study



Oliver Gottschalk, MD¹, Sebastian Altenberger, MD¹, Sebastian Baumbach, MD^{1,2}, Stefanie Kriegelstein, MD¹, Florian Dreyer, MD¹, Alexander Mehlhorn, MD¹, Hubert Hörterer, MD¹, Andreas Töpfer, MD¹, Anke Röser, MD¹, Markus Walther, MD³

¹ Physician Specialized in Orthopedic Surgery, Center for Foot and Ankle Surgery, Schön Klinik München Harlaching, Munich, Germany

² Physician Specialized in Orthopedic Surgery, Department of General Trauma, and Reconstructive Surgery, University Hospital Munich, Ludwig-Maximilians University Munich, Munich, Germany

³ Professor, Center for Foot and Ankle Surgery, Schön Klinik München Harlaching, Munich, Germany

ARTICLE INFO

Level of Clinical Evidence: 3

Keywords:

AMIC
microfracturing
osteochondral defects
osteochondrosis dissecans osteochondral lesion
sports
talus

ABSTRACT

Autologous matrix-induced chondrogenesis (AMIC) has gained popularity in the treatment of osteochondral lesions of the talus. Previous studies have presented promising short-term results for AMIC talar osteochondral lesion repair, a 1-step technique using a collagen type I/III bilayer matrix. The aim of the present study was to investigate the mid-term effects. The 5-year results of a prospective cohort study are presented. All patients underwent an open AMIC procedure for a talar osteochondral lesion. Data analysis included general demographic data, preoperative magnetic resonance imaging findings, intraoperative details, and German version of the Foot Function Index (FFI-D) scores preoperatively and at 1 and 5 years after surgery. The primary outcome variable was the longitudinal effect of the procedure, and the influence of various variables on the outcome was tested. Of 47 consecutive patients, 21 (45%) were included. Of the 21 patients, 8 were female (38%) and 13 were male (62%), with a mean age of 37 ± 15 (range 15 to 62) years and a body mass index of 26 ± 5 (range 20 to 38) kg/m^2 . The defect size was 1.4 ± 0.9 (range 0.2 to 4.0) cm^2 . The FFI-D decreased significantly from preoperatively to 1 year postoperatively (56 ± 18 versus 33 ± 25 ; $p = .003$), with a further, nonsignificant decrease between the 1- and 5-year follow-up examination (33 ± 25 versus 24 ± 21 ; $p = .457$). Similar results were found for the FFI-D subscales of function and pain. The body mass index and lesion size showed a positive correlation with the preoperative FFI-D overall and subscale scores. These results showed a significant improvement in pain and function after the AMIC procedure, with a significant return to sports by the 5-year follow-up point. The greatest improvement overall was seen within the first year; however, further clinical satisfaction among the patients was noticeable after 5 years. © 2017 by the American College of Foot and Ankle Surgeons. This is an open access article under the CC BY-NC-ND license (<http://creativecommons.org/licenses/by-nc-nd/4.0/>).

Osteochondral lesions (OCLs) are being more frequently diagnosed owing to the better diagnostic tests available and a better awareness of the symptoms. The intrinsic repair mechanisms are poor; thus, good therapeutic options are needed (1,2). Nonoperative treatment should only be considered for stage I, II, or III lesions using the Berndt and Harty classification. Higher stage lesions show better outcomes with operative treatment. Most likely, the causes for OCLs include

vascular necrosis (3), systemic vasculopathy, acute trauma (4), chronic microtrauma (5), endocrine or metabolic factors (6), degenerative joint disease (7), joint malalignment (8), and genetic predisposition (9). The primary goal of operative treatment is to restore the blood circulation and regain joint protection most similar to the original hyaline cartilage. The microfracture method has been a promising therapeutic option but with the notable limitation of lesions $>150 \text{ mm}^2$ in area or $>15 \text{ mm}$ in diameter (10,11). The aim of microfracturing is to mobilize progenitor cells from the bone marrow such that repair cartilage can develop to cover the defect. Bone marrow stimulation results in mesenchymal cells from the marrow to create a fibrocartilaginous repair tissue at the site of the lesion (12).

Lesions $>150 \text{ mm}^2$ in area or $>15 \text{ mm}$ in diameter require a different treatment approach. Osteochondral autologous transplantation and autologous chondrocyte implantation (ACI) are new therapeutic options

Financial Disclosure: None reported.

Conflict of Interest: M. Walther received reimbursements of travel expenses and speaker's fees from Geistlich Pharma AG (Wolhusen, Switzerland).

Address correspondence to: Oliver Gottschalk, MD, Center for Foot and Ankle Surgery, Schön Klinik München Harlaching, Harlachinger Strasse 51, Munich 81347, Germany.

E-mail address: ogottschalk@schoen-kliniken.de (O. Gottschalk).

for large lesions (13). Both options harvest cartilage cells from a donor site separate from the location of the actual lesion. ACI is a 2-step procedure that is time consuming and expensive. Recently, a study by Buda et al (14) showed no advantage for ACI compared with bone marrow-derived cell transplantation. They also reported the preferred use of bone marrow-derived cell transplantation compared with ACI (14). Because of limitations, such as sacrificing healthy cartilage, multiple-stage operations, the high cost, and limited graft availability, alternative methods to repair OCLs are needed. Autologous matrix-induced chondrogenesis (AMIC) meets this need by addressing the limitations of other OCL repair methods. AMIC was first described in 1999 by Behrens et al (15) and uses a collagen type I/III bilayer matrix (Chondro-Gide®; Geistlich Pharma AG, Wolhusen, Switzerland) to stabilize the super clot on top of the lesion after microfracturing (16). In AMIC, the matrix is secured at its location using commercially available fibrin glue. After microfracture, mesenchymal progenitor cells migrate toward and adhere to the porous layer of the matrix. With the matrix in place, the loss of cells through leakage into the joint space can be avoided. Also, mechanical stress on the cells in the regeneration zone will be minimized. The combined use of the AMIC matrix and the fibrin glue (Tissucol or Tisseel; Baxter Healthcare, Deerfield, IL) support the chondrogenic differentiation of human mesenchymal stem cells and significantly enhance proteoglycan deposition (17,18).

Although fibrin glue has been used in surgical procedures for more than a decade, serving a variety of purposes, such as sutureless closure of colonic defects (19), corneal lamellar healing (20), bone repair (21,22), and reconstruction of focal cartilage defects (23), its use is not without controversy. A study by Filardo et al (24) showed improvement in postoperative scaffold stability and integrity using fibrin glue. Wang et al (25), however, reported that a bone matrix gelatin and fibrin glue scaffold showed signs of degradation after 8 weeks despite the presence of supporting chondrocyte attachment, proliferation, and biosynthesis of cartilaginous matrix components. Another study proposed that fibrin sealant supports the migration and proliferation of human chondrocytes via thrombin (26).

Although the AMIC procedure seems to have a beneficial effect on OCLs of the talus, diverse results of microfracture and AMIC use have been presented. In a sheep model, Beck et al (27) used a different collagen membrane and showed bone cyst formation after microfracturing with a communication present between the drilling holes and the cysts. Another study, by Zhang et al (28), demonstrated with a short-term follow-up period that the clinical symptoms had significantly improved. Specifically, magnetic resonance imaging (MRI) showed that defect coverage of the lesion of $\leq 75\%$, with hyaline-like cartilage tissue, was achieved (28).

The different approaches available to examine the effect of AMIC outcomes have been of recent interest. New studies have reported good results for all arthroscopic uses of AMIC (29,30). MRI examination of AMIC-treated patients during a short-term follow-up period showed differences in the collagen matrix and cartilage present (31), with lower glycosaminoglycan content than present in normal hyaline cartilage (32). In patients with high function demands and the need for pain-free joints, such as athletes and patients with increased activity levels, AMIC intervention has provided good results (33,34).

Therefore, the aim of our study was to investigate the mid-term outcomes at the 5-year follow-up point on pain and function in patients who had undergone the AMIC procedure.

Patients and Methods

Study Design

We performed a cohort study from a single specialized orthopedic foot and ankle clinic using prospective 5-year follow-up data. The institutional review board approved the present study. Patients were included after providing informed consent.

Patients

Of 47 consecutive patients undergoing an open AMIC procedure for a talar OCL without malleolar osteotomy from June 2010 to December 2011, 21 (45%) were included in the study cohort. The exclusion criteria were generalized degenerative changes in the joint, cartilage defects in the corresponding opposite joint surface, inflammatory joint disease, crystal arthropathy, neuroarthropathy, or 5-year follow-up data missing.

Surgical Technique

Preoperative MRI scans of the ankle were used for assessment of cartilage lesions, possible subchondral cysts, areas of necrotic bone, and other accompanying pathologic entities (Figs. 1 and 2).

In all patients, the skin incision was performed using a ventral approach, depending on the location of the defect (either a ventromedial approach between the medial malleolus and the anterior tibial tendon or a ventrocentral approach between the anterior tibial and the extensor hallucis longus tendon). After dissection to the level of the joint capsule, the joint was opened by a longitudinal incision. A 2.0-mm Kirschner wire was drilled into the distal tibia and a second one parallel to it in the talus. Unstable cartilage was radically debrided. All necrotic bone was removed, and any cysts were curetted (Fig. 3). The underlying sclerotic zone was perforated using multiple small drill holes (1.2-mm Kirschner wire) with adequate cooling or microfracture. The osseous defect was reconstructed to the level of the subchondral bone lamella using autologous cancellous bone.

The defect size was measured with the help of aluminum foil, which was pressed into the defect with forceps such that the borders of the cartilage were clearly depicted. The aluminum foil was then cut to size and its exact fit was verified. The collagen matrix, hydrated in a physiologic saline solution, was cut to shape with the help of the template. When hydrated, the matrix expands by 10% to 15%. The matrix has a rough side, which was placed facing the bone, with the smooth side facing the joint. The cancellous bone graft was covered with commercially available fibrin glue, and the collagen matrix was glued onto it (Fig. 4).

Finally, the joint was closed in layers using resorbable suture material. A drain without suction was inserted, when necessary.

Postoperative Management

The operated ankle was completely immobilized at 90° for 48 hours. The drain, if inserted, was removed within the 48-hour period, and continuous passive motion exercises, limited to the 20°–0°–20° range, were started. A splint was used for 2 weeks until wound healing was complete. Partial weightbearing of 10 kg for the first 6 weeks was advised. Thereafter, a stepwise increase in weightbearing, increasing by 10 to 15 kg each week, up to week 12 was allowed. From week 13 onward, the patient was permitted to incur stress from activities of daily living, cycling, and swimming. Patients

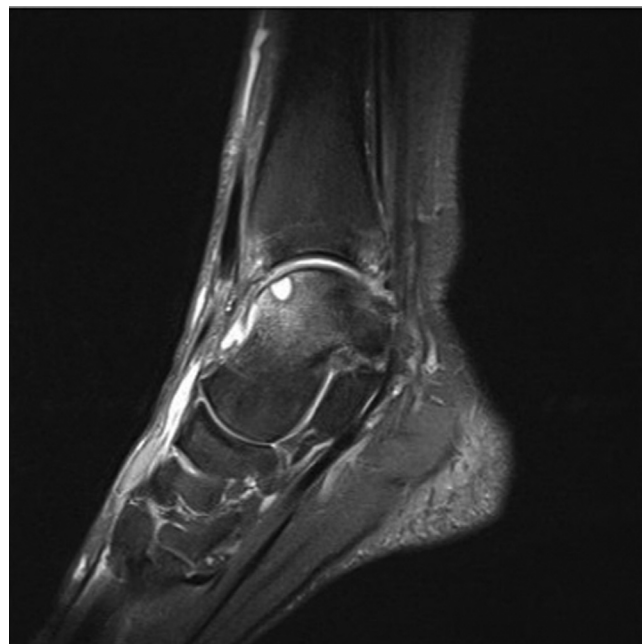

Fig. 1. Preoperative magnetic resonance image, sagittal view, of medial osteochondral lesion.

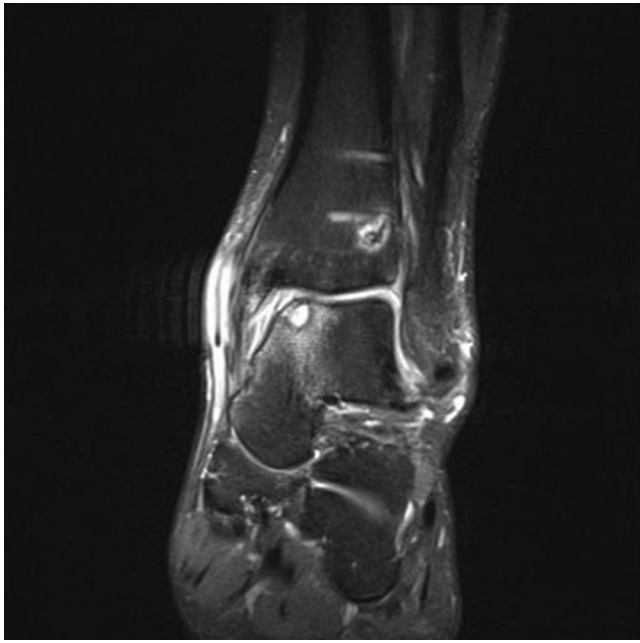


Fig. 2. Preoperative magnetic resonance image, coronal view, of medial osteochondral lesion.

were advised to avoid participation in sports involving impact loading or rapid changes in direction for ≥ 12 months.

Data Collection

Data were collected from the outpatient records and available in-house data. In accordance with our standardized quality management policy, the patients were asked to complete a standardized foot and ankle questionnaire (Foot Function Index, German version [FFI-D]) (35) preoperatively and 1 year postoperatively. At the 5-year follow-up examination, the patients were asked to again complete the FFI-D. The collected data points of interest are listed in Table 1.

Outcome Variables

The primary outcome variable was the FFI-D score. The secondary outcome variables were the influence of age, gender, smoking, body mass index (BMI), duration of symptoms, relationship to trauma, defect size, and defect location.

Statistical Analysis

Statistical analysis was performed using the software package SPSS, version 22 (IBM Corp., Armonk, NY). The data are presented as the mean \pm standard deviation. General descriptive statistical analyses were performed. Data were compared using the *t* test and repeated measurement analysis of variance (post hoc Bonferroni test).

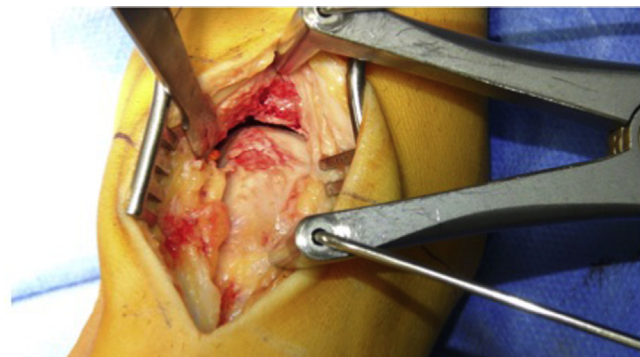


Fig. 3. Intraoperative view of the lesion.

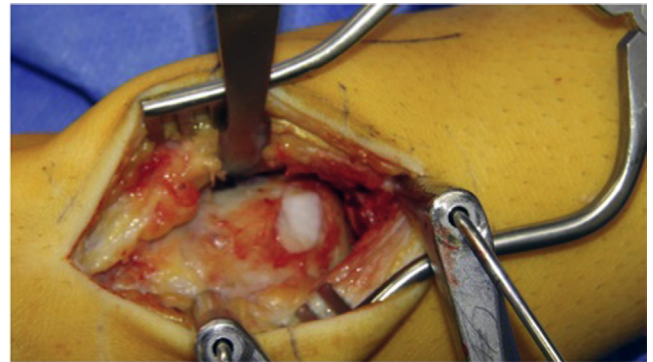


Fig. 4. Lesion after cancellous bone filling and covering with the collagen membrane.

Correlations were determined by calculating the Spearman coefficient for normally distributed values. *p* Values $\leq .05$ were considered to indicate statistical significance.

Results

Demographic Data

Twenty-one patients (45% of 47 consecutive patients) were included in our analysis. The other AMIC patients were not included owing to missing follow-up data, a change of address, or a lack of interest. Of the 21 patients, 8 (38%) were female and 13 (62%) were male, with a mean age of 37 ± 15 (range 15 to 62) years and an average BMI of 26 ± 5 (range 20 to 38) kg/m^2 . The mean duration of symptoms was 54 ± 43 (range 5 to 132) months. Of the 21 patients, 3 (14%) were smokers; and 12 (57%) had undergone a previous ipsilateral surgical intervention. Finally, 10 (48%) had not experienced any trauma before the beginning of the symptoms; 2 (10%) had experienced trauma within in the previous year; and 9 (43%) had experienced trauma >12 months before surgery.

Preoperative MRI

All 21 patients (100%), underwent preoperative MRI. Sagittal and coronal views were used to determine the defect size and location. The mean defect size was 1.4 ± 0.9 (range 0.2 to 4) cm^2 . The defect was

Table 1
Inventory of patient data collected

Variable
Demographic data
Gender
Age (y)
BMI (kg/m^2)
Symptom duration (mo)
Smoking status
Previous surgical interventions
Etiology (no trauma, trauma within 12 mo, trauma >12 mo)
Preoperative MRI findings
Lesion size (cm^2)
Lesion location (medial, central, lateral)
Surgical factors
Date of surgery
Additional procedures
FFI-D
Preoperative assessment
1-y Postoperative assessment
Prospective
5-y Postoperative follow-up assessment

Abbreviations: BMI, body mass index; FFI-D, German version of the Foot Function Index; MRI, magnetic resonance imaging.

located medial to the talus in 16 (76%), central in 2 (10%), and lateral in 3 (14%) patients.

Intraoperative Details

Surgery was performed from June 8, 2010 to December 6, 2011. Additional procedures, listed in Table 2, were required for 20 patients (95%).

Subjective Outcome (FFI-D)

The FFI-D total score decreased significantly from preoperatively to 1 year postoperatively (56 ± 18 versus 33 ± 25 ; $p = .003$), with a further, nonsignificant decrease between the 1- and 5-year follow-up points (33 ± 25 versus 24 ± 21 ; $p = .457$; Fig. 5).

Similar results were observed for the 2 FFI-D subscales of function (Fig. 6A) and pain (Fig. 6B). Analysis of the FFI-D subscales of function and pain revealed significant decreases from preoperatively to 1 year postoperatively (58 ± 18 versus 36 ± 27 , $p = .004$; and 53 ± 21 versus 29 ± 24 , $p = .003$; respectively), with a further, nonsignificant decrease between the 1- and 5-year follow-up points (36 ± 27 versus 27 ± 23 , $p = .482$; and 29 ± 24 versus 21 ± 20 , $p = .514$; respectively).

Furthermore, each item of the FFI-D at each follow-up examination (preoperatively and 1 and 5 years postoperatively) was analyzed separately (Supplemental Table 1). No overall significant differences (analysis of variance) could be found for the items 2 to 8 in the pain subscale and items 6, 7, 8, and 10 in the function subscale. For all other items, significant overall differences were found. No significant differences could be identified between the preoperative and 1-year postoperative values, except for the item 1 in the pain subscale ($p = .002$). However, significant differences were found for all items when comparing the preoperative and 5-year follow-up scores ($p = .022$ to $p < .001$). In particular, item 9 in the FFI-D function subscale, evaluating sports activity (Fig. 7), showed a significant decrease between the preoperative and 5-year follow-up points ($p = .013$).

Factors Affecting FFI-D Scores

Gender, smoking status, previous surgical interventions, etiology (trauma), defect location, and symptom duration had no a significant influence on the FFI-D score or subgroup scores. Age and BMI showed a moderate, but significant, positive correlation with the preoperative FFI-D and both subscale (FFI-D for pain and FFI-D for function) outcomes analyzed (Table 3). Only the size of the lesion resulted in a significant positive correlation with the FFI-D and subscale scores preoperatively and at 5 years postoperatively.

MRI Findings at 5-Year Follow-Up Point

The MOCART (3-dimensional magnetic resonance observation of cartilage repair tissue) score was used to assess the findings on the

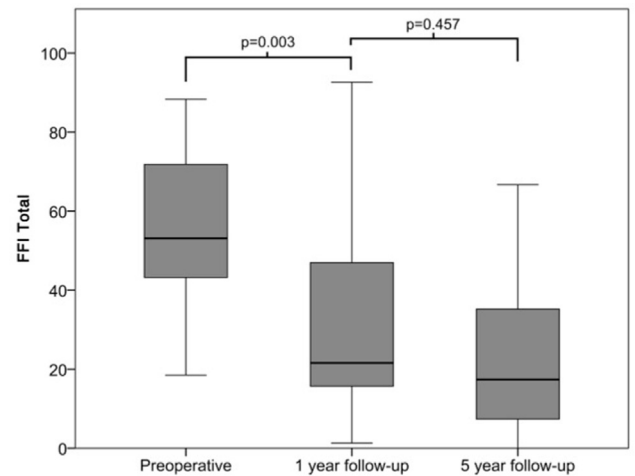


Fig. 5. Comparison of the German version of the Foot Function Index (FFI-D) total score at the preoperative and 1- and 5-year follow-up assessments.

MRI scans at the 5-year follow-up point. Local hypertrophy was found in 60% of the patients; however, the cartilage signal showed no significant differences compared with the surrounding cartilage. Bone regeneration was incomplete in a great number of patients. The subchondral lamella was intact in only 20% of the patients, and the subchondral bones showed minimal edema in 90% of the patients. The average MOCART score was 54 ± 14 . Further details are given in Table 4.

Discussion

Using a biomaterial, in AMIC, a collagen matrix, helps to keep and stabilize the super clot in the defect zone and protects it from being displaced (36,37). The collagen matrix can be implanted without having to perform an osteotomy of the medial malleolus (38). The collagen matrix is available as a ready to use product with a long shelf-life (Chondro-Gide®; Geistlich Pharma AG). The membrane has been certified in the European community for cartilage reconstruction. No donor site is required. Compared with cartilage reconstruction with in vitro-cultured chondrocytes, the use of the membrane results in significantly lower selling.

The results of the present investigation showed significant improvement in pain and function 5 years after AMIC talar OCL repair. Several short-term studies have demonstrated good clinical and morphologic results (16,39). However, to the best of our knowledge, no other study has investigated the outcomes of AMIC treatment of talar OCLs during a 5-year period. Using AMIC in other joints, however, has resulted in beneficial clinical outcomes in several studies (40–42). One study by Fontana and de Girolama (43) reported the mid-term results with a 5-year benefit of AMIC for femoral acetabular impingement-induced chondral lesions compared with microfracture treatment.

Although most patients showed a decrease in the overall FFI-D score after 5 years, some patients still reported a pain level and constraint of function unchanged from those preoperatively. A few patients presented with a greater FFI-D score postoperatively than preoperatively. This raises the question of which factors might influence the long-term outcomes with AMIC treatment. Because most patients with talar OCLs have experienced trauma (5), it is not uncommon for patients undergoing surgery of a talar OCL to also present with other pathologic features in the ankle. One of the reasons for the different outcomes in clinical satisfaction might be related to the

Table 2

Additional procedures performed concurrent with Autologous matrix-induced chondrogenesis procedure (N = 21 patients)

Additional Procedure	Patients [n (%)]
Cancellous bone graft	16 (76.19)
Reconstruction of lateral ligaments	5 (23.81)
Neurolysis of peroneus superficialis nerve	1 (4.76)
Arthroscopy before arthrotomy	10 (47.62)
Reconstruction of peroneal tendon	2 (9.52)
Hardware removal	1 (4.76)
Lengthening of Achilles tendon	1 (4.76)
Reconstruction of syndesmosis	1 (4.76)

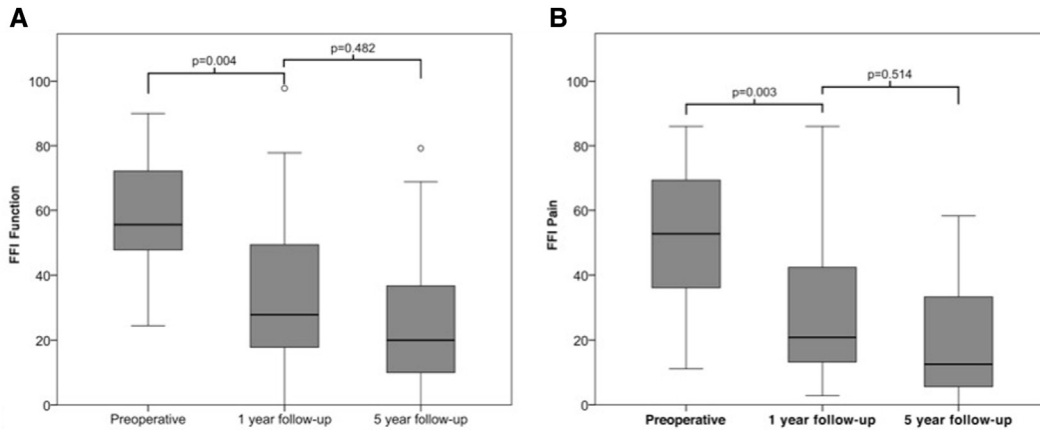


Fig. 6. German version of the Foot Function Index (FFI-D) subscale scores for (A) function and (B) pain at the preoperative and 1- and 5-year follow-up assessments.

additional interventions performed in addition to the repair of an OCL using AMIC. An additional intervention such as calcaneus osteotomy requires a prolonged recovery that is almost double the amount of non-weightbearing. Such long recovery times also make it more difficult for the patient to return to normal movement, mobility, and exercise. Additional interventions will also cause additional scars, making the soft tissue stiffer and slowing down recovery. The outcomes with AMIC will be influenced in a high percentage of cases by the additional interventions required. Some of our patients also presented with subdiagnoses, which can intervene with recovery and thus influence the clinical outcomes. In contrast, Woelfle et al (44) reported that only the age influenced the outcome, with no other factors such as BMI > 25 kg/m², preexisting osteoarthritis, or failed previous surgery affecting the outcome. Elderly patients are also more prone to develop physical limitations such as ipsilateral hip or knee osteoarthritis, which can influence patient satisfaction of OCL repair in the ankle.

Patients' ability to return to normal or even increased sports activity after surgery could also be a factor influencing the different satisfaction rates. Although some patients undergoing osteochondral transplantation of the talus were able to return to sports activity at an equal level compared with preoperatively when performing low- or

mid-level activities, some of the patients changed their sporting activity. Wiewiorski et al (34) reported that the percentage of patients involved in sporting activities before the onset of symptoms had become significantly lower at the time of surgery, which differs from our findings regarding patients return to sporting activity. No significant difference in the weekly sports frequency and the duration of sports activity was found postoperatively. Considering the different sports and the results, high-impact and contact sports seemed to have the most negative outcomes (34,45).

Further studies comparing all-arthroscopic AMIC and open procedures might show additional improvement, allowing patients to return more quickly to normal activity, which could also result from the lesser formation of scar tissue. To date, studies investigating all-arthroscopic AMIC have shown good clinical and radiologic results (30). However, the open procedure should be reserved for lesions reaching a certain size, especially those with subchondral cyst formation.

Even at the final follow-up examination, the number of abnormalities seen on the MRI scans was high. Ninety percent of our patients still had some local edema of the subchondral bone and irregularities of the subchondral lamella. Kubosch et al (39) recently reported a study of MRI after AMIC. They also found persistent bone edema in a high percentage of patients, with a cartilage signal of the reconstructed tissue that showed no significant differences compared with the surrounding cartilage.

The FFI-D subgroups include a variety of questions for patients to evaluate their pain and function during the previous week. Some of

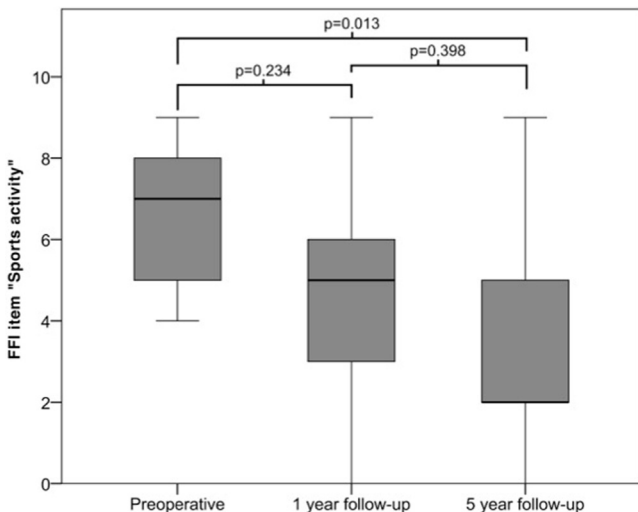


Fig. 7. German version of the Foot Function Index (FFI-D) item for sports activity at the preoperative and 1- and 5-year follow-up assessments.

Table 3

Correlation of age, body mass index, lesion size, and symptom duration with German version of Foot Function Index scores (N = 21 patients)

Variable	FFI Score at t0			FFI Score at t1			FFI Score at t5		
	Pain	Function	Total	Pain	Function	Total	Pain	Function	Total
Age									
Correlation coefficient	0.656	0.542	0.636	0.291	0.250	0.271	0.407	0.393	0.411
p Value	.001	.011	.002	.224	.302	.262	.067	.078	.064
BMI									
Correlation coefficient	0.618	0.506	0.600	0.119	0.106	0.113	0.297	0.339	0.326
p Value	.004	.023	.005	.638	.675	.654	.204	.144	.161
Lesion size									
Correlation coefficient	0.536	0.448	0.520	0.469	0.465	0.472	0.561	0.544	0.568
p Value	.018	.055	.023	.058	.060	.056	.012	.016	.011

Abbreviations: BMI, body mass index; FFI-D, German version of Foot Function Index; t0, preoperatively; t1, 1 year postoperatively; t5, 5 years postoperatively. Bold indicates p values ≤ 0.05.

Table 4

Three-dimensional magnetic resonance observation of cartilage repair tissue score at 5-year follow-up assessment (N = 21 patients)

MOCART Score	Mean Value	SD
Degree of defect repair	13.75	4.60
Integration of border zone	10.25	3.61
Surface of repair tissue	6.25	3.04
Structure of repair tissue	2	2.39
Signal intensity PDW-TSE	6.5	6.38
Signal intensity 3D GRE	7.25	6.45
Subchondral lamina	1	1.95
Subchondral bone	0.75	1.74
Adhesions	5	0
Effusion	1.5	2.24

Abbreviations: 3D GRE, 3-dimensional gradient recalled echo; MOCART, Three-dimensional magnetic resonance observation of cartilage repair tissue; PDW-TSE, proton density-weighted turbo spin echo; SD, standard deviation.

the items are likely to remain unchanged if no osteoarthritis has developed in the ankle joint. These items include night pain and “leaving the house” as major factors for participating in a social life. Importantly, our findings showed that the worst pain decreased significantly after an AMIC procedure and was maintained during the follow-up period.

Although some might believe that using the FFI would result in limitations, especially during the mean study period of 5 years, a study by Naal et al (35) proved the good reliability and validity of the FFI for the self-assessment of pain and disability in German-speaking patients without rheumatoid disease but with foot complaints.

Most of the demographic data analyzed in the present study did not show effects on the FFI-D outcomes. One possible reason might be the small number of patients studied. However, patient questionnaires also include the patient’s expectations, which is likely to differ between those older and younger. It is widely known that smoking has a negative effect on the healing process and wound healing (46,47). Therefore, the low number of 2 patients smoking in our study should generally be considered good but the number of patients was not representative enough to result in an effect.

The BMI is a good factor that relates to the patients’ activity level. Thus, the correlation found preoperatively was not surprising and was in accordance with published data showing that a lower BMI results in better clinical outcomes (48). The duration of symptoms did not seem to influence the clinical outcomes, which could contrast with the idea of pain memory; therefore, a reduced outcome, especially for the FFI-D pain subscale, would be expected.

The location of the lesion also did not have an effect on the outcome. Thus, a medial, lateral, or central location for an OCL is secondary to the lesion size. Previous studies have shown that the size of a lesion influences the outcome, as does the operative procedure chosen (13,49,50). The reason we did not see an influence from the OCL location compared with recent findings from Polat et al (51) might have been related to the small number of lateral lesions (14%) in our patients and the aggressive treatment of adjacent pathologic features such as instability.

In the case of incomplete healing of the bone graft with renewed cyst formation (52), it is possible to repeat the intervention. However, after surgical failure, it is important to reassess the possible mechanical causes such as axial malalignment or instability, which should be addressed in any type of revision surgery.

The limitations of our study were as follows. The final follow-up proportion was 45%. This limited follow-up proportion is a clear limitation of our study. The heterogeneity of the patient sample was also a limitation. More than 50% of the patients had experienced trauma before surgery, some had undergone previous surgery, and >90% had undergone additional surgical procedures concurrent with

AMIC. Finally, the preoperative work status and level of activity was unknown. Consequently, we were unable to report any correlation between the activity level and the outcomes. However, the FFI-D subscale function items 8 and 9 measure the patient’s return to fast walking or running and hobbies and sports activities, respectively.

Although the FFI-D is a good and reliable questionnaire, it includes limitations to a complete and diverse investigation of the clinical outcomes. The FFI-D represents a 1-week retrospective by the patient, which might have been an especially poor or good week for the individual patient. Another bias could also be the period in which the patient should best be able to remember their answers from 5 years earlier to appropriately compare their answers at 3 different time points.

In conclusion, to the best of our knowledge, we have reported for the first time the follow-up data for clinical parameters using the FFI-D during a 5-year study period. Our results showed that the greatest improvement occurs within the first year after the surgery, as shown by the significant decrease in the FFI-D scores. Even after a 5-year period, further improvement could be seen. Different parameters seemed to have an effect on the clinical outcomes, with the lesion size having a major role.

Supplementary Material

Supplementary material associated with this article can be found in the online version at www.jfas.org (<http://dx.doi.org/10.1053/j.jfas.2017.05.002>).

References

- Bruns J, Habermann CR, Petersen JP. Osteochondritis dissecans of the talus—a critical review. *Z Orthop Unfall* 154:199–216, 2016.
- Körner D, Gueorguiev B, Niemyer P, Bangert Y, Zinsler W, Aurich M, Walther M, Becher C, Ateschrang A, Schröter S. Parameters influencing complaints and joint function in patients with osteochondral lesions of the ankle—an investigation based on data from the German Cartilage Registry (KnorpelRegister DGOU). *Arch Orthop Trauma Surg* 137:367–373, 2017.
- König F. Über freie Körper in den Gelenken. [on the presence of loose bodies in joints]. *Deutsche Z Chir* 27:90–109, 1888.
- Berndt AL, Harty M. Transchondral fractures (osteochondritis dissecans) of the talus. *J Bone Joint Surg Am* 41:988–1020, 1959.
- Flick AB, Gould N. Osteochondritis dissecans of the talus (transchondral fractures of the talus): review of the literature and new surgical approach for medial dome lesions. *Foot Ankle* 5:165–185, 1985.
- Pick MP. Familial osteochondritis dissecans. *J Bone Joint Surg Br* 37:142–145, 1955.
- Thordarson DB. Talar body fractures. *Orthop Clin North Am* 32:65–77, 2001.
- Guettler JH, Demetropoulos CK, Yang KH, Jurist KA. Osteochondral defects in the human knee: influence of defect size on cartilage rim stress and load redistribution to surrounding cartilage. *Am J Sports Med* 32:1451–1458, 2004.
- Mubarak SJ, Carroll NC. Familial osteochondritis dissecans of the knee. *Clin Orthop Relat Res* 140:131–136, 1979.
- Chuckpaiwong B, Berkson EM, Theodore GH. Microfracture for osteochondral lesions of the ankle: outcome analysis and outcome predictors of 105 cases. *Arthroscopy* 24:106–112, 2008.
- Grambart ST. Arthroscopic management of osteochondral lesions of the talus. *Clin Podiatr Med Surg* 33:521–530, 2016.
- Murawski CD, Kennedy JG. Operative treatment of osteochondral lesions of the talus. *J Bone Joint Surg Am* 95:1045–1054, 2013.
- Ramponi L, Yasui Y, Murawski CD, Ferkel RD, DiGiovanni CW, Kerkhoffs GM, Calder JD, Takao M, Vannini F, Choi WJ, Lee JW, Stone J, Kennedy JG. Lesion size is a predictor of clinical outcomes after bone marrow stimulation for osteochondral lesions of the talus: a systematic review. *Am J Sports Med* 45:1698–1705, 2017.
- Buda R, Vannini F, Castagnini F, Cavallo M, Ruffilli A, Ramponi L, Pagliuzzi G, Giannini S. Regenerative treatment in osteochondral lesions of the talus: autologous chondrocyte implantation versus one-step bone marrow derived cells transplantation. *Int Orthop* 39:893–900, 2015.
- Behrens P, Ehlers EM, Köchermann KU, Rohwedel J, Russlies M, Plötz W. New therapy procedure for localized cartilage defects. Encouraging results with autologous chondrocyte implantation. *MMW Fortschr Med* 141:49–51, 1999.
- Valderrabano V, Miska M, Leumann A, Wiewiorski M. Reconstruction of osteochondral lesions of the talus with autologous spongiosa grafts and autologous matrix-induced chondrogenesis. *Am J Sports Med* 41:519–527, 2013.
- Dickhut A, Dexheimer V, Martin K, Lauinger R, Heisel C, Richter W. Chondrogenesis of human mesenchymal stem cells by local transforming growth factor-beta delivery in a biphasic resorbable carrier. *Tissue Eng Part A* 16:453–464, 2010.

18. Richter W. Mesenchymal stem cells and cartilage in situ regeneration. *J Intern Med* 266:390–405, 2009.
19. Vakilopoulos KA, Wu Z, Kroese LF, Jeekel J, Kleinrensink GJ, Dodou D, Lam KH, Lange JF. Sutureless closure of colonic defects with tissue adhesives: an in vivo study in the rat. *Am J Surg* 213:151–158, 2016.
20. Abdelkader A. Effect of fibrin glue on corneal lamellar healing and how it correlates to biomechanical properties: biomechanical wavefront analysis and confocal study. *Eye Vis (Lond)* 3:15, 2016.
21. Santos Tde S, Abuna RP, Almeida AL, Beloti MM, Rosa AL. Effect of collagen sponge and fibrin glue on bone repair. *J Appl Oral Sci* 23:623–628, 2015.
22. Angermann P, Riegels-Nielsen P. Fibrin fixation of osteochondral talar fracture. *Acta Orthop Scand* 61:551–553, 1990.
23. Walther M, Altenberger S, Kriegelstein S, Volkering C, Röser A. Reconstruction of focal cartilage defects in the talus with miniarthrotomy and collagen matrix. *Oper Orthop Traumatol* 26:603–610, 2014.
24. Filardo G, Drobnic M, Perdisa F, Kon E, Hribernik M, Marcacci M. Fibrin glue improves osteochondral scaffold fixation: study on the human cadaveric knee exposed to continuous passive motion. *Osteoarthritis Cartilage* 22:557–565, 2014.
25. Wang ZH, Zhang J, Zhang Q, Gao Y, Yan J, Zhao XY, Yang YY, Kong DM, Zhao J, Shi YX, Li XL. Evaluation of bone matrix gelatin/fibrin glue and chitosan/gelatin composite scaffolds for cartilage tissue engineering. *Genet Mol Res* 15, 2016. <http://dx.doi.org/10.4238/gmr.15038431>.
26. Kirilak Y, Pavlos NJ, Willers CR, Han R, Feng H, Xu J, Asokanathan N, Stewart GA, Henry P, Wood D, Zheng MH. Fibrin sealant promotes migration and proliferation of human articular chondrocytes: possible involvement of thrombin and protease-activated receptors. *Int J Mol Med* 17:551–558, 2006.
27. Beck A, Murphy DJ, Carey-Smith R, Wood DJ, Zheng MH. Treatment of articular cartilage defects with microfracture and autologous matrix-induced chondrogenesis leads to extensive subchondral bone cyst formation in a sheep model. *Am J Sports Med* 44:2629–2643, 2016.
28. Zhang C, Cai YZ, Lin XJ. One-step cartilage repair technique as a next generation of cell therapy for cartilage defects: biological characteristics, preclinical application, surgical techniques, and clinical developments. *Arthroscopy* 32:1444–1450, 2016.
29. Usulli FG, de Girolamo L, Grassi M, D'Ambrosi R, Montrasio UA, Boga M. All-arthroscopic autologous matrix-induced chondrogenesis for the treatment of osteochondral lesions of the talus. *Arthrosc Tech* 4:e255–e259, 2015.
30. Usulli FG, D'Ambrosi R, Maccario C, Boga M, de Girolamo L. All-arthroscopic AMIC® (AT-AMIC®) technique with autologous bone graft for talar osteochondral defects: clinical and radiological results. *Knee Surg Sports Traumatol Arthrosc*, 2016 Sept 12. <http://dx.doi.org/10.1007/s00167-016-4318-4> [Epub ahead of print].
31. Kretzschmar M, Bieri O, Miska M, Wiewiorski M, Hainc N, Valderrabano V, Studler U. Characterization of the collagen component of cartilage repair tissue of the talus with quantitative MRI: comparison of T2 relaxation time measurements with a diffusion-weighted double-echo steady-state sequence (dwDESS). *Eur Radiol* 25:980–986, 2015.
32. Wiewiorski M, Miska M, Kretzschmar M, Studler U, Bieri O, Valderrabano V. Delayed gadolinium-enhanced MRI of cartilage of the ankle joint: results after autologous matrix-induced chondrogenesis (AMIC)-aided reconstruction of osteochondral lesions of the talus. *Clin Radiol* 68:1031–1038, 2013.
33. Hoftiel T, Engelhardt M. Osteochondritis dissecans of the talus with hindfoot malalignment—autologous matrix-induced chondrogenesis with lateral calcaneal distraction osteotomy in an internationally successful young female ski racer. *Sportverletz Sportschaden* 29:118–121, 2015.
34. Wiewiorski M, Werner L, Paul J, Anderson AE, Barg A, Valderrabano V. Sports activity after reconstruction of osteochondral lesions of the talus with autologous spongiosa grafts and autologous matrix-induced chondrogenesis. *Am J Sports Med* 44:2651–2658, 2016.
35. Naal FD, Impellizzeri FM, Huber M, Rippstein PF. Cross-cultural adaptation and validation of the Foot Function Index for use in German-speaking patients with foot complaints. *Foot Ankle Int* 29:1222–1228, 2008.
36. Chen H, Chevrier A, Hoemann CD, Sun J, Ouyang W, Buschmann MD. Characterization of subchondral bone repair for marrow-stimulated chondral defects and its relationship to articular cartilage resurfacing. *Am J Sports Med* 39:1731–1740, 2011.
37. Hoemann CD, Hurtig M, Rossomacha E, Sun J, Chevrier A, Shive MS, Buschmann MD. Chitosan-glycerol phosphate/blood implants improve hyaline cartilage repair in ovine microfracture defects. *J Bone Joint Surg Am* 87:2671–2686, 2005.
38. Young KW, Deland JT, Lee KT, Lee YK. Medial approaches to osteochondral lesion of the talus without medial malleolar osteotomy. *Knee Surg Sports Traumatol Arthrosc* 18:634–637, 2010.
39. Kubosch EJ, Erdle B, Izadpanah K, Kubosch D, Uhl M, Südkamp NP, Niemeyer P. Clinical outcome and T2 assessment following autologous matrix-induced chondrogenesis in osteochondral lesions of the talus. *Int Orthop* 40:65–71, 2016.
40. Lee YH, Suzer F, Thermann H. Autologous matrix-induced chondrogenesis in the knee: a review. *Cartilage* 5:145–153, 2014.
41. Leunig M, Tibor LM, Naal FD, Ganz R, Steinwachs MR. Surgical technique: second-generation bone marrow stimulation via surgical dislocation to treat hip cartilage lesions. *Clin Orthop Relat Res* 470:3421–3431, 2012.
42. Cuéllar A, Ruiz-Ibán MÁ, Cuéllar R. The use of all-arthroscopic autologous matrix-induced chondrogenesis for the management of humeral and glenoid chondral defects in the shoulder. *Arthrosc Tech* 5:e223–e227, 2016.
43. Fontana A, de Girolamo L. Sustained 5-year benefit of autologous matrix-induced chondrogenesis for femoral acetabular impingement-induced chondral lesions compared with microfracture treatment. *Bone Joint J* 97B:628–635, 2015.
44. Woelfle JV, Reichel H, Nelitz M. Indications and limitations of osteochondral autologous transplantation in osteochondritis dissecans of the talus. *Knee Surg Sports Traumatol Arthrosc* 21:1925–1930, 2013.
45. Paul J, Sagstetter M, Lämmle L, Spang J, El-Azab H, Imhoff AB, Hinterwimmer S. Sports activity after osteochondral transplantation of the talus. *Am J Sports Med* 40:870–874, 2012.
46. Bettin CC, Gower K, McCormick K, Wan JY, Ishikawa SN, Richardson DR, Murphy GA. Cigarette smoking increases complication rate in forefoot surgery. *Foot Ankle Int* 36:488–493, 2015.
47. Jaiswal PK, Macmull S, Bentley G, Carrington RW, Skinner JA, Briggs TW. Does smoking influence outcome after autologous chondrocyte implantation?: a case-controlled study. *J Bone Joint Surg Br* 91:1575–1578, 2009.
48. Kumagai K, Akamatsu Y, Kobayashi H, Kusayama Y, Koshino T, Saito T. Factors affecting cartilage repair after medial opening-wedge high tibial osteotomy. *Knee Surg Sports Traumatol Arthrosc* 25:779–784, 2016.
49. Lynch TS, Patel RM, Benedick A, Amin NH, Jones MH, Miniaci A. Systematic review of autogenous osteochondral transplant outcomes. *Arthroscopy* 31:746–754, 2015.
50. Deol PP, Cuttica DJ, Smith WB, Berlet GC. Osteochondral lesions of the talus: size, age, and predictors of outcomes. *Foot Ankle Clin* 18:13–34, 2013.
51. Polat G, Erşen A, Erdil ME, Kızılkurt T, Kılıçoğlu Ö, Aşık M. Long-term results of microfracture in the treatment of talus osteochondral lesions. *Knee Surg Sports Traumatol Arthrosc* 24:1299–1303, 2016.
52. Walther M, Becher C, Volkering C. Treatment of chondral and osteochondral defects of the talus by autologous matrix induced chondrogenesis. *Fuß Sprunggelenk* 10:121–129, 2012.