

ORIGINAL ARTICLE

***Aegle Marmelos* Enhances Gastric Mucosal Protection: Relevance for NSAIDS-Induced Gastric Mucosal Injury**

Purnima Singh¹ and Debjani Guha^{2*}

¹Department of Physiology, Rungta College of Dental Science & Research, Bhilai, Chhattisgarh, India and ²S. N. Pradhan Centre for Neurosciences, University of Calcutta, 244 B, A. J. C. Bose Road, Kolkata-700020 India

Abstract: *Objective:* In order to study the gastroprotective effect of *Aegle marmelos* extract (AM), this study was undertaken on aspirin-induced ulcerogenesis in cannulated free-moving rats. *Background:* Most of the non-steroidal anti-inflammatory drugs (NSAIDs) including aspirin (ASP) cause gastric ulcer. The efficacy of several plants for the treatment of gastroduodenal disease is confirmed by clinical research, while basic scientific research helps us to uncover the mechanisms by which these plants exert their therapeutic effects. *Method:* To assess the possible antiulcer effect of AM, lesion index, gastric secretions glycoprotein levels and mucosal histopathology were determined in ASP induced gastric mucosal injury in cannulated free-moving rats. *Results:* Pretreatment with AM significantly prevented the development of gastric mucosal lesion and decreased the gastric toxicity produced by ulcerogen. In addition, ulcerated rats showed depletion of gastric wall mucus, glycoproteins and enhanced gastric acid secretion whereas treatment with AM prevented these ASP induced responses in cannulated free-moving rats. *Histological studies confirmed the results.* *Conclusion:* The present finding suggests that AM promotes ulcer protection by the decrease in ulcer index, gastric secretions and increase in the glycoprotein level, gastric mucin content and maintenance of mucosal epithelium. AM protects the gastric mucosa against ulceration by its antisecretory and cytoprotective property.

Keywords: Antiulcer activity, aspirin, *Aegle marmelos* extract, histopathology, mucus content.

Introduction

Nonsteroidal anti-inflammatory drugs (NSAIDs) represent a category of medications that require continuous re-evaluation of their clinical benefits versus risks. NSAIDs (aspirin, indomethacin, etc) are among the most frequently used drugs in the world because of their strong analgesic, anti-inflammatory, and antipyretic properties [1]. Aspirin (ASP), one of the most widely used NSAIDs, damages gastrointestinal mucosa by irritant action, causing alterations in mucosal permeability and/or suppression of prostaglandin synthesis [2]. Aspirin induced ulcer has been used as a model for the evaluation of antiulcerogenic agent [3].

Clinical research has already confirmed the efficacy of several plants for the treatment of gastroduodenal disease, while basic scientific research has uncovered the mechanisms by which some plants exert their therapeutic effects [4]. *Aegle marmelos* (L) Correa (AM), commonly known as bael, is one such plant. It belongs to the family Rutaceae. It is indigenous to India and is grown throughout the subcontinent as well as in Myanmar, Pakistan and Bangladesh.

Different parts of the plant (leaves and ripe fruits) have been used in the treatment of diarrheas, dysenteries and diabetes mellitus [5-6]. The root bark extract of this plant has been reported to be beneficial to cure intermittent fever, mental diseases, pericarditis and angina pectoris [7]. *Aegle marmelos* leaf extracts also have been reported to possess antibacterial activity [8]. *Aegle marmelos* fruit has been reported to possess antioxidant activity [9]. Pharmacological studies show presence of flavonoids, coumarins, alkaloids, lignan glucosides, triterpenoids, sterols, tannins, phlobatannins, flavonoid glycosides, carbohydrates, anthraquinones, lactones etc. [10] in *Aegle marmelos*, most of which have antioxidant and antiulcer activity. The common usage, wide acceptability in human beings, and diverse medicinal properties attributed to bael fruit stimulated us to investigate the effect of pretreatment with aqueous extract of ripe fruit pulp of *Aegle marmelos* (AM) on acid secretion and mucus content in stomach in ASP-induced ulcerogenesis in cannulated rats, which might be useful for the treatment of peptic ulcer.

Material and Methods

Preparation of AM ripe fruit extract: The ripe fruit of *Aegle marmelos* was purchased from the local market. The pulp was taken out from ripe fruit of AM after identification and authentication by the Botanical Survey of India, Howrah (No. CNH/I-I/239/2008/Tech.II/278). It was then strained through wire-mesh, sun dried and powdered in an electric grinder. The crushed powder that was obtained was soaked in double distilled water for 24 hours. The extract obtained was filtered through Whatman filter paper and vacuum dried at 40-50°C to get a dry powder and it was stored at -4°C for further use [11].

Drugs and chemicals: Hemoglobin was purchased from Sigma, USA. Trichloroacetic acid (TCA) was obtained from Ranbaxy Fine Chemicals Ltd., India. All other chemicals were obtained from Merck, India.

Animal use and maintenance: Holtzman strain adult albino rats (of either sex) weighing 200-250 g were used throughout the experiment. They were maintained under standard laboratory conditions (22°-28°C, 60-70% relative humidity, 12 hour light/dark cycle) with standard pellet diet (M/s. Hindustan Lever Ltd., India) and water *ad libitum*. Food intake (g/day/rat) and body weights of the rats were recorded everyday and maintained throughout the experimental period. The experiments were carried out as per the regulation of the Institutional Animal Ethical Committee.

Experimental design and animal grouping: 30 rats were taken for the experiment. Before the start of the treatment schedule and experiment, the rats were divided into 5 different groups having 6 animals in each group.

Group 1: Control group: Rats were treated with double distilled water (2 ml/Kg body weight), once daily for 14 consecutive days orally by using an orogastric cannula between 10:30 am-11:30 am.

Group 2: AM group: Rats were treated with aqueous extract of ripe fruit pulp of *Aegle marmelos* at a dose of 250 mg/Kg (standardized in laboratory), once daily for 14 consecutive days orally by using an orogastric cannula between 10:30 am-11:30 am.

Group 3: ASP group: Aspirin induced ulcerated rats (acute model) which were treated with double distilled water (2 ml/Kg body weight), once daily for 14 consecutive days orally by using an orogastric cannula before giving aspirin.

Group 4: AM + ASP group: Aspirin induced ulcerated rats pretreated with *Aegle marmelos* ripe fruit extracts.

Group 5: RAN + ASP group: Ranitidine (Glaxo India Ltd.) was used as reference drug. Animals were treated with ranitidine at a dose of 10 mg/Kg body weight [12] for 14 consecutive days before giving aspirin.

Preparation of aspirin induced ulcer model: Rats were fasted for overnight and only water was allowed *ad libitum*. A single dose of aspirin (500 mg/Kg body weight) was given [13] orally using orogastric cannula. After 4 hours, rats were sacrificed by an overdose of sodium pentothal following overnight fasting. Stomach was cut along the greater curvature and dissected longitudinally, stretched on paraffin bed, washed with normal saline and distribution of bleeding spots were counted following the method of Szabo [14].

Gastric cannulation for collection of gastric juice from conscious rats: All animals were implanted with stainless steel gastric cannula under anesthesia for collecting gastric juice from free-moving conscious rats. Gastric secretion in these rats was studied following overnight fasting. The animals were placed in plastic restraining cages for collection of gastric juice for 1 hour period [15].

Postoperative care: Following surgery all the animals were carefully maintained with all the necessary precautions and aseptic measures to recover from surgical stress. Routine antibiotic injection (i. m.) of Benzyl Penicillin (10,000 IU) was given in all the animals for three consecutive days after surgery [16]. Particular care was taken for feeding until the animals recovered from surgical stress. For the first two days, animals were given intraperitoneal injection of dextrose-saline until the animals became capable of taking either liquid milk or standard diet.

Collection of Gastric Secretion: After post-operative period of 7 days, the animals were placed in restraining cages (No. 51339, Stoelting Co, Chicago) for gastric juice collection from conscious rats. Prior to juice collection, stomach was lavaged with 0.9% saline until the effluent was clear of any food particles. Gastric juice was collected for 1 hour in the morning under fasting condition through a sialistic tube firmly attached to the gastric cannula.

Biochemical Analysis of Gastric Juice

1. Gastric juice was collected and volume of gastric juice (ml) and pH was determined using digital pH meter.
2. **Acidity:** Acidity of gastric juice was measured titrimetrically with 0.01 (N) NaOH solutions by using 0.5% Topfer's reagent and 1% alcoholic phenolphthalein as an indicator [17].
3. **Estimation of mucus content:** Dissolved mucosubstances were estimated by determining the total carbohydrate (sum of Hexose, Hexosamine, Sialic acid and Fucose) and protein in a 5% ethanolic precipitate of gastric juice [18].

The total carbohydrate and total protein ratio (TC:TP) has been accepted as a reliable index of mucus secretion and mucosal resistance [11, 19]. 0.5 ml gastric juice together with 5ml absolute alcohol was centrifuged for 20 mins. The precipitate was dissolved in 0.5 ml of 0.01 (N) NaOH. 0.1 ml from this solution was taken for the estimation of Total Protein [20] and rest was mixed with 2 ml of 6 (N) HCl and boiled for 2 hours and after cooling, 1 drop of phenolphthalein was added and titrated against 10 (N) NaOH. Pink colour which was obtained disappeared after titration with 6 (N) HCl, and then the total volume was made up to 4 ml with distilled water. From this, 1 ml each was taken for the estimation of Total Hexose [21], Hexosamine [22], Fucose [23] and Sialic acid [24].

Ulcer scoring: After termination of the experiment, the animals were sacrificed by an overdose of sodium pentothal following overnight fasting. The stomach was cut opened along the greater curvature, and ulcer was indexed accordingly [11, 14]. After the collection of the tissues, those were rinsed in normal saline and spread over paraffin tray and numbers of bleeding spots were examined using a magnifying glass. The length of bleeding spots (in mm) was also measured using a scale and scoring of ulcer index was done by the following grade for a single animal.

- 0 = normal, i.e., no pathology
- 1 = small ulcer (bleeding spot with 1-2 mm in length)
- 2 = medium ulcer (bleeding spot with 3-4 mm in length)
- 4 = large ulcer (bleeding spot with 5-6 mm in length)
- 8 = larger ulcer (bleeding spot with >6 mm in length)

The sum of the total severity scores in each group of rats divided by the number of rats was expressed as the mean ulcer index (MUI).

Determination of Percentage protection (%P) by AM: Percentage protection (%P) by aqueous extract of ripe fruit pulp of *Aegle marmelos* (AM) against peptic ulceration was determined [11, 25] using the following formula:

$$\% P = [(MUI_{ulcer} - MUI_{extract}) / MUI_{ulcer}] * 100.$$

Histomorphological studies: To observe significant structural and functional correlations, morphological data were required which was obtained by histological studies. After termination of experiment, all animals were sacrificed by an overdose of sodium pentothal following overnight fasting and immediately stomach of each animal was dissected out, washed with normal saline and stored in 4% formalin solution for 24 hours. The tissues were then prepared for paraffin sections which were cut at 4-5 μ m for stomach. Stomach sections were examined using haematoxyline and eosin for routine morphological study [26] and to assess histomorphological changes due to ulcerogenesis.

Statistical Analysis: All the data were expressed as MEAN \pm SEM. The One-Way Analysis of Variance (ANOVA) followed by multiple comparison 't' test was used for statistical analysis. Difference below the probability level 0.05 was considered statistically significant.

Results

There was no mortality during the experimental period and food intake was similar in all the groups. The following results were obtained:

Effect of AM on Ulcer index: Animals of ASP group showed extensive gastric lesions that were confined to the glandular portion of the stomach. In contrast, treatment with aqueous extract of ripe fruit pulp of AM orally at a dose of 250 mg/Kg body weight daily, for 14 consecutive days protected the gastric mucosa from ulcer induced by aspirin (NSAIDs) (Table 1). The extract treatment, significantly ($p < 0.001$) lowered the ulcer index in stomach (2.67 ± 0.67) of AM + ASP group of rats and thereby rendered protection to the stomach from ulcer by 93.09%. Protection rendered by ranitidine was 89.65% against ulcer induced by aspirin in RAN + ASP group of rats. No significant gastric mucosal lesions were observed in control and AM group of rats.

Parameters	Group 1 (Control)	Group 2 (AM)	Group 3 (ASP)	Group 4 (AM+ASP)	Group 5 (RAN+ASP)
Mean ulcer index	No lesion	No lesion	$38.67 \pm 2.74^*$	$2.67 \pm 0.67^\#$	$4 \pm 0.58^\#$
% P	100	100	-	93.09	89.65
Values are Mean \pm SEM from 6 animals in each group; * $p < 0.001$ when compared to Control group; $^\#$ $p < 0.001$ when compared to ASP group.					

Effect of AM on gastric juice (Volume, pH & Total acid output): Pretreatment with AM alone for 14 days reduced the volume of gastric juice (significant change, $p < 0.05$ as compared to control), acid output and increased the pH of gastric juice as compared to control (but the latter changes were not statistically significant). Aspirin produced gastric hyperacidity as evidenced by increased acid content of gastric juice and decreased pH of gastric juice but volume of gastric juice was reduced significantly ($p < 0.01$ as compared to control). However, pretreatment with AM for 14 days to the AM + ASP group showed significant antiulcer effect and prevented gastric hyperacidity by reducing the volume of gastric juice and acid output, and a significant increase in pH (Table 2). Ranitidine also showed antiulcer activity by reducing gastric acid output.

Parameters	Group 1 (Control)	Group 2 (AM)	Group 3 (ASP)	Group 4 (AM+ASP)	Group 5 (RAN+ASP)
pH	2.13 ± 0.04	2.3 ± 0.10	$1.65 \pm 0.06^*$	$2.05 \pm 0.08^\#\#$	$2.10 \pm 0.10^\#$
Volume of gastric juice (ml)	1.33 ± 0.04	$1.23 \pm 0.04^{***}$	$1.17 \pm 0.02^{**}$	1.12 ± 0.03	1.16 ± 0.03
Total acid output (mEq/l)	37.15 ± 1.69	35.63 ± 1.49	$46.00 \pm 2.81^{**}$	$35.62 \pm 2.54^\#\#$	$36.0 \pm 2.02^\#\#$
Values are Mean \pm SEM from 6 animals in each group; * $p < 0.001$, ** $p < 0.01$, *** $p < 0.05$ as compared to Control group; $^\#$ $p < 0.001$, $^\#\#$ $p < 0.01$ as compared to ASP group.					

Effect of AM on mucus content of gastric juice: Analysis of gastric secretion after administration of aspirin in the rats showed significant reduction in mucus content as evidenced by decreased TC:TP ratio ($p < 0.001$) as compared to control) and decreased level of individual mucopolysaccharides like Hexose, Hexosamine, Fucose and Sialic acid. Pretreatment with aqueous extract of ripe fruit pulp of *Aegle marmelos* at a dose of 250 mg/Kg body weight, for 14 consecutive days *per se* increased the mucus content of gastric juice as compared to the control group but the increase was not statistically significantly. Pretreatment with AM to the AM + ASP group significantly increased the TC:TP ratio ($p < 0.001$) and enhanced the glycoprotein level (Hexose, Hexosamine, Fucose, Sialic acid) and decreased the protein level as compared to the ASP group (Table 3). Mucus production in RAN + ASP group was also increased as compared to ASP group.

Parameters	Group 1 (Control)	Group 2 (AM)	Group 3 (ASP)	Group 4 (AM+ASP)	Group 5 (RAN+ASP)
Hexose ($\mu\text{g/ml}$)	326.18 \pm 17.21	343.01 \pm 6.17	199.49 \pm 10.04*	295.38 \pm 14.9 [#]	300.82 \pm 8.97 [#]
Hexosamine ($\mu\text{g/ml}$)	181.54 \pm 14.08	185.46 \pm 10.34	138.89 \pm 10.14***	172.73 \pm 7.8 ^{###}	174.00 \pm 11.65 ^{###}
Fucose ($\mu\text{g/ml}$)	125.12 \pm 11.38	126.66 \pm 11.01	59.39 \pm 8.85*	97.73 \pm 10.67 ^{###}	106.67 \pm 5.96 [#]
Sialic acid ($\mu\text{g/ml}$)	85.88 \pm 6.05	89.83 \pm 3.19	40.05 \pm 2.84*	62.84 \pm 6.15 [#]	72.67 \pm 5.23 [#]
Total carbohydrate ($\mu\text{g/ml}$)	727.05 \pm 7.34	744.96 \pm 13.06	437.83 \pm 9.10*	625.40 \pm 26.54 [#]	654.98 \pm 23.64 [#]
Total protein ($\mu\text{g/ml}$)	347.67 \pm 7.91	338.89 \pm 4.17	442.34 \pm 16.33**	343.78 \pm 10.72 ^{##}	425.64 \pm 14.97
TC:TP	2.09 \pm 0.03	2.19 \pm 0.02	1.00 \pm 0.05*	1.82 \pm 0.09 [#]	1.54 \pm 0.01 [#]
Values are Mean \pm SEM from 6 animals in each group; * $p < 0.001$, ** $p < 0.01$, *** $p < 0.05$ as compared to Control group; # $p < 0.001$, ## $p < 0.01$, ### $p < 0.05$ as compared to ASP group.					

Histomorphological evaluation of Stomach: The general gastric morphology was maintained in control and AM treated rats and the presence of normal mucosa in the upper region of gastric section was observed (Figures 1A & 1B). The histological picture of AM alone treated rats showed normal cytoarchitecture of gastric mucosa with no pathological changes. Aspirin induced gastric damage and gastric lesions were mainly observed in the glandular portion of the stomach. Disruption of the epithelium could be seen after treatment with the chemical agent (Figure 1C). There was a reduction of surface mucus coat of the gastric mucosa.

The mucous cells appeared moderately disorganized. Protection against these histopathological changes was observed by apparent epithelialization, glandular organization, and maintenance of muscularis mucosa in AM + ASP group of rats. The stomachs of rats showed a significant reduction in the severity of the lesions and the continuity of mucus lining was maintained (Figure 1D).

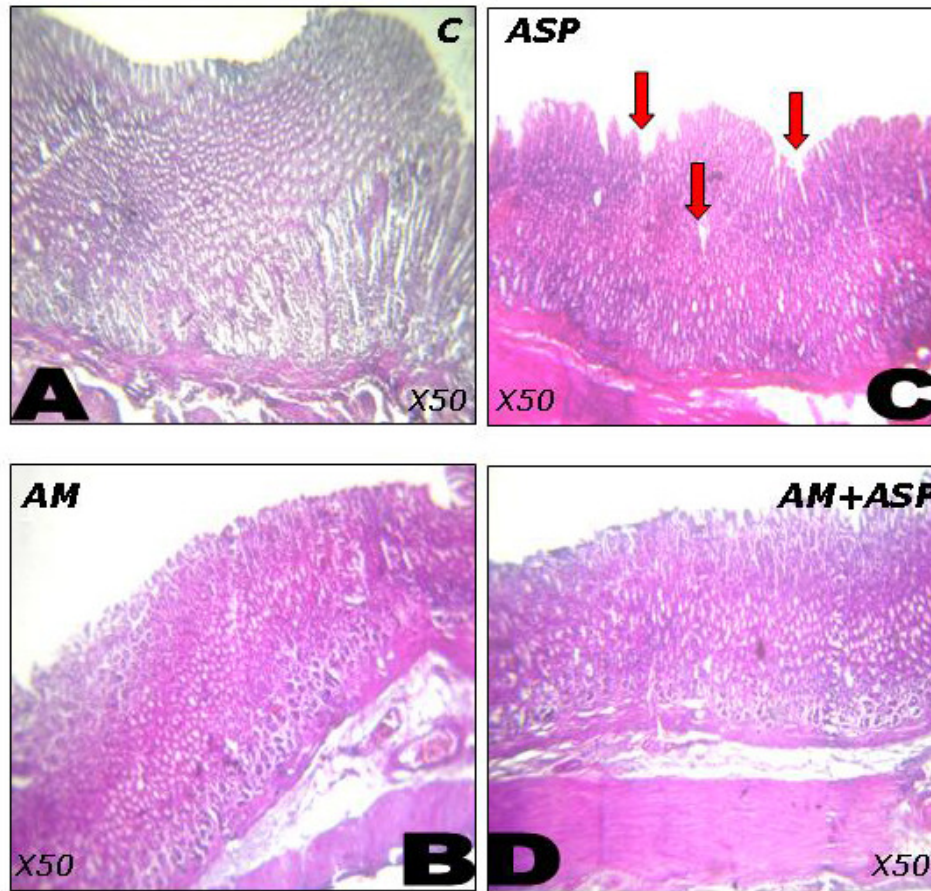


Fig-1: Paraffin sections of gastric mucosa of rat stained by HE: (A) Control. The gross histomorphological appearance of the upper gastrointestinal tract is intact. (B) AM. The continuity of the gastric mucosal epithelium is maintained. (C) ASP. Gastric lesions are mainly observed in the glandular portion of the stomach. The continuity of mucus lining is disrupted. (D) AM + ASP. The continuity of mucus lining is maintained.

Discussion

The present results suggested that pretreatment with AM markedly ameliorated the ulcer index, histological and biochemical changes of ASP induced gastric ulceration in rats. Synthetic non-steroidal anti-inflammatory drugs, such as aspirin, cause mucosal damage by interfering with prostaglandin synthesis, increasing acid secretion and back diffusion of H^+ ions [27].

The net imbalance in gastric mucosal offensive and defensive factors is thought to be the detrimental factor in ulcerogenesis[28]. Administration of aspirin produces severe gastric hemorrhagic erosions and significantly decreases the volume of gastric juice because of so called back diffusion of HCl through the broken barrier, inhibition of mucosal blood flow and acute inflammation [29-30] that is consistent with the present report. The present study shows that the aqueous extract of *Aegle marmelos* possesses gastroprotective activity as evidenced by its significant inhibition of the development of ulcers induced by aspirin (chemical agent). AM demonstrated significant antiulcer activity by decreasing the ulcer lesions, volume of gastric juice, acid output and an increase in pH. The protection in stomach from ulceration was found to be about 93.09%, thus revealing the protective role of ripe fruit extract of AM against gastric mucosal lesions in aspirin induced ulceration in rats. Treatment with AM results in a decline in volume of gastric juice secretion, gastric acid secretion and an increase of pH within the gastric luminal milieu indicating its antisecretory effect [31].

Early studies in frog [32], rat [33] and mouse [34] show that gastric mucosa is responsible for secretion of HCl. This HCl aggravates mucosal lesions by activating pepsinogen to pepsin which increases the size of lesions by proteolytic action of pepsin leading to back diffusion of acid. Acid back diffusion also releases histamine causing inflammation and additional acid output to cause more damage [35]. However, mucosal injury by luminal hydrogen ions (H^+) occurs when integrity of the mucosa is disrupted by other different aggressive factors. This is in coherence with our study which shows that administration of aspirin increases the acid output in gastric secretion leading to gastric mucosal lesion. Therefore, acid suppression is regarded as the main target in most pharmacological treatments designed to prevent or heal gastric ulcers [36]. The back-diffusing hydrogen ion is counter-balanced by the deposition of *de novo* synthesized and secreted gastric mucin (mucus glycoprotein) within the so-called mucus-buffer layer covering the surface epithelium [37-39]. The ability of this layer to effectively retard the back-diffusion of hydrogen ion depends on the content of the major components of mucus, such as mucin, highly hydrophobic mucin-associated fatty acids, and lipids as well as non-mucin glycoproteins, prostaglandins, and peptide growth factors [37-38, 40]. This viscoelastic mucus layer retains bicarbonate and non- bicarbonate buffers elaborated by the mucosa and ad hoc released into the mucus layer [39]. It has been demonstrated that ulcerogenic properties of NSAIDs are related to their inhibition of prostaglandin synthesis mediated through the COX-1 enzymatic pathway as well as to their direct inhibitory impact on production of mucus and its major mucin component [38-39, 41]. Our results show that there is increased acid secretion and decreased pH following treatment with aspirin, which may be possibly due to inhibition of prostaglandin synthesis mediated through COX-1 as described above, leading to ulceration. Pretreatment with AM maintained the normal pH of the gastric internal milieu by decreasing the production of acid. This may also be due to trapping of bicarbonate ions by the mucosal layer.

Mucus secreted by the mucous neck cells is therefore a crucial factor in the protection of gastric mucosa from the gastric lesions and has been regarded as an important factor in the gastric mucus barrier. It constitutes the first line of defense against ulcerogenesis [42] and helps to retard diffusion of hydrogen ions and retain bicarbonate close to the mucosal surface. The increase in TC:TP ratio is the direct reflection of mucin activity, which is indicated by the enhanced level of individual mucopolysaccharides like Hexose, Hexosamine, Fucose and Sialic acid [43]. The increase in protein content of the gastric juice resulting in a decrease in the TC:TP ratio indicates damage to the gastric mucosa by aspirin, as a result of which plasma proteins may leak into the gastric juice [44]. Decrease in protein content in the gastric juice also signifies decrease in the leakage from the mucosal cells indicating mucosal resistance [45]. Our current study demonstrates that AM has a profound stimulatory impact on the content of mucus and mucin as evidenced by increased TC:TP ratio in gastric juice aspirated both in basal conditions and during stimulation with aspirin that mimics the natural chemical-induced gastric secretion scenario. The demonstrated increase in gastric mucin content in gastric juice by *Aegle marmelos* indicates that this phenomenon is not merely resulting from diminished volume of gastric secretion. The sialic acid content observed to increase after prophylactic treatment with *Aegle marmelos* suggests a qualitative change in the mucus. The mucinous fraction consists of polymers of glycoprotein molecules which by their high molecular weight impart high viscosity to gastric mucus. The increased hexose and sialic acid in the gastric mucosa after *Aegle marmelos* treatment may contribute towards its antiulcerogenic and cytoprotective effect by increasing the viscosity of the gastric mucus [27]. We have earlier reported that AM prevented cerebellar lesion induced ulceration by its cytoprotective property [11].

Administration of AM results in a decline of gastric acid, thus in a lesser degree of peptic erosion of the mucus gel layer. In addition, augmented production of the gastric mucin within the mucosal epithelium may further enhance the thickness of the mucus layer and increase the content of mucin within gastric juice. This not only helps to augment the protective quality of the mucus-buffer barrier but also improves viscosity and the lubricating potential of gastric secretion and can accelerate propulsion of the solid food bolus as well as protect the surface epithelium from mechanical injury during grinding of solid food by vigorous antral contractions. The significant reduction in basal gastric secretion and ulcer formation by AM in aspirin induced ulcerated rats suggests that the cytoprotective mechanism of the extract on gastric mucosa may involve direct reduction of gastric secretion. AM significantly reduced gastric secretion and acidity, which might be due to the enhancement of mucus by AM. This antiulcer activity of AM might be attributed to the presence of biological compounds such as triterpenoids, glycosides, saponins, tannins, β -sitosterol and amino acids [46] in the extract. Triterpenoids and glycosides have been shown to inhibit gastric acid secretion and enhance gastric mucus content against several experimental ulcer models [47]. Histomorphological study of stomach tissue of aspirin treated rats proves that disruption of this pre-epithelial barrier may be a key mechanism of gastric mucosal injury.

Many agents are known to either enhance or damage the gastric mucosal barrier. Alcohol, aspirin, and bile salts have been shown to inhibit components of the mucosal barrier. Conversely, prostaglandins, chemical irritants, vagal stimulation, and fundic distension induce goblet cells to increase mucus secretion and, thereby, increase the effectiveness of this barrier [48]. Histomorphological evaluation of stomach shows that the general gastric morphology was maintained in control and AM treated rats and the presence of normal mucosa in the upper region of gastric section was observed (Figures 1A & 1B). The histological picture of AM alone treated rats showed normal cytoarchitecture of gastric mucosa with no pathological changes. Aspirin induced gastric damage and gastric lesions were mainly observed in the glandular portion of the stomach. Disruption of the epithelium could be seen after treatment with the chemical agent (Figure 1C). There was a reduction of surface mucous coat of the gastric mucosa. The mucus cells appeared moderately disorganized. Protection against these histopathological changes was observed by apparent epithelialization, glandular organization, and maintenance of muscularis mucosa in AM + ASP group of rats. The stomachs of rats showed a significant reduction in the severity of the lesions and the continuity of mucus lining was maintained (Figure 1D). These findings confirm the antiulcer and cytoprotective nature of *Aegle marmelos* [49].

There is substantial evidence that the suppression of gastric PG is the fundamental mechanism responsible for the gastrointestinal toxicity of NSAIDs [2]. PG inhibition leads to a decrease in epithelial mucus, secretion of bicarbonate, mucosal blood flow, epithelial proliferation, and mucosal resistance to injury [50]. The observations of the present study also suggests that aspirin produces gastric lesion by increasing acid secretion by parietal cells and also decreases the mucus secretion and causes denudation of mucus, possibly mediated through inhibition of prostaglandin synthesis. The protection rendered by AM against aspirin induced ulceration may also be possibly mediated by stimulation of prostaglandin synthesis by any one of the many active compounds present in it. Ranitidine used as a standard antiulcer drug in the present study showed antiulcer activity by decreasing gastric acid secretion. Ranitidine, a potent H₂-receptor antagonist inhibits acid production by reversibly competing with histamine for binding to H₂ receptors on the basolateral membrane of parietal cells [51].

Our ultimate goal in therapy of acid-related disorders is to reach equilibrium among the luminal concentration of hydrogen ion, the corresponding proteolytic activity of pepsins determined by activity of hydrogen ion, and the protective mechanisms represented by the integral components of the mucus-buffer layer. This beneficial impact of *Aegle marmelos* administration on the concentration of mucin in gastric secretion seems to represent a new phenomenon in the pharmacodynamics of herbal treatment in humans. This may translate into tangible clinical benefits, as a higher concentration of mucin in gastric juice may profoundly benefit the gastric mucosal barrier. These data may further the understanding of pathophysiology and therapy of acid-related disorders and provide a rationale for further exploration of this phenomenon especially in patients receiving nonsteroidal anti-inflammatory drugs

that are well known for inhibition of gastric mucin production with a propensity to the development of both acute and chronic mucosal injury and complications [52]. In conclusion, the unique pharmacological property of *Aegle marmelos*, significantly augmenting production of gastric mucus and mucin, and enhancing protective properties of the mucous barrier, may translate to additional clinical benefits in protecting the upper alimentary tract mucosa during the acid-related challenge.

References

1. Simmons DL, Botting RM, Hla T. Cyclooxygenase isoenzymes: the biology of prostaglandin synthesis and inhibition. *Pharmacol Rev* 2004; 56(3): 387-437.
2. Scheon RT, Vender RJ. Mechanisms of NSAID-induced gastric damage. *Am J Med* 1989; 86: 449-458.
3. Goel RK, Chakrabarti A, Sanyal AK. The effect of biological variables on the antiulcerogenic effect of vegetable plantain. *Planta Medica* 1985; 51: 85-88.
4. Kanner J, Lapidot T. The stomach as a bioreactor dietary lipid peroxidation in the gastric fluid and the effects of plant derived antioxidants. *Free Radical Biology and Med* 2001; 31(11): 1388-1395.
5. Saheb Dass G. *Aegle marmelos*. In: Trivedi KP, ed. Dhanvantari. Dhanvantari Karyalaya: Aligarh, India, 1969; 204.
6. Chopra RN, Chopra IC, Handa KL, Kapur LD. In: Chopra RN, Dhar VN & Sons, ed. *Indigenous Drugs of India*. Calcutta, India, 1958; 267-270.
7. Nadkarni AK. In: Nadkarni KM, ed. Indian Materia Medica. *Popular Prakashan Pvt Ltd: Bombay*, 2000; 45-49: 779-80.
8. Balakrishnan N, Bhaskar VH, Jayakar B, Sangameswaran B. Antibacterial activity of *Mimosa pudica*, *Aegle marmelos* and *Sida cordifolia* (Short communication). *Pharmacognosy Magazine* 2006; 2(7): 198-199.
9. Kamalakkannan N, Prince S. Effect of *Aegle marmelos* Correa (Fruit) extract on tissue antioxidants in streptozotocin diabetic rats. *Indian J Exp Biol* 2003; 41(11): 1285-1288.
10. Ali MS, Pervez MK. Marmenol: a 7-geranyloxy coumarin from the leaves of *Aegle marmelos* Corr. *Nat Prod Res* 2004; 18(2): 141-146.
11. Singh P, Sarkar S, Guha D. *Aegle marmelos*: possible role of antioxidants on aspirin induced peptic ulcer. *Ind J Physiol and Allied Sc* 2008; 62(1): 6-15.
12. Kath RK, Gupta RK. Antioxidant activity of hydro-alcoholic leaf extract of *Ocimum sanctum* in animal models of peptic ulcer. *Indian J Physiol Pharmacol* 2006; 50(4): 391-396.
13. Bose M, Motghare VM, Dakhale GN, Turankar AV. Antiulcer activity of levromakalim and nicorandil in albino rats: A comparative study. *Pol J Pharmacol* 2003; 55(1): 91-95.
14. Szabo S, Trier JS, Brown A, Schnoor J, Howan HD, Bradford JC. A quantitative method for assessing the extent of experimental gastric erosions and ulcer. *J Pharmacol Method* 1985; 13(1): 59-66.
15. Guha D, Dutta SN, Pradhan SN. Conditioning of gastric secretion by epinephrine in rats. *Proc Soc Exp Biol Med* 1974; 147: 817-819.
16. Guha D, Purkayastha S, Chakrabarty P. Vestibulo-cerebellar participation in protection of duodenal mucosa: Possible role of neurotransmitters. *Indian J Exp Biol* 2002; 40(5): 541-545.
17. Guha D, Maiti AK. Gastric hypersecretion by intranodular vasopressin and role of vestibulo-cerebellum. *Ind J Physiol and Allied Sc* 1990; 44(3): 124-134.

18. Sanyal AK, Mitra PK, Goel RK. A modified method to estimate dissolved substances in gastric juice. *Indian J Exp Biol* 1983; 21(2): 78-80.
19. Sanyal AK, Pandey BL, Goel RK. The effect of a traditional preparation of copper, tamrabhasma, on experimental ulcers and gastric secretion. *J Ethnopharmacol* 1982; 5(1): 79-89.
20. Lowry OH, Rosebrough NJ, Farr AL, Randall RJ. Protein measurement with the folin phenol reagent. *J Biol Chem* 1951; 193(1): 265-275.
21. Elson LA, Morgan WTT. A colorimetric method for the determination of glucosamine and chondrosamine. *Biochem J* 1953; 27(6): 1824-1828.
22. Dische Z, Borenfreund E. A spectrophotometric method for the micro determination of hexosamine. *J Biol Chem* 1950; 184(2): 517-522.
23. Dische Z, Shettes LB. A specific colour reaction of methyl pentoses and spectrophotometric micro-methods for their determination. *J Biol Chem* 1948; 175: 593-603.
24. Warren L. The thiobarbituric acid assay of sialic acid. *J Biol Chem* 1959; 234(8): 1971-1975.
25. Njar VCO, Adesanwo JK, Raji. Methyl Angolensate: The antiulcer agent of the stem barks of *Etandrophragma angolense*. *Plant Medica* 1995; 61: 91-92.
26. Bancroft JD, Stevens A, Turner DR. The haematoxyline and eosin. In: Theory and Practice of Histological Techniques. *Churchill Livingstone, New York*, 1996; 4: 99-112.
27. Rao Ch V, Sairam K, Goel RK. Experimental evaluation of *Bacopa monniera* in rat gastric ulceration and secretion. *Indian J Physiol Pharmacol* 2000; 44(4): 435-441.
28. Goel RK, Bhattacharya SK. Gastroduodenal mucosal defense and mucosal protective agents. *Indian J Exp Biol* 1991; 29(8): 701-714.
29. Akhtar MS, Munir M. Evaluation of antiulcerogenic effect of *Solanum nigrum*, *Brassica oleracea* and *Ocimum basilicum* in rats. *J Ethnopharmacol* 1989; 27(1-2): 163-176.
30. Tanaka H, Kosaka N, Tomaru A, Shuto K, Ogihara T, Sato N. Augmentation of the gastric mucosal defense mechanism induced by KW-5805 a novel antiulcer agent. *Scand J Gastroenterol* 1989; 162(Suppl): 170-173.
31. Amagase K, Ikeda K, Okabe S. Antisecretory and ulcer healing effect of S-0509, a novel CCK-B/gastrin receptor antagonist in rats. *Dig Dis Sci* 1999; 44(5): 879-888.
32. Bannister WH. The relation between acid secretion and oxygen uptake by gastric mucosa of the frog. *J Physiol* 1965; 177(3): 429-439.
33. Main IHM, Pearce JB. A rat isolated gastric mucosal preparation for studying the pharmacology of gastric secretion and the synthesis or release of endogenous substances. *J Pharmacol Methods* 1978; 1: 27-38.
34. Davenport HW, Chavre VJ. Acid secretion and oxygen consumption by mouse stomach *in vitro*. *Am J Physiol* 1953; 172 (2): 203-208.
35. Hoogerwerf WA, Pasricha PJ. Pharmacotherapy of gastric acidity, peptic ulcers, and gastroesophageal reflux disease. In: Hardman JG, Limberd LE, ed. Goodman and Gillman's The Pharmacological Basis of Therapeutics. *McGraw Hill & Co: USA*, 2001; 10: 1005-19.
36. Lehmann F, Hildebrand P, Beglinger C. New molecular targets for treatment of peptic ulcer disease. *Drugs* 2003; 63(17): 1785-1797.
37. Sarosiek J, Marshall BJ, Peura DA, Hoffman S, Feng T, McCallum RW. Gastroduodenal mucus gel thickness in patients with *Helicobacter pylori*: a method for assessment of biopsy specimens. *Am J Gastroenterol* 1991; 86(6): 729-734.
38. Slomiany BL, Sarosiek J, Slomiany A. Gastric mucus and the mucosal barrier. *Dig Dis* 1987; 5(3): 125-145.

39. Allen A. Structure and function of gastrointestinal mucus. In: Johnson LR, ed. *Physiology of Gastrointestinal Tract*. Raven Press: New York, 1981; 1: 617–39.
40. Bilski J, Sarosiek J, Murty VLN, Aono M, Moriga M, Slomiany A, et al. Enhancement of the lipid content and physical properties of gastric mucus by geranylgeranylacetone. *Biochem Pharmacol* 1987; 36(23): 4059–4065.
41. Sarosiek J, Marcinkiewicz M, Parolisi S, Peura DA. Prostaglandin E₂ content in residual gastric juice reflects endoscopic damage to the gastric mucosa after naproxen sodium administration. *Am J Gastroenterol* 1996; 91(5): 873–878.
42. Zalewsky CA, Moody FG. Mechanism of mucus release in exposed canine gastric mucosa. *Gastroenterology* 1979; 77(4): 719-729.
43. Goel RK, Maiti RN, Mukhopadhyay K. Effect of Tamrabhasma, an Indian indigenous preparation of copper on rat gastric mucosal resistance. *Indian J Exp Biol* 1994; 32(8): 559-561.
44. Goel RK, Sairam K. Antiulcer drugs from indigenous sources with emphasis on *Musa sapientum*, Tamrabhasma, *Asparagus racemosus* and *Zingiber officinale*. *Indian J Pharmacol* 2002; 34(2): 100-110.
45. Menguy R, Desbaillets L. The gastric mucous barrier: influence of protein bound carbohydrate in mucus on the rat of proteolysis of gastric mucus. *Ann Surg* 1968; 168(3): 475-482.
46. Pasquale R, Germano MP, Keita A, Sanoga R, Iauk L. Antiulcer activity of *Pteleopsis suberosa*. *J Ethnopharmacol* 1995; 47(1): 55-58.
47. Bandhopadhyay UK, Biswas R, Chatterjee I, Chattopadhyay CK, Ganguly K, Banerjee R. Gastroprotective effect of Neem (*Azadiracta indica*) bark extract: Possible involvement of H⁺-K⁺-ATPase inhibition and scavenging of hydroxyl radical. *Life Sci* 2002; 71(24): 2845-2865.
48. Shorrock CJ, Rees WDW. Overview of gastroduodenal mucosal protection. *Am J Med* 1988; 84(2 Suppl 1): 25- 34.
49. Goel RK, Maiti RN, Manickam M, Ray AB. Antiulcer activity of naturally occurring pyrano-coumarin and isocoumarins and their effect on prostanoid synthesis using human colonic mucosa. *Indian J Exp Biol* 1997; 35(10): 1080-1083.
50. Wolfe MM, Soll AH. The physiology of gastric acid secretion. *N Engl J Med* 1988; 319(26): 1707–1715.
51. Chong E, Ensom MH. Pharmacogenetics of the proton-pump inhibitors: a systematic review. *Pharmacotherapy* 2003; 23(4): 460-471.
52. Allen A, Flemstrom G, Garner A, Kivilaakso E. Gastroduodenal mucosal protection. *Physiol Rev* 1993; 73(4): 823–857.

*All correspondences to: Dr. Debjani Guha, S. N. Pradhan Centre for Neurosciences, University of Calcutta, 244 B, A. J. C. Bose Road, Kolkata-700020 WB, India. Email: debjaniguha@rediffmail.com