

University of Montana

## ScholarWorks at University of Montana

---

Graduate Student Theses, Dissertations, &  
Professional Papers

Graduate School

---

1990

### Use of flexible fiberoptic nasendoscopy (FFN) for the purpose of laryngeal examination with the voice disordered population.

Katherine A. Cody  
*The University of Montana*

Follow this and additional works at: <https://scholarworks.umt.edu/etd>


**Let us know how access to this document benefits you.**

---

#### Recommended Citation

Cody, Katherine A., "Use of flexible fiberoptic nasendoscopy (FFN) for the purpose of laryngeal examination with the voice disordered population." (1990). *Graduate Student Theses, Dissertations, & Professional Papers*. 7297.  
<https://scholarworks.umt.edu/etd/7297>

This Thesis is brought to you for free and open access by the Graduate School at ScholarWorks at University of Montana. It has been accepted for inclusion in Graduate Student Theses, Dissertations, & Professional Papers by an authorized administrator of ScholarWorks at University of Montana. For more information, please contact [scholarworks@mso.umt.edu](mailto:scholarworks@mso.umt.edu).



Mike and Maureen  
**MANSFIELD LIBRARY**

---

Copying allowed as provided under provisions  
of the Fair Use Section of the U.S.

**COPYRIGHT LAW, 1976.**

Any copying for commercial purposes  
or financial gain may be undertaken only  
with the author's written consent.

---

University of  
**Montana**



The Use of Flexible Fiberoptic Nasendoscopy (FFN)  
for the Purpose of Laryngeal Examination with the  
Voice Disordered Population

by

Katherine A. Cody

B.Sc., University of Alberta, 1986

Submitted to the

Department of Communication Sciences and Disorders

and the Graduate School

in partial fulfillment of the requirements

for the degree of

Master of Communication Sciences and Disorders

University of Montana

1990


Approved by



Chairman, Board of Examiners



Dean, Graduate School



Date

UMI Number: EP38098

All rights reserved

INFORMATION TO ALL USERS

The quality of this reproduction is dependent upon the quality of the copy submitted.

In the unlikely event that the author did not send a complete manuscript and there are missing pages, these will be noted. Also, if material had to be removed, a note will indicate the deletion.



UMI EP38098

Published by ProQuest LLC (2013). Copyright in the Dissertation held by the Author.

Microform Edition © ProQuest LLC.

All rights reserved. This work is protected against unauthorized copying under Title 17, United States Code



ProQuest LLC.  
789 East Eisenhower Parkway  
P.O. Box 1346  
Ann Arbor, MI 48106 - 1346

## TABLE OF CONTENTS

CHAPTER ONE: Introduction .....	p. 1
CHAPTER TWO: Flexible Fiberoptic Nasendoscopy (FFN)	
Development of FFN .....	p. 5
Equipment .....	p. 6
Procedures .....	p. 9
Safety .....	p. 11
Training .....	p. 13
Maintenance .....	p. 17
Conclusions .....	p. 17
CHAPTER THREE: Clinical Applications of FFN	
Introduction .....	p. 19
Diagnostic Applications .....	p. 19
Confirming Diagnosis .....	p. 21
Prevention .....	p. 22
Patient and Professional Education .....	p. 22
Remediation Applications .....	p. 23
Monitoring Progress .....	p. 24
Case Studies .....	p. 25
Conclusions .....	p. 33
CHAPTER FOUR: Comparison of FFN with other methods of laryngeal assessment	
Introduction .....	p. 34
Indirect Laryngoscopy .....	p. 34
s/z ratio .....	p. 35
Aerodynamic Studies .....	p. 36
Electroglottography .....	p. 38
Electromyography .....	p. 39
Ultrasound .....	p. 40
Cinematography & Ultra High Speed Photography .....	p. 41
Stroboscopy .....	p. 41
Laryngoscopy .....	p. 43
Rigid Fiberoptic Scope .....	p. 44
Perceptual Assessments .....	p. 44
Acoustic Measures .....	p. 45
Flexible Fiberoptic Nasendoscopy .....	p. 46
Comparison of Nasendoscopy with other Methods .....	p. 51
CHAPTER FIVE: Issues for Speech-language Pathologists use of Nasendoscopy	
Introduction .....	p. 53
Speech Pathologists Role in Laryngeal Exam .....	p. 53
The FFN Technique; Issues to Consider .....	p. 56
Conclusions .....	p. 58

TABLE OF CONTENTS

CHAPTER SIX: Conclusions .....	p. 60
REFERENCES .....	p. 62

## LIST OF TABLES

### Table 4.1

Comparison of the advantages and disadvantages  
of indirect and direct techniques of quantifying,  
qualifying, and observing vocal fold function ..... pp.48-51



LIST OF ILLUSTRATIONS

Figure 2.1  
Flexible Fiberoptic Endoscope ..... p.8

Figure 2.2  
Schematic Representation of Equipment Set Up for  
Videonasendoscopy ..... p. 8

## Introduction

Many authors, this author included, believe that the management of the voice disordered population is largely an art (Aronson, 1985; Brewer & McCall, 1974; Moore, 1971; Reed, 1980). Blaustein and Bar (1983) suggested that the majority of speech-language pathologists working with voice patients rely almost entirely on perceptual judgments to identify and treat disorders. In completing a routine voice evaluation, for example it was suggested that:

Speech clinicians have demonstrated a tendency to describe voice problems on the basis of subjective auditory judgments rather than objective observations of vocal fold function (Pannbacker 1984, p.169).

Presently, within the field of speech-language pathology there is an increasing demand for accountability for program effectiveness and for accurate diagnosis (Reed, 1980). Because of this demand it is becoming necessary that speech-language pathologists be more accountable in the assessment and management of the voice disordered population.

In order to be accountable in managing voice patients knowledge of the patient's vocal mechanism is considered vital because without it "patients can neither be accurately or convincingly informed nor can therapy be rationally planned" (Aronson, 1985, p.254). Regretfully, traditional voice evaluations by speech-language pathologists do not allow the

clinician a first hand knowledge of the patient's vocal mechanism. During a traditional voice evaluation speech-language pathologists use rating scales to describe the patient's voice according to a variety of parameters such as: quality, loudness, pitch, and resonance (Boone, 1980; Perkins, 1971; Wilson & Rice, 1977). Additional measures recorded during a typical voice evaluation include more objective or quantitative measures such as sustained phonation and laryngeal efficiency. Sustained phonation and laryngeal efficiency are used as indicators of laryngeal function. A case history, oral peripheral examination, and a hearing screening are also routinely performed during a standard assessment of voice. Unfortunately, traditional voice evaluation measures, such as those discussed, are limited because they only providing a description of the deviant voice. In order to identify or rule out pathological conditions of the vocal mechanism, evaluation of laryngeal structures of voice patients is necessary.

Speech-language pathologists typically treat a variety of voice patients such as patients with: vocal nodules, vocal polyps, vocal fold paralysis, and functional voice disorders. These laryngeal pathologies frequently disturb the physiological process required for speaking, and as a result, the reversal of laryngeal pathology often becomes an essential treatment goal in voice therapy (Brewer & McCall, 1974). Therefore, frequent evaluation of laryngeal structures of

voice patients in therapy is necessary to monitor laryngeal pathologies and determine treatment effectiveness (Reed, 1980).

In completing an evaluation of the laryngeal mechanism the appearance of the laryngeal structures such as: the size, shape, and color of the vocal folds, and the movement patterns of the vocal folds are evaluated. The flexible fiberoptic nasendoscope (FFN) is one of several of the techniques currently available for performing such an examination of the larynx. The FFN is suggested as "an excellent means for laryngeal examination " (Brewer & McCall, 1974) because it permits examination of laryngeal structure and function during continuous phonation of: sounds, words, sentences, and passages (Selkin, 1984). Because FFN permits study of the larynx during connected speech it has appeal to voice clinicians. In fact, some speech-language pathologists working in medical settings use FFN as a clinical tool that compliments existing diagnostic protocols for voice evaluations and assists in voice treatment (Chapey & Salzberg, 1981). Nevertheless, the speech-language pathologist's role in laryngeal evaluation is controversial. Laryngeal evaluation is often considered the sole responsibility of the otolaryngologist because identification of laryngeal pathologies is considered in the domain of the medical profession (Baken, 1987).

It is the intent of this paper to investigate the use of

the FFN as a clinical tool that can be used by speech-language pathologists to evaluate the laryngeal mechanism, thereby, improving accountability for diagnosis and treatment of voice patients. FFN has applications with other types of communication disorders, such as in evaluating velopharyngeal valving in those voice patients with hypernasal resonance, but for the purpose of this paper the use of FFN will only be discussed as it relates to evaluating the laryngeal mechanism.

In the chapters to follow an in-depth examination of the use of FFN in the assessment and management of the laryngeal mechanism of voice patients will be addressed. An examination of the procedures for nasendoscopic study of the vocal folds will be followed by a discussion of FFN's clinical uses. A comparison of the advantages and disadvantages of FFN will also be provided by comparing it with other methods of laryngeal examination. In the final chapter the issues surrounding speech-language pathologists' use of the procedure will be addressed. Finally, an attempt will be made to outline the ideal management of the voice population. Throughout the paper examples from the Glenrose Rehabilitation Hospital in Edmonton, Alberta will be provided to illustrate uses of the flexible fiberoptic nasendoscope.

## CHAPTER TWO: FLEXIBLE FIBEROPTIC NASENDOSCOPY

### Development of Fiberoptic Endoscopy

Examination of the laryngeal mechanism has been considered routine ever since Manuel Garcia created the indirect laryngoscope in 1854 (Baken, 1987; Wilson, 1988; Yanagisawa, Cassuccio, Suzuki, 1981). For more than 100 years the indirect method using the laryngeal mirror served as the laryngologist's standard method for viewing the vocal folds (Harris & Collins, 1989). Typically, when using the indirect method, vowels, such as the vowel /i/ have been used to obtain information on vocal fold movement (Selkin, 1984). However, vocal fold movement for other vowels, nasals, and voiced consonants can also be observed.

Although the indirect method has been the most common method for evaluating laryngeal structures it has received criticism because the examiner is often provided only a fleeting glimpse of the larynx (Williams, Farquaharson & Anthony, 1975). This is the case because the placement of the laryngeal mirror in the oral cavity has a tendency to elicit a gag reflex; limiting the examiner's view. Another criticism of the indirect technique has been that it only provides information for vocal fold movement for a very select group of speech sounds, and does not represent laryngeal function during connected speech. Therefore, in order to examine the larynx during continuous phonation of words, phrases, and sentences it was recognized that new methods of laryngeal

examination had to be developed. As a result, the technological development of flexible endoscopic devices in the 1960's was considered to be of great assistance in examination of the laryngeal mechanism during continuous phonation.

Sawashima and Hirose (1968) developed an endoscope that used two fiberoptic bundles that formed a single cable; one bundle carried light, while the other fiberoptic bundle carried the image back to the eyepiece of the scope (Baken, 1987). The cable of the fiberoptic scope was small in diameter (about 5 mm) and was flexible (see Figure 2.1). Controls in the instrument allowed the flexible portion of the nasendoscope to be bent and positioned, allowing the examiner to manipulate its passage through body orifices (Baken, 1987). Further developments such as wrap around fiberoptic bundles increased the amount of light, allowing for better visualization of the image (Wilson, 1988).

#### Equipment

Depending upon the intended purpose, the FFN procedure may require a variety of equipment. Typically, clinical examination of the laryngeal mechanism using FFN makes use of a flexible fiberoptic endoscope and a light source (zenon light source). The diameter of the fiberoptic scope is important for patient comfort; the narrower the scope the better. Unfortunately, the narrower the diameter of the fibre bundle the poorer the light and the poorer the resolution of

the image (Harris & Collins, 1989).

For photographic purposes a 35mm single lens reflex endoscopic camera can be used or a non-endoscopic camera with a 70-125mm focal lens length is suitable (Wilson, Kudryk & Sych, 1986). In order to allow multiple viewers the same view as the examiner (such as in the case of patient education and professional consultation) additional equipment is required. These additional equipment requirements include: a video camera suitable for endoscopic work, a videorecorder (for recording purposes), and a television monitor. The use of the videorecording equipment set up is referred to as flexible fiberoptic videonasendoscopy (FFVN) (represented schematically Figure 2.2).

FFVN requires attachment of the nasendoscope and light source to a camera which is then attached to the television monitor and videorecording equipment. A microphone is also attached to the videorecording equipment to allow simultaneous voice recording. The FFVN procedure is preferable over the FFN technique as it allows multiple viewers. It has been demonstrated that an endoscopic team of multiple observers can significantly improve the reliability of diagnosis of laryngeal pathology (Brewer & McCall; D'Antonio, Marsh, Province, Muntz, & Phillips, 1989; Wilson et al., 1986). For this reason the FFVN technique will primarily be addressed throughout the following chapters.



Figure 2.1 Flexible Fiberoptic Endoscope.  
 Source: Williams, Farquharson and Anthony, 1975.

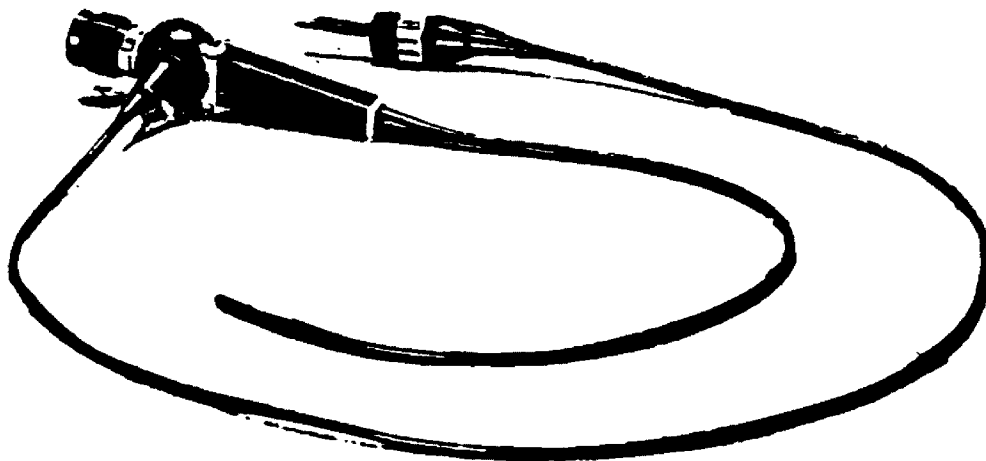
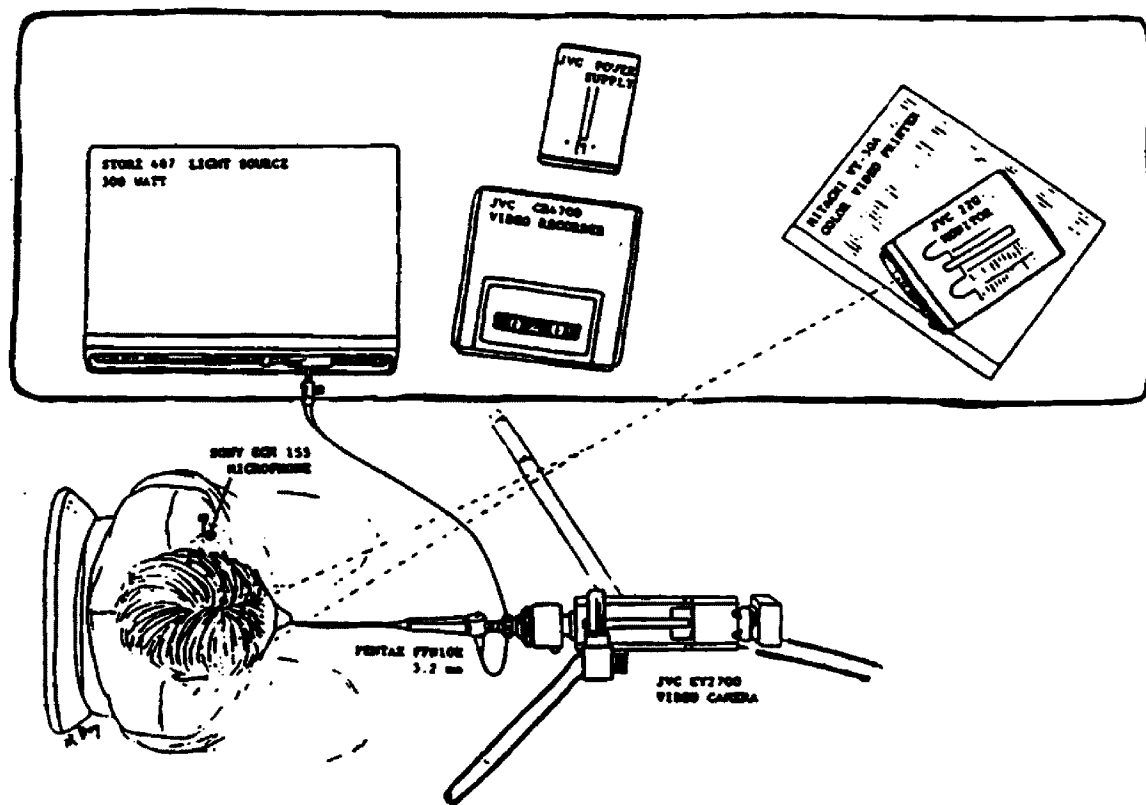


Figure 2.2 Schematic representation of equipment set up for Videonasendoscopy. Source: Wilson, Kudryk, and Sych, 1986.



## Procedure

After reviewing the literature on nasendoscopy one is impressed by the fact that there does not appear to be a universally agreed upon method for performing laryngeal examination using FFN. The basic procedure for FFN evaluation of the laryngeal mechanism involves using the positioning controls of the fiberoptic scope to visually guide it through the nasal cavity and nasopharynx, through the velopharyngeal port and oropharynx, into the hypopharynx. The tip of the scope is brought down to the level of the epiglottis and angled to provide a view of the superior surface of the vocal folds (Sawashima, Abramson, Cooper & Lisker, 1970).

Variations in the FFN procedure are many, and include: 1) the use of anesthetic for either anesthetizing the nasal cavity or oral cavity 2) the use of video imaging and simultaneous voice recording 3) the use of equipment (such as the use of different light sources), and 4) the use of different procedures (e.g. stereoimaging where two nasendoscopes are utilized).

For the purpose of this paper the FFVN procedure for laryngeal examination that is used at the Glenrose Rehabilitation Hospital in Edmonton, Alberta will be described because it is representative of procedures required for videonasendoscopic study. The following procedural description for FFVN is largely based upon the description provided by Wilson et al. (1986).

Prior to performing nasendoscopy it is important that the procedure be explained to the patient and the patient sign consent forms. A medical history can then be obtained with particular attention given to any contraindications to topical anaesthetic (such as allergic reactions that may have taken place in the past following topical anesthetic for dental work).

Once it has been determined that there are no contraindications to topical anesthetic and the patient's medical history is not considered to be too risky, (ie: the need for laryngeal evaluation is not out weighed by serious risks to the patient's health or well being), then the patient's nasal cavities can be inspected. The patient's larger nasal cavity can be anesthetized using cotton soaked in a solution of Xylocaine (a lidocaine hydrochloride solution) and Neo-Synephrine (phenylephrine hydrochloride nasal solution). Those patients with a hyper-active gag reflex may be sprayed orally with Lidocaine (an anilide derivative).

While waiting for the anesthesia to take effect the distal end of the fiberoptic scope is polished with pHysoHex (a hexachlorophene cleaning emulsion) to prevent fogging of the nasendoscope lens. After about 5-10 minutes the soaked cotton is removed from the nasal cavity and the patient is seated in a comfortable chair. A microphone is attached to the patient's clothing and the nasendoscope is inserted into the anesthetized nasal cavity.

Wilson et al. (1986) reported that to facilitate passage of the scope through the velopharyngeal port the patient is asked to sustain the nasal /m/. Alternatively, Silberman, Wilf and Tucker (1976) reported that to facilitate passage of the fiberoptic scope, patients are instructed to breathe through their nose allowing the soft palate to fall away from the posterior pharyngeal wall. After the scope is brought into position above the vocal folds, the patient is asked to state his/her name, count, and then perform a variety of speech tasks such as: sing, hold the tone /i/ as long as possible, produce /i/ going from highest to lowest, repeat sounds, words, phrases, sentences, and passages (Wilson et al., 1986). The scope is then removed and the image is played back for the endoscopic team and the patient. Patients are encouraged to ask questions and participate in the discussion.

#### Safety

The FFN technique is a relatively safe procedure. Batch (1985) reported overall complication rates for nasendoscopy at 1.3 per 1000 cases, and for over 211,000 scopings there was an overall mortality rate of only 0.007 percent. According to Batch (1985):

This technique is relatively easy and can be satisfactorily performed by inexperienced operators...In fact almost no patient is too frail or unfit for flexible endoscopy with the possible exception of those too breathless to lie flat for ten minutes or those who

have recently had a myocardial infarction or dangerous cardiac arrhythmia (p.788).

Although the risks associated with nasendoscopy are minimal patients with cardiac or respiratory problems, pregnant women or individuals with complicated medical histories, do pose complications for performing the nasendoscopic procedure. The greatest risk to the patient is due to the use of anesthetic. The pharmacological action of anesthetic drugs allow them to be rapidly absorbed into the body which creates complications if the patient is allergic to the drug.

#### Clinician Safety

In performing the nasendoscopic procedure Wilson (1989) recommended safety precautions be taken to prevent temporary visual acuity shifts that can occur if the xenon light used in FFN is exposed onto the unprotected eye for any length of time. Wilson noted dangers of exposing the light source onto the unprotected eye were minimal, but could affect the clinician making adjustments of the light source. Therefore, he suggested protective goggles (such as a welder type of goggle) be worn when making equipment adjustments. He also noted exposure to body fluids represents the greatest risk to the clinician so protective gloves should be worn when ever possible.

#### Patient Safety

To assure the protection of the patient all equipment coming in contact with body fluids should be properly cleaned

and sterilized (Wilson, 1989). Because the nasendoscope is inserted into a body orifice, sterilization procedures must be routine and meticulously followed to protect the patient from any health risk that may be passed from one person to another. At the Glenrose Rehabilitation Hospital, once a scope is used it is immediately washed with pHisoHex, rinsed, then placed in a container of Cidex (a sterilizing and disinfecting solution) (Wilson, 1989). The scope remains in that solution for a minimum of 30 minutes. The scope is then removed and wiped off with a disinfectant wipe.

Regardless of who applies the topical anesthetic necessary precautions must be taken to ensure the patient's protection, therefore, the examiner needs to ask about contraindications such as allergies to topical anesthetic. Use of the topical anesthetics Lidocaine and Xylocaine should only be administered by a physician because the pharmacological actions of these drug are such that they can be quickly absorbed into the body and can have very serious effects if an individual were allergic to the drug.

#### Training

Presently, specified training requirements do not exist for speech-language pathologists who want to perform nasendoscopy. Batch (1985) stated that endoscopy was relatively simple to perform. Similarly, Gleeson, Siodlak and Wengraf (1985) stated "the skill required to manipulate such an instrument through the nasal passages and across the

pharynx to the larynx of the conscious patient is readily acquired" (p.775). Although the actual nasendoscopic procedure is relatively easy to perform, the interpretative aspects of nasendoscopy are complex. Presently, there is an ASHA AdHoc Committee investigating matters of extended practice in speech pathology such as the use of FFN. Frank Wilson, of the University of Alberta, who is serving on this ASHA AdHoc Committee noted that in order to conduct FFN :

The clinician conducting the procedure, regardless of professional background, must have sufficient training to be alert of any variance from normal. Therefore, considerable knowledge of anatomy and physiology of voice production mechanism, as well as, voice perceptions and acoustics are essential. Knowledge of normal structure, color and movement are necessary prerequisites. Whoever conducts the procedure must be sufficiently trained to synthesize the image and movement and effectively use that information to either refer or treat the patient (Wilson, 1989 p.3).

Because of the complexity of FFN interpretation, a training program similar to Wilson's (1989) suggestion of five levels of skill development including:

- 1) technical skill involving equipment,
- 2) technical skill involving the process of nasendoscopy,
- 3) knowledge of normal and pathological conditions,
- 4) familiarity with perceptual and acoustic function,
- 5) knowledge of

procedures for voice remediation (p.6). should be considered in FFN training. In addition to the above training suggestions it is also imperative, in the author's opinion, that a nasendoscopic training program educate students of normal anatomy and physiology of the vocal mechanism.

Wilson (1989) also suggested training requirements for speech-language pathologists be covered within a multidisciplinary environment where a multimedia approach is used. Students learning the technique should have access to a video library of pathological conditions of the laryngeal mechanism with accompanying audio tapes of the pathological voice. Because of the high level of specialization required for interpreting the findings, Wilson recommended that an internship or residency be completed in a clinical experience during which time the clinician should examine numerous patients with FFVN. Finally, the FFN results should be interpreted under supervision.

A study by D'Antonio et al. (1989) investigating the reliability of visual perceptual ratings of FFN by both expert and novice judges revealed interesting findings that this author believes could have useful applications for FFN training. The findings of the study suggested that experienced speech-language pathologists working together as a group can make highly consistent judgments of FFN videotapes. Experienced clinicians working in a group were found to be



more consistent than novices working alone. D'Antonio et al. (1989) also found that novice speech-language pathologists were more consistent than novice plastic surgeons and otolaryngologists. D'Antonino et al. (1989) suggested that one of the reasons for speech-language pathologists consistency in rating FFN videos was that speech-language pathologists spent more time viewing the FFN videos and were more dependent on auditory information than the novice physicians. They suggested that combined FFN evaluations using both visual and auditory modalities seem to be superior to single modality observations. Finally, D'Antonio et al. (1989) found that exposure to 125 segments of FFN videos in isolation was insufficient to increase novice performance, indicating that training for interpretive aspects of FFN must be extensive.

D'Antonio et al. (1989) suggested that FFN training should teach new raters to use both auditory and visual information. Both expert and novice raters in the study reported they prefer to work in a group and when asked how to train others to rate FFN they reported a preference for calibration tapes. The raters indicated that training tapes accompanied by feedback helped anchor perceptual judgments.

In conclusion, training for FFN should emphasize interpretive aspects of laryngeal evaluation. An understanding of anatomy and physiology of the vocal mechanism is essential for any examiner performing the procedure. Skill levels such as those purposed by Wilson (1989) should also be included in

FFN training. Finally, FFN interpretation should be trained using training tapes and feedback from expert judges. Auditory and visual aspects of FFN should also be emphasized in training.

#### Maintenance

Like any mechanical instrument the FFN deteriorates over time. Wilson et al. (1986) reported that endoscopes tend to deteriorate because of fibre breakage, poor handling, and exposure to high environmental heat. Nasendoscopes need to be routinely checked for fiber leaks and if a leak is found the scope should immediately be returned to the manufacturer for repair or replacement (Wilson, 1989). If the FFVN procedure is used the VCR, TV monitor, light source should be routinely checked and calibrated.

#### Conclusion

The development of FFN in the 1960's permitted observation of the vocal fold movement for continuous phonation of consonants, words, phrases and sentences. Previous to the development of FFN observation of vocal fold movement was primarily assessed using the laryngeal mirror permitting observation of vowels, some nasals, and some voiced consonants. In performing FFN the nasendoscope is passed through the client's nasal cavity over the velopharyngeal port to a level just above the epiglottis. It was noted that the procedure can be performed with or without the use of a closed circuit television monitor which permits multiple observers.

To date there are no standards regarding training for the procedure, however, it is agreed that experience is required to both perform and interpret the findings.

## CHAPTER THREE: CLINICAL APPLICATIONS OF FLEXIBLE FIBEROPTIC NASENDOSCOPY

### Introduction

FFN has found numerous clinical uses within the medical community such as investigating the gastro-intestinal tract and respiratory system (Batch, 1985; Lancer & Moir, 1985; Ward et al., 1974). Speech-language pathologists and otolaryngologists find the FFN appealing for examination of the larynx because it illuminates the laryngeal structures with minimal discomfort to the patient. In addition, FFN is appealing because it is possible to observe speech sounds both in isolation and in connected speech at the laryngeal level with minimal interference from oral articulation. In this chapter some of the clinical uses of FFN will be discussed with particular attention given to those applications that apply to the speech-language pathologist.

### Diagnostic Applications

According to Aronson (1985), diagnosis of voice patients should determine whether the type and severity of the deviant voice is congruent with the size and position of the vocal lesion or paralysis. Aronson suggested that if the pathology and the perceptual voice characteristics were congruent then the disorder is probably organic. If a discrepancy exists, however, (i.e. the voice quality is more severe than warranted by the appearance of the laryngeal mechanism), then one should suspect a psychogenic component to the deviant voice.

It is the author's opinion that the size and appearance of the vocal lesion should be congruent with the perceptual voice characteristics. In instances when the perceptual voice characteristics are not congruent with the appearance of laryngeal structures, one can generally assume that the patient is misusing their vocal mechanism to produce the deviant voice quality. Nevertheless, one should always exercise caution when using Aronson's diagnostic approach, in order that one does not assume that a pathology does not exist because it is not visible.

Use of FFN allows examination of aspects of the laryngeal mechanism's structure and movement patterns. Examiners using the FFN for laryngeal examination are able to identify: 1) mass lesions of the vocal folds, 2) discoloration in the appearance of the vocal folds, and 3) asymmetrical movement patterns of the vocal folds. It is important to point out that it is difficult to quantify FFN observations except for gross subjective judgments of size, color, and movement. Observations of color are often distorted by the television monitor. Additionally, it is difficult to quantify asymmetrical movement patterns because one cannot determine adduction of the vocal folds to midline position based upon the image provided by the TV monitor. Nevertheless, FFN allows physicians to visualize gross differences in laryngeal structure and function allowing them to diagnose certain laryngeal pathologies with a good deal of confidence while

ruling out many other voice disorders.

#### Confirming Diagnosis

Misdiagnosis of voice disorders is unfortunately a common occurrence. It is also very concerning since reliance on a misdiagnosis may result in the use of inappropriate management strategies and may result in a delay in treatment (Wilson, 1989). Wilson (1988) reported about 50% of the patients that were referred to him for the purpose of FFVN evaluation had a previous diagnosis that was inconsistent with the findings of FFVN. Similarly, it was this author's experience in working with patients at the Glenrose Rehabilitation Hospital that there was a higher incidence of misdiagnosis of laryngeal pathology in those voice patients who were initially evaluated with a laryngeal mirror.

FFVN serves as a means for confirming a diagnosis of vocal pathology because it can be used in an unhurried manner providing the examiner with a sufficiently long observation of the appearance and movement of the vocal folds. Because FFVN can be used in an unhurried manner it is considered to be an improvement over the indirect technique using the laryngeal mirror which permitted only a brief glimpse of laryngeal structures. FFVN also permits a videorecorded image of the larynx that can be viewed repeatedly and at different time intervals allowing the image to be shared with other professionals for consultation purposes.

### Prevention

In addition to use of FFN for traditional clinical purposes (ie: diagnosis and confirmation of diagnosis), Chapey and Salzberg (1981) suggested fiberoptic systems such as FFN could have applications for prevention of voice disorders. They suggested that the FFN could be used by speech-language pathologists in routine oral peripheral examinations, thereby, assisting in identification of laryngeal disorders and speeding up the process for further treatment.

This author believes that routine use of FFN in oral peripheral examinations would probably not be practical for most clinical settings because the equipment expense would not be difficult to justify.

### Patient and Professional Education

FFVN has the advantages of allowing instant replay of recorded images and the option of multiple viewers. Recorded laryngeal images can be instantly replayed allowing patients to directly observe their laryngeal mechanism and associated pathology. Lancer and Jones (1985) reported FFN is: "particularly useful for instructing patients with functional laryngeal diseases and in cases of vocal abuse. The patient is able to visualize his own larynx and can actually see what the problems are" (p. 772). It was this author's experience that patients who have the opportunity to observe their laryngeal function seem to have a greater understanding of the their disorder and have an increased awareness of the

structure and function of the larynx.

Not only is the videonasendoscopic procedure useful for patient education, it is also informative for referring physicians and voice clinicians. Many therapists find it informative to observe their clients' phonatory behavior prior to seeing the patient for treatment. It is suggested that this provides insights regarding the patient's laryngeal function and assists in formulating realistic goals for voice therapy (Brewer & McCall, 1974; Chapey & Salzberg, 1981). The video tapes can also be shared with other professionals for consultation purposes.

#### Remediation Applications

FFN can be used therapeutically by speech-language pathologists as a visual feedback device (Brewer & McCall, 1974; McFarlane & Lavarato, 1984). A biofeedback system such as the FFVN procedure allows the patient to almost simultaneously observe their laryngeal function. This type of feedback allows the patient to make ongoing adjustments in their phonatory output.

A point that is noteworthy is that instantaneous feedback has been found to be more successful for short term gains in therapy in helping clients modify their behavior than traditional behaviorist methods of feedback (Rubow & Swift, 1985). Behaviorist feedback relies upon the clinician's perceptual skills in provides reinforcement contingent upon the client's response. When providing feedback to the patient



during therapy voice clinicians must quickly and reliably identify both the acceptable and the deviant qualities (such as excessive breathiness, low pitch or excessive tension) in the patient's voice (Rosenbeck & Lapointe, 1978). Unfortunately, speed and consistency in clinical judgments are not infallible. Clinicians are biased by their own emotions, their level of fatigue, and by previous client's vocal behavior (Rosenbeck & LaPointe, 1978). For this reason, the visual, almost instantaneous feedback that the FFVN videorecording provides regarding vocal fold movement is particularly valuable feedback for the patient that can supplement the clinician's perceptual feedback.

FFVN as a biofeedback device has met with success in patients with vocal fold paralysis. Studies have demonstrated that patients with vocal fold paralysis who are able to visualize abduction and adduction of the vocal folds are better able to make compensations with their non-paralyzed vocal fold. These patients are believed to make improvements because they are able to visualize their own adjustments in voicing (McFarlane & Lavarto, 1984; Wilson, 1988).

It is this authors opinion that FFVN is not an appropriate feedback device for all voice patients. Some voice patients may find the FFN noxious and as a result would not tolerate the device for the lengthy periods in therapy.

#### Monitoring Progress

The use of FFVN as a method of documenting progress is

perhaps its most appealing application to speech-language pathologists. Videorecording of laryngeal images provides a permanent record that can be reviewed repeatedly and at a later date allowing comparison of the laryngeal pathology over time.

In many instances the reversal of laryngeal pathology is a treatment goal for management of certain voice disorders (Brewer & McCall, 1974). Because the nasendoscopic procedure permits visualization of the laryngeal structures, it is possible to observe a gross reduction in size or the absence of a previous lesion. Therefore, examiners are able to describe changes in the laryngeal condition over time allowing the examiner to make decisions regarding discharge planning.

This author's believes caution should be exercised in using visual appearance alone as a criteria for dismissal from treatment. The etiological factor with many voice patients is vocal abuse. Therefore, regardless of the absence of the vocal pathology, a reduction of vocal abuse and an understanding of vocal hygiene should be considered necessary criteria for dismissal.

#### Case Studies

At the Glenrose Rehabilitation Hospital in Edmonton, Alberta, voice patients from North Central Alberta are initially evaluated at a biweekly Voice Clinic. FFVN is a routine component of the voice evaluation and is often a component of the dismissal criteria. It is estimated that

approximately 432 patients are seen through the Glenrose Voice Clinic yearly. This value includes both patients seen for initial evaluation and patients seen for reviews (Wilson, 1988). The majority of these patients are evaluated with the FFVN procedure because their deviant perceptual voice characteristics warrant laryngeal evaluation.

The case reports of three voice patients from the Glenrose/ University of Alberta will be discussed in the section that follows. The intervention with these patients will illustrate the clinical value and utility of the FFVN procedure in managing the voice disordered population. The first case report will demonstrate the use of FFVN in monitoring laryngeal pathology. The second case report will illustrate FFVN's use in confirming diagnosis and, finally, the last case report will demonstrate FFVN's use as a feedback device. The two final cases were taken from Wilson's (1988) chapter "On the Importance of Laryngeal Visualization".

#### PATIENT #1

Patient #1 is a 49 year old male referred to the Voice Clinic by an Otolaryngologist (ENT). In the referral letter the ENT indicated that the patient was impossible to examine using a mirror because of his severe gag reflex. As a result he requested that FFVN evaluation be completed on the patient.

The patient was self employed and operated a consultation business that served the North West Territorial (NWT) government. He reported the use of his voice was vital to his

work as he was required to conduct interviews, and to provide seminars and workshops.

At the time of the initial evaluation in January the patient reported problems with his voice for about one year. He reported that he had previously had a vocal polyp.

A voice evaluation and FFVN study were completed. Perceptually, the patient's voice was characterized by breathiness, lack of projection, diplophonia, and low pitch. The FFVN examination indicated redness of the vocal folds and a hemorrhagic-like vocal polyp on the right vocal fold. The videotape recording was shared with the referring physician and he recommended a period of voice therapy. The patient was subsequently referred to a speech-language pathologist in the NWT, however, she reported she would be unable to work with the patient. An intensive period of voice therapy was then recommended for a time that would be convenient for the patient to come to Edmonton for treatment.

The patient was seen for two weeks of intensive voice therapy in March. At the end of this period he was reviewed through the Voice Clinic. FFVN revealed an improvement in vocal fold appearance, (i.e.: less redness and a decrease in the size of the polyp was noted). A perceptual assessment of his voice also revealed an improvement in quality.

The client was reviewed through the clinic again in May. At that time, a perceptual assessment of his voice indicated diplophonia. The FFVN examination revealed marked changes in

the epithelial layers of the right vocal fold giving the appearance of a large polypoid structure on that vocal fold. The findings were shared with the ENT and surgical management was recommended. In June the polyp was surgically removed. Reportedly, the patient's voice improved for a short while following the surgery.

In October, when the patient was seen for review through the Voice Clinic, FFVN was again performed and revealed reduced movement of the right vocal fold; additionally, leukoplakial-like structures on the anterior 1/3 of the right vocal fold were noted. Perceptual assessment of the patient's voice revealed breathiness, lack of projection and vocal fatigue. The findings were shared with the referring ENT. The ENT performed a biopsy the results of which revealed precancerous tissue growth. At the referring ENT's recommendation, the patient was seen at the Glenrose Rehabilitation Hospital for an intensive period of voice therapy in December in order to review strategies such as vocal hygiene and voice placement techniques in order to obtain optimal voicing. In conjunction with voice therapy, stress and tension reduction treatment by the psychology department was also recommended. At the end of this treatment period the client was reviewed through the Voice Clinic. FFVN was performed revealing redness and structural changes of an irregular nature extending from the anterior 1/3 to 1/2 of the right vocal fold. Restricted movement of that vocal fold was

also noted. The videotape results were shared with the referring physician.

In January the physician performed a biopsy the results of which indicated cancerous growth affecting the right vocal fold. The patient was subsequently referred to the Cancer Clinic and received a six week period of radiotherapy.

The previous case study demonstrates why FFVN is a valuable tool for clinical examination of the larynx. For this patient his severe gag reflex made it impossible to monitor changes in the laryngeal structures with the indirect method using the laryngeal mirror. Periodic reviews performed at the Voice Clinic at the Glenrose Hospital with FFVN were vital for monitoring changes in the precancerous growth on his vocal fold. FFVN was easily and quickly performed with minimal discomfort and the results provided invaluable diagnostic information regarding the structural changes in the patient's vocal mechanism. Had the patient been hospitalized for laryngoscopy there would have been considerable expense and the results would not have been obtained as quickly. In addition, the videotape images served as an excellent means for documenting changes over time and for sharing information with the referring physician.

#### PATIENT #2

Patient #2 was a 64 year old female referred with a diagnosis of spastic dysphonia. The patient described herself

as a professional beer hall singer. She had not received voice training. Reportedly, during a six week singing commitment she developed an upper respiratory infection and, reportedly, she had to use increased laryngeal tension to sing. She reported that at that time her voice was breathy, low pitched and strained with frequent loss of voice. Her physician recommended a three week period of voice rest but this did not improve her voice. She was subsequently seen by two specialists. The second specialist provided a diagnosis of spastic dysphonia. At that time she was informed that spastic dysphonia was a complicated disorder with a poor prognosis. The physician indicated her singing career was probably over. Wilson (1988) reported this created a great deal of anxiety for the patient and as result she increased inappropriate compensatory behaviors to attain voicing.

The patient was referred to the University of Alberta voice lab for further consultation. Both an FFVN evaluation and a voice evaluation were completed. The voice evaluation revealed excessive breathiness, intermittent aphonia, severe tension, and intermittent pitch breaks. It was suggested that the voice could be thought of as "strained strangled" voice quality but no laryngeal spasms were noted that would suggest spastic dysphonia. The FFVN evaluation indicated supraglottic tension with the ventricular folds closing off the glottic area for most voicing. These findings were not consistent with the diagnosis of spastic dysphonia rather the findings

required a diagnosis of ventricular eclampsia. The findings were discussed with the patient. Because of the change in diagnosis, her prognosis for improved voice was stressed. The video tape replay helped demonstrate to the patient how she was using her vocal folds inappropriately.

Voice therapy was recommended and Wilson reports that within two weeks the patient was symptom free.

The previous case history serves as a useful example of how FFN can be used as a method for confirming a previous diagnosis. FFN can be used in an unhurried manner permitting a sufficiently long observation of laryngeal structures and laryngeal function.

#### PATIENT #3

Patient #3 is a 28 year old female with vocal fold paralysis resulting from a job related accident that severed the recurrent laryngeal nerve. Three weeks after the accident the patient noticed a marked reduction in voice production, reduced loudness, and a reduced pitch range. She was referred to an otolaryngologist who made a diagnosis of left vocal fold paralysis with poor compensation of the right vocal fold. The patient was subsequently referred for voice therapy.

During the initial voice evaluation excessive breathiness, pitch breaks, diplophonia, and periods of intermittent aphonia were noted. The FFVN provided an view of the laryngeal area illustrating the reduced mobility of the



left vocal fold which left a gap in the posterior portion when it approximated midline. With the endoscope in place it was demonstrated that by using the "pushing technique" the patient could close the vocal fold thereby improving the quality of her voice. The laryngeal image and the simultaneous voice were videorecorded. Therefore, once the scope was removed the tape could be played back to the patient in therapy to demonstrate what was happening at the level of her larynx when she used the pushing technique. It also provided her with information on vocal fold paralysis.

Wilson (1988) reported that therapy focused upon evaluation of the videotape as well as the traditional pulling and pushing techniques. Increasing air supply to improve the subglottic air pressure was also targeted. The patient was seen over a period of three months. At the end of therapy the voice characteristics were nearly normal with good loudness and only mild breathiness. The vocal folds were reviewed with FFVN every six months for approximately 18 months. The left vocal fold was still paralyzed but the patient was using good compensatory strategies.

The final case history demonstrated FFN's use as a feedback device. The visual feedback provided by the FFVN technique was particularly useful for allowing the patient with vocal fold paralysis to make compensations in adduction with her non-paralyzed vocal fold.

### Conclusions

Throughout this chapter numerous clinical applications of FFN were addressed. It was noted that FFN has numerous uses beyond simply being a tool for diagnosis of laryngeal pathology. FFN is useful as a method for confirming diagnosis, and it has several applications that are particularly applicable for speech-language pathologists working with voice patients. FFN can be used by speech-language pathologists in routine oral peripheral examinations for prevention of voice disorders, it can be used as a feedback device, and it can serve as an means for documenting progress in therapy.

## CHAPTER FOUR: COMPARISON OF FLEXIBLE FIBEROPTIC NASENDOSCOPY WITH OTHER METHODS OF LARYNGEAL EXAMINATION

### Introduction

Recent advances in research and technology have made possible observation of laryngeal function from numerous levels. Some methods for laryngeal observation such as FFN permit direct visualization of laryngeal structures. Conversely, other methods (aerodynamic study, perceptual assessments, muscle and neural studies), allow inferences to be made about the laryngeal function but do not permit a view of the vocal folds. In this chapter, a brief review of several of the methods currently available for investigating the vocal mechanism will be addressed. The benefits and disadvantages of each technique will be compared with the advantages and disadvantages of FFN (see Table 4.1).

### Indirect Laryngoscopy

The traditional method of laryngeal exam and probably the most common method of examining the larynx is the indirect technique using a laryngeal mirror. Patients are seated upright and the patient's tongue is grasped with a piece of gauze and drawn out of the mouth. A mirror which has been slightly warmed is placed in the mouth and positioned into the oropharynx by pushing the uvula up and back (Aronson, 1985). A light beam from a head lamp reflects light onto the laryngeal mirror which illuminates the laryngeal structures permitting examination of the tongue, epiglottis, pyriform

sinuses, and aryepiglottic folds, in addition to examination of the vocal folds (Aronson, 1985). Patients are usually asked to phonate the vowel /i/ which tends to elevate the larynx permitting observation of laryngeal structures.

Indirect laryngoscopy is often criticized because it often does not provide a good view of the entire length of the vocal folds. In addition, use of the laryngeal mirror for laryngeal examination is criticized because of the reversal of the image, mirror fogging, and difficulty in obtaining photographic documentation (Ward et al., 1974). Many patients have a tendency to gag when viewed with a mirror and, as a result, only a fleeting glimpse of the larynx or a portion of it is possible (Williams et al., 1975). Young children do not tolerate the procedure well which limits the view of the vocal folds. According to Williams et al. (1975): "Gross abnormality can usually be ruled out but a precise and considered diagnosis in less obvious lesions cannot be safely given" (p.306).

Despite these criticisms the indirect technique is quickly and easily performed and provides useful information on symmetry of movement, normal color, and presence or absence of mass lesions.

#### S/Z Ratio

The s/z ratio is typically used as a method for evaluating laryngeal function. This ratio is a reliable indicator of vocal fold pathology (Eckel & Boone, 1981). The

s/z ratio is obtained by having the patient sustain the fricatives /s/ and /z/ for as long as possible. The length of time the patient is able to sustain the fricative /s/ provides an indicator of expiratory control; while the /z/ value provides a measure of sustained phonation. In normal subjects typical s/z ratios approximate 1.0 indicating that the length of sustained phonation should be equivalent to the length of time for sustained expiration. Poor laryngeal control is indicated when patients demonstrate large time differences such that their s/z value approximates a ratio of 2:1 (Prater & Swift, 1984). Eckel and Boone (1981) found that the s/z ratios of patients with glottal margin pathologies such as nodules or polyps demonstrated s/z ratios in excess of 1.4. Therefore, values greater than 1.4 are considered suggestive of a laryngeal pathology. The s/z ratio has occasionally found use as an indicator of treatment effectiveness (Eckel & Boone, 1981).

Although the s/z ratio is clinically useful it is not meant to be substituted for the laryngeal examination. According to Eckel and Boone (1981) the s/z ratio only "indicates the possible presence of a laryngeal lesion" (p.149).

#### Aerodynamic Studies

Aerodynamic studies of the laryngeal mechanism are similar to the s/z ratio in that they are based upon laryngeal airway resistance. Measures of laryngeal airway resistance

allow inferences to be made about the function of the larynx during speech production (Netsell, Lotz & Shaughnessy, 1984; Smitheron & Hixon, 1981). The technique is a non-invasive procedure. Subjects are seated upright and an Rothesberg mask is placed over the subject's mouth and nose forming an air tight seal. A pressure sensing tube is placed in the patients mouth and the client is asked to repeat successive repetitions of the voiceless consonant/vowel combination /pi:pi:pi/.

Netsell et al. (1984) provided data regarding the aerodynamic performance for normal and voice disordered patients. Levels above and below the normal performance for pressure and flow indicated a laryngeal dysfunction/ abnormality. Netsell et al. (1984) also found that levels of airway resistance were similar within a disordered group (eg. nodules, polyp, head injured, ulcers, post nodule surgery and severed laryngeal nerve) allowing these etiologies to be classified from the pressure flow measurements.

The speech signal /pi/ used in measures of pressure flow is simple and easy to produce and is therefore appropriate for young children. A physician is not required to perform the procedure. Once the examiner has experience with the technique it is relatively quick and easy to perform. A criticism of the aerodynamic technique is that if the pressure sensing tube in patient's mouth is not placed correctly it may interfere with articulation. Young children often react negatively to having the mask placed over the mouth and nose.

### Electroglottography (EGG)

EGG is a non-invasive procedure that involves applying two electrodes to the surface of the skin. EGG is based upon the property of resistance. EGG measures the change in electrical impedance between two electrodes placed on either side of the larynx (Harris & Collins, 1989). The resistance of current flowing across the glottis varies, thereby, providing information on the late adductory phase and the early abductory phase of the vocal cycle (Harris & Collins, 1989). The laryngeal resistance reflects two events; slow changes in resistance are considered changes in ventilation and articulation, while rigid resistance patterns demonstrate vocal fold vibration (Baken, 1987).

EGG is appealing because it is not invasive. Diagnosis of laryngeal pathologies is possible, and EGG can be used as a tool in voice therapy (Fourcin, 1974, 1981; Fourcin and Abberton, 1976; Reed, 1982). The main criticism of the technique centers around the fact that EGG only gives reliable information about part of the vocal cycle. EGG does not give information about glottal activity when air is passing through the glottis, rather, EGG represents activity around the closed phase of the vocal cycle (Harris & Collins, 1989).

Body movement must be minimized during testing because movement artifacts are often picked up and could contaminate the results. Care must also be taken to ensure that the amount of current that is safely passed through human tissue is

small.

### Electromyography

The human muscle fiber is a moderately good conductor of electrical activity. When a neural impulse arrives at the motor end plate of the muscle a neurotransmitter substance is released causing depolarization of the muscle which results in contraction of the muscle. Accompanying this contraction is a small electrical potential (Gay & Harris, 1971; Hirano, 1981). Electrodes placed outside of the muscle membrane can pick up the muscle activity. Three types of electrodes are used in performing electromyography: needle, hooked-wire and surface.

Gay and Harris (1971) report that in the past the needle electrodes were the most commonly used for speech research because they could be inserted directly into the intrinsic muscles, however, needle electrodes were relatively heavy and were uncomfortable. Hooked-wire electrodes which consist of a wire formed into a hook are considered better suited to speech research. Hooked-wire electrodes stay in place, permit natural movement, and are relatively painless (Gay & Harris, 1971; Hirano & Dhala, 1969). Surface electrodes are easily placed and are minimally uncomfortable for the patient. Surface electrodes sum over many motor units providing information on overall muscle activity, but are limiting when specific muscle activity is of interest.

The patterns of the muscle activity provide information



about muscle action and can be displayed on an oscilloscope (Gay & Harris, 1971). The disadvantages of electromyography depend upon the type of electrode that is used. Needle type electrodes have been criticized because they are too heavy and movement artifacts contaminate the signal. In addition, the needle electrodes cause discomfort for the patient (Gay & Harris, 1971). Hooked-wire electrodes are criticized because of problems with breakage, placement, and discomfort to the subject. Clinical applicability of electromyography is limited because of patient discomfort and because it can be a time consuming procedure.

In conclusion, although electromyography is not a routine and simple procedure it has been shown to be reliable for investigating the intrinsic laryngeal muscles (Gay, Hirose, Strome & Sawashima, 1972). For some populations such as for patients with vocal fold paralysis, the electromyography technique provides useful information on the activity of the paralyzed muscle .

#### Ultrasound

Ultrasound operates by using high frequency sound waves that pass through the body tissues. It provides useful information on unilateral movement patterns of the vocal folds particularly for demonstrating the opening and closing of the glottis (Baken, 1987). Because of the small edges of the vocal folds a narrow ultrasound beam is required to provide fine details of glottal opening and closing. Fine resolution is

unfortunately difficult to achieve and correct with the ultrasound technique and as a result displacements of the vocal folds are often difficult to interpret (Baken, 1987).

#### Cinematography and Ultrahigh Speed Photography

A motion picture view of the functioning larynx is possible with cinematography. This technique allows for a slow and regular motion view of the finer details of vocal fold movement during the vibratory cycle (Baken, 1987). In addition, it serves as a means for examining glottal behavior.

Ultra high speed photography photographs the larynx at speeds that are approximately 20-30 times the fundamental frequency of the vibration of the vocal folds (Hirano, 1981). Thus, the vocal folds appear to move at an ultra slow rate. Ultra high speed photography provides little blurring of the image, fine displacements of the vocal folds are visible, and small physiological variations in the vibratory cycle that would not be visible otherwise are observable (Baken, 1987). Drawbacks of the procedure are that it is expensive, time consuming, and often requires a sound proof room for audio recording. In addition, a laryngeal mirror is used to reflect the light for photography purpose onto the laryngeal structures resulting in all the problems of using the laryngeal mirror.

#### Stroboscopy

Stroboscopy is useful for examination of the vibratory

action of the vocal folds. It is a very practical technique that operates with a strobelight source which flashes light on an intermittent basis (Hirano, 1981). The light flashes can be either synchronous with the vibratory cycle of the vocal folds or can be at a slightly slower rate than the vibratory cycle. When light flashes at the identical frequency as the vocal folds an optical illusion is created that provides a clear picture of the stationary vocal folds. When light flashes at a slightly slower frequency than the vibration of the vocal folds a slow motion effect of the vibration of the vocal folds is provided.

The stroboscope can be used as a light source for FFN, thereby, providing information on laryngeal movement during speech. The technique is usually used in combination with the laryngeal mirror which creates several problems associated with use of the laryngeal mirror. The technique is criticized because it does not show fine details of the vibratory cycle, rather, it depends upon rapid sampling of vocal fold position at selected time intervals. The image that results from the rapid sampling is a composite of samples of different vibratory cycles (Baken, 1987), and this averaging of cycles can create misleading, confusing, and invalid interpretation. The examiner cannot assume the averaged vocal fold cycles are equivalent to a normal vibratory cycle. In addition, if the flash of light is too long then the image is blurred. Nevertheless, the stroboscope serves an extremely useful

purpose in illuminating glottal structures and provides useful information regarding vocal fold movement.

#### Laryngoscopy

Direct laryngoscopy is an alternative for laryngeal examination of individuals (such as children or infants) who are difficult to examine. Direct laryngoscopy is often used in conjunction with surgery. The technique requires a general anesthetic and hospital admission, both of which result in considerable expense (Benjamin, 1981; Lancer & Jones, 1985; Williams et al., 1975).

Patients are in a supine position and the laryngoscope is introduced along the right side of the tongue and is guided to the level of the vocal folds. As the laryngoscope is introduced the palate and oropharynx are examined (Benjamin, 1981). Vocal fold movement is best assessed when the anesthesia has been discontinued and the patient is recovering some pharyngeal and laryngeal movement.

The main disadvantage of the technique is that it requires a hospital admission and, as a result, there is a good deal of expense associated with the procedure (Lancer & Moir, 1985; Parnes, Lavarato, & Myers, 1978;). It is important that in performing the procedure that assessment of larynx not be distorted by the pressure from the laryngoscope blade or by the direction in which the scope is introduced since this could lead to misdiagnosis (Benjamin, 1981). According to Benjamin (1981):

Each and every endoscopic examination is necessarily traumatic in some degree by virtue of the instruments passed, the surface trauma to the mucosa of the upper and lower respiratory tract, the drying effect of the anesthetic gases and of the antropine, and the loss of body heat (p.30).

One final problem of direct laryngoscopy is that the larynx is partially fixed and it is impossible to observe it going through its normal vibration.

#### Rigid Fiberoptic Scope

The right angle scope is very similar to FFN in terms of its operating principles, however, it offers better image resolution than does the flexible scope (Ward et al., 1974). The rigid fiberoptic scope requires that patients protrude the tongue and the scope is then introduced into the patients mouth and oropharynx permitting access to glottal imaging.

The major limitations of the oral endoscope are due to positioning. The position of the rigid scope in the patient's mouth limits normal articulatory movement and often provides limited information on vocal fold movement during speech (Wilson, 1988). As well, patients with hyperactive gag reflexes often do not tolerate the device which reduces the number of patients for whom the device is clinically applicable.

#### Perceptual Assessments

It is generally agreed that a trained ear can often

assist in identification of vocal pathology (Aronson, 1985; Hirano, 1981). Hirano (1981), noted "well trained clinicians are able to determine the causative pathologies of the psychoacoustic perception of abnormal voices. This appears to be analogous to the auscultation of heart and respiratory sounds by physicians" (p.81). The final test of the acceptability of voice is its perceptual acceptability to listeners.

Typically, the abnormal voice is classified and described in terms of its auditory impression through the use of rating scales. Unfortunately, these rating scales and the terminology used are not standardized among clinicians resulting in a confusion over the terminology that is used (Boone, 1983; Brewer & McCall, 1974; Hirano, 1981; Pannbacker, 1984). Pannbacker (1984) provided the example that what is considered hoarseness to one examiner may not be considered hoarseness to another examiner. Blaustein and Bar (1983), in an investigation of the reliability of perceptual voice assessment, suggested that identification of voice disorders based solely on the perceptual judgments of a single listener could be unreliable. In conclusion, although an expert ear is indispensable for detecting and describing the abnormal voice (Aronson, 1985), a reliance upon the vocal disturbance alone does not reliably indicate a laryngeal pathology (Moore, 1964; Brodnitz (1965).

#### Acoustic

Acoustic analysis of voice may be one of the most

attractive methods of assessing phonatory function of laryngeal pathology because it is non-invasive and provides quantitative and qualitative data (Hirano, 1981). Acoustic analysis of the glottal wave provides information about the vocal components of speech and it provides information about the size of the glottis. The glottal wave is derived acoustically through neutralization of vocal tract characteristics by inverse filtering or by a reflectionless tube (Baken, 1987). Baken (1987) noted that while the reflectionless tube is not appropriate for comparison to normal data, it does show abnormalities in the waveform of patients with confirmed pathologies.

#### Flexible Fiberoptic Nasendoscopy

In this section, the advantages and disadvantages of FFN technique will be addressed.

The most appealing characteristic of FFN is that it allows visualization of the larynx during continuous phonation with little disturbance to normal posture and vocal gesture (Baken, 1987; Harris & Collins, 1989; Parnes et al., 1978). FFN allows visualization of the appearance and movement patterns of the vocal folds and it can be quickly and easily performed. FFN can be quickly performed, yet it can also be used in an unhurried manner allowing a more critical examination of laryngeal structures (Ward et al., 1974; Yanagisawa et al., 1981). Patients often prefer FFN over the indirect method using the laryngeal mirror because of

decreased gagging with FFN (Lancer & Jones, 1985).

FFN can also be set up to allow simultaneous voice recording and video imaging which are of tremendous value for patient education and monitoring changes in laryngeal conditions. Replay permits "freezing" of the vocal fold motion for analysis which allows the examiner to detect small, obscure lesions which may be missed otherwise (Yanagisawa, et al, 1981). Simultaneous voice documentation is of particular value for a preoperative and post operative voice analysis of the patient (Yanagisawa et al., 1981). Finally, FFN can be used in treatment as a biofeedback device (McFarlane & Lavarato, 1984). The techniques of ultrahigh speed photography and stroboscopy can be used in combination with the FFN which allow a more detailed analysis of the movement patterns of the vocal folds. One final advantage of FFN is that it uses a cold light supply which allows FFN to be tolerated by the patient for a longer period of time than traditional light sources (Williams et al., 1975).

The advantages of the FFN literally come at a cost. Instrumentation for videonasendoscopy (preferred over simply using the nasendoscope alone) is estimated at \$32,000 Canadian funds (Wilson, 1989, p.5). Therefore, if it is not used extensively, the per patient cost is high which certainly limits the universality of FFN as a clinical tool for evaluating voice patients. Another disadvantage of the FFN technique is that there is some distortion of the laryngeal



image on the TV screen. Harris and Collins (1989) noted : "the image received by the viewer is made up of dots of color one for each fibre, and so resolution of the picture can never be as good as that achieved by a rigid lens system" (p.6). Because of the distortion of laryngeal images on the TV monitor it is often difficult to evaluate color changes and size changes. FFN does require training for performing and interpreting the findings. Mechanical problems with the transmission system (ie: fiber breakage) can also occur. In addition, some patients such as those patients with an omega shape epiglottis are difficult to examine with FFN (Williams et al., 1975). One final disadvantage is that children and infants often do not tolerate the procedure well because the nasendoscope is inserted into their nasal cavity and can be uncomfortable.

**Table 4.1** Comparison of the advantages and disadvantages of indirect and direct techniques of quantifying, qualifying, and observing vocal fold function.

<u>technique</u>	<u>advantages</u>	<u>disadvantages</u>
acoustic	-provides information on the vocal components of speech and information and on the size of the glottis -non-invasive -physician not required	-cannot view vocal -no information on connected speech -does not indicate laryngeal pathology
airflow studies	-provides information on vocal pathology comparison data (Netsell et al.,1984) -physician not required -non-invasive	-pressure tube may interfere slightly with articulation -does not directly view larynx

Table 4.1 cont.d	<u>advantages</u>	<u>disadvantages</u>
cinematography/ ultra high speed photograph	<ul style="list-style-type: none"> <li>-provides a distinctive view of vocal fold movement</li> <li>-slow motion allows observation of finer points of vocal fold movement</li> </ul>	<ul style="list-style-type: none"> <li>-expensive</li> <li>-time consuming</li> <li>-used with laryngeal mirror</li> </ul>
electromyography	<ul style="list-style-type: none"> <li>-provides useful information on muscle functioning</li> </ul>	<ul style="list-style-type: none"> <li>-can be invasive</li> <li>-no direct view of vocal folds</li> <li>-must infer laryngeal function</li> </ul>
electroglottography	<ul style="list-style-type: none"> <li>-non-invasive</li> <li>-information on vibration of vocal folds</li> <li>-diagnosis of pathologies</li> <li>-applications in voice treatment</li> </ul>	<ul style="list-style-type: none"> <li>-validity is questioned</li> <li>-results can be contaminated by body movement</li> </ul>
flexible fiberoptic nasendoscopy	<ul style="list-style-type: none"> <li>-provides a direct view of functioning larynx during continuous phonation</li> <li>-can observe appearance, &amp; movement patterns of vocal folds</li> <li>-can diagnose vocal pathologies</li> <li>-applications as feedback device</li> <li>-can be used for educational purposes</li> <li>-can be used in conjunction with cinematography and stroboscopic imaging</li> <li>-can be set up with videorecording equipment and microphone; allowing records and simultaneous voice recording</li> </ul>	<ul style="list-style-type: none"> <li>-expensive</li> <li>-requires experience to perform and interpret</li> <li>-requires topical anesthetic</li> <li>-invasive</li> <li>-difficult to examine some patients</li> <li>-results can be misleading confusing or invalid</li> <li>-difficult to quantify reliably</li> <li>-entire length of vocal folds not always visible</li> </ul>

Table 4.1 cont.d

indirect

laryngoscopy

advantages

- quick to perform
- provides view of vocal folds
- permits visualization of movement pattern of vocal folds
- can be used in combination with cinematography and stroboscopy

disadvantages

- entire length of vocal folds not always visible
- difficult to examine patients with hyper active gag reflex

laryngoscope

- can visualize of laryngeal structures
- can view larynx of difficult patients such as children and infants
- can diagnose vocal pathologies

- requires local anesthetic
- expensive hospital stay required
- cannot view movement of vocal folds

perceptual

- can provide an indicator of disordered laryngeal function

- not standardized
- confusion over terminology
- interjudge reliability varies
- requires training to learn to use a rating scale
- cannot observe laryngeal function

rigid fiberoptic scope

- illuminates glottal structures permitting observation of appearance and movement

- interferes with oral articulation
- not tolerated well tendency to gag

s/z ratio

- indicator of laryngeal pathology
- quickly performed

- suggests a pathology does not confirm one

stroboscopy

- permits observation of movement of the vocal folds
- can be attached to the flexible fiberoptic nasendoscope

- examiner must be trained in order to make accurate observations
- results can be confusing misleading invalid
- averages many vocal folds cycles
- image can be distorted

Table 4.1 cont.d

	<u>advantages</u>	<u>disadvantages</u>
ultrasound	-provides information on adduction and abduction of the vocal folds	-interpretation requires training

#### Comparison of Nasendoscopy with other Methods of Laryngeal Examination

In comparison of the techniques for laryngeal observation several techniques can be immediately be ruled out for clinical use because they are simply too time consuming, invasive or are not reliable enough to be used clinically. Techniques such as: the s/z ratio, perceptual judgments, acoustic measures, ultrasound, electroglottography, and electromyography provide useful information about laryngeal function, but do not allow diagnosis of a pathological condition. Aerodynamic studies of the larynx allow for diagnosis of pathological conditions, but in the end the only way one can determine with certainty what is happening at the level of the larynx is to observe it more or less directly (Baken, 1987).

The techniques that allow direct visualization include: the indirect method using the laryngeal mirror, the rigid scope, the laryngoscope, and FFN. The indirect method using the laryngeal mirror is acceptable for a cursory examination of the vocal folds, but often only a brief glimpse is provided because patients do not tolerate the procedure well. Similarly, patients have a tendency to gag when using the

rigid scope. Nevertheless, the rigid scope does provide excellent illumination of the glottal structures. Examination with the laryngoscope is required when magnification of the laryngeal mechanism is necessary to performing medical procedures such as a tissue biopsy. The laryngoscope is not a tool that can be used clinically by a speech-language pathologist as it requires a local anesthetic and a hospital admission. In addition, this technique does not provide information on vocal fold movement.

FFN is a mildly invasive technique, yet most patients considered it to be preferable to the indirect evaluation using the laryngeal mirror. FFN provides information on appearance and movement of the vocal folds, thereby, permitting diagnosis of some laryngeal conditions. The procedure can be performed quickly and safely. It is also one of the few techniques that allow visualization of the vocal folds during connected speech.

## CHAPTER FIVE: ISSUES FOR SPEECH-LANGUAGE PATHOLOGISTS PERFORMING NASENDOSCOPY

### Introduction

Clinical examination of the laryngeal mechanism using FFN is a controversial issue among speech-language pathologists. Some speech-language pathologists (Andrews, 1986; Boone, 1983) maintain that evaluation of laryngeal structures is the physician's responsibility, while others (Chapey & Salzberg, 1981; Fisher & Logemann, 1970; Moore, 1964, Wilson, 1988) believe speech-language pathologists should be able to evaluate the vocal mechanism in order to learn how to examine the larynx skillfully so they may observe and describe laryngeal conditions and follow changes in the course of treatment.

This chapter will address the responsibilities and limitations of the speech-language pathologist. Particular attention will be given to the issue of the speech-language pathologist's role in laryngeal examination. The last section of the chapter will include a discussion of the issues specifically related to use of the FFN as clinical tool in voice evaluations.

### Speech-Language Pathologists Role in Laryngeal Examination

Speech-language pathologists are specialists educated in describing and understanding speech and language disorders. The speech-language pathologist is the individual most

knowledgeable to diagnose disorders of speech and language, and to determine the cause and management procedures for these disorders (Nation & Aram, 1984). Physicians, on the other hand, make a medical diagnosis that involves: "establishing the presence or absence of and reasons for a condition, a disease, or other abnormality of structure and function" (Nation & Aram, 1984 p.16).

While speech-language pathologists cannot make a medical diagnosis because the definitive diagnosis of any pathology rests with the appropriate medical personnel, speech-language pathologists should not merely be a passive recipients of a medical diagnosis (Nation & Aram, 1984). The voice clinician's role is not simply that of a technician, rather, the speech-language pathologist has a major role in searching for and identifying probable causes (Chapey & Salzberg, 1981; Nation & Aram, 1984). It is suggested that physicians are responsible for treating:

those conditions that require and are amenable to surgical intervention. But it falls on the speech pathologist to remediate abnormal laryngeal functions (perhaps including those that led to the tissue pathology in the first place) and, therefore, a separate assessment of laryngeal *behavior* by the vocal therapist is in order." (Baken, 1987, p.197).

Presently, there is a trend among practicing voice clinician's towards evaluation of the laryngeal mechanism.

This is particularly true of speech-language pathologists who are working with voice patients in a hospital setting. It is the author's opinion that this practice of laryngeal examination by speech-language pathologist will likely continue. As a result, the profession of speech-language pathology must consider regulating laryngeal evaluation to ensure that only qualified personnel evaluate the laryngeal mechanism. Normal certification requirements for practice in speech-language pathology are not sufficient to train speech pathologists to perform laryngeal examination (Wilson, 1989). Therefore, this author believes laryngeal examination should be restricted to speech-language pathologists who have specialized training to perform specific techniques such as FFN, and more importantly, have specialized training to interpret the findings.

It is the author's opinion that speech-language pathologists should be trained to make observations of laryngeal structure and function in order to monitor laryngeal conditions without frequent recourse to physicians. Speech-language pathologists should not make diagnosis of laryngeal pathology. Diagnosis of laryngeal pathology should only be made by appropriate medical personnel.

In instances where speech-language pathologist make observations of pathological conditions of laryngeal structures, a referral to a physician should be immediate. If speech-language pathologists diagnose pathological conditions



of the larynx they would be liable for misdiagnosis and inappropriate management in much the same way as physicians are presently liable.

Ideally, speech-language pathologists and otolaryngologists should work directly with one another in evaluating voice patients (Brewer & McCall, 1974; Wilson, 1989). Boone (1983) said:

The best voice evaluations are probably those in which the laryngologist and the speech pathologist work together as a team, each providing the assessment data regarding a problem to make the decisions relative to overall management of the problem (Boone, 1983, p.72).

There are numerous advantages to team membership for the speech-language pathologist. For instance, it is believed that widespread use of fiberoptic laryngoscopy by voice clinicians will help improve communication between physicians and speech-language pathologists. This improved communication will heighten the physician's awareness of the speech-language pathologist's area of expertise, and consequently, may increase the number of referrals for voice therapy (Andrews, 1986). An added benefit of ongoing contact between speech pathologists and the laryngologist is that this contact gives the patient a sense of mutual cooperation and smooth decision making between the two disciplines (Aronson, 1985).

#### The FFN Technique; Issues to Consider

Interestingly, in the otolaryngological literature a 1976

article by Rayl reported no real training programs were available for physician's training in nasendoscopy nor was there a specific training requirement, either legally, or by the medical profession (Rayl, 1976). According to Rayl (1976), all that was available at the time was a few scattered seminars for endoscopic training. Programs for teaching endoscopy to physicians were to be designed as a continuing education course for self instruction with a clinical phase during which time the physician would be required to perform the technique and interpret the findings.

Given that physicians receive minimal training in order to perform FFN one could assume that the actual FFN technique is easily learned and could easily be learned by speech pathologists. However, it has been noted several times through out this paper that the interpretive aspects of FFN are complex and speech-language pathologists require considerable training in order to learn to interpret the findings reliably. Nonetheless, the study by D'Antonio et al. (1989) reported earlier, demonstrated that speech-language pathologists can reliably evaluate FFN video tapes. The D'Antonio et al. study suggested speech-language pathologists are often more consistent in their reporting of laryngeal conditions than physicians and otolaryngologists.

In performing FFN the speech-language pathologist must also remember that the technique is an invasive procedure, and ethically speech-language pathologists have a

responsibility to ensure the safety of their patients. However, as noted earlier in Chapter Two, FFN is a safe procedure when used by trained personnel and when safety precautions are taken (Wilson, 1988). A concern with FFN is its limited universality as a clinical tool for evaluating voice patients. Because of the nasendoscope's expense it cannot be justified as a clinical tool unless one can ensure that there is sufficient numbers of clients to justify the expense. FFN does have applications with other communicatively disordered populations such as patients with hypernasal resonance. Therefore, if large numbers of the voice and hypernasal resonance patients were treated by a particular setting, the expense of the FFN set up would be well worth the cost spent because FFN provides invaluable information about these patient's physiologic mechanism.

#### Conclusions

Presently, examination of the laryngeal mechanism by speech-language pathologists could be considered ethically questionable because of the lack of standardized training for speech pathologists performing the technique. The American Speech and Hearing Association ethical proscription I under the Principle of Ethics II states:

Individuals must neither provide services nor supervision of services for which they have not been properly prepared, nor permit services to be provided by any of their staff who are not properly prepared (ASHA, 1988,

p.47)

Because of the above principle of ethics it is imperative, in the authors opinion, that the profession of speech-language pathology require certification in the use and interpretation of nasendoscopy in order to ensure qualified personnel are performing the technique. The ASHA Code of Ethics also states "individuals shall use every resource available including referral to other specialists as needed to best provide the best service." In interpreting this principle the use of FFN as a means of diagnosing patients with voice disorders could be interpreted as using each and every resource available. In conclusion, if speech-language pathologist are to be involved in clinical management of the voice population then we have an ethical responsibility to have first hand knowledge of the involved structures. Wilson (1989) stated:

In an analogous fashion, we as speech pathologists would not take on the responsibility of altering or attempting to rehabilitate a person with an articulation disorder without directly obtaining knowledge of the oral, cognitive, phonologic and genetic history of the individual. In fact, to do so would be practicing in a less than ethical manner. The same applies to voice (p.2).

## CHAPTER SIX: CONCLUSIONS

In chapter one, the discussion began with the increasing demand for accountability in speech-language pathology. It was noted that laryngeal examination is considered vital with voice patients for determining both the etiology of the voice disorder and the course of treatment. This paper served as an overview of the utility of FFN as a clinically useful tool for laryngeal examination that can assist in assessment and management of the voice disordered population. It was noted that laryngeal examination has traditionally been performed by otolaryngologists, however, it was suggested that with proper certification speech-language pathologists could increase accountability for diagnosis and treatment of voice patients if they performed the laryngeal examination and participated in evaluation of laryngeal disorders.

Ideally, assessing the voice disordered population is a combination of both quantitative and qualitative measures. A comprehensive evaluation of all levels of the speech production chain provides the greatest information on voice production (Brewer & McCall, 1974; Hirano, 1975; Ludlow & Hart, 1981; Netsell et al., 1984; Sawashima & Hirano, 1981). A multilevel test battery such as the one suggested by Netsell et al. (1984) that combines: 1) a detailed case history, 2) listener evaluations, 3) aerodynamic study, and 4) video nasendoscopy would significantly improve most speech-language pathologists diagnostic protocol for evaluations of the voice

disordered.

Often, purchase of expensive equipment such as FFN is not feasible unless a setting has the clinical population to support the expense. Therefore, in such settings it would be ideal if a referral system could be set up in an urban medical centre allowing speech-language pathologists to refer voice patients throughout the province or state for nasendoscopic assessment of the laryngeal structures.

It is becoming increasingly important that we have access to a technique such as nasendoscopy if we are to become more accountable for management of the voice disordered population. (Chapey & Salzberg, 1981; Wilson, 1988). It was suggested that:

To ignore the development of this technology and continue with purely acoustic analysis of the vocal folds and their part in voice management is an ethically questionable approach. We should strive to exploit the technical advances that enhance the efficacy of our service (Wilson, 1988, p.166).

## REFERENCES

- Andrews, M., (1986). Voice Therapy for Children. New York: Longman Inc.
- Aronson, A., (1985). Clinical Examination of Voice Disorders. Clinical Voice Disorders ( 2nd ed.). New York: Theime Inc. (p. 251-270).
- American Speech and Hearing Association. (1988). Code of Ethics of the American Speech-Language Hearing Association, ASHA, 30, 47-48.
- Baken, R.J., (1987). Clinical Measurement of Speech and Voice. Boston: Little, Brown and Company.
- Batch, A., (1985). The role of fiberoptic oesophagogastroscopy in E.N.T practice. The Journal of Laryngology and Otology, 99, 783-791.
- Benjamin, B., (1981). Atlas of paediatric endoscopy upper: respiratory tract and oesophagus. New York: Oxford University Press.
- Blaustein, S., & Bar, A. (1983). Reliability of perceptual voice assessment, Journal of Communication Disorders, 16, 157-161.
- Boone, D.R., (1980). Voice disorders, In T. Hixon, L. Shrieberg, & J.Saxman (Eds.), Introduction to Communication Disorders. Englewood Cliffs, NJ.: Prentice Hall.
- Boone, D. R., (1983). The Voice And Voice Therapy. Englewood Cliffs, NJ: Prentice-Hall Inc..
- Brewer, D., & McCall, G. (1974). Visible changes during voice therapy, Annals of Otology Rhinology and Laryngology, 83, 423-427.
- Brodnitz, F., (1984). Vocal Rehabilitation. MN: American Academy of Opthamology and Otolaryngology.
- Chapey, R., & Salzberg, A. (1981). The speech clinician's use of fiberoptics in indirect laryngoscopy. Journal of Communication Disorders, 14, 87-90.
- D'Antonio, L., Marsh, J., Province, M., Muntz, H., & Phillips, C. (1989). Reliability of flexible fiberoptic nasopharyngoscopy for evaluation of velopharyngeal function in a clinical population. Cleft Palate Journal, 26, 217-225.

- Eckel, F., & Boone, D. (1981). The s/z ratio as an indicator of laryngeal pathology, Journal of Speech and Hearing Disorders, 46, 147-149.
- Fisher, H., & Logemann, J. (1970). Objective evaluation of therapy for vocal nodules: a case report, Journal of Speech and Hearing Disorders, 35, 277-285.
- Fourcin, A. (1974). Laryngographic assessment of phonatory function. In Wyke, B. (Ed.) Ventilatory and Phonatory Control Systems. New York: Oxford University Press 315-333.
- Fourcin, A. (1981). Laryngographic assessment of phonatory function. In Ludlow, C.L., & Hart, M.O. (Eds.). Proceedings of the Conference on the Assessment of Vocal Pathology, ASHA Reports, 11, 116-127.
- Fourcin, A., & Abberton, E. (1976). The laryngograph and the voicscope in speech therapy. Proceedings of the 16 International Congress of Logopedics and Phoniatrics, 116-122.
- Gay, T., Harris, K., (1971). Some recent developments in the use of electromyography in speech research. Journal of Speech and Hearing Research, 14, 241-246.
- Gay, T., Hirose, H., Strome, M., & Sawashima, M. (1972). Electromyography of the intrinsic laryngeal muscles during phonation. Annals of Otology, 81, 401-409.
- Gleeson, M., Siodlak, M., & Wengraf, C. (1985). Fibre optic guided nasal intubation-shouldn't we be the experts?. The Journal of Laryngology and Otology, 99, 775-778.
- Harris, T., & Collins, S. (1989). The voice clinic: tools of the trade. The College of Speech Therapists Bulletin, 448, 6-9.
- Hirano, M., (1975). Phonosurgery: basic and clinical investigations. Otologia (Fukoka) 21 (suppl.1) 239-240.
- Hirano, M., (1981). Clinical Examination of the Voice, In G.E. Arnold, F. Winkel, & B.D. Wyke (Eds.), New York: Springer-Verlag.
- Hirano, M., & Ohala, J. (1969). Use of hooked-wire electrodes for electromyography of the intrinsic laryngeal muscles. Journal of Speech and Hearing Research, 12, 362-373.
- Lancer, I. & Jones, A. (1985). Flexible fiberoptic rhinolaryngoscopy. The Journal of Laryngology and Otology, 99, 771-773.



- Lancer, I., & Moir, A. (1985). The flexible fiberoptic rhinolaryngoscope, The Journal of Laryngology and Otology, 99, 767-770.
- Ludlow, C., & Hart, M. (1981). Proceedings of the conference of assessment of vocal pathology. American Speech-Language Hearing Association Report No. 11, Rockville, Maryland.
- McFarlane, S., & Lavarato, A. (1984). The use of video endoscopy in evaluation and treatment of dysphonia. Communication Disorders, 9, (8), 117-126.
- Moore, G.P. (1971). Voice Disorders Organically Based, In L. E. Travis (ed.), Handbook of Speech Pathology and Audiology. New York: Appelton-Century-Crofts.
- Moore, P. (1964). Organic Voice Disorders. Engelwood Cliffs, NJ: Prentice-Hall.
- Nation, J., & Aram, D., (1984). Diagnosis as a professional activity. Diagnosis of Speech and Language Disorders (2nd ed.). San Diego: College-Hill Press, Inc.
- Netsell, R., Lotz, W., & Shaughnessy, A., (1984). Laryngeal aerodynamics associated with selected voice disorders. American Journal of Otolaryngology, 5 (6), 397-403.
- Pannbacker, M. (1984). Classification Systems of Voice Disorders: A Review of the Literature, Language, Speech and Hearing Services in Schools, 15, 169-174.
- Parnes, S., Lavarato, A., & Myers, E. (1978). Study of dysphonia using videofiberoptic laryngoscopy, Annals of Otology, 87, 322-326.
- Perkins, W., (1971). Vocal function: assessment and therapy, In L.E. Travis (Ed.) Handbook of Speech Pathology and Audiology, Englewood Cliffs, NJ: Prentice-Hall, 505-534.
- Prater, R., & Swift, R. (1984). Manual of Voice Therapy, Toronto: Little Brown and Company.
- Rayl, J. (1976). Educational Training in Endoscopy, Annals of Otology, 85, 627-630.
- Reed, C. (1980). Voice Therapy: A Need for Research. Journal of Speech and Hearing Disorders, 45, 157-169.
- Reed, V., (1982). The electroglottograph in voice teaching. In Lawrence, V.L., (Ed). Transcripts of the tenth symposium on care of the professional voice. New York: The voice Foundation.

- Rubow, R., & Swift, E. (1985). A microcomputer based warble biofeedback device to improve transfer of treatment in parkinsonian dysathria following EMG biofeedback. Journal of Speech and Hearing Disorders, 49, 26-33.
- Rosenbeck, J., & Lapointe, L. (1978). The dysarthrias: description, diagnosis and treatment. In D.F. Johns (Ed.) Clinical Management of Neurogenic Communicative Disorders, Boston: Little, Brown and Company.
- Sawashima, M., Abramson, A.S., Cooper, F.S., & Lisker, L. (1970). Observing laryngeal adjustments during running speech by use of fiberoptic system. Phonetica, 22, 193-201.
- Sawashima, M., & Hirano, M. (1981). Clinical evaluation of voice disorders. Annu Bull Res Inst Logoped Pjonia 15 165-171.
- Sawashima, M., & Hirose, H. (1968). A new laryngoscopic technique by use of fiberoptics. Journal of the Acoustical Society of America, 43, 168-169.
- Selkin, S. (1984) Other clinical applications of flexible fiberoptic endoscopy, Cleft Palate Journal, 21 (1), 29-32.
- Silberman H., Wilf, H., & Tucker J.A (1976) Flexible Fiberoptic Nasopharyngolaryngoscope, Annals of Otology, 85, 640-645.
- Smitheron, J., & Hixon, T. (1981). A clinical method for estimating laryngeal airway resistance during vowel production, Journal of Speech and Hearing Disorders, 46, 138-146.
- Ward, P., Berci, G., & Calcaterra, T. (1974). Advances in Endoscopic Examination of the Respiratory System, Annals of Otology, 83, 754-760.
- Williams, G., Farquharson, I., & Anthony, J. (1975). Fiberoptic laryngoscopy in the assessment of laryngeal disorders, Journal of Laryngology and Otology, 89, 299-316.
- Wilson, F. (1989). (Ad Hoc Committee on Extended Practice Issues in Endoscopy in Voice and Resonance). unpublished paper.
- Wilson, F. (1988). The importance of laryngeal visualization in voice management. In S. Gerber & G. Mencher (Eds.), Speech Pathology and Audiology: An International Perspective (pp.130-167).

Wilson, F., Kudryk, W., & Sych, J. (1986). The development of flexible fiberoptic video Nasendoscopy (FFVN): Clinical teaching-research applications, ASHA, 28(11), 25-30.

Wilson, F., & Rice, M. (1977). A programmed approach to voice therapy. Austin: Learning Concepts.

Yanagisawa, E., Cassuccio, J. R., & Suzuki, M. (1981). Video laryngoscopy using a rigid telescope and video home system, Annals of Otology, 90, 346-350.