

Finger Asisted Laparoscopic Renal Cyst Excision A Simple Technique

Mete Kilciler, Mustafa Okan Istanbuluoğlu, Şeref Basal, Selahattin Bedir, Ali Avcı,
Yaşar Özgök

Purpose: Simple renal cysts are asymptomatic incidental findings; however, for a small subset of benign renal cysts, patients may present with pain, hematuria, recurrent infection, pyelocaliceal obstruction, or hypertension. Laparoscopic cyst ablation is an effective minimally invasive modality for the treatment of symptomatic benign renal cysts. We describe a simple laparoscopic cyst excision technique.

Materials and Methods: Between June 2003 and May 2008, 28 patients underwent laparoscopic renal cyst excision via retroperitoneal approach. In our technique, retroperitoneum and Gerota's fascia were dissected with finger blindly before insertion of the trocars to the retroperitoneal space. Following finger dissection, 3 trocars were placed and the cyst walls were excised at the level of renal cyst and base of the cysts were cauterized with electrocautery scissors.

Results: Mean patients' age was 59.3 years (range, 31 to 72 years). Mean operation duration time was 46 minutes (range, 27 to 102 minutes). Symptomatic and radiological success were achieved in 26 (92.8%) and 27 (96.4%) patients, respectively, with a median follow-up of 28 months (range, 6 to 56 months). No serious complications were encountered.

Conclusion: Laparoscopy is a versatile minimally invasive modality ideal for treating benign symptomatic renal cysts. According to our experience, we think that the finger assisted laparoscopic cyst excision is an easy and non-invasive procedure.

Keywords: dissection, laparoscopy, cystic renal disease, retroperitoneal space

*Urol J. 2010;7:90-4.
www.uj.unrc.ir*

INTRODUCTION

Simple renal cysts are the most common benign lesions of the kidney. In recent years, with the increasing use of diagnostic tools such as ultrasonography and computed tomography, the number of renal cysts diagnosed increased dramatically although most of them do not require treatment. The treatment indications for renal cysts are abdominal and/or flank pain, hematuria, hypertension, recurrent urinary infection, and obstruction

in the collecting system due to compression.⁽¹⁻¹¹⁾

Open surgery had been successfully performed for the treatment of symptomatic renal cysts, but in this case morbidity increased while patient satisfaction decreased.⁽¹⁻¹¹⁾ Percutaneous cyst aspiration is one of the most common treatment modalities.^(1,2,5,6,10,11) There had been some modifications regarding cyst aspiration such as injecting sclerosing material into

*Gulhane Faculty of Medicine,
Department of Urology,
Ankara, Turkey*

*Corresponding Author:
Mustafa Okan Istanbuluoğlu, MD
Gulhane Askeri Tıp Akademisi,
Uroloji Bölümü 06018 Etilik,
Ankara, Turkey
Tel: +90 312 304 5610
Fax: +90 332 257 0637
E-mail: drokanist@yahoo.com*

*Received August 2009
Accepted February 2010*

the cysts,^(2,6,8) but high treatment failure and recurrence rates have been reported.^(4,8-11) On the other hand, laparoscopic renal cyst excision, which was first described by Hulbert in 1992, is an effective and minimally invasive treatment method that is commonly used.^(1,3,4,9-11) Finger assisted laparoscopic cyst excision method that we describe below, decreases the operation time and morbidity.

MATERIALS AND METHODS

Finger assisted retroperitoneal laparoscopic approach was performed on 28 patients with symptomatic renal cysts who referred to our clinic between June 2003 and May 2008. Preoperatively, all patients were evaluated with urine analysis, urine culture, renal ultrasonography, and abdominal computed tomography. Bosniak class 3-4 renal cysts, cysts located at the parapelvic regions, multiple cysts, and patients with history of previous renal surgery were excluded from the study. Since obesity was an obstacle to performing the procedure, obese patients were also excluded from the study.

Patients were placed in the lateral decubitus position under general anesthesia. Three trocars were used. A 1.5 to 2 cm incision was performed on the midaxillary line, and the muscles and the transversalis fascia were dissected blindly with finger. The peritoneum was swept medially. The Gerota's fascia over the cyst was dissected carefully, avoiding rupture of the cyst and the adipose tissue was visualized as much as possible. Then, a second incision was performed on the anterior axillary line under digital guidance. The muscles and the transversalis fascia were dissected blindly with finger once more, and a second finger was used for this procedure (Figures 1 and 2). The third trocar was placed at the junction of the lateral border of the erector spinae muscle underside the 12th rib (posterior axillary line). The retroperitoneal dissection was performed with balloon dissectors, which was inflated 600 cc maximally.

Following CO₂ insufflation, a 10-mm trocar was inserted in the first incision and 30° telescope was placed through this trocar. The other trocars

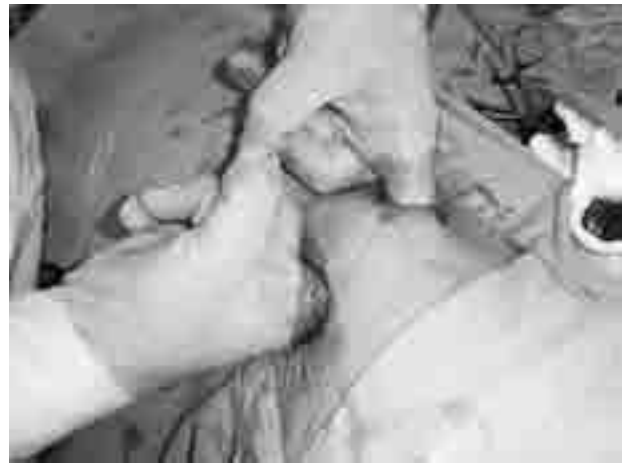

Figure 1. Operative image of the bilateral finger assisted laparoscopic renal cyst excision.

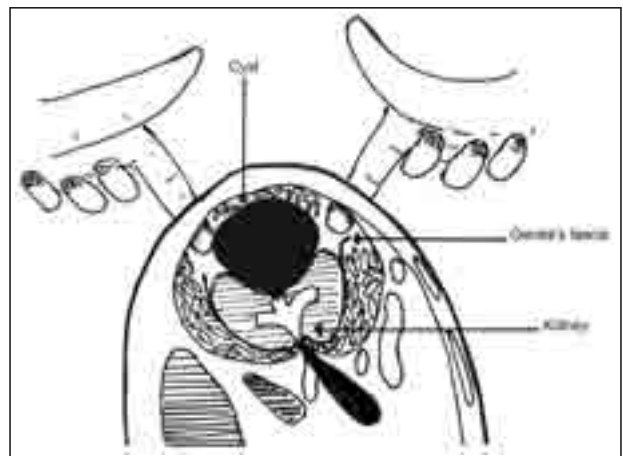


Figure 2. Illustration of bilateral finger dissection of Gerota's fascia and perirenal fat tissue.

used in the operation were 5-mm trocars. It was observed through the telescope whether sufficient dissection of the perirenal tissue was performed. The pressure was kept at 12 to 14 mmHg during the operation. The cyst wall was excised at the level of renal capsule and the base of renal cyst was fulgurised after excision to destroy the secretory activity of the residual cyst wall and to avoid recurrence. The excised cyst wall was pathologically evaluated.

RESULTS

Twenty-two men and 6 women with the mean age of 59.3 years (range, 31 to 72 years) were operated on. Twelve cysts were located on the right side and 16 were on the left side. Nineteen cysts were located in the lower pole and 9 were

located in the middle portion of the kidney. The cysts were laterally and posteriorly localized in 15 and 13 patients, respectively. Twenty-two cysts were Bosniak class 1, while 6 cysts were Bosniak class 2. The mean diameter of cysts measured with computed tomography was 7.6 cm (range, 6 to 14 cm).

The treatment indications were obstruction in the collecting system in 12 patients and pain that was unresponsive to analgesics in 16 patients. Thirteen patients had history of previous unsuccessful cyst aspiration at other institutions (Table). In all of the patients, the operation was performed with 3 ports. The mean operation duration was 46 minutes (range, 27 to 102 minutes). Any major bleeding requiring transfusion did not occur. Blunt dissection of the renal fat tissues caused minor bleeding, but it did not lead to any significant sight impairment during the procedure. The mean hospitalization was 1.7 days (range, 1 to 4 days). All the drains were removed on the first postoperative day. Two patients had pain that was unresponsive to nonsteroidal analgesics during the postoperative period. Thus, they were treated with narcotic analgesics. Two patients had prolonged fever that was treated with parenteral antibiotics for 3 days. Pathological evaluation of all cysts was reported as benign. No other serious complications were encountered.

The mean follow-up was 28 months (range, 6 to 56 months). Follow-up was performed with

renal ultrasonography on postoperative 3-, 6-, and 12-month in the first year, then annually. Symptomatic improvement was achieved in 26 patients (92.8%) while radiological recurrence was reported only in 1 patient (96.4% radiological success).

DISCUSSION

Simple renal cyst is common in adults and the incidence increases with age. Till the age of 40, simple renal cyst has been reported in 20% of adults, while at the age of 60, the incidence increases to 30 to 35%.^(1,7) The cysts are mostly asymptomatic. Bleeding, pain refractory to analgesics, hypertension, unresolved infection, and compression to the collecting system are the indications for the treatment. A very small subset of patients with renal cyst need intervention.⁽¹⁻¹¹⁾

The percutaneous cyst aspiration is non-invasive and there is no need for hospitalization; thus, percutaneous cyst aspiration is the first choice of treatment, but recurrence rates were reported to be up to 78%.⁽¹¹⁾ Many sclerosing agents were used as a combination to increase the effectiveness of the percutaneous treatment such as ethanol, tetracycline, glucose phenol, povidone-iodine, bismuth-phosphate, urea cholehydrolytate, polidocanol, and pantopaque.^(2,5,6,8) There have been some successful reports in the literature upon the usage of sclerosing agents, but on the other hand, the recurrence rates still range from 32% to 100%.^(4,9,11) Sclerosing agents had been used in repeated sessions to increase the effectiveness although they had potential side effects such as migration to the collecting system, allergy, and anaphylaxis.^(4,9) Chung and colleagues compared 40 patients that had been treated with multiple 99% ethanol injections via a pigtail catheter inserted into the cyst, with 42 patients who were treated with single session injections. The multiple session treatment was reported to be more effective.⁽¹²⁾ Okeke and associates also revealed that the multiple session treatment was superior to single session. But 2 to 3 days hospitalization and discomfort caused by the catheter are disadvantages of multiple treatments.⁽¹³⁾ The only study in the literature that compares the percutaneous treatment with

Patients Characteristics

Male/Female	22/6
Mean Age	59.3 years (31 to 72 years)
Side	
Right	12 (42.8%)
Left	16 (57.2%)
Cyst Size (mean)	7.6 cm (6 to 14 cm)
Localization	
Middle	9 (2.1%)
Lower	19 (67.9%)
Previous surgery	
Percutaneous aspiration	13 (46.4%)
None	15 (53.6%)
Indication for operation	
Pain	16 (57.2%)
Obstruction in the collecting system	12 (42.8%)
Procedure	Retroperitoneal

laparoscopic excision was reported by Okeke and coworkers in which they concluded that laparoscopic treatment is a better option.⁽⁵⁾

Open surgery is the most effective treatment for the renal cysts and has been performed since the beginning of the 20th century.⁽¹⁾ Laparoscopic procedures have replaced open surgery due to its high morbidity. Laparoscopy is now being performed in many centers. In the literature, symptomatic progression of the patients with laparoscopic surgery is 78% to 100%, and the radiological treatment rates are 80% to 100%. The mean operation duration differ from 75 to 194 minutes.^(1,9-11) In our series, the symptomatic and the radiological success rates were 92.8% and 96.4%, respectively, which are compatible with the literature, but the mean operation duration is shorter than those previously reported. With laparoscopy, we performed minimal retroperitoneal dissection to reach the renal cyst that resulted in minimum postoperative pain. “Short operation period” term describes decreased anesthetic gas usage and decreased systemic toxicity.

Hulbert performed the first laparoscopic cyst excision 16 years ago.⁽³⁾ Thwaini and colleagues reported that of a total of 22 patients with renal cysts, 17 (77%) fully recovered, with a radiological success rate of 100% (mean follow-up of 60 months).⁽⁹⁾ Shiraishi and coworkers also showed that in 36 patients treated with laparoscopic cyst excision, symptomatic and radiologic success rates were 92% and 81%, respectively, after a mean follow-up of 69 months (range, 13 to 128 months).⁽¹⁰⁾ In the series of 45 patients, Atug and associates reported 91.1% symptomatic and 95.5% success rates (mean follow-up of 39 months, ranging from 3 to 96 months).⁽¹¹⁾ The long-term follow-up studies demonstrate that laparoscopic cyst excision is an effective treatment.

Another important issue in laparoscopic surgery is the approach route which can be transperitoneal or retroperitoneal. The transperitoneal approach is the most preferred one in the published literature. Transperitoneal approach has advantages especially for the anteriorly located exophytic and parapelvic cysts. In addition, anatomical landmarks help us to

reach the kidney easily. However, retroperitoneal way is beneficial especially for the posteriorly located cysts. The organ injury is less compared to transperitoneal approach and there is no risk of peritonitis, as the intracystic fluid does not interact with the peritoneum.⁽¹⁾ In our study, we preferred the retroperitoneal approach. If the location of the cysts is favorable, we recommend retroperitoneal approach, which has lower morbidity.

CONCLUSION

Laparoscopy is a versatile minimally invasive modality ideal for treating benign symptomatic renal cysts. According to our experience, we think that the finger assisted laparoscopic cyst excision is an easy, non-invasive, and not time consuming procedure. However, it is better to evaluate this technique with further prospective studies that are matched with control group.

CONFLICT OF INTEREST

None declared.

REFERENCES

1. Su LM. Laparoscopic renal cyst ablation: Technique and results. In: Gill IS, ed. Textbook of laparoscopic urology. New York: Taylor & Francis Ltd; 2006:259-78.
2. Demir E, Alan C, Kilciler M, Bedir S. Comparison of ethanol and sodium tetradecyl sulfate in the sclerotherapy of renal cyst. *J Endourol.* 2007;21:903-5.
3. Hulbert JC. Laparoscopic management of renal cystic disease. *Semin Urol.* 1992;10:239-41.
4. Gupta NP, Goel R, Hemal AK, Kumar R, Ansari MS. Retroperitoneoscopic decortication of symptomatic renal cysts. *J Endourol.* 2005;19:831-3.
5. Okeke AA, Mitchelmore AE, Keeley FX, Timoney AG. A comparison of aspiration and sclerotherapy with laparoscopic de-roofing in the management of symptomatic simple renal cysts. *BJU Int.* 2003;92:610-3.
6. Kilinc M, Tufan O, Guven S, Odev K, Gurbuz R. Percutaneous injection sclerotherapy with tetracycline hydrochloride in simple renal cysts. *Int Urol Nephrol.* 2008;40:609-13.
7. Laucks SP, Jr., McLachlan MS. Aging and simple cysts of the kidney. *Br J Radiol.* 1981;54:12-4.
8. Madeb R, Feldman PA, Knopf J, Rub R, Erturk E, Yachia D. Povidone-iodine sclerotherapy is ineffective in the treatment of symptomatic renal cysts. *J Endourol.* 2006;20:402-4.

9. Thwaini A, Shergill IS, Arya M, Budair Z. Long-term follow-up after retroperitoneal laparoscopic decortication of symptomatic renal cysts. *Urol Int.* 2007;79:352-5.
10. Shiraishi K, Eguchi S, Mohri J, Kamiryo Y. Laparoscopic decortication of symptomatic simple renal cysts: 10-year experience from one institution. *BJU Int.* 2006;98:405-8.
11. Atug F, Burgess SV, Ruiz-Deya G, Mendes-Torres F, Castle EP, Thomas R. Long-term durability of laparoscopic decortication of symptomatic renal cysts. *Urology.* 2006;68:272-5.
12. Chung BH, Kim JH, Hong CH, Yang SC, Lee MS. Comparison of single and multiple sessions of percutaneous sclerotherapy for simple renal cyst. *BJU Int.* 2000;85:626-7.
13. Okeke AA, Mitchelmore AE, Timoney AG. Comparison of single and multiple sessions of percutaneous sclerotherapy of simple renal cysts. *BJU Int.* 2001;87:280.

EDITORIAL COMMENT

Renal cyst is a common finding among old age population; however, few cases require intervention. Percutaneous aspiration and sclerosing agents injection are the first option for treatment.⁽¹⁾ Laparoscopic cyst decortication is an appropriate alternative for management of parapelvic cysts and recurrent symptomatic cysts after percutaneous aspiration.⁽²⁾ However, based on my experience, there is a large amount of fibrosis and adhesion surrounding the cyst in patients with the previous history of aspiration. As mentioned in this paper, laparoscopic cyst ablation needs general anesthesia and hospitalization, while percutaneous aspiration is an outpatient less invasive procedure. Authors selected posterior and lateral renal cysts that are easily accessible by percutaneous aspiration; however, success rate in laparoscopic cyst ablation is higher than percutaneous procedure.

In most cases, although cysts were not completely disappeared after percutaneous aspiration and sclerosing agents injection, but their size reduced and patients' problems resolved.⁽³⁾ I think that their technique is simple and minimally invasive with short operation time, but I recommend comparing this technique with classic laparoscopic cyst ablation in a prospective controlled study with long-term follow-up.

Akbar Nouralizadeh

*Urology and Nephrology Research Center, Shahid Labbafinejad Medical Center, Shahid Beheshti University, MC, Tehran, Iran
E-mail: nouralizadeh@yahoo.com*

REFERENCES

1. Demir E, Alan C, Kilciler M, Bedir S. Comparison of ethanol and sodium tetracycl sulfate in the sclerotherapy of renal cyst. *J Endourol.* 2007;21:903-5.
2. Abbaszadeh S, Taheri S, Nourbala MH. Laparoscopic decortication of symptomatic renal cysts: experience from a referral center in Iran. *Int J Urol.* 2008;15:486-9.
3. Chung BH, Kim JH, Hong CH, Yang SC, Lee MS. Comparison of single and multiple sessions of percutaneous sclerotherapy for simple renal cyst. *BJU Int.* 2000;85:626-7.

REPLY BY AUTHOR

Editorial comment includes valuable personal experience leading to comparisons between alternative procedures, together with positive suggestions. We will take these recommendations into consideration in our future studies.

Mete Kilciler

Gulhane Faculty of Medicine, Department of Urology, Ankara, Turkey