

# Kansas Agricultural Experiment Station Research Reports

---

Volume 0  
Issue 1 *Cattleman's Day (1993-2014)*

Article 522

---

1998

## Early detection of problem implants using infrared thermography

M.F. Spire

J.C. Galland

James S. Drouillard

Follow this and additional works at: <https://newprairiepress.org/kaesrr>



Part of the [Other Animal Sciences Commons](#)

---

### Recommended Citation

Spire, M.F.; Galland, J.C.; and Drouillard, James S. (1998) "Early detection of problem implants using infrared thermography," *Kansas Agricultural Experiment Station Research Reports*: Vol. 0: Iss. 1. <https://doi.org/10.4148/2378-5977.1925>

This report is brought to you for free and open access by New Prairie Press. It has been accepted for inclusion in Kansas Agricultural Experiment Station Research Reports by an authorized administrator of New Prairie Press. Copyright 1998 Kansas State University Agricultural Experiment Station and Cooperative Extension Service. Contents of this publication may be freely reproduced for educational purposes. All other rights reserved. Brand names appearing in this publication are for product identification purposes only. No endorsement is intended, nor is criticism implied of similar products not mentioned. K-State Research and Extension is an equal opportunity provider and employer.



---

## Early detection of problem implants using infrared thermography

### Abstract

Thermal imaging of feedlot cattle ears is a noninvasive diagnostic tool that aids in identifying properly placed or abscessed growth-promoting implants. Thirty-two calves were used to determine if abscessed and normal, functional implants could be identified and differentiated using infrared thermography. Infrared images were taken at implantation on days 2, 4, 7, 14, and 21 after implantation. Abscessed implants were easily identified. Use of thermal imaging can verify implant administration and, thus, has the potential to immediately impact feedlot quality assurance programs.

### Keywords

Kansas Agricultural Experiment Station contribution; no. 97-309-S; Report of progress (Kansas State University. Agricultural Experiment Station and Cooperative Extension Service); 804; Cattlemen's Day, 1998; Beef; Infrared thermography; Feedlot cattle

### Creative Commons License



This work is licensed under a [Creative Commons Attribution 4.0 License](https://creativecommons.org/licenses/by/4.0/).

## EARLY DETECTION OF PROBLEM IMPLANTS USING INFRARED THERMOGRAPHY<sup>1</sup>

*M. F. Spire<sup>2</sup>, J. C. Galland<sup>2</sup>,  
and J. S. Drouillard*

---

### Summary

Thermal imaging of feedlot cattle ears is a noninvasive diagnostic tool that aids in identifying properly placed or abscessed growth-promoting implants. Thirty-two calves were used to determine if abscessed and normal, functional implants could be identified and differentiated using infrared thermography. Infrared images were taken at implantation on days 2, 4, 7, 14, and 21 after implantation. Abscessed implants were easily identified. Use of thermal imaging can verify implant administration and, thus, has the potential to immediately impact feedlot quality assurance programs.

### Introduction

Problem implants in fed cattle result in economic losses ranging from \$2.70 to \$4.94 per head implanted. Much of the observed loss is attributed to abscessed implants, missing implants and improper implantation technique that causes variation in the surface area of the implant. Factors affecting implant surface area will alter product release. The full extent of the problem rate can be assessed only by observing 100% of implant sites 7 to 21 days after implanting. The repeated handling of feedlot cattle necessary for 100%

inspection is a major drawback for correcting problem implants. Infrared thermography can remotely and non-invasively detect problem implants. This experiment was designed to determine if variation over time exists in the thermographic appearance of ears implanted with normally functioning growth-promotant implants and improperly functioning abscessed implants.

### Experimental Procedures

A total of 32 calves was assigned randomly to one of two treatment groups. Group A (normal implant) received a Synovex-Plus implant following disinfection of the ear. Group B (abscessed implant) received a Synovex-Plus implant in which the ear and the implant needle were contaminated with fecal material. Half of each treatment group received the implant in the left ear. The remaining calves were implanted in the right ear. The nonimplanted ear on each calf served as the control for thermographic comparisons. Thermographic images of the front and back of the ears of each calf were obtained on trial days 0, 2, 4, 7, 14, and 21 using an Amber Engineering Radiance PM, high resolution, shortwave length (3-5  $\mu\text{m}$ ), radiometric, infrared, thermal-imaging unit. All thermographic images were taken from a

---

<sup>1</sup>The authors express their appreciation to Ft. Dodge Animal Health for providing grant support of this research.

<sup>2</sup>Food Animal Health and Management Center, College of Veterinary Medicine

distance of about 3 ft, with the animal in standing restraint in a hydraulic squeeze chute. Temperature measurements were determined from an area on the front of the ear or on the back of the ear at the base, middle, and tip.

A randomized, complete block design was used to investigate the thermographic patterns of cattle with normal, functional growth-promotant ear implants vs. cattle with abscessed implants. Repeated measures analysis of variance was used to determine the relationships among distribution of temperature for the entire ear and the zone surrounding the implant (the response variables) and treatment; pen; treatment×pen interaction; time, treatment×time interaction; and side (ear) of placement (the explanatory variables) for the front, back, and front/back of each implanted ear. Mean temperatures between normal implants vs. abscessed implants were contrasted.

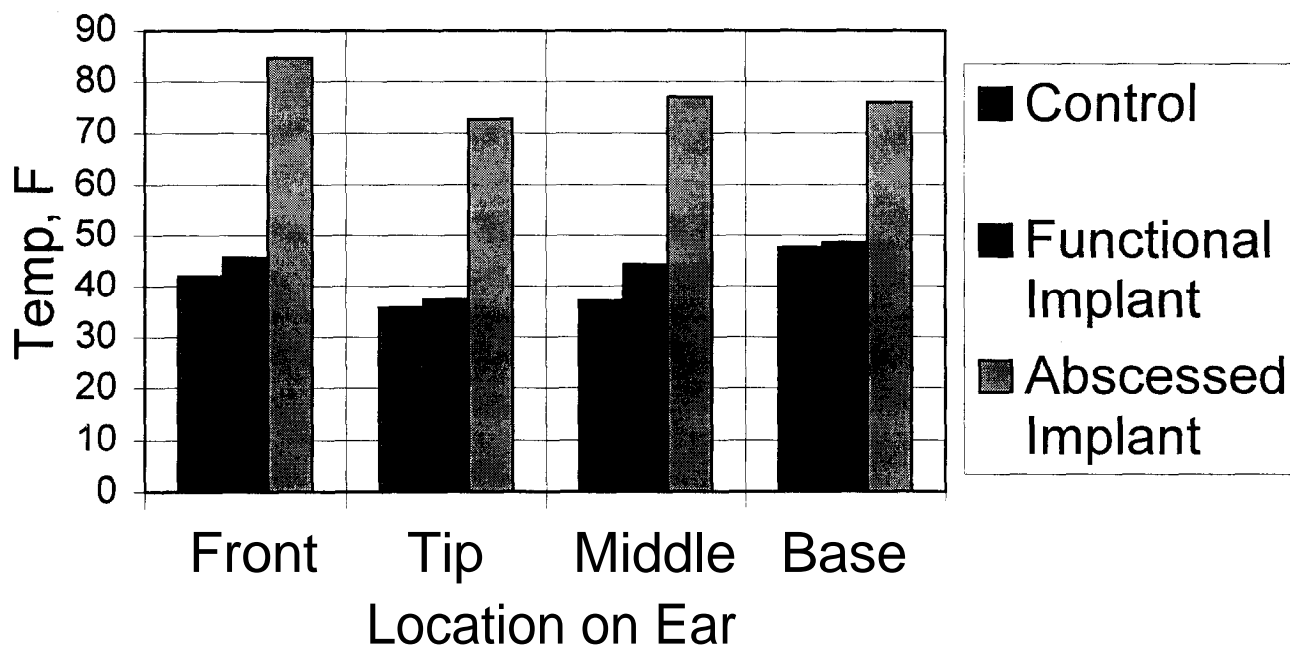
### **Results and Discussion**

Images of the front or back of the ear were comparable on postimplantation days 2, 4, 7, and 14 when used to differentiate abscessed ears from the nonimplanted ear. The side (left or right) of implantation did not affect detection of abscessed vs. functional implants. Thermal imaging the front of the ear detected the difference between an abscessed implant and a functional implant on postimplantation days 2, 4, 7, and 14 ( $P<.001$ ). Abscessed implanted ears imaged from the front were found to be  $32.9^{\circ}\text{F} \pm 5.02$  warmer than functional implanted ears on day 4.

Image of the back of the ear detected temperature differences between abscessed and

functional implanted ears on postimplantation days 4 and 7 ( $P<.001$ ). Thermography also detected temperature differences between functional implanted ears and nonimplanted control ears on day 2 postimplantation using images of either the front or back and on day 4 when the ear was viewed from the rear. Figure 1 demonstrates the least square mean temperatures of abscessed implanted ears, functional implanted ears, and nonimplanted control ears on day 4 postimplantation at various locations on the ear.

Thermal imaging is a remote, non-invasive tool capable of detecting temperature differences between functional implanted, abscessed implanted, and non-implanted ears. Thermal imaging within the first 2 weeks after arrival in the feedyard or at reimplanting after 60-70 days is a useful tool that can aid in identifying properly placed or abscessed growth-promoting implants placed in the ears of feedlot cattle. Its use to assess the efficiency of implanting by processing crews has the potential to immediately impact quality assurance programs. Far greater potential lies in the ability of thermal imaging to differentiate between functional implants and nonfunctional (abscessed or missing) implants in the pen (Figure 2). Once identified, cattle with nonfunctional implants can be reimplanted and returned immediately to their home pen with a functional implant.



**Figure 1. Least Square Mean Temperatures by Location on Ear, Day 4 Only, for Abscessed Implanted Ears, Functional Implanted Ears, and Nonimplanted Control Ears.**



**Figure 2. Thermal Image of Feedlot Heifers Taken in Pen. Heifer in Foreground Has a Functional Implant in Right Ear (4.0°F Warmer than Right Ear). Heifer in Background Has an Abscessed Implant in Left Ear (17.7°F Warmer than Left Ear). (Black=cold, White=hot).**