

**DIFFERENTIAL DIAGNOSIS OF PARKINSONISM AND
TREMOR DISORDERS: BASAL GANGLIA IMAGING WITH A
NOVEL ISOTOPE**

BY

HANI TAHA SHERIF BEN AMER

**A thesis submitted for the degree of Doctor of Philosophy in the Department of
Neurology, Faculty of Medicine, University of Glasgow.**

October 1999

**Department of Neurology
Institute of Neurological Sciences
Southern General Hospital
Glasgow G51 4TF**

© Hani Taha Sherif Ben Amer 1999

ProQuest Number: 13832529

All rights reserved

INFORMATION TO ALL USERS

The quality of this reproduction is dependent upon the quality of the copy submitted.

In the unlikely event that the author did not send a complete manuscript and there are missing pages, these will be noted. Also, if material had to be removed, a note will indicate the deletion.



ProQuest 13832529

Published by ProQuest LLC (2019). Copyright of the Dissertation is held by the Author.

All rights reserved.

This work is protected against unauthorized copying under Title 17, United States Code
Microform Edition © ProQuest LLC.

ProQuest LLC.
789 East Eisenhower Parkway
P.O. Box 1346
Ann Arbor, MI 48106 – 1346

GLASGOW
UNIVERSITY
LIBRARY

11843

(copy 1)

DECLARATION

I hereby declare that the work presented in this thesis is original and was conducted solely by the author, except where collaboration with others is acknowledged.

There are 4 studies in this thesis. In the first of these, 67 subjects were studied by me in Glasgow, and the further (153) subjects were contributed from the other five centres as part of a European multi-centre study. The analysis and interpretation of results as presented in the thesis was conducted by me. Some aspects of statistical design are acknowledged from their professional statistical source. The other studies (studies 2, 3 and 4) were single centre studies conducted by myself in Glasgow.



DEDICATION

To my mother

for all her sacrifice throughout the years.

To my late father

whose memory is my greatest inspiration.

To my wife Hiba

for her support and patience during the preparation of this work.

ACKNOWLEDGEMENTS

I would like to express my sincere gratitude to Dr. D G Grosset, my supervisor for his guidance, criticism, advice, encouragement, and for his enormous patience.

I would also like to thank Dr. J Patterson, Department of Clinical Physics, for his constant help and advice during the course of this work.

I am also grateful to Professor P G E Kennedy, Department of Neurology, for his continuous support over the years.

Also, my thanks to Ms T Jones (Research Nurse) and Mrs L Johnstone (Research Secretary) for their help.

Finally, I am thankful to all patients and their relatives for agreeing to participate in this study.

ABBREVIATIONS

AI	Asymmetry index
CNS	Central Nervous System
[¹¹ C]RTI-32	2B-[O- ¹¹ C]-carboxymethoxy-3B-aryltropanes
CT	Computerised Tomography
ECG	Electrocardiogram
EMG	Electromyography
ET	Essential Tremor
FDG	[¹⁸ F] 2-fluoro-2-deoxy-glucose
¹⁸ F-dopa	6-[¹⁸ F] fluoro-L-3,4- dihydroxyphenylalanine
GGT	Gamma glutamyl transferase
H&Y	Hoehn and Yahr
¹²³ I-β-CIT	Iodine-123-beta-carbomethoxy-3beta-(4-iodophenyl)-tropane
¹²³ I-FP-CIT	¹²³ I-N-fluoropropyl-2β-carbomethoxy-3β-(4-iodophenyl) nortropane
¹²³ I-IBZM	123 iodobenzamide
¹²³ I-IPT SPECT	¹²³ I-N-3-iodopropyl-2-yl)- 2β-carbomethoxy-3β-(4-chlorophenyl) tropane
iPD	Idiopathic Parkinson's Disease
LBP	Lower Body Parkinsonism
OPCA	Olivopontocerebellar Atrophy
MPTP	1-methyl-4-phenyl-1,2,3,6-tetrahydropyridine
MRI	Magnetic Resonance Imaging

MSA	Multiple System Atrophy
PET	Positron Emission Tomography
P:C ratio	Putamen:caudate ratio
PS	Parkinsonian Syndrome
PSP	Progressive Supranuclear Palsy
SPECT	Single Photon Emission Computed Tomography
SP:NS	Specific:nonspecific ratio
SND	Striatonigral Degeneration
TIA	Transient Ischaemic Attack
UPDRS	Unified Parkinson's Disease Rating Scale

PUBLICATIONS

Benamer HTS, Patterson J, Hadley DM, Grosset DG. [¹²³I]-FP-CIT SPECT as a Tool in Differential Diagnosis of Parkinsonism and Tremor Disorders (Abs.). *J Neurology Neurosurgery Psychiatry* 1999;67;267.

Benamer HTS, Grosset DG. Diagnostic Pitfalls for Parkinsonism and Tremor Disorders: A Clinical Approach. *J Neurosciences* 1999;4;148-153.

Benamer HTS, Patterson J, Hadley DM, Grosset DG. Visual Assessment of ¹²³I- FP-CIT SPECT Striatal Uptake to Differentiate Between Mild Parkinson's Disease and Essential Tremor (Abs.). *Parkinsonism & Related Disorders* 1999;5:57.

Benamer HTS, D G Grosset. SPECT Imaging in the Diagnosis and Staging of Parkinsonism. *CNS* 1999;2:9-12.

Patterson J, **Benamer HTS, Grosset DG, Hadley DM, Wyper DJ.** Correlation of Severity of Parkinson's Disease with [¹²³I]-FP-CIT SPECT Striatal Uptake (Abs.). *European Journal of Nuclear Medicine.* 1999;26;345.

Benamer HTS, Russell AJC, Hadley DM, Grosset DG. Unilateral Arm Tremor As the Sole Feature of Ischaemic Stroke: A 5 Year Follow-up. *Movement Disorders* (1999, accepted for publication).

Benamer HTS, Patterson J, Hadley DM, Grosset DG. Variable Clinical Involvement in Parkinson's Disease: An Extension of the Presymptomatic Parkinson's Disease Hypothesis (Abs.). J Neurology Neurosurgery Psychiatry (1999, accepted for publication).

The [¹²³I]-FP-CIT Study Group. **Benamer HTS**, Patterson J, Grosset DG (Writing committee). Accurate Differentiation of Parkinsonism and Essential Tremor Using Visual Assessment of [¹²³I]-FP-CIT SPECT Imaging. Submitted to Movement Disorders (1999, provisional acceptance for publication)

Benamer HTS, Patterson J, Wyper DJ, Hadley DM, Macphee GJA, Grosset DG. Correlation of Parkinson's Disease Severity and Duration with ¹²³I-FP-CIT SPECT Striatal Uptake. Submitted to Movement Disorders

CONTENTS

TITLE	i
DECLARATION	ii
DEDICATION	iii
ACKNOWLEDGEMENT	iv
LIST OF ABBREVIATIONS	v
PUBLICATIONS	vii
CONTENTS	ix
LIST OF FIGURES	xiv
LIST OF TABLES	xvii
SUMMARY	xx

CHAPTER 1 - GENERAL OVERVIEW

CLINICAL DIAGNOSTIC ACCURACY OF PARKINSONISM

AND TREMOR DISODERS: PROBLEMS AND PITFALLS	1
1.1 DIAGNOSIS OF TREMOR AND PARKINSONISM	2
1.2 PARKINSONISM	3
1.3 DEFINITION AND CLASSIFICATION OF PARKINSONISM	5
1.4 IDIOPATHIC PARKINSON'S DISEASE	5
1.4.1 Epidemiology	6
1.4.2 The Clinical Features and Course of Idiopathic Parkinson's Disease	6
1.4.3 Diagnosis	7
1.5 MULTIPLE SYSTEM ATROPHY	9
1.5.1 Classification	10
1.5.2 Epidemiology	11

1.5.3	Clinical Features	11
1.6	PROGRESSIVE SUPRANUCLEAR PALSY	13
1.6.1	Epidemiology	13
1.6.2	Clinical Features	14
1.6.3	Pathology	15
1.7	RED FLAGS	16
1.8	ESSENTIAL TREMOR	16
1.8.1	Definition and Classification	16
1.8.2	Diagnostic Difficulties	16
1.8.3	Epidemiology	17
1.8.4	Clinical Features	17
1.8.5	How Familial is Essential Tremor?	18
1.8.6	Effect of Alcohol	19
1.9	VASCULAR PARKINSONISM	19
1.10	DIAGNOSTIC CHALLENGE TESTS FOR PARKINSONISM	24
	<u>CHAPTER 2 - IMAGING IN PARKINSONIAN SYNDROMES</u>	26
2.1	COMPUTERISED TOMOGRAPHY	27
2.2	MAGNETIC RESONANCE IMAGING	28
2.3	FUNCTIONAL IMAGING	29
2.4	PET STUDIES	30
2.4.1	[¹⁸ F]2-Fluoro-2-Deoxy-Glucose PET (FDG PET)	30
2.4.2	6-[¹⁸ F]Fluoro-L-3,4- Dihydroxyphenylalanine (¹⁸ F-Dopa PET)	31
2.4.3	¹¹ C-Raclopride PET	32
2.5	SPECT	34
2.5.1	¹²³ Iodobenzamide SPECT (¹²³ I-IBZM-SPECT)	34

<u>CHAPTER 3</u> - THE DOPAMINE TRANSPORTER SYSTEM	36
3.1 INTRODUCTION	37
3.1.1 PET	37
3.1.2 SPECT	38
<u>CHAPTER 4</u> - STUDY 1: ¹²³I-FP-CIT SPECT IMAGING AS A TOOL TO DIFFERENTIATE PARKINSONISM AND ESSENTIAL TREMOR	42
4.1 INTRODUCTION	43
4.2 METHODS	43
4.2.1 Study Subjects	43
4.2.2 Study Assessments	46
4.2.3 Imaging	47
4.2.4 Data Analysis	47
4.2.5 Statistical Analysis	50
4.3 RESULTS	54
4.3.1 Study Populations	54
4.3.2 Visual Assessments	55
4.3.3 Semi-quantitative Analysis	58
4.3.4 Adverse Events	59
4.4 DISCUSSION	82
4.5 CONCLUSIONS	89

CHAPTER 5 – STUDY 2: CORRELATION OF PARKINSON’S DISEASE

SEVERITY AND DURATION WITH ¹²³I-FP-CIT SPECT STRIATAL

UPTAKE. PATTERNS OF DOPAMINE TRANSPORTER LOSS

IN PARKINSON’S DISEASE, MULTIPLE SYSTEM ATROPHY AND

PROGRESSIVE SUPRANUCLEAR PALSY 90

5.1 INTRODUCTION 91

5.2 METHODS 92

5.2.1 Study Subjects 92

5.2.2 Study Assessments 92

5.2.3 Imaging 93

5.2.4 Data Analysis 94

5.2.5 Statistical Analysis 99

5.3 RESULTS 111

5.4 DISCUSSION 129

5.5 CONCLUSIONS 135

CHAPTER 6 – STUDY 3: ¹²³I-FP-CIT SPECT STRIATAL UPTAKE

IN TREMOR DISORDERS 137

6.1 INTRODUCTION 138

6.2 METHODS 139

6.2.1 Study Subjects 139

6.2.2 Study Assessments 139

6.2.3 Imaging 140

6.2.4 Data Analysis 140

6.3 RESULTS 140

6.3.1 Study Populations 140

6.3.2	Visual Assessments	141
6.3.3	Specific:nonspecific Ratios	141
6.4	DISCUSSION	155
6.5	CONCLUSIONS	159

CHAPTER 7 – STUDY 4: THE RELATIONSHIP BETWEEN TREMOR

DISORDERS, PARKINSONISM AND CEREBROVASCULAR DISEASE 161

7.1	INTRODUCTION	162
7.2	METHODS	163
7.2.1	Study Subjects	163
7.2.2	Study Assessments	163
7.2.3	Imaging	163
7.2.4	Data Analysis	164
7.2.5	Statistical Analysis	164
7.2.6	Index Case	164
7.3	RESULTS	165
7.4	DISCUSSION	184
7.5	CONCLUSIONS	189

REFERENCES 190

LIST OF FIGURES

Figure 3.1 A schematic diagram of the dopaminergic nerve terminal.	41
Figure 4.1 Example of ^{123}I -FP-CIT images in normal and parkinsonism cases.	52
Figure 4.2 Mean specific:nonspecific uptake ratio in per-protocol patients with parkinsonism, essential tremor and healthy volunteers.	68
Figure 4.3 Presymptomatic putamen, and early symptomatic putamen uptake ratio in per-protocol patients with idiopathic Parkinson's disease compared to healthy volunteers.	70
Figure 4.4 Mean specific:nonspecific uptake ratio in per-protocol patients with idiopathic Parkinson's disease, multiple system atrophy, and progressive supranuclear palsy.	72
Figure 4.5 Asymmetry index in per-protocol patients with parkinsonism, essential tremor and healthy volunteers.	74
Figure 4.6 Asymmetry index in per-protocol patients with idiopathic Parkinson's disease, multiple system atrophy, and progressive supranuclear palsy.	76
Figure 4.7 Putamen:caudate ratio in per-protocol patients with parkinsonism, essential tremor and healthy volunteers.	78
Figure 4.8 Putamen:caudate ratio in per-protocol patients with idiopathic Parkinson's disease, multiple system atrophy, and progressive supranuclear palsy.	80
Figure 5.1 SPECT imaging: 12 individual point-focused radiation detectors move both tangentially and radially such that the focal point scans the brain in a "raster" pattern.	101
Figure 5.2 Three adjacent axial sections through the middle of the striatum.	103

Figure 5.3 Outline of the brain, striatal structures and the occipital region of interest templates obtained using image manipulation software.	105
Figure 5.4 Normal anatomical pattern of the striatum.	107
Figure 5.5 Application of region of interest to SPECT images.	109
Figure 5.6 Putamen specific:nonspecific ratio compared to unilateral UPDRS scores in 41 idiopathic Parkinson's disease patients and 6 healthy volunteers.	122
Figure 5.7 Correlation of Unified Parkinson's Disease Rating Scale motor score with mean putamen specific:nonspecific uptake ratio in 41 patients with idiopathic Parkinson's disease.	125
Figure 5.8 Correlation of duration of disease in 41 idiopathic Parkinson's disease patients with mean putamen specific:nonspecific uptake ratio.	127
Figure 6.1 ^{123}I -FP-CIT uptake in 10 tremor patients.	147
Figure 6.2 Specific:nonspecific ratios in 10 patients with tremor, 9 idiopathic Parkinson's disease cases, and 6 healthy volunteers.	151
Figure 6.3 Correlation of duration of disease in idiopathic Parkinson's disease (41 cases) and tremor patients (10 cases) with mean putamen specific:nonspecific uptake ratio.	153
Figure 7.1 Abnormal ^{123}I -FP-CIT uptake in patients with lower body parkinsonism	172
Figure 7.2 Structural and functional imaging in case 5.	174
Figure 7.3 Structural and functional imaging in case 6.	176
Figure 7.4 Striatal specific:nonspecific ratios in patients with vascular parkinsonism (n=12) and healthy volunteers (n=6).	178
Figure 7.5 A) T2-weighted MRI, 6 months after acute onset of left arm tremor, shows an ischaemic lesion in anterolateral aspect of the right putamen (arrow).	180

B) Repeated MRI at 30 months shows no change (arrow). 180

Figure 7.6 A) Surface recording EMG from left extensor digitorum communis
which shows a regular 5-6 Hz tremor with arm out-stretched. 182

B) Simultaneous accelerometer recording from the left middle finger
also demonstrating 5-6 Hz tremor. 182

LIST OF TABLES

Table 4.1 Study population: 158 patients with parkinsonian syndrome, 27 with essential tremor and 35 healthy volunteers.	60
Table 4.2 Demographic data of 158 patients and 35 healthy volunteers enrolled to ¹²³ I-FP-CIT SPECT.	61
Table 4.3 Results of institutional read and consensus blinded read of ¹²³ I-FP-CIT SPECT according to clinical diagnosis.	62
Table 4.4 ¹²³ I-FP-CIT institutional read results according to type of parkinsonism in the intention-to-treat population.	63
Table 4.5 ¹²³ I-FP-CIT institutional read results according to severity of idiopathic Parkinson's disease as assessed by H&Y scale.	64
Table 4.6 ¹²³ I-FP-CIT institutional read results according to study centre in patients with parkinsonian syndrome and essential tremor.	65
Table 4.7 ¹²³ I-FP-CIT institutional read results according to age in patients with parkinsonian syndrome and essential tremor.	66
Table 4.8 Adverse events reported in more than 1% of 224 subjects given ¹²³ I-FP-CIT.	67
Table 5.1 Difference between ipsilateral and contralateral uptake for both caudate and putamen in 9 unilateral, and 32 bilateral idiopathic Parkinson's disease patients, and 6 healthy volunteers.	115
Table 5.2 Correlation coefficients (Spearman rank correlation) for ¹²³ I-FP-CIT SPECT measures and unilateral UPDRS in idiopathic Parkinson's disease.	116

Table 5.3 Correlation coefficients (Spearman rank correlation) for ^{123}I -FP-CIT SPECT measures and UPDRS motor scoring and duration of illness in 41 idiopathic Parkinson's disease patients.	117
Table 5.4 Asymmetry index and putamen:caudate ratio in 9 unilateral and 32 bilateral Parkinson's disease patients and 6 healthy volunteers.	118
Table 5.5 Correlation coefficients (Spearman rank correlation) for Putamen:caudate ratio of ^{123}I -FP-CIT striatal uptake and UPDRS motor scoring and duration of illness in 41 idiopathic Parkinson's disease patients.	119
Table 5.6 Correlation coefficients (Spearman rank correlation) for Asymmetry index of ^{123}I -FP-CIT striatal uptake and UPDRS motor scoring and duration of illness in 41 idiopathic Parkinson's disease patients.	120
Table 5.7 The mean specific:nonspecific uptake in Parkinson's disease, multiple system atrophy, progressive supranuclear palsy, and controls.	121
Table 6.1 Characteristics and clinical features in 10 patients, not fulfilling diagnostic criteria for idiopathic Parkinson's disease or essential tremor.	142
Table 6.2 Further clinical features of 10 patients not fulfilling diagnostic criteria for idiopathic Parkinson's disease or essential tremor.	143
Table 6.3 ^{123}I -FP-CIT institutional read results in tremor patients, idiopathic Parkinson's disease and healthy volunteers.	144
Table 6.4 A) Specific:nonspecific ^{123}I -FP-CIT uptake ratios in 10 patients with tremor.	145
B) Specific:nonspecific ^{123}I -FP-CIT uptake ratios in idiopathic Parkinson's disease patients (n=9) and healthy volunteers (n=6).	146
Table 7.1 Clinical features and investigation of 12 patients with vascular parkinsonism.	167

Table 7.2 ^{123}I -FP-CIT institutional read results for vascular parkinsonism and healthy volunteers.	169
Table 7.3 A) Striatal ^{123}I -FP-CIT specific:nonspecific uptake ratios of patients with vascular parkinsonism (12) and healthy volunteers (6).	170
B) Specific:nonspecific ^{123}I -FP-CIT uptake ratios in 12 patients with vascular parkinsonism.	171

SUMMARY

There have been continual changes in medical diagnosis and treatment throughout the generations. Present medical practice emphasises accuracy and accountability, and an evidence base for diagnosis and therapeutic intervention. The differential diagnosis of tremor disorders and parkinsonism serves as a good example of evolving concepts and treatment approaches, and is the subject of the present thesis.

It is necessary first to review present knowledge about the accuracy of diagnosis and why this is important (Chapter 1), then to review how imaging techniques have contributed to the knowledge base (Chapter 2) and then report current understanding of the dopamine transporter (Chapter 3) - as it is at this site that the new isotope ^{123}I -N-fluoropropyl-2 β -carbomethoxy-3 β -(4-iodophenyl) nortropane (^{123}I -FP-CIT) is known to work.

It is the aim of the present thesis to examine an advanced phase of clinical application of the technique of SPECT imaging with ^{123}I -FP-CIT to the differential diagnosis of selected movement disorders as follows:

In study 1 (Chapter 4) the design and result of study of 220 subjects with idiopathic Parkinson's disease (iPD), multiple system atrophy (MSA), progressive supranuclear palsy (PSP), essential tremor (ET) and healthy volunteers are presented. A new technique of assessing ^{123}I -FP-CIT SPECT by visual inspection was developed which proved to be useful in differentiating essential tremor from other parkinsonian syndromes. Semi-quantitative analysis showed limited usefulness of ^{123}I -FP-CIT

SPECT in differentiating iPD from atypical parkinsonism. This study provides evidence against significant association between iPD and ET.

Study 2 (Chapter 5) addressed the issue of the correlation of severity, staging and duration of parkinsonian features with ^{123}I -FP-CIT striatal uptake in 41 patients with iPD. A positive correlation of striatal uptake was identified for these variables and for bradykinesia, but not for tremor suggesting that tremor could have an origin outwith the dopamine transporter system. The clinical lateralisation of parkinsonian signs was studied in relation to striatal uptake with the finding that clinical asymmetry in iPD was more marked than the degree of the asymmetry in ^{123}I -FP-CIT uptake. The patterns of ^{123}I -FP-CIT uptake in iPD, 8 MSA, 3 PSP and 6 healthy volunteers were reported, confirming that the posterior putamen is the most affected part in iPD and showing that there are limitations in attempting to differentiate parkinsonism subtypes using this technique.

In study 3 (Chapter 6) 10 patients with tremor and/or clinical features suggesting possible parkinsonism (but not fulfilling diagnostic criteria for either iPD or ET) were compared to 9 unilateral patients fulfilling diagnostic criteria for iPD and 6 healthy volunteers. Reduced ^{123}I -FP-CIT striatal uptake was found bilateral in 7 tremor patient and all 9 of the unilateral iPD patients, confirming the presymptomatic phase of the illness not only in early parkinsonism cases but even in monosymptomatic cases who have yet to develop definitive clinical features. Of the 10 tremor cases, 3 showed striatal uptake values above the range established for iPD patients fulfilling clinical criteria, even although the duration of disease in the tremor patients was similar to that in definite iPD patients. Three of the 10 tremor patients showed normal striatal

uptake. This indicated the usefulness of this technique in demonstrating the nigrostriatal change at a very early stage of disease, helping to exclude or confirm the diagnosis of parkinsonism.

In study 4 (Chapter 7) the relationship between cerebrovascular disease and parkinsonism was studied. ^{123}I -FP-CIT striatal uptake in 12 patients with vascular parkinsonism was compared to 6 healthy volunteers. Also an index case of isolated tremor related to ischaemic lesion was reported. A reduction in uptake was shown in all vascular parkinsonism patients except one. Two distinct patterns of dopaminergic loss, both of which differ from idiopathic Parkinson's disease were identified, indicating that vascular lesions may disrupt the dopaminergic system to produce parkinsonian features.

In summary, a simple visual inspection of ^{123}I -FP-CIT SPECT scans helps in differentiating parkinsonian syndromes from essential tremor and detecting changes in the dopaminergic system in patients with unilateral parkinsonism, even in patients not fulfilling diagnostic criteria for iPD. However there are limitations in using this technique in differentiating iPD from MSA or PSP. A reduction in striatal uptake was shown in vascular parkinsonism patients supporting a dopaminergic source of symptoms in this group. The correlation of disease staging, severity and duration with striatal ^{123}I -FP-CIT uptake indicates the potential usefulness of SPECT in monitoring disease progression and the effects of putative neuroprotective therapy.

In conclusion, this new technique represents a significant advance in medical diagnosis of movement disorders. It is not a substitute for clinical assessment but

should be used in conjunction with it, to clarify diagnosis where there is uncertainty, and in particular when this has implications for patient care, such as in guiding about prognosis, or in choosing drug treatments. As we enter the next century of medical innovation, it seems probable that this technique has future application as objective test for assessing the benefits of neuroprotective drugs, the effects of neuronal growth factors or the survival of transplant of dopaminergic material.

CHAPTER 1

***CLINICAL DIAGNOSTIC ACCURACY OF
PARKINSONISM AND TREMOR DISORDERS:
PROBLEMS AND PITFALLS***

1.1 DIAGNOSIS OF TREMOR AND PARKINSONISM

Accurate diagnosis of idiopathic Parkinson's disease (iPD) is important in patient care through providing accurate prognostic information. The obvious differences in clinical progress and survival from the more benign essential tremor (ET) through the tremor dominant Parkinson's disease to iPD itself and the Parkinson plus disorders, are reflected for example in survival statistics for Multiple System Atrophy (MSA) at 6 years (Wenning et al 1997) and near normal life expectancy in iPD (Marsden 1994). It is appropriate for practising clinician to address patient and family concerns about prognosis from a firm diagnostic footing.

In drug treatment, accurate diagnosis allows for introduction and amendment of drug therapy tailored to the patient condition and clinical progress. For example patients initially diagnosed iPD in whom a revised diagnosis of ET or MSA is reached, can have appropriate levodopa withdrawal or adjustment. In addition, it is important to define an accurate patient cohort for clinical research studies, such as trials of putative neuroprotective drugs, or novel therapies for MSA and Progressive Supranuclear Palsy (PSP). Finally, accurate diagnosis would help in understanding the aetiology and pathophysiology of different causes of parkinsonism and tremor disorders, for example, similarities and differences between ET and benign tremulous Parkinson's disease.

1.2 PARKINSONISM

“Involuntary tremulous motion, with lessened muscular power, in parts not in action and even when supported; with a propensity to bend the trunk forward, and to pass from a walking to a running pace: the sense and intellects being uninjured.”

James Parkinson 1817

Dr. James Parkinson, in his Essay on the Shaking Palsy, described six male patients aged 50 to 72 whose disease has since carried his name. It is interesting that no female patients were described. With great success, he illustrated in 66 pages and five chapters the features of Paralysis Agitans.

Parkinson described many cardinal features of the disorder: tremor “the shaking of the limbs...was particularly noticed”, onset and progress “symptoms gradually increase in the part affected ... seldom in less than twelve months or more, the morbid influence is felt in other part”, posture “patient is found to be less strict than usual in preserving an upright posture”, gait “irresistibly impelled to take much quicker and shorter steps, and thereby to adopt unwillingly a running pace”. He also mentioned other features of the disease such as, speech changes “words are now scarcely intelligible...the power of articulation is lost”, difficulty swallowing “the power of conveying the food to the mouth is at length”, sialorrhoea “saliva...is continually draining from the mouth”.

As for differential diagnosis, Parkinson recognised other causes of tremor such as alcohol, and “palsy as consequent to compression of the brain, or dependent on partial exhaustion of the energy of that organ”. He disagreed with the use of the term shaking

palsy in convulsion and involuntary movement when he described two patients, one with ballistic attacks and another with possible torsion dystonia (Pearce 1989).

Parkinson mistakenly believed the site of pathological change to be in the superior cervical vertebrae and extending, as the disease proceeds, to the medulla oblongata. Although he expresses uncertainty he assumed that the disease could be a “result of injuries of the medulla itself, or of the theca helping to form the canal in which it is enclosed”. However he makes it clear that no patient recollected receiving any injury. Without adequate knowledge of either the correct anatomical site or the nature of the chemical deficiencies, Parkinson made inappropriate suggestions for treatment such as “blood should be taken from the upper part of the neck, and purulent discharge obtained by appropriate use of the sabine Liniment”.

Parkinson ignored rigidity completely as a cardinal feature of the disease and it was described later by Trousseau’s 15th Lecture on Clinical Medicine (Pearce 1989). Also, Parkinson made some observations which were later proven to be untrue, such as “intellects being uninjured, and the tremulous motion of the limbs occur during sleep”. It is known now that dementia may occur in up to 44% of patients with iPD (Hughes et al 1993), and the tremor usually disappears in sleep.

1.3 DEFINITION AND CLASSIFICATION OF PARKINSONISM

Parkinsonism is a clinical syndrome characterised by bradykinesia: slowness of movement, hypokinesia: reduced movement, akinesia: loss of movement, rigidity: increased resistance to passive extension and flexion, tremor: mainly resting and postural abnormalities.

Parkinsonism is usually classified as:

1. Idiopathic Parkinson's disease, of unknown aetiology.
2. Parkinsonism as part of other neurodegenerative disorders.
3. Symptomatic (secondary) parkinsonism with known aetiology.

1.4 IDIOPATHIC PARKINSON'S DISEASE (iPD)

Idiopathic Parkinson's Disease consists of parkinsonism and is characterised pathologically by changes of neuronal loss, with Lewy bodies, in the substantia nigra.

Lewy bodies, first described by German pathologist F H Lewy in 1914, are eosinophilic intracytoplasmic inclusions. These bodies are also found in specific extranigral sites in iPD, e.g. Locus coeruleus, thalamus, cerebral cortex and autonomic nervous system (Gibb 1989a). Lewy bodies are not specific for iPD, and are reported in elderly patients without clinical features of iPD, hence the term incidental Lewy bodies, which probably represent pre-clinical or early stages of iPD rather than the effect of age (Forno 1969, Gibb and Lees 1988). Also, Lewy bodies are reported in MSA (Gibb 1988), PSP (Gomori et al 1984, Jellinger et al 1980), familial Alzheimer's disease (Gibb et al 1989b), Hallervorden-Spatz disease (Gibb 1989a), ataxia-telangiectasia (Agamonolis et al 1979), subacute sclerosing

panencephalitis (Gibb et al 1990a), and diffuse Lewy body dementia (Gibb et al 1985). Other pathological changes such as Alzheimer-type pathology and vascular striatal abnormalities can coexist with the typical pathological features of iPD (Hughes et al 1992).

1.4.1 Epidemiology

Idiopathic Parkinson's Disease is the commonest cause of parkinsonism (Quinn 1995), with an annual incidence of 20.5 per 100 000 of the population and prevalence 164 per 100 000 (Rajput et al 1984a, Mutch et al 1986). The prevalence of the disease increases with age from 47 per 100 000 for ages 40-49 years, to 832 per 100 000 for 70-79 years (Mutch et al 1986).

In a population of 250 000 there are 400 patients with Parkinson's Disease, of whom 342 have significant disability (Association of British Neurologists 1992).

Therefore, iPD is a common and disabling condition particularly with increased age.

1.4.2 The Clinical Features and Course of Idiopathic Parkinson's Disease

The mean age at onset of iPD is between 55 and 65 years, with a slight male predominance of 60%, and mean age of death is 75.5 years (Hoehn and Yahr 1967, Mutch et al 1986, Hughes et al 1993). There is no difference in the age of onset, age at death or duration of illness between males and females (Hughes et al 1993).

In a study of clinical features of 100 pathologically proven cases of iPD, Hughes et al (1993) reported asymmetric disease onset in 72%. Marked tremor was present in 69%

but 42% had tremor only without bradykinesia or rigidity. The disease was tremor dominant in 11%, akinetic rigid in 23%, and mixed in 64% with the mean survival being longer by 3.7 years in patients with tremor dominant disease. The initial response to levodopa was nil to poor in 6%, moderate in 17%, good in 53%, and excellent in 24%. Dementia was present in 44% of cases, increasing with duration of illness. Autonomic dysfunction was reported in 27 patients, mainly mild postural hypotension, although 4 patients had severe autonomic failure. Marked speech abnormalities were reported in 20, 11 patients had swallowing difficulties, and 13 had marked gait freezing. Over one quarter of iPD patients were dead or disabled within 5 years, rising to 60% after 5-9 years, to over 80% after 10 to 14 years, and to almost 90% after 15 years (Hoehn and Yahr 1967).

With the introduction of levodopa in 1968, mortality fell to approach that of the normal population (Marsden 1994). Ischaemic heart disease, cancer and cerebrovascular disease are the common causes of death unrelated to parkinsonism, while infections (broncho-pneumonia, urinary infection, infected bed sores), operations and accidents remain implicated in mortality related to parkinsonism (Hoehn and Yahr 1967, Hughes et al 1993). Survival had no relation to the type of onset or initial response to levodopa but correlated negatively to age at onset (Hughes et al 1993).

1.4.3 Diagnosis

The diagnosis of iPD can be very difficult especially in the early stage of the disease. There are no biological markers or specific neuroimaging techniques to diagnose this condition.

Two major clinico-pathological studies have evaluated the accuracy of clinical diagnosis of iPD.

Hughes et al (1992) examined 100 consecutive cases with a clinical diagnosis of iPD over 3 years, of which 70 cases were assessed prospectively and annually by a neurologist associated with The Parkinson's Disease Society Brain Bank, and other cases were diagnosed by consultant neurologists or geriatricians.

Pathologically, the diagnosis was based on finding a clear depletion of brain stem pigmented neurones with the presence of Lewy bodies in some of the remaining nerve cells. Of the 100 cases, 76 fulfilled pathological criteria, while the remaining 24 patients were clinically misdiagnosed. The principle findings in the cases without Lewy bodies were PSP (six), MSA (five), Alzheimer's disease (three), Alzheimer-type pathology (three), vascular disease (three), isolated nigral atrophy with no Lewy bodies (two), post-encephalitic parkinsonism (one), and one case with normal pathology in which review of the clinical details suggested possible ET. Retrospective application of the UK Brain Bank Criteria improved the diagnostic accuracy to 82%. Three patients with atypical clinical features had typical pathological features of iPD.

In a similar clinico-pathological study, 59 patients with parkinsonism had postmortem examination (Rajput et al 1991a). The initial diagnosis was iPD in 43 patients, in whom Lewy body pathology was verified in only 28 (65%). The final clinical diagnosis after an average duration of illness of 11.7 years (range 2-39) was iPD in 41 patients (76%). The diagnosis in the 10 cases who were incorrectly labelled as iPD were: striatonigral degeneration (four), profound substantia nigra neuronal loss

without inclusions (two), neurofibrillary tangle parkinsonism (two), drug induced parkinsonism (one), and Alzheimer's disease (one).

Both of these pathological studies indicate that 24% of patients with a clinical diagnosis of iPD do not fulfil pathological criteria and have an alternative diagnosis. MSA or PSP are the most common pathological diagnoses in such cases.

The bias introduced by pathological studies when compared to a clinical setting, is in the absence of the most common movement disorder ET. The presence of only one case within the above two clinico-pathological studies probably reflects the benign course of ET.

Also, applying rigid clinical criteria could lead to misdiagnosis. In a study of 100 pathologically proven iPD patients, 12 cases failed to fulfil the UK Brain Bank Criteria. Thus patients with unusual features, such as early onset of dementia or poor response to levodopa, may still have iPD (Hughes et al 1993).

1.5 MULTIPLE SYSTEM ATROPHY (MSA)

MSA is a sporadic, adult onset, neurodegenerative disease. It is a clinico-pathological entity which can be present with any combination of parkinsonism, cerebellar and/or pyramidal signs and autonomic dysfunction.

Pathologically, it is characterised by cell loss and gliosis in any two of the following brain areas: substantia nigra, striatum, locus coeruleus, pontine nuclei, cerebellar

purkinje cells, inferior olives, together with the presence of oligodendroglial cytoplasmic inclusions (Quinn 1994, Wenning et al 1995).

1.5.1 Classification

Shy and Drager described in 1960 a neurological syndrome associated with orthostatic hypotension. In 1969, Graham and Oppenheimer introduced the term MSA, but it has since become a title which covers a wide range of different degenerative conditions (Quinn 1994).

There is ongoing debate about how to use these terms. The following subtypes of MSA have been defined in a clinico-pathological study (Litvan et al 1997):

- (i) Shy-Drager syndrome, in which autonomic failure predominates.
- (ii) Striatonigral degeneration, in which parkinsonism predominates.
- (iii) Olivopontocerebellar atrophy, in which cerebellar features predominate.

However, Oertel and Quinn (1996) argue against using the term Shy-Drager syndrome because autonomic dysfunction is almost universal in MSA (Wenning et al 1994a) and they defined MSA subtypes as follows:

- (i) Striatonigral degeneration (MSA - parkinsonian type).
- (ii) Sporadic olivopontocerebellar atrophy (MSA - cerebellar type).

Wenning et al (1995) further emphasised the overlap in clinical features in a clinico-pathological study of 35 cases of MSA, in which one case had isolated parkinsonism and the remaining 34 had a mixture of autonomic, cerebellar and pyramidal features at different times through the clinical course.

1.5.2 Epidemiology

MSA contributes to between 3.6 and 22% of incident cases of parkinsonism, a mean figure of 8.2%. The wide range indicates the need for a prospective population-based study of this condition, with pathological follow-up (Quinn 1994, Wenning et al 1997).

1.5.3 Clinical Features

Wenning et al (1997) reviewed the clinico-pathological features of 203 cases, from the literature, with pathologically proven MSA. The male: female ratio was 1.3:1 with mean age of onset 54.3 years, mean age at death was 60.3 years and mean duration of illness was 6.1 years. Bronchopneumonia was the most common cause of death. Pure striatonigral degeneration (SND) was present in 46%, predominantly SND in 14%, pure olivopontocerebellar atrophy (OPCA) in 13%, predominantly OPCA in 15%, and 12% had an equal mix of parkinsonism and cerebellar features.

Autonomic features were present in 74% of the cases with urinary incontinence in 55% and/or urinary retention in 18%. Impotence was reported in 47% of male patients. Postural faintness was present in 51%.

Parkinsonism occurred in 87% of cases, all of them had akinesia, and two thirds had rigidity or tremor, rest tremor was described in 39% and classical pill-rolling rest tremor seen only 8% of patients.

Cerebellar signs, mainly gait ataxia, were present in 54% and pyramidal signs in 48%, 41% showed extensor plantars while 46% showed hyperreflexia and only 10% of patients had spastic paraparesis.

Other features included stridor (13%), intellectual deterioration which was mild in 22%, moderate in 2%, and severe in 0.5%.

Only 28% of patients had a good or excellent response to levodopa while 27% developed dyskinesia, mainly axial.

In a clinical series of 100 consecutive patients with a clinical diagnosis of probable MSA, Wenning et al (1994a) showed similar prevalence rates of parkinsonism, cerebellar ataxia, and pyramidal features. Autonomic failure however, was reported more in the clinical series, probably because of reporting bias in favour of more severe autonomic features and in favour of motor features. Also, the median survival in the clinical series was 9.5 years suggesting either more severe cases in the published postmortem series, or less diagnostic accuracy in the clinical series.

These studies showed clearly the clinical features, the worse prognosis for MSA than iPD, and the poor response to anti-parkinsonian medication.

Litvan et al (1997) addressed the issue of the accuracy of clinical diagnosis of MSA by studying 105 autopsy cases of parkinsonism, and found MSA in 16 cases, and related disorders in 89 cases. Neurologists correctly identified 25% of the 16 MSA cases at the first clinic visit (a median of 42 months after the onset of symptoms) and

50% at the last visit (74 months after the onset of symptoms). In another study only 29% of patients shown to have MSA had the correct clinical diagnosis at the time of death (Wenning et al 1997). Clearly therefore, MSA is under-recognized, and is frequently misdiagnosed as either iPD or PSP. Early severe autonomic failure, absence of cognitive impairment, early cerebellar symptoms, and early gait disturbances were identified as the best predictive features to diagnose MSA.

1.6 PROGRESSIVE SUPRANUCLEAR PALSY (PSP)

(STEELE-RICHARDSON-OLSZWESKI SYNDROME)

Steele, Richardson and Olszewski (1964) described clinical and pathological features of nine patients with a progressive disorder of vertical gaze, axial rigidity, dysarthria, pseudobulbar palsy and mild dementia, which they called Progressive Supranuclear Palsy.

1.6.1 Epidemiology

PSP is under-diagnosed, making accurate epidemiological data difficult to obtain. However, from a search of neurologists, nursing homes and movement disorder centre records in New Jersey with a total population of 800 000, a prevalence of 1.46 per 100 000 and annual incidence of 3.1 to 4.0 cases per million has been estimated (Golbe et al 1988).

Although all of the initial reported cases were male (Steele et al 1964), no significant sex difference (Golbe et al 1988), or only a slight (1.5:1) male predominance (Lees et al 1987) are now recognised. Three necropsy series have also confirmed this (De Bruin et al 1994, Collins et al 1995a, Litvan et al 1996a).

1.6.2 Clinical Features

PSP is a sporadic disorder, but familial cases have been described (Brown et al 1993, de Yebenes et al 1995). Patients with PSP usually present in the seventh decade, with postural instability and falls in the first year in more than 50% and dysarthria in one third. Visual disturbances in form of diplopia, blurred vision, burning eyes, and light sensitivity are the initial symptoms in around 15% of patients. Cognitive or behavioural changes generally follow (Litvan et al 1996a).

Vertical downward gaze palsy is the single most important clinical feature of PSP. Although upward gaze and convergence become impaired first, this also occurs in other basal ganglia disorders and in old age (Lees 1987). The oculocephalic manoeuvre remains intact (except in very advanced stages), and it is this characteristic that makes the disorder supranuclear (Jankovic 1984, Stell and Bronstein 1994). Other ocular manifestations include supranuclear ophthalmoplegia, absent Bell's phenomenon, impaired pupillary light reflexes, lid retraction, a markedly reduced blink rate, frontalis muscle over-activity, blepharospasm, and apraxia of eye opening or closure (Duvoisin et al 1987, Lees 1987). These changes give the patient a fixed, staring, and astonished expression (Lees 1987). Although the presence of down-gaze palsy is an essential finding to secure the diagnosis of PSP, there are a few pathologically proven cases reported which did not develop such abnormality during life (Collins et al 1995a, Litvan et al 1996a). Other clinical features include; bilateral bradykinesia, axial rigidity, speech changes (dysphonia, palilalia, ataxic and unintelligible speech), frontal lobe symptoms, personality changes, dysphagia and neck dystonia (Litvan et al 1996a).

In a review of first and last neurology clinical visits of 24 patients with pathologically confirmed PSP to tertiary centres in three European countries and USA, the first clinic visit occurred at a mean of 3.7 years after the onset of symptoms. Most of the patients had gait disorder, postural instability, backward falls, bilateral bradykinesia, axial rigidity, vertical supranuclear palsy, and dysarthria. The median survival from the onset of the disease was 5.6 years and the most common cause of death was pneumonia. The clinical diagnosis by the attending Neurologist was correct in 58% of PSP cases at the first visit, while an incorrect diagnosis of iPD was made in 21%. Recognition of an atypical parkinsonism was made in some cases, but with the wrong label applied: corticobasal degeneration in 4%, Alzheimer's disease in 4% and others in 8%. The diagnostic accuracy improved to 88% at the final visit pre-mortem, indicating that PSP is under-diagnosed especially in the early course of the disease (Litvan et al 1996a).

1.6.3 Pathology

Pathological criteria of typical PSP are of a high density (two or more neurones) of neurofibrillary tangles and neuropil threads in at least three of the following areas: pallidum, subthalamic nucleus, substantia nigra, and pons, and a low (one or more neurone) to high density in at least three of the following areas: striatum, oculomotor complex, medulla, and dentate nucleus. The presence of tau-positive astrocytes or processes or tangles in astrocytes in these areas also supports the diagnosis. Atypical PSP should be diagnosed if the pathological findings are a low density of neurofibrillary tangles and neuropil threads in at least five of the following areas: pallidum, subthalamic nucleus, substantia nigra, pons, medulla, and dentate nucleus (Hauw et al 1994).

1.7 RED FLAGS

Quinn (1995) has described a number of clinical features (red flags) which should alert the clinicians to the possibility of an atypical parkinsonian disorder. The most important are, absent or poor response to levodopa, rapid disease progression, autonomic failure, early falls, cerebellar and/or pyramidal signs, supranuclear palsy, lower body parkinsonism, early dementia, and early or severe speech and swallowing impairment.

1.8 ESSENTIAL TREMOR (ET)

1.8.1 Definition and Classification

Essential Tremor is a tremor typically on posture and therefore occurring while voluntarily maintaining position against gravity and mainly involving the upper limbs. It is different from parkinsonian tremor which is mainly resting and therefore occurs inactive muscles which are completely supported against gravity (Findley and Koller 1995, Findley 1996).

1.8.2 Diagnostic Difficulties

Although the description of tremor in parkinsonism and ET implies clear separation of the tremor types, there is often a degree of overlap (Martinelli et al 1987), and therefore Findley (1996) states that “no single type of tremor can be pathognomonic of a particular disorder”.

Essential tremor may be misdiagnosed as iPD. Hoehn and Yahr (1967) reviewed 856 patients with a diagnosis of parkinsonism and 39 were found to have ET. Critchley (1972) reviewed 42 patients with ET and found 10% incorrectly diagnosed as parkinsonism. Larsen and Calne (1983) have stated that “patients with essential

tremor are commonly diagnosed as having Parkinson's disease..., the frequency of this mistake has varied from 20% to 25%". Quinn (1995) acknowledges that essential tremor is one of the two conditions most commonly misdiagnosed as iPD by many non-specialists, and even by some specialists. Recently, 402 cases with presumed iPD receiving antiparkinsonian medication were reviewed in a community-based study, and 50 patients (29%) were found to have ET without any features of parkinsonism (Meara et al 1999).

1.8.3 Epidemiology

Essential tremor is the commonest movement disorder, with a prevalence rate up to 20 times that of iPD, although only 10% of patients aged above 40 have sought medical treatment (Rautakorpi et al 1982).

The world-wide prevalence is estimated at between 4 and 39 per 1000, and increases up to 50 per 1000 with advancing age (Louis et al 1998). The annual incidence is about 23 per 100 000 population (Rajput et al 1984b).

1.8.4 Clinical Features

A bimodal distribution with peaks in the second and fifth decades has been reported with men and women equally affected (Lou and Jankovic 1991, Bain et al 1994), but other studies indicate an onset usually around 45 years with an earlier onset in familial ET (Koller et al 1994). No correlation has been found between the age of onset and either tremor severity or disability, but both severity and disability increase with advancing age and tremor duration (Bain et al 1994).

Although ET may be classified as either hereditary or sporadic, clinical features are usually discussed without distinguishing between the two based on the assumption that they are the same entity (Bain 1993).

The main manifestation of ET is postural and/or kinetic tremor of the hands, starting intermittently and progressing to become permanent, rarely remitting (Larsen and Calne 1983) and usually worsened by emotion. Tremor of the head, voice, tongue, and legs may follow (Lou and Jankovic 1991, Bain et al 1994).

Essential tremor is sometimes described as benign, and although it does not affect life expectancy, it can impair physical function, such as the ability to eat, drink, write and can be a social embarrassment (Koller et al 1986, Busenbark et al 1991). Up to 15% of patients took early retirement as a result of the disability caused by the tremor (Rautakorpi et al 1982).

There are no specific pathological features of ET (Rajput et al 1991b).

1.8.5 How Familial is Essential Tremor?

It is commonly stated that 30 to 50% of ET patients have an affected relative (Martinelli et al 1987, Salemi et al 1994). In reviewing all service-based and community-based published studies of familial aggregation in ET, Louis et al (1996) found a range of 17-100% for reporting of affected relatives, clearly suggesting variation in data collection techniques. Busenbark et al (1996) found on an initial assessment 67% of patients reported a positive family history but after full assessments including a mailed questionnaire to all first degree relatives this was

increased to 96%. Penetrance is usually complete by the age of 65 years, and no evidence of the disease skipping a generation was found in studying 20 kindreds, thereby indicating autosomal dominant inheritance (Bain et al 1994). However no responsible gene has yet been identified (Britton 1995).

1.8.6 Effect of Alcohol

As many as 50-66% of ET patients report improvement of their tremor after alcohol (Critchley M 1949, Critchley E 1972, Lou and Jankovic al 1991, Bain et al 1994). Although this was reported for postural tremor associated with parkinsonism (Rajput et al 1975), Koller and Biary (1984) found no effect of intravenous ethanol in 5 iPD patients with resting tremor compared to 15 ET patients.

The rate of alcoholism in ET patients was reported to be high in one retrospective study (Schroeder and Nasrallah 1982), but another prospective study did not confirm this (Koller 1983).

1.9 VASCULAR PARKINSONISM (VP)

Stroke is much more common than iPD, especially among the elderly population, with an overall incidence of 200 per 100 000 increasing to 1400 per 100 000 for a population aged 75-84 years and an overall prevalence of 800 per 100 000 in the UK (Bamford et al 1988, Warlow 1991). The annual incidence of iPD is 20.5 per 100 000 of the population and the prevalence 164 per 100 000 (Rajput et al 1984a, Mutch et al 1986). The prevalence of the disease increases with age from 47 per 100 000 for ages 40-49 years, to 832 per 100 000 for 70-79 years (Mutch et al 1986). Therefore, there is an overall 1.6 per 100 000 chance for case of iPD to have co-existing

cerebrovascular disease, while increases to 11 per 100 000 for patients aged over 70 years.

Alternatively, a parkinsonian syndrome may be caused by cerebrovascular disease, a concept introduced when Critchley (1929) described 5 types of clinical presentation of what he termed arteriosclerotic parkinsonism. Rigidity, fixed faces and short-stepping gait were the main clinical signs. Pseudo-bulbar, dementia, incontinence, pyramidal or cerebellar signs were considered as additional features. After several clinical studies in the 1960's and 1970's showed no relation between arteriosclerosis and iPD (Eadie et al 1964, Parkes et al 1974, Marttila et al 1976b), Critchley in 1981 renamed the condition arteriosclerotic pseudo-parkinsonism. Several alternative terms have been used including vascular parkinsonism and lower body parkinsonism, but there are no generally accepted clinical criteria to diagnose the condition.

With the development of CT and MRI the concept of vascular parkinsonism was revived (Chang et al 1992, Inznelberg et al 1994, Reider-Groswasser et al 1995). This was supported by postmortem studies showing that iPD can co-exist with vascular lesions in the striatum, and lacunar infarcts can produce clinical features similar in all aspects to iPD including a response to levodopa (Tolosa and Santamaria 1984, Murrow et al 1990, Hughes et al 1991, 1992).

Several clinical features have been described relating brain vascular lesions to parkinsonism. Two patients presented with acute onset parkinsonism, due to vascular lesions in the basal ganglia, and recovery without anti-parkinsonian drugs had been reported (Friedman et al 1986, Mayo et al 1986). On the other hand, an insidious

onset of parkinsonism at times indistinguishable from iPD due to brain vascular infarcts has been described (Tolosa and Santamaria 1984, Murrow et al 1990, Inzelberg et al 1994, Reider-Groswasser et al 1995, Mark et al 1995).

Lower body parkinsonism (LBP) is another clinical pattern suggesting a cerebrovascular cause for parkinsonian features. FitzGerald and Jankovic (1989) compared ten patients with marked gait difficulty to 100 patients with iPD. Gait disturbance was the initial symptom in 7% of iPD cases. The only difference in vascular risk factors was an excess of hypertension in LBP. Only 22% of LBP responded to levodopa while 96% of iPD responded. Scores for speech, hypomimia, neck rigidity, and upper limb rest tremor, rigidity, and hand dexterity were significantly lower in LBP emphasising the relative sparing, though not absence, of the upper body and trunk involvement. The duration of symptoms was considerably shorter in LBP than iPD. All LBP patients had structural imaging (MRI, CT, or both) performed, and multiple deep sub-cortical lesions were seen in all but one. On the other hand only 4 of 8 MRI scans and one of 34 CTs for patients with iPD showed sub-cortical white matter lesions. In a clinico-pathologic study Yamanouchi and Nagura (1997) compared the symptoms and signs in 24 patients with VP (defined as: parkinsonism with evidence of cerebrovascular lesions and no depigmentation or Lewy bodies in the substantia nigra) with 30 age-matched pathologically confirmed iPD patients. Also, they compared the brain pathological changes in VP patients with 22 age-matched Binswanger's disease cases without parkinsonism. Resting tremor was present in one patients, and action tremor in 3 patients with VP while 22 patients with iPD had tremor. Nine patients with VP had hemiparesis and 15 had pyramidal signs, while no hemiparesis or pyramidal signs were found in iPD. Half of the patients

with VP had pseudobulbar palsy, and 27% of iPD patients had dysphagia or dysarthria. Dementia was present in 17 VP and 13 iPD cases. Fifteen VP patients received anti-parkinsonian medications, none showed good response, 3 a transient response, and the remaining 12 showed no response at all, while the majority of iPD patients showed a good response. Asymmetry of limb rigidity was reported in 7 patients with VP and 22 iPD patients. Interestingly, no difference was found in the gait disorders between VP (all patients had gait problems) and iPD (23 patients). Pathologically, 11 iPD patients had evidence of cerebrovascular disease. The white matter lesions in VP were less severe than Binswanger's disease but the extent of vascular lesions in both groups were equal.

Recently, Winikates and Jankovic (1999) reported a difference in the clinical features of vascular parkinsonism compared to iPD. They defined vascular parkinsonism as patients with at least 2 of the 4 cardinal features of parkinsonism (bradykinesia, rigidity, tremor and postural instability) and 2 or more points on a specially design vascular rating scale (2 points for pathologically or angiographically proven diffuse vascular disease, 1 point for onset of parkinsonism within 1 month of clinical stroke, 1 point for history of 2 or more strokes, 1 point for history of 2 or more risk factors of stroke, and 1 point for neuroimaging evidence of vascular disease in 2 or more vascular territories). They found VP patients were older, more likely to present with gait difficulty rather than tremor, and less likely to respond to levodopa. Also VP patients tend to have more predominant lower body involvement, postural instability, a history of falling, dementia, corticospinal findings, incontinence and pseudobulbar palsy.

Therefore, LBP or VP may represent a group of patients, probably hypertensive, who usually have gait difficulty, symmetrical rigidity, absent tremor, and no response to levodopa therapy.

The association of ischaemic stroke and vascular risk factors was addressed in two studies, where the incidence of ischaemic stroke among iPD patients was lower than controls in one study (Struck et al 1990) but an association was found in another (Levine et al 1992). Cigarette smoking is recognised as protective from iPD (Baumann et al 1980, Morens et al 1996) and a low incidence of both smoking and myocardial infarction has been shown in iPD patients (Struck et al 1990, Levine et al 1992).

Thus iPD may co-exist with cerebrovascular disease, but there may be a lower probability of a chance association because of the risk factor profiles for each disease. Postmortem studies provide definite evidence that iPD patients may also have cerebrovascular disease, and that patients with parkinsonism may have cerebrovascular disease but no pathological features of iPD (Hughes et al 1992). The clearest clinical description of parkinsonism in association with cerebrovascular disease is that of LBP. However, upper body signs and symptoms are not excluded in such patients, and a vascular aetiology for patients with less than pure lower body features appears possible. Finally, a small subset of patients may be unfortunate enough to have predominately upper body features from iPD and lower body features from VP.

1.10 DIAGNOSTIC CHALLENGE TESTS FOR PARKINSONISM

The concept of diagnostic challenge tests for patients with parkinsonism was introduced recently to assess the dopaminergic responsiveness in patients with parkinsonism.

Hughes et al (1990) performed apomorphine and levodopa challenge testing in 65 iPD patients (15 *de novo*, 16 stable and 34 fluctuators) and 35 parkinsonian syndrome (PS) patients (4 MSA, 6 PSP, 5 dementia with parkinsonism, 4 possible early iPD, 8 Parkinson's plus and 8 others). Motor function was assessed using alternate unilateral hand tapping for 30 seconds on digital counters mounted 20 cm apart, time taken to walk 12 metres, clinical assessments of tremor and dyskinesia according to a four-point scale, and modified Webster disability scale. A test was considered positive if there was a 15% or more increase in tapping score, a 25% or more improvement in walking time, reduction of tremor score alone of a least 2 points, or an improvement of Webster's score of 3 or more. Long-term response to levodopa was also assessed. Fifty-one iPD and 7 PS patients showed a positive response to challenge testing and there were 6 false negative results in iPD cases and 2 in PS cases. There was only one questionable false positive in the iPD group. Challenge testing accurately predicted the long-term response to dopaminergic therapy in 90% of patients.

In another study of 20 iPD and 8 PS cases (5 MSA, and 3 PSP) apomorphine challenge testing was assessed by tapping and walking measures and considered positive if there was a 15% or more increase in either walking or tapping measures. The response to sustained levodopa treatment was assessed a month later. The majority of iPD patients (95%) and 25% of PS responded positively to challenge tests,

and there was one false positive in the iPD group, and two false positives and two false negatives in PS group. Again challenge testing accurately predicted the long-term response to dopaminergic therapy in 90% of patients. (D'Costa et al 1991).

In untreated iPD, Hughes et al (1991) reported a predictive accuracy of only 67% for apomorphine and 80% for levodopa. There were 13 false negative and 2 false positive apomorphine tests and 7 false negative and 2 false positive levodopa tests. After prolonged follow-up, 10% of patients showed features atypical for iPD, which may explain the relatively low predictive accuracy. Another explanation is that some patients with early iPD may have very mild parkinsonian signs, making the assessment of improvement difficult. The discrepancy between apomorphine and levodopa results has been considered as due to dose-limiting side effects of apomorphine. In another study of 62 untreated iPD cases, apomorphine had a predictive accuracy of 81%, sensitivity of 90%, and specificity of 88%. Motor function was assessed in three ways, the impression of the investigator, finger tapping and the UPDRS motor section of which the UPDRS was the best predictor (Gasser et al 1992).

Although there are some limitations in challenge testing, it can help in assessing dopaminergic responsiveness and guide appropriate therapy either by dose escalation in responsive cases, or drug withdrawal in non-responders. Positive challenge testing makes iPD likely but may also be positive in cases of MSA and PSP.

CHAPTER 2

IMAGING IN PARKINSONIAN SYNDROMES

Imaging techniques are of obvious interest in the diagnosis of parkinsonism and tremor disorders. Structural cerebral imaging (CT and MRI) identifies some causes of secondary parkinsonism, such as infarction, haemorrhage, tumours and hydrocephalus, and shows certain distinguishing features of MSA, and PSP, although these are not of adequate sensitivity for clinical practice. Recent developments in functional neuroimaging (PET and SPECT) allowed a detailed in vivo study of dopaminergic system, with its pre- and post-synaptic structures, in normal human brain and in parkinsonian patients.

Prior studies of these different techniques are now reviewed.

2.1 COMPUTERISED TOMOGRAPHY (CT)

Brain atrophy is the main CT scan finding in PS. In a study of 173 iPD patients, 51% were considered to have pathological brain atrophy (Becker et al 1979). Steiner et al (1985) reported brain atrophy in younger patients with iPD, while one in three patients were reported to have prefrontal atrophy mainly the older ones (Adam et al 1983). Brain stem atrophy is seen with PSP, usually more obvious in the later stage of the disease (Schonfeld et al 1987). In MSA Wenning et al (1994b) found 21% of 33 patients with normal CT, 42% showed infratentorial atrophy, cerebellar atrophy was present in 39% and pontine atrophy in 18%, although these findings were not thought to be particularly helpful in making a diagnosis of MSA.

Thus, atrophy affecting various parts of the brain can be identified on CT scan in PS, however, it seldom helps in diagnosis or differentiation between iPD, MSA, or PSP.

2.2 MAGNETIC RESONANCE IMAGING (MRI)

Decreased signal intensity of the putamen compared to the globus pallidus, and decreased signal intensity of the lateral substantia nigra on T2 weighted MRI is reported in MSA and PSP (Drayer et al 1986, Pastakia et al 1986, Stern et al 1989, Olanow et al 1992). However not all PSP patients have signal hypointensity in the putamen. While iPD patients and controls have normal putamen signal (Olanow et al 1987, Braffman et al 1988). The MRI changes did not differentiate PSP, MSA and atypical parkinsonism cases (Stern et al 1989). The amount of putaminal atrophy but not the degree of putaminal hypointensity correlates with the severity of MSA (Wakai et al 1994). In a study of the usefulness of MRI in MSA, Schrag et al (1998) reported that putaminal atrophy, a hyperintense putaminal rim and infratentorial signal have a high specificity but low sensitivity, while finding any infratentorial abnormality is highly sensitive but has low specificity.

The width of the substantia nigra pars compacta was reduced in iPD compared with controls on T2-weighted MRI (Duguid et al 1986, Braffman et al 1988). However, the reduction was found only in advanced and not early-stage iPD patients (Huber et al 1990). This narrowing of pars compacta was also found in MSA, PSP and atypical parkinsonism (Stern et al 1989). Olanow (1992) commented on variability, according to MRI protocols, with widths of 5.2 ± 0.15 mm in one study and 0.68 ± 0.09 mm in another, so comparison between studies is difficult.

Midbrain atrophy is another feature on MRI scanning in some patients with PSP, MSA, and atypical parkinsonism (Rutledge et al 1987, Stern et al 1989, Yagishita and Oda 1995). Also, a significant shortening of the T₂ relaxation time was found in

substantia nigra, caudate nucleus and putamen in iPD patients which is likely to be due to an increased iron concentration in these areas. However this feature was not a reliable measure to differentiate iPD patients from healthy controls (Antonini et al 1993). These changes increase in patients with more than a 10 year history of iPD (Ryvlin et al 1995).

A signal change in the dorso-lateral aspect of the substantia nigra has been described in parkinsonism and is referred to as restoration, meaning that the normally reduced signal in this brain area was found to be replaced by a signal level similar to that of brain parenchyma without iron (Rutledge et al 1987). This finding was not confirmed in a later report (Braffman et al 1988).

Thus the MRI changes in parkinsonism reflect focal atrophy which may give diagnostic clues, but these tend to be subtle or absent in early stages of the disease and are not practically useful in differentiating parkinsonism from other movement disorders or classifying parkinsonism.

2.3 FUNCTIONAL IMAGING

PET and SPECT are the two major types of functional neuroimaging. PET is not generally accessible to clinical practice due to the great expense involved in establishing a PET centre, while SPECT is less expensive and more easily available because the tracers used, (^{99m}Tc or ^{123}I based) have a longer half-life. However, SPECT measurements are semi-quantitative, and provide less reconstructed resolution than PET, which is considered a disadvantage (Brooks 1993).

2.4 PET STUDIES

2.4.1 [¹⁸F] 2-Fluoro-2-Deoxy-Glucose PET (FDG PET)

FDG PET was used to measure regional cerebral glucose metabolism in several studies of patients with parkinsonism.

De Volder et al (1989) reported significant hypometabolism in the putamen, caudate and frontal cortex in 7 patients with probable SND when compared with 16 controls using FDG PET. When compared with severity and duration matched iPD, striatal metabolism was also significantly reduced. Putamen metabolism correlated with the severity of the disease measured by UPDRS motor scores in the SND patients but caudate metabolism did not show such a correlation (Eidelberg et al 1993). Otsuka et al (1991, 1996) reported reduced striatal glucose metabolism of patients with atypical parkinsonism and MSA when compared with iPD patients, however there was no difference in the striatal and cerebral glucose metabolism between iPD and controls. In another study of 9 MSA patients, 10 iPD and 10 healthy controls, caudate glucose metabolism measured by FDG PET was not able to differentiate between the three groups. On the other hand putamen metabolism was significantly reduced in MSA when compared with controls and iPD patients. Putamen:caudate ratio was also reduced in MSA patients when compared with the other two groups. Using discriminant function analysis, caudate and putamen FDG values differentiate between MSA and iPD patients, and separate MSA from controls but not between iPD from normal control. No correlation between putamen FDG values and MSA severity was found (Antonini et al 1997). Otsuki et al (1997) showed no difference in glucose metabolic rate in frontal, temporal, caudate, putamen, cerebellar, and brain stem areas in iPD and controls. However, the metabolic rate in these areas was significantly

reduced in MSA compared to controls and iPD patients only in caudate, putamen, cerebellar, and brain stem areas. In another study 75% of 48 patients with an atypical parkinsonian disorder showed striatal abnormalities when compared with 56 patients with iPD (Antonini et al 1998).

2.4.2 *6-[¹⁸F] Fluoro-L-3, 4- Dihydroxyphenylalanine (¹⁸F-Dopa PET)*

Uptake of ¹⁸F-dopa reflects the ability of the striatum to decarboxylate dopa because the striatum handles ¹⁸F-dopa, after an intravenous injection, in a similar way to endogenous dopamine (Brooks 1993).

Early studies of ¹⁸F-dopa PET in iPD showed bilateral reduction of putamen tracer uptake, with activity being most reduced in the putamen contralateral to the affected side in patients with hemiparkinsonism (Garnett et al 1984, Nahmias et al 1985). Leenders et al (1986) confirmed these findings and found that patients with long standing iPD retain ¹⁸F-dopa less effectively than those with early disease.

¹⁸F-dopa PET as a tool for differential diagnosis of PS and tremor disorders has been used in various studies. In one such study, regional striatal ¹⁸F-dopa uptake was depressed in 16 iPD patients compared to normal subjects but there was significant sparing of the head of caudate and anterior putamen and severe involvement of the posterior putamen. In 10 PSP patients a uniform severe depression of striatal ¹⁸F-dopa uptake in the caudate, anterior and posterior putamen was demonstrated while in 18 MSA patients the reduced uptake pattern appeared to be a mixture of the features seen in iPD and PSP. The severity of disease assessed by the H&Y scale correlated with the decline in ¹⁸F-dopa uptake in iPD and MSA, but not PSP patients (Brooks et al

1990). Burn et al (1994) reported that ^{18}F -dopa PET, by using discriminant function analysis, differentiated PS patients from controls, and also, between iPD and PSP patients but not between iPD and MSA. However, no differences were found in putaminal ^{18}F -dopa uptake between 8 iPD patients and 8 atypical Parkinsonism patients in another study, but uptake in the caudate in both groups was decreased compared with normal controls with relatively sparing of caudate in iPD (Otsuka et al 1991). ^{18}F -dopa striatal uptake was correlated with the duration and severity assessed by H&Y in MSA patients (Brooks et al 1990). Antonini et al (1997) confirm that ^{18}F -dopa PET was able (using discriminant function analysis, caudate and putamen uptake, and putamen:caudate ratio) to differentiate MSA patients from healthy controls but not from iPD. Also, they found significant correlation between putaminal ^{18}F -dopa uptake and motor score using a five-point scale for rigidity, bradykinesia and tremor, but no correlation was found using the H&Y scale. On the other hand, Otsuka et al (1997) showed that ^{18}F -dopa uptake caudate-putamen index may help in differentiating MSA from iPD but 3 MSA patients out of 9 were mis-classified as iPD.

2.4.3 ^{11}C -Raclopride PET

Many PET and SPECT tracers have been developed to study striatal dopamine receptor density, which is classified as: (i) D1-like (D1, D5) which are adenylyl cyclase-dependent and (ii) D2-like (D2, D3, D4) which are not (Brooks 1993).

These receptors are present equally in the striatum. D1 receptors are primarily present on the neurones forming the direct pathway, whereas D2 receptors are present on the neurones of the indirect pathway (Strange 1993, Brooks 1993).

Brooks et al (1992a) reported normal or raised striatal D2 ^{11}C -raclopride binding potential in untreated iPD patients, and a decline in the receptor density in SND, PSP, and treated iPD with fluctuating response to levodopa, caudate being severely affected in PSP patients. This decline was less severe in PSP and SND patients than in treated iPD patients. An increase in striatal ^{11}C -raclopride binding in untreated iPD patients was reported in another series, which was higher in the striatum or putamen contralateral to the more affected side (Rinne et al 1993,1995).

Antonini et al (1997) reported that D2 ^{11}C -raclopride binding using PET was significantly reduced in both caudate and putamen in MSA when compared with healthy controls, and only in putamen when compared with iPD patients, showing the ability of ^{11}C -raclopride PET to help in differentiating MSA from healthy controls and iPD, but not iPD from healthy controls. Also, they reported significant correlation between putaminal D2 ^{11}C -raclopride binding and the H&Y scale as well as motor score using a five-point scale for rigidity, bradykinesia and tremor.

Other studies using the PET tracer ^{11}C -methylspiperone have shown normal striatal uptake in four untreated iPD patients (Leenders et al 1985). Striatal uptake was normal in another study of 6 treated patients, and slightly increased in two untreated iPD patients, while in contrast 6 SND patients showed a marked decrease in striatum uptake (Shinotoh et al 1993).

2.5 SPECT STUDIES

2.5.1 ¹²³Iodobenzamide SPECT (¹²³I-IBZM-SPECT)

A ¹²³I-IBZM SPECT study of 83 iPD patients, 13 PSP or MSA cases, and 14 controls compared to apomorphine testing and long-term oral dopaminergic therapy responses during 4 months of follow-up was reported. 20% of iPD patients had a decreased ¹²³I-IBZM uptake, and none of these cases had a positive apomorphine test. The majority of iPD patients with normal ¹²³I-IBZM binding had a positive apomorphine challenge and positive response to long-term therapy. On the other hand, all patients with MSA or PSP had abnormal ¹²³I-IBZM binding, and 6 of these patients failed to respond to apomorphine challenge or long-term dopaminergic therapy; the other 7 did not have apomorphine challenge but they did not respond to long-term dopaminergic therapy.

It has been postulated that patients with a normal ¹²³I-IBZM binding and positive apomorphine tests are likely to have iPD while patients with reduced ¹²³I-IBZM binding and a negative apomorphine test are unlikely to have iPD. The importance of these observations is the fact that *de novo* patients have inadequate clinical features to allow accurate differential diagnosis, but SPECT and challenge testing allow for greater accuracy of diagnosis at the early stage. Patients with normal ¹²³I-IBZM binding and a negative apomorphine testing are left as having an uncertain diagnosis (Schwarz et al 1993). A highly significant loss of striatal uptake of ¹²³I-IBZM in 17 MSA and 4 PSP patients was confirmed in another study, and a reduced basal ganglia to frontal lobe ratio was shown in 5 PSP patients but not in another three (van Royen et al 1993, Arnold et al 1994). In another study of 55 patients with parkinsonism in whom the response to dopaminomimetic therapy was not clear, ¹²³I-IBZM SPECT accurately predicted the response to apomorphine challenge in 84% of patients. Eight

of the nine patients who developed clinical features indicating a diagnosis other than iPD had reduced uptake (Schwarz et al 1997). Schwarz et al (1998a) found significant correlation of the results of ^{123}I -IBZM SPECT with the long-term response to dopaminomimetic therapy, the development of motor fluctuations and clinical signs incompatible with iPD.

In a comparative study of ^{123}I -IBZM with ^{11}C -raclopride PET in 19 iPD patients and 2 patients with atypical parkinsonism the qualitative D2 dopamine receptor binding results were equal (Schwarz et al 1994).

It can be concluded that most patients with MSA and PSP have reduced ^{123}I -IBZM uptake while in iPD striatal ^{123}I -IBZM uptake is usually normal. Combining ^{123}I -IBZM with apomorphine testing predicts long-term dopaminergic therapy responsiveness. However, a few iPD with normal ^{123}I -IBZM uptake have a poor response to treatment, and a small group of PS patients have normal ^{123}I -IBZM, making the interpretation of normal striatal D2 binding difficult in some parkinsonian patients.

CHAPTER 3

THE DOPAMINE TRANSPORTER SYSTEM

3.1 INTRODUCTION

The dopamine transporter, or re-uptake site, is a Na^+/Cl^- dependent pre-synaptic protein located on the membrane of dopaminergic neurone terminals, which projects from the substantia nigra to the striatum. Its function is to actively re-uptake dopamine from the synaptic cleft after the termination of its interaction with the dopamine receptors on the post-synaptic neurone, therefore controlling dopamine levels (Rudnick and Clark 1993, Amara et al 1993, Jaber et al 1997) (*Figure 3.1*).

Pathologically iPD is characterised by severe degeneration of dopaminergic neurones in the substantia nigra, while results in a marked decrease in striatal dopamine and a parallel loss of the dopamine transporter, as shown in postmortem studies (Kaufman and Madras 1991, Niznik et al 1991). This makes the dopamine transporter a potential surrogate marker for dopaminergic nigrostriatal neurones.

Using PET or SPECT to image dopamine transporters assesses the integrity of the nigrostriatal dopaminergic system, and different ligands have been developed for this purpose.

3.1.1 PET

^{11}C -nomifensine has been used in PET studies, and shows a significantly reduced uptake in striatum especially putamen in iPD compared with healthy controls. Putamen uptake side-to-side differences was also correlated with left-right differences of motor function (Tedroff et al 1988, Leenders et al 1990).

The labelled cocaine-like ligand ^{11}C -WIN35,428 also shows marked loss of dopamine transporters in caudate and putamen, especially its posterior portion (Frost et al 1993). Using a similar ligand, [^{11}C] RTI-32, a PET study in 11 early iPD patients with an average UPDRS motor score of 11 compared to 10 healthy control, a significant reduction in the uptake was found in the putamen, again more in the posterior portion, but not in the caudate. No correlation between uptake and UPDRS was found (Guttman et al 1997).

3.1.2 SPECT

Bilateral loss in striatal ^{123}I - β -CIT uptake using SPECT was shown in hemiparkinsonism (Marek et al 1996, Brucke et al 1997). In a study of 113 iPD, 9 MSA, and 4 PSP patients ^{123}I - β -CIT SPECT demonstrated bilateral asymmetrical loss of dopamine transporters. It was not possible however, to differentiate between iPD, MSA, and PSP. There was correlation between ^{123}I - β -CIT binding ratios and severity of the parkinsonism assessed by H&Y and UPDRS. This correlation was significant for total UPDRS motor score, activities of daily living, rigidity, akinesia, and axial symptoms but not tremor (Brucke et al 1997). In another study, H&Y scale, total UPDRS, motor UPDRS, and UPDRS bradykinesia but not the tremor measures were correlated with age-corrected specific to non-displaceable striatal ^{123}I - β -CIT uptake. Interestingly, ipsilateral but not contralateral putamen:caudate ratio correlated with the total UPDRS but not other measures (Seibyl et al 1995). Recently, ^{123}I - β -CIT uptake was shown to be reduced in putamen in both iPD and PSP patients. However, PSP patients demonstrate a significantly reduced uptake of 72% in the head of the caudate compared to only a 47% reduction in iPD, enabling 10 out of 13 iPD cases to

be differentiated from PSP. No correlation between disease duration or severity using H&Y and UPDRS scale was found (Messa et al 1998).

^{123}I - β -CIT SPECT imaging is reproducible with a correlation coefficient of 96% for the ratio of specific striatal uptake to non-specific uptake, and 98% for the total specific striatal uptake expressed as a percentage of injected radioactivity in 7 iPD patients and 7 healthy controls (Seibyl et al 1997).

A practical disadvantage of ^{123}I - β -CIT is its slow kinetics, as striatum radioactivity increases for 20 hours after injection, so that imaging is undertaken on the day after injection (Laruelle et al 1994). On the other hand ^{123}I -FP-CIT, which shows marked association with dopamine transporters in animal studies (Booij et al 1997a), and has tested in iPD and healthy volunteers shows faster kinetics allowing SPECT imaging to be taken 3-6 hours after injections (Booij et al 1998a, 1999).

A comparison of ^{123}I FP-CIT with ^{123}I - β -CIT was undertaken in 5 drug-naive iPD patients who had two consecutive SPECT scans 12 weeks apart using both ligands. The uptake ratio of both ligands, in caudate and putamen, when expressed as a percentage of healthy controls showed similar decreases and variability of data. Therefore, ^{123}I -FP-CIT and ^{123}I - β -CIT offer equal quality in assessment of dopaminergic deficit in iPD (Booij et al 1997b).

^{123}I -FP-CIT striatal uptake is reduced using SPECT in early and advanced iPD and also in hemiparkinsonism. No correlation between uptake and disease motor severity assessed by the UPDRS motor section was found (Booij et al 1997c, Tissingh et al

1998), which contrasts with results from a ^{123}I - β -CIT study (Brucke et al 1997). On the other hand Ishikawa et al (1996) showed a correlation between iPD severity and ^{123}I -FP-CIT in 12 mildly affected patients (H&Y I and II).

^{123}I -FP-CIT SPECT is reliable and reproducible, based on a study of 10 iPD patients and 6 healthy volunteers, with a correlation coefficient of 100% using a region of interest protocol to measure the ratio of the striatal to non-specific uptake, and a correlation of 96% using volume of interest protocol (Booij et al 1998b).

In conclusion ^{123}I -FP-CIT SPECT is a reliable method to assess dopamine transporters and therefore the pre-synaptic dopaminergic nerve terminals. With its fast kinetics ^{123}I -FP-CIT has a major advantage over ^{123}I - β -CIT in routine clinical practice.

Figure 3.1 A schematic diagram of the dopaminergic nerve terminal.

Synaptic cleft

Dopamine

Dopamine

Dopamine vesicles

Post-synaptic
neurone

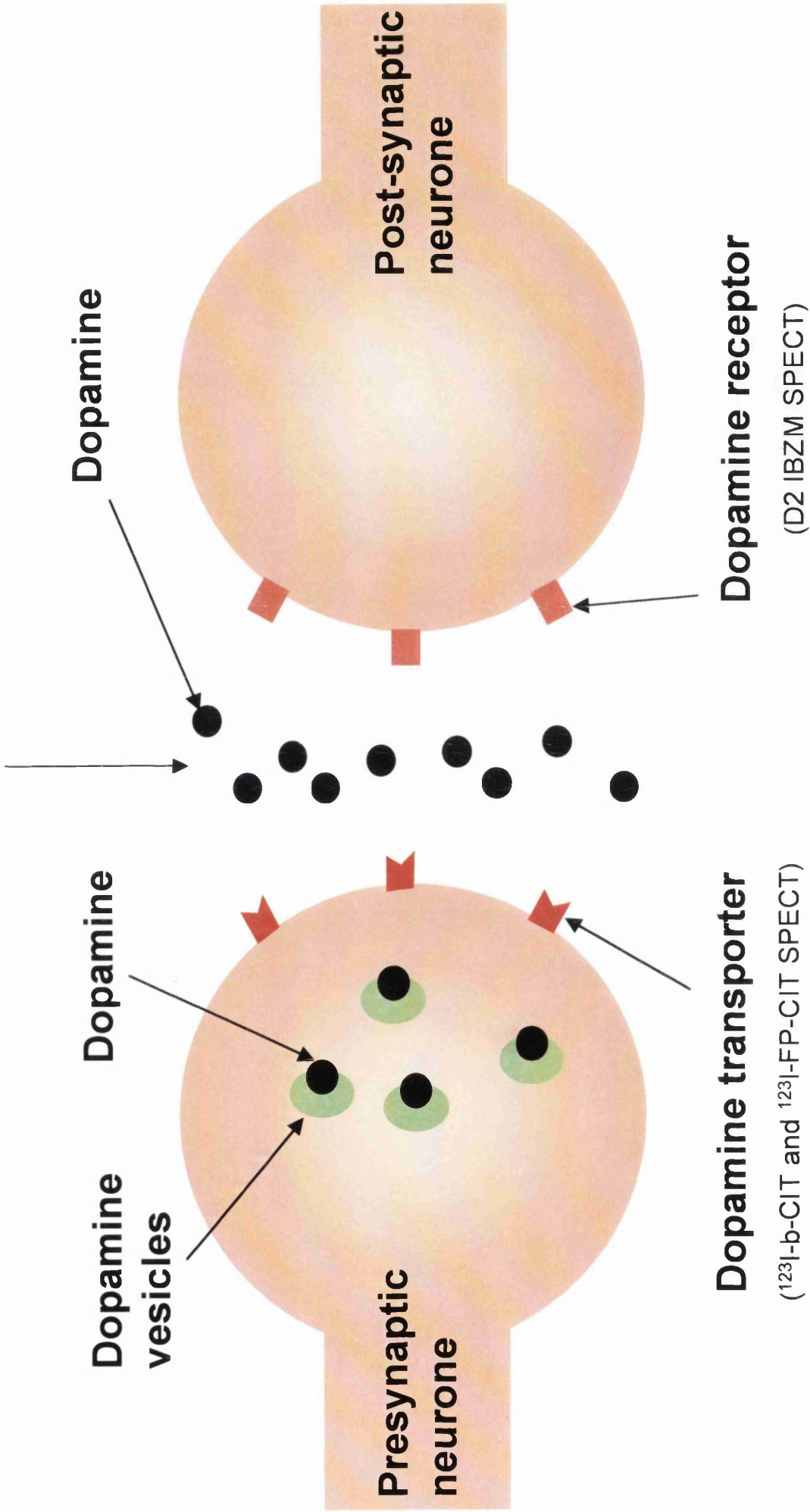
Dopamine receptor

(D2 IBZM SPECT)

Presynaptic
neurone

Dopamine transporter

(¹²³I-b-CIT and ¹²³I-FP-CIT SPECT)



CHAPTER 4

STUDY 1

***¹²³I-FP-CIT SPECT IMAGING AS A TOOL TO
DIFFERENTIATE PARKINSONISM AND
ESSENTIAL TREMOR***

4.1 INTRODUCTION

Essential tremor is one of the conditions most commonly misdiagnosed as parkinsonism, and early clinical differentiation between these conditions can be difficult, with up to 29% of patients initially diagnosed as iPD later having their diagnosis changed to ET (Marshall 1962, Critchley 1972, Marttila et al 1976a, Larsen and Calne 1983, Koller 1984, Meara et al 1999). Differentiation between parkinsonism and ET is important in defining prognosis, which is relatively benign in ET compared with parkinsonism, in treatment decisions, and in defining patients accurately for research. There is therefore a need to improve the accuracy of differentiating patients with ET from those with parkinsonism. Also, differentiation of iPD from other causes of parkinsonism, mainly MSA and PSP can be difficult and clinico-pathological studies suggest that the clinical diagnosis of iPD is only 76% reliable (Hughes et al 1991, Rajput et al 1991a).

The aim of this study is to assess the clinical application of ^{123}I -FP-CIT SPECT to differentiate between parkinsonism and ET and to assess whether this technique can help in differentiating between iPD, MSA, and PSP.

4.2 METHODS

4.2.1 Study subjects

Parkinsonian syndrome and essential tremor patients were selected from patients attending the movement disorder clinics or general neurology clinics. Healthy volunteers were selected from patient spouses and via advertisement at the study site.

Patients of either sex, within an age of 40-80 years, were first defined as having Parkinsonian syndrome (PS) and secondly classified as iPD, MSA, PSP, each on the basis of standard clinical criteria. Thus patients were selected on the basis of bradykinesia with rigidity and/or tremor, as defined by UK Brain Bank criteria step 1 (Gibb and Lees 1988), without evidence of cerebrovascular disease, structural brain disease (cranial imaging if clinically suspected), dementia, head injury or encephalitis. Thereafter disease specific criteria were applied, as follows:

For idiopathic Parkinson's Disease: Patients with established disease were required to fulfil the UK Brain Bank criteria step 3 - supportive prospective positive criteria, thus three or more from unilateral onset, rest tremor, progressive, persisting asymmetry affecting side of onset most, excellent response (70-100%) to levodopa, severe levodopa-induced chorea, levodopa response for 5 years or more, and clinical course of 10 years or more. However, *de novo* patients were required only to have a positive response to apomorphine or levodopa challenge test which was defined as an improvement of at least 30% determined by using the UPDRS - motor section.

For Multiple System Atrophy: Consensus Committee of the American Autonomic Society and the American Academy of Neurology diagnostic criteria (1996) were applied: (i) Parkinsonism (bradykinesia with rigidity or tremor or both), usually with a poor or unstained motor response to chronic levodopa therapy; (ii) Cerebellar or corticospinal signs; (iii) Orthostatic hypotension, impotence, urinary incontinence or retention, usually preceding or within 2 years after the onset of the motor symptoms.

For Progressive Supranuclear Palsy: The National Institute of Neurological Disorders and Stroke and the Society for PSP clinical research diagnostic criteria was applied (Litvan et al 1996) being a gradual, progressive disorder, onset at age 40 years or older, vertical supranuclear palsy, and prominent postural instability with falls in the first year of disease onset, as mandatory criteria, and supported by any of the following: slowing of vertical saccades, symmetric akinesia or rigidity proximal more than distal, abnormal neck posture, especially retrocollis, early dysphagia and dysarthria, early onset of cognitive impairment with at least two of apathy, impairment in abstract thought, decreased verbal fluency, utilisation or imitation behaviour, or frontal release signs; and with evidence of a poor or absent response to chronic levodopa therapy. For PSP, exclusion of clinical features suggesting alternative diagnoses such as Cortico-Basal Ganglionic Degeneration, Alzheimer's disease, or MSA were applied.

For Essential Tremor: Patients with a working clinical diagnosis of ET were screened for inclusion in the study. Clinical features were reassessed according to Findley and Koller (1994), thus excluding patients with abnormal neurological signs, causes of enhanced physiological tremor including hyperthyroidism, exposure to tremorogenic drugs, possible psychogenic tremor, or with any evidence of sudden onset or stepwise deterioration. In addition, patients with a first degree relative diagnosed with iPD were excluded. The definite ET criteria were fulfilled being a duration of at least 5 years and bilateral postural tremor with or without kinetic tremor, involving hands or forearms, that is visible and persistent, with at times tremor of other body parts, bilateral postural tremor which may be asymmetric, tremor

reported by the patient to be persistent although the amplitude may fluctuate and tremor not necessarily producing disability.

Healthy volunteers of either sex, within an age range of 50-80 years, underwent a general health screening questionnaire and clinical examination, and had no history of psychiatric illness.

For all patients with PS or ET and for volunteers, any drug intake with the potential to interact with striatal uptake of ^{123}I -FP-CIT by the dopamine transporter was disallowed, such as some CNS stimulants (amphetamine), anti-anorexia and obesity treatments, sympathomimetics including some nasal decongestants, the anti-depressants amoxapine and buspirone, and anti-parkinsonian drugs selegiline and benzotropine. The minimum wash out period for all such therapy was 4 weeks except for selegiline which was 7 days, and was considered sufficient to eliminate its amphetamine by-products. Standard comorbid renal, hepatic, and cardiac conditions and drug or alcohol misuse were excluded.

4.2.2 Study assessments

Six European centres were involved in the study, because of the large number of patients required for the study (section 4.2.5), which could take a single centre between 4 and 12 years to recruit the subjects. The Glasgow centre was the largest contributor (more than 30% of the study subjects).

Patients and volunteers gave written informed consent and the study was approved by the Ethics Committee in each study site. Standard safety assessments (vital signs,

physical examination, laboratory tests) were conducted at baseline and repeated at least twice during the study period. Parkinsonian syndrome patients were assessed using UPDRS motor section and H&Y rating scales in 'practically-defined off', following withdrawal of anti-parkinsonian therapy for 12 hours.

Patients and healthy volunteers reported any adverse events occurring after ^{123}I -FP-CIT injection, with a follow-up visit at 24-72 hours and a seven day telephone questionnaire. Female subjects of reproductive age were advised to avoid conception for at least three complete menstrual cycles post-injection.

4.2.3 Imaging

All subjects underwent thyroid blocking according to an established site protocol. An intravenous injection of ^{123}I -FP-CIT containing activity in the range 111-185 MBq was given over approximately 15 seconds followed by a saline flush. SPECT imaging was conducted 3-6 hours post-injection. SPECT images were obtained using a site specific gamma camera system (multi-detector single slice system in 3 centres, a triple headed camera system in 2 centres and a double headed camera system in one centre). Each system provided transverse slices with clear visualisation of the head of the caudate nucleus and putamen.

4.2.4 Data analysis

Visual Assessment

The primary endpoint for the study was designated the institutional read, and consisted of visual assessment of ^{123}I -FP-CIT striatal uptake. This was conducted on scans reconstructed to the highest usable resolution in each centre by an investigator

blinded to clinical data. The secondary endpoint of the study was designated the consensus blinded read, and was conducted on uniform reconstruction of electronic raw data using an identical colour scale and format for each image. The resultant hard copy images were randomised for the blinded read panel, consisting of a neurologist with limited experience in assessing ^{123}I -FP-CIT images and four nuclear medicine physicians experienced in ^{123}I -FP-CIT imaging. Each panel member evaluated the SPECT images independently and blinded to the clinical data. Where there was agreement from three or more individual blinded readers, this was taken as the consensus blinded read.

A predefined classification was used, as follows (*Figure 4.1*):

Normal: characterised by uptake of the tracer in both right and left putamen and caudate nuclei. The image is largely symmetrical with approximately equal levels of uptake on both left and right sides. Activity is contained close to the centre image, forming two crescents shaped areas of uptake.

Abnormal: can be described in one of three ways:

(i) Abnormal ^{123}I -FP-CIT SPECT image grade 1:

Uptake is symmetrical with almost normal or reduced putamen activity in one hemisphere and a significantly lower or absent uptake in the putamen on the other side.

(ii) Abnormal ¹²³I-FP-CIT SPECT image grade 2:

Uptake is significantly reduced in the putamen on both the right and left sides.

Activity is confined to the caudate nuclei and forms two roughly circular areas.

(iii) Abnormal ¹²³I-FP-CIT SPECT image grade 3:

Uptake is virtually absent from both putamen and caudate nuclei on each side of the brain resulting in a significant reduction in contrast and the visualisation of background activity throughout the rest of the image.

Semi-quantitative assessments

All data were collected and analysed in one centre in standardised form. Semi-quantitative assessment was based on region of interest (ROI) analysis. The total amount of tracer in the striatum consists of dopamine transporter bound ligand and nonspecifically bound ligand. A correction for nonspecifically bound ¹²³I-FP-CIT is made as follows, uptake per unit area in a reference region, representing nonspecific uptake, is subtracted from the total recorded activity uptake per unit area in the striatum. The occipital cortex was used as a suitable reference region, being nearly devoid of dopamine transporter binding sites but receiving an equal supply of tracer from the vascular compartment.

A standard template was used, with fixed ROIs corresponding to caudate nucleus, putamen and occipital cortex according to the stereotactic atlas of Matsui and Hirano (1978). For analysis of the regional activity distribution in various images, the size and shape of each structure shown on the template was not changed and the template's region of interest was placed over the image corresponding to each of the regions of interest.

Semi-quantitative ROI analysis was used as a secondary study endpoint. Three measurement methods were adopted:

Specific:nonspecific ratio (SP:NS)	$\frac{\text{Specific uptake in striatal ROI}}{\text{Mean occipital ROI uptake}}$
Putamen:caudate ratio (P:C)	$\frac{\text{Specific uptake in putamen ROI}}{\text{Specific uptake in caudate ROI}}$
Asymmetry Index (AI)	$\frac{100x(\text{Specific uptake ipsilateral-contralateral})}{0.5x(\text{Specific uptake ipsilateral+contralateral})}$

4.2.5 Statistical analysis

Sample size was based on a one-sided 5% significance level, a power of 80%, and on the assumption that 95% of parkinsonism patients have abnormal $^{123}\text{I-FP-CIT}$ striatal uptake, and 5% of ET patients have abnormal $^{123}\text{I-FP-CIT}$ uptake. This was calculated as 118 parkinsonism patients, and 30 ET patients.

Sensitivity of $^{123}\text{I-FP-CIT}$ striatal uptake for parkinsonism was calculated as number of abnormal SPECT images / (number of abnormal SPECT images + number of normal SPECT images). Specificity for ET was calculated as number of normal SPECT images / (number of normal SPECT images + number of abnormal SPECT images).

Both per-protocol (all subjects enrolled with an available $^{123}\text{I-FP-CIT}$ SPECT image who did not violate the protocol), and intention-to-treat analysis (all subjects recruited with an available $^{123}\text{I-FP-CIT}$ SPECT image) were conducted. Analysis of variance models presented type III sums of squares. Response rates used a one sided 95% confidence lower boundary level. All p-values were two-sided and set at 5% significance. Differences in binary response rate of abnormal/normal striatal uptake

were analysed using Fisher's exact and Wilcoxon rank sum tests as appropriate. For semi-quantitative analysis, ANOVA techniques were used.

Comparisons of striatal uptake in iPD, MSA, PSP and healthy volunteers were made by one-way analysis of variance with Bonferroni correction for pre-specified multiple comparisons.

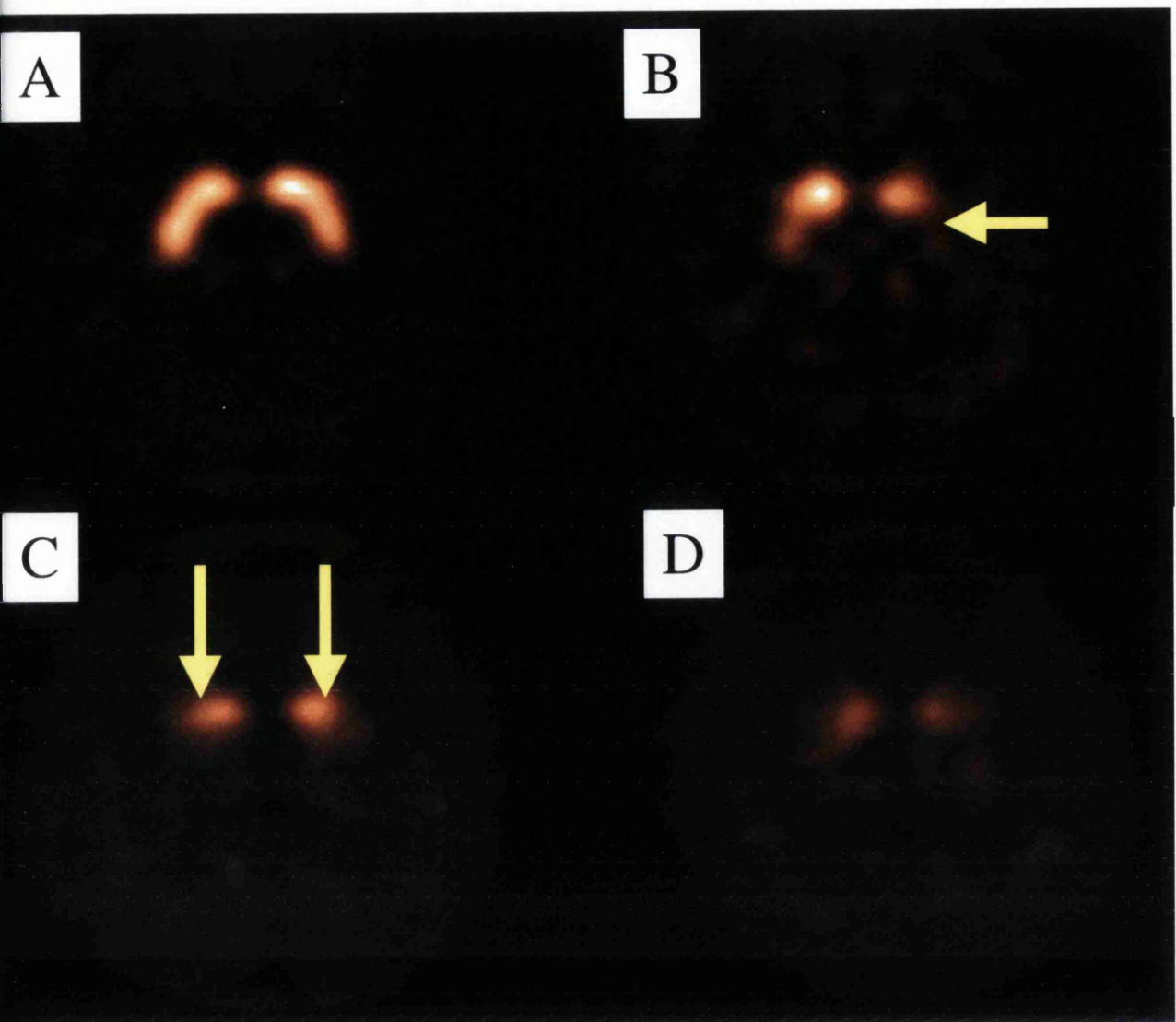
Figure 4.1 Example of ^{123}I -FP-CIT images in normal and parkinsonism cases.

A) *Normal* tracer uptake in both right and left putamen and caudate nuclei.

B) *Abnormal image grade 1*: Asymmetric uptake with normal or almost normal putamen activity in one hemisphere and with a more marked reduction in the contralateral putamen (arrow).

C) *Abnormal image grade 2*: Significant bilateral reduction in putamen uptake, with activity confined in the caudate nuclei (arrows).

D) *Abnormal image grade 3*: Virtually absent uptake bilaterally affecting both putamen and caudate nuclei.



4.3 RESULTS

4.3.1 Study Populations

Two hundred and ten patients and 38 matched healthy volunteers (*Tables 4.1,4.2*) were screened, 177 (84.3%) diagnosed clinically as parkinsonism and 33 (15.7%) as ET. The parkinsonism patients were further classified as iPD 145 (82%), MSA 22 (12%) and PSP 10 (6%). Of the twenty one patients and 3 healthy volunteers excluded from the study, most withdrew consent, and in addition 4 patients did not have SPECT images after receiving ^{123}I FP-CIT injections (three due to failure of the imaging equipment and one withdrew from the study after receiving the injection). Of the 220 subjects who had SPECT images and were defined as intention-to-treat, 63 were excluded from per-protocol analysis, mainly because of injection dosage being outwith the range 111-185 MBq and/or had imaging was performed outside the 3-6 hour post-injection interval (n=51). Fourteen cases were excluded from per-protocol analysis because of errors in recording clinical criteria therefore they failed one or more inclusion/exclusion criteria.

In Glasgow, cases were identified for possible inclusion by reviewing the hospital case records of 211 patients mostly attending the movement disorder clinic, and 41 patients with a diagnosis other than iPD, MSA, PSP or ET and a further 57 patients were excluded as unsuitable mainly because of concomitant disease, or distance from hospital. Of the remainder 113 patients, 24 patients were not able to attend and 89 patients and 7 healthy volunteers were asked to participate, and 12 patients declined. Seventy-seven patients (51 iPD, 9 MSA, 3 PSP, and 14 ET) and seven healthy volunteers were screened; nine patients and one healthy volunteer withdrew consent. A further 7 patients were excluded from the study, of whom three failed inclusion

criteria, one had abnormal laboratory results, and three had unobtainable SPECT images for technical reasons. A total of 6 healthy volunteers, 44 iPD, 6 MSA, 3 PSP, and 8 ET contributed to the study at the Glasgow site. Of the 67 subjects who have SPECT images, 3 were included in intention-to-treat analysis but excluded from per-protocol analysis because of errors in recording clinical criteria.

The H&Y score in intention-to-treat patients was I in 35 cases, II in 48 cases, III in 25 cases, IV in 17 cases and V in 5 cases, and in per-protocol patients was I in 23 cases, II in 38 cases, III in 14 cases, IV in 14 cases and V in 4 cases. The median UPDRS motor score was 21 (interquartile range 14-34).

4.3.2 Visual Assessments

Institutional read

In the per-protocol population the institutional reading scored 111 of 115 (96.5%) cases of parkinsonism abnormal, all 16 cases (100%) of ET as normal, and all 26 healthy volunteers as normal (100%). For the intention-to-treat population 154 of 158 (97.5%) cases of parkinsonism score abnormal, all 27 cases (100%) of ET score normal, and 34 of 35 healthy volunteers scored normal (97.1%) (*Table 4.3*). The institutional read was not able to differentiate between iPD, MSA and PSP (*Table 4.4*).

The overall sensitivity for the per-protocol and intention-to-treat populations for the institutional read was 97% and specificity was 100%.

In the institutional read the 4 parkinsonism patients with a normal ^{123}I -FP- CIT study were common to the per-protocol and intention-to-treat groups. Three had a clinical diagnosis of iPD and one had PSP.

Consensus blinded read

In the per-protocol population the blinded reading scored 109 of 115 (94.8%) cases of parkinsonism abnormal, 15 of 16 cases (93.8%) with ET as normal, and 24 of 26 (92.3%) healthy volunteers as normal. For the intention-to-treat population 150 of 158 (94.9%) cases of parkinsonism scored abnormal, 25 of 27 (92.6%) ET scored normal, and 33 of 35 (97.1%) healthy volunteers scored normal (*Table 4.3*). The blinded read was not able to differentiate between iPD, MSA and PSP.

The overall sensitivity for the per-protocol and intention-to-treat populations for the blinded read was 94.8% and specificity was 93.2%.

Of the 150 patients with parkinsonism who scored abnormal in the consensus blinded read, there was agreement amongst all 5 investigators in 143 patients; 6 patients were scored abnormal by 4 of 5 investigators; and 1 patients was scored abnormal by 3 of 5 investigators. Four patients with parkinsonism were scored normal by all 5 investigators; 3 parkinsonism patients were normal according to 4 of 5 investigators; 1 additional case was scored normal by 3 of 5 investigators. In the healthy volunteers 29 of 33 were scored normal by all 5 investigators, 3 were scored normal by 4 of 5 investigators and one patient was scored normal by 3 of 5 investigators. One of two controls was scored abnormal by 4 of 5 investigators while one was scored abnormal by 3 of 5 investigators.

In addition to the 4 parkinsonian patients scored as normal in the institutional read, 4 more parkinsonian patients were scored as normal by the blinded read of whom 2 had a clinical diagnosis of iPD, and 2 had a clinical diagnosis of MSA. Two patients with clinical diagnosis of ET were scored abnormal in the blinded read.

Visual assessment in mild unilateral iPD (H&Y I)

Of the 23 iPD cases with H&Y stage I (in the per-protocol analysis group), only one patient scored normal by the institutional read. Of the 35 iPD cases with H&Y stage I (in the intention-to-treat analysis group), only one scored normal in the institutional read. The same result was obtained in the blinded read for the 23 iPD cases in the per-protocol analysis group i.e. one patient was scored normal. Of the 35 iPD cases (H&Y I, intention-to-treat analysis group), the blinded read scored normal in 2 cases.

Correlation of visual assessment with disease severity and duration

The grading of the institutional read of 41 iPD patients (Glasgow site) was significantly correlated with the disease severity assessed by H&Y ($r=-0.59$, $p<0.0001$) and UPDRS ($r=-0.52$, $p=0.0006$). Also, there was significant correlation between disease duration and visual grading ($r=-0.62$, $p<0.0001$).

Effect of the disease severity on the visual assessment

There was no effect of H&Y grade for abnormal/normal striatal uptake in either institutional read for per-protocol iPD cases ($p=0.689$) or intention-to-treat iPD patients ($p=0.716$) or in the consensus blinded read for per-protocol iPD ($p=0.662$) or intention-to-treat iPD patients ($p=0.337$) (Table 4.5).

Effect of investigational centre on the visual assessment

There was no effect of investigation centre for abnormal/normal striatal uptake in either institutional read for per-protocol PS ($p=0.327$) or ET or intention-to-treat PS ($p=0.456$) or consensus blinded read for per-protocol PS ($p=0.06$) or ET ($p=0.125$) and intention-to-treat PS ($p=0.227$) or ET ($p=0.182$). The data for institutional read and blinded read according to investigation centre is shown in *Table 4.6*, the tabular score is provided on the basis that PS patients are expected to have an abnormal scan and that ET patients are expected to have a normal scan.

Effect of age on the visual assessment

There was no effect of age for abnormal/normal striatal uptake in either institutional read for per-protocol PS ($p=0.942$) or ET and intention-to-treat PS ($p=0.838$) or consensus blinded read for per-protocol PS ($p=0.774$) or ET ($p=0.723$) or intention-to-treat PS ($p=0.93$) or ET ($p=0.884$) (*Table 4.7*).

4.3.3 Semi-quantitative Analysis

Specific:nonspecific uptake ratios

There were no differences in mean striatum, caudate, or putamen SP:NS ratios between ET patients and healthy volunteers. Uptake ratios were however significantly reduced in parkinsonism ($p<0.001$) (*Figure 4.2*). Also, patients with unilateral iPD (H&Y I) showed significant reduction in SP:NS putamen uptake bilaterally (*Figure 4.3*). There were no significant differences in the mean striatum, caudate, or putamen uptake ratios between iPD, MSA, and PSP (*Figure 4.4*).

Asymmetry index

There were no differences in mean striatum, caudate, or putamen asymmetry indices between ET patients and healthy volunteers, however the indices were significantly high in parkinsonism ($p < 0.001$) (*Figure 4.5*).

There were no significant differences in the striatum or caudate asymmetry indices between iPD [7.1 (CI 5.5, 8.7), 8.2 (6.3, 10)], MSA [2.4 (-2.5, 7.3), 3.6 (-3, 10)] and PSP [-0.68 (-7.4, 6.0), -0.76 (-7.4, 5.9)] but putamen asymmetry index was significantly lower in MSA ($p < 0.01$) and PSP ($p < 0.001$). There was overlap between the asymmetry indices in the three groups but patients with an asymmetry index greater than 5.0 were more likely to have iPD than either MSA or PSP (*Figure 4.6*).

Putamen:caudate ratios

There were no differences between putamen:caudate ratios between ET patients and healthy volunteers, however the ratios were significantly reduced in parkinsonism ($p < 0.001$) (*Figure 4.7*). Moreover, there were no significant difference in the putamen:caudate ratios between iPD, MSA, and PSP (*Figure 4.8*).

4.3.4 Adverse Events

Of these adverse events 2 were considered severe. One patient had headache and the one had extrapyramidal symptoms, but neither was considered by the investigator to be related to ^{123}I -FP-CIT injection. Of 65 adverse events in 36 subjects, (43 in parkinsonism cases, 13 in ET cases, and 9 in healthy volunteers), thirty (46%) were thought to be probably or possibly related to ^{123}I -FP-CIT, adverse events reported in more than 1% of the 224 subjects is shown in *Table 4.8*.

Table 4.1 Study population: 158 patients with parkinsonian syndrome, 27 with essential tremor and 35 healthy volunteers

248 Subjects Screened

220 subjects included and 28 subjects excluded

	Per-protocol	Intention-to-treat
Parkinsonian Syndrome	115	158
Idiopathic Parkinson's disease	93	130
Multiple system atrophy	14	18
Progressive supranuclear palsy	8	10
Essential Tremor	16	27
Healthy volunteers	26	35

Table 4.2 Demographic data of 158 patients and 35 healthy volunteers enrolled to ¹²³I-FP-CIT SPECT.

		Parkinsonism		Essential Tremor		Healthy Volunteers	
		Intent- to-treat (n=158)	per- protocol (n=115)	Intent- to-treat (n=27)	per- protocol (n=16)	Intent- to-treat (n=35)	per- protocol (n=26)
Institutional read	Normal	4 (2.5%)	4 (3.5%)	27 (100%)	16 (100%)	34 (97.1%)	26 (100%)
	Abnormal	154 (97.5%)	111 (96.5%)	0 (0%)	0 (0%)	1 (2.9%)	0 (0%)
Consensus blinded read	Normal	8 (5.1%)	6 (5.2%)	25 (92.6%)	15 (93.8%)	33 (94.3%)	24 (92.3%)
	Abnormal	150 (94.9%)	109 (94.8%)	2 (7.4%)	1 (6.3%)	2 (5.7%)	2 (7.7%)

Data are mean (SD)

Table 4.3 Results of institutional read and consensus blinded read of ¹²³I-FP-CIT

SPECT according to clinical diagnosis.

		Parkinsonism		Essential Tremor		Healthy Volunteers	
		Intent-to-treat (n=158)	per-protocol (n=115)	Intent-to-treat (n=27)	per-protocol (n=16)	Intent-to-treat (n=35)	per-protocol (n=26)
Institutional read	Normal	4 (2.5%)	4 (3.5%)	27 (100%)	16 (100%)	34 (97.1%)	26 (100%)
	Abnormal	154 (97.5%)	111 (96.5%)	0 (0%)	0 (0%)	1 (2.9%)	0 (0%)
Consensus blinded read	Normal	8 (5.1%)	6 (5.2%)	25 (92.6%)	15 (93.8%)	33 (94.3%)	24 (92.3%)
	Abnormal	150 (94.9%)	109 (94.8%)	2 (7.4%)	1 (6.3%)	2 (5.7%)	2 (7.7%)

Table 4.4 ^{123}I -FP-CIT institutional read results according to type of parkinsonism in the intention-to-treat population.

	Normal	Abnormal		
		Grade 1	Grade 2	Grade 3
Idiopathic Parkinson's disease (n=130)	3	30	68	29
Multiple system atrophy (n=18)	0	2	10	6
Progressive supranuclear palsy (n=10)	1	1	4	4

Normal (grade 0): Symmetrical uptake in both right and left caudate and putamen.

Abnormal (grade 1): Uptake is symmetrical with almost normal or reduced putamen activity in one hemisphere and a more marked change on the other side.

Abnormal (grade 2): Uptake is significantly reduced in the putamen on both the right and left sides.

Abnormal (grade 3): Uptake is virtually absent from both putamen and caudate nuclei on each side.

For more detailed definition of abnormal scan types, see methods section.

Table 4.5 ¹²³I-FP-CIT institutional read results according to severity of idiopathic Parkinson's disease as assessed by H&Y scale.

	Institutional read		Blinded read	
	per-protocol	ITT	per-protocol	ITT
H&Y I	95.7% (22/23)	95.1% (34/35)	95.7% (22/23)	94.3% (33/35)
H&Y II	97.4% (37/38)	97.9% (47/48)	94.4% (36/38)	95.8% (46/48)
H&Y III	92.9% (13/14)	96.0% (24/25)	92.9% (13/14)	96.0% (24/25)
H&Y IV	100% (18/18)	100% (22/22)	100% (18/18)	100% (22/22)

ITT = intention-to-treat
H&Y = Hoehn and Yahr

Table 4.6 ¹²³I-FP-CIT institutional read results according to study centre in patients with parkinsonian syndrome and essential tremor.

Population		Institutional read		Blinded read	
		per-protocol	ITT	per-protocol	ITT
Parkinsonian syndrome	Centre I	100% (9/9)	100% (23/23)	100% (9/9)	95.7% (22/23)
	Centre II	94.7% (18/19)	96% (24/25)	94.7% (18/19)	96% (24/25)
	Centre III	98% (49/50)	98.1% (52/53)	98% (49/50)	98.1% (52/53)
	Centre IV	95.8% (23/24)	96.2% (25/26)	91.7% (22/24)	92.3% (24/26)
	Centre V	100% (8/8)	100% (21/21)	100% (8/8)	95.2% (20/21)
	Centre VI	80% (4/5)	90% (9/10)	60% (3/5)	80% (8/10)
Essential tremor	Centre I	100% (1/1)	100% (5/5)	0.0% (0/1)	60% (3/5)
	Centre II	100% (2/2)	100% (5/5)	100% (2/2)	100% (5/5)
	Centre III	100% (8/8)	100% (8/8)	100% (8/8)	100% (8/8)
	Centre IV	100% (2/2)	100% (2/2)	100% (2/2)	100% (2/2)
	Centre V	100% (2/2)	100% (4/4)	100% (2/2)	100% (4/4)
	Centre VI	100% (1/1)	100% (3/3)	100% (1/1)	100% (3/3)

ITT = intention-to-treat

Table 4.7 ^{123}I -FP-CIT institutional read results according to age in patients with parkinsonian syndrome and essential tremor.

	Age	Institutional read		Blinded read	
		per-protocol	ITT	per-protocol	ITT
Parkinsonian syndrome	31-40	100% (1/1)	100% (1/1)	100% (1/1)	100% (1/1)
	41-50	90% (9/10)	94.1% (16/17)	90% (9/10)	94% (16/17)
	51-60	100% (27/27)	100% (40/40)	96.3% (26/27)	95% (38/40)
	61-70	96.1% (49/51)	97% (65/67)	94.1% (48/51)	95.5% (64/67)
	71-80	96.2% (25/26)	97% (32/32)	96.2% (25/26)	93.9% (31/33)
Essential tremor	40-50	100% (1/1)	100% (2/2)	100% (1/1)	100% (2/2)
	51-60	100% (5/5)	100% (7/7)	100% (5/5)	100% (7/7)
	61-70	100% (8/8)	100% (11/11)	87.5% (7/8)	81.1% (9/11)
	71-80	100% (2/2)	100% (7/7)	100% (2/2)	100% (7/7)

ITT = intention-to-treat

Table 4.8 Adverse events reported in more than 1% of 224 subjects given ^{123}I -FP-CIT.

Adverse event	Number of events in patients	Number of events in healthy volunteers
Headache	15	2
Flu like symptoms	4	2
Injection site bleeding	4	1
Vertigo	4	0
Parasthesia	3	0

Figure 4.2 Mean specific:nonspecific uptake ratio in per-protocol patients with parkinsonism (n=115), essential tremor (n=16) and healthy volunteers (n=27).

Specific:nonspecific ratio is significantly reduced in parkinsonism as compared to essential tremor and healthy volunteers ($p < 0.001$).

Data are mean and 95% confidence interval.

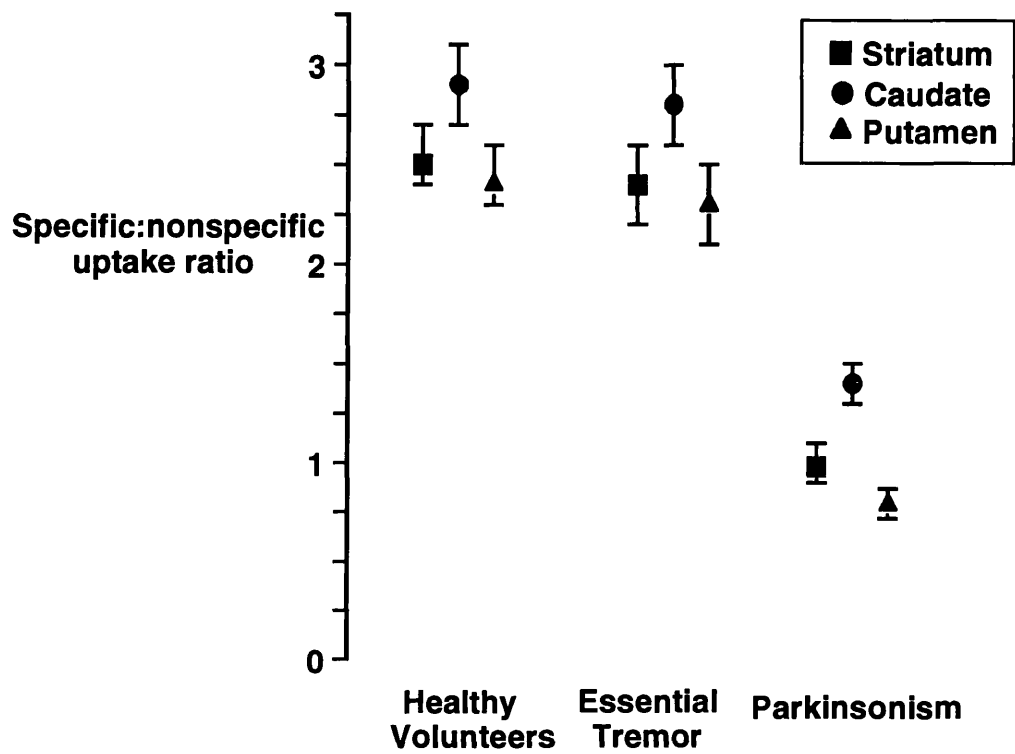


Figure 4.3 Presymptomatic putamen, and early symptomatic putamen uptake ratios in per-protocol patients with idiopathic Parkinson's disease (H&Y stage I, n=23) compared to healthy volunteers (n=26).

There was a significant reduction in both symptomatic and presymptomatic hemispheres ($p < 0.001$).

Data are mean (95% confidence interval).

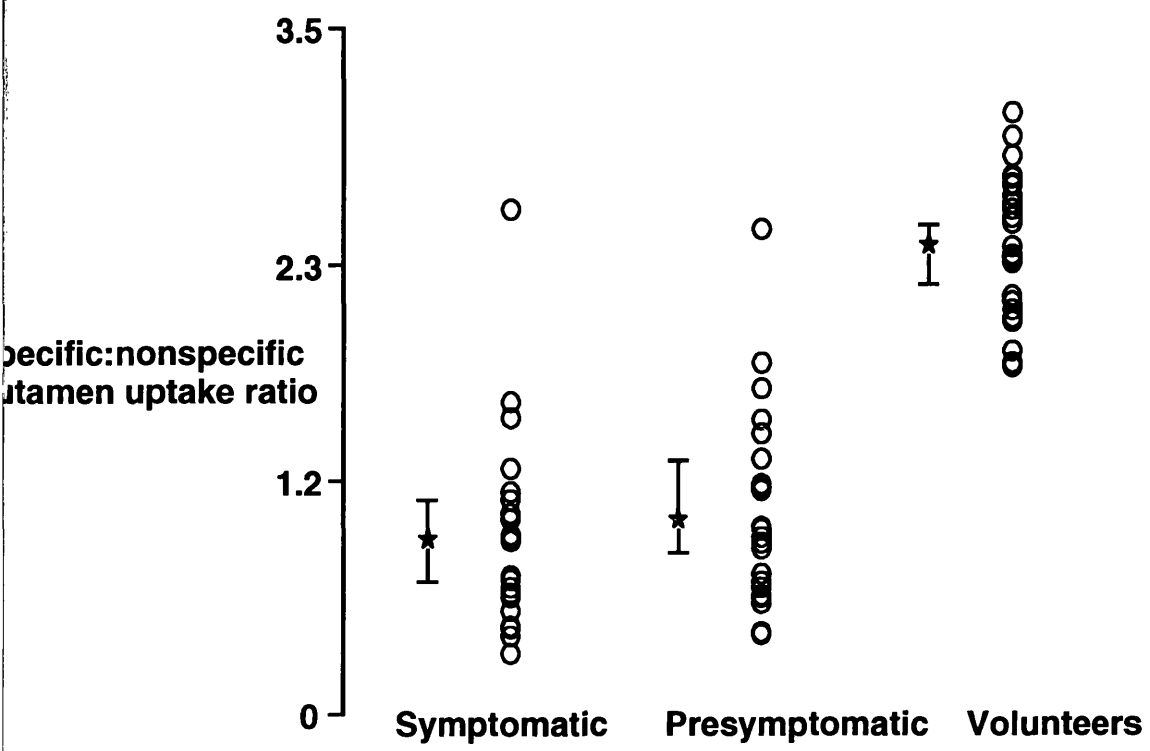


Figure 4.4 Mean specific:nonspecific uptake ratio in per-protocol patients with idiopathic Parkinson's disease (n=93), multiple system atrophy (n=14), and progressive supranuclear palsy (n=8).

No significant difference in the specific:nonspecific ratio was shown between idiopathic Parkinson's disease, multiple system atrophy and progressive supranuclear palsy.

Data are mean and 95% confidence interval.

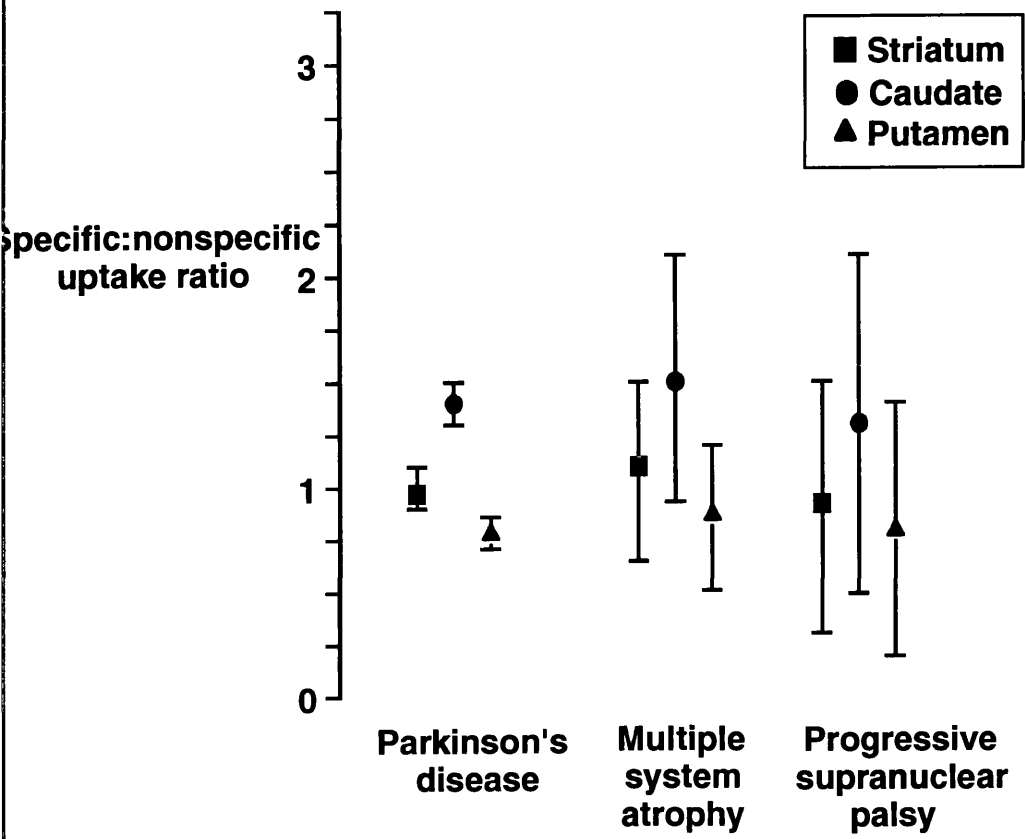


Figure 4.5 Asymmetry index in per-protocol patients with parkinsonism (n=115), essential tremor (n=16) and healthy volunteers (n=27).

Asymmetry index was significantly high in parkinsonism compared to essential tremor and healthy volunteers ($p < 0.001$).

Data are mean and 95% confidence interval.

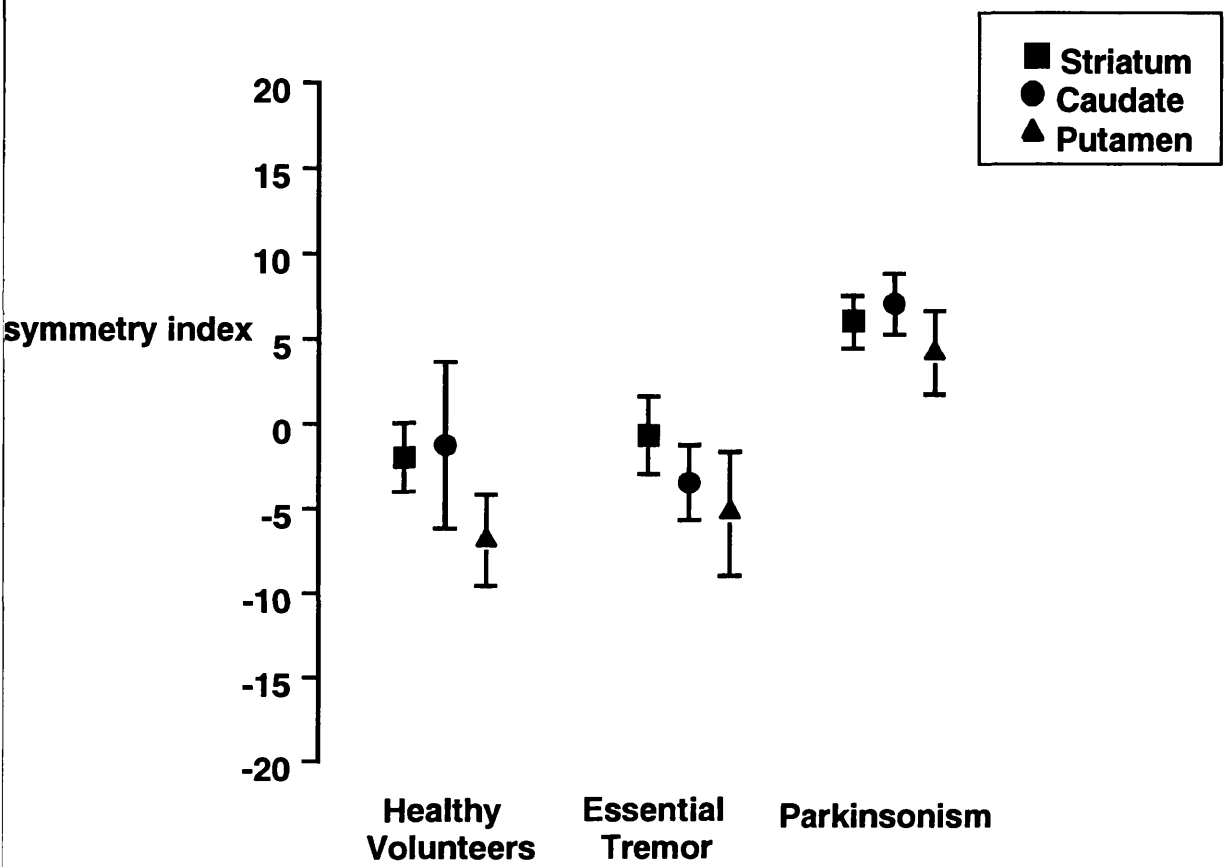


Figure 4.6 Putamen asymmetry index in per-protocol patients with idiopathic Parkinson's disease (n=93), multiple system atrophy (n=14), and progressive supranuclear palsy (n=8).

Putamen asymmetry index was significantly lower in multiple system atrophy ($p < 0.01$) and progressive supranuclear palsy ($p < 0.001$) compared to idiopathic Parkinson's disease. No significant difference was found in striatum or caudate asymmetry index.

Data are mean and 95% confidence interval.

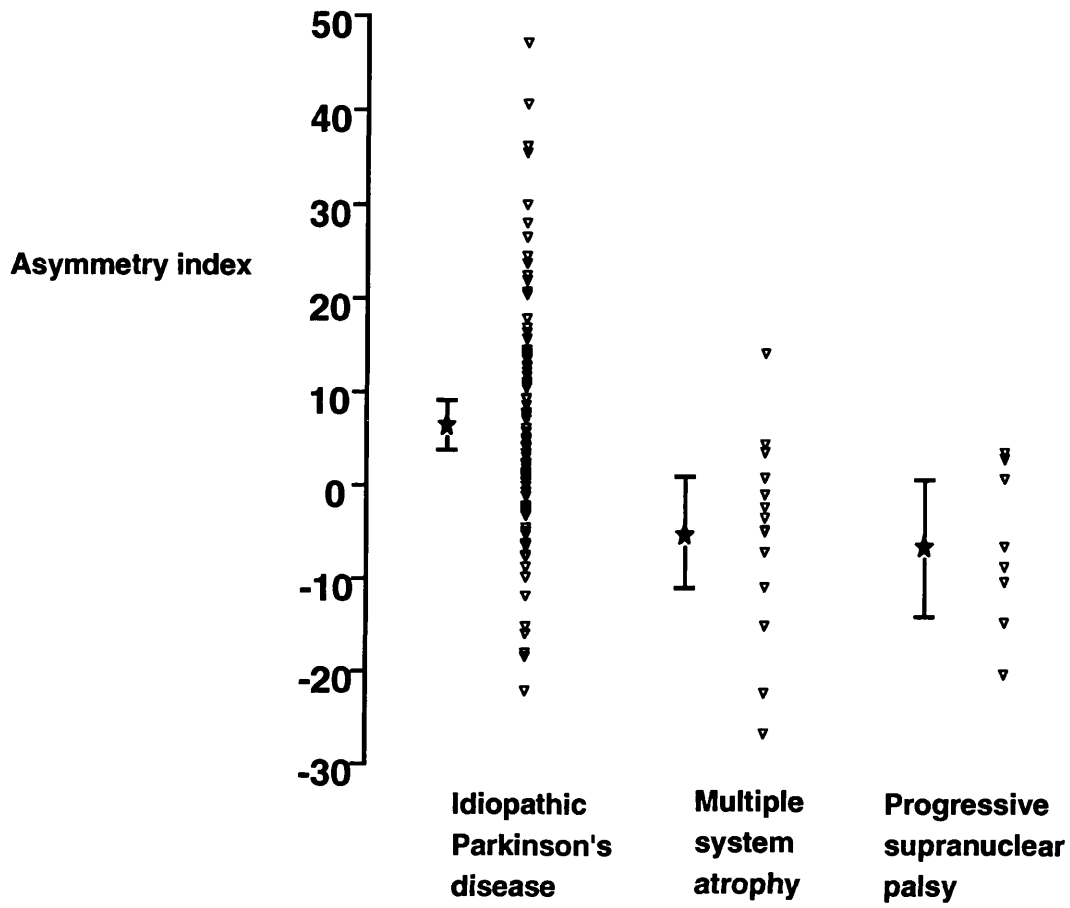


Figure 4.7 Putamen:caudate ratio in per-protocol patients with parkinsonism (n=115), essential tremor (n=16) and healthy volunteers (n=27).

Putamen:caudate ratio was significantly reduced in parkinsonism compared to essential tremor and healthy volunteers ($p < 0.001$).

Data are mean and 95% confidence interval.

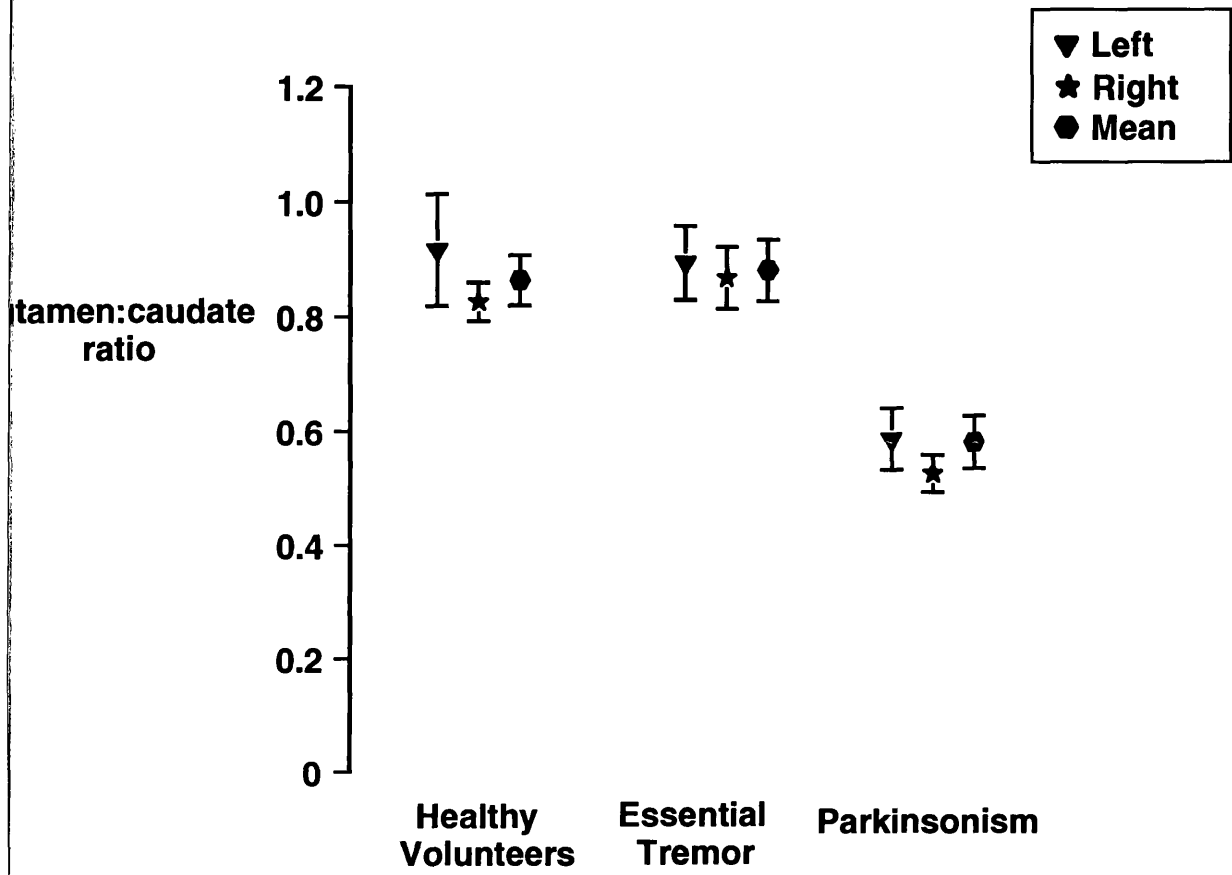
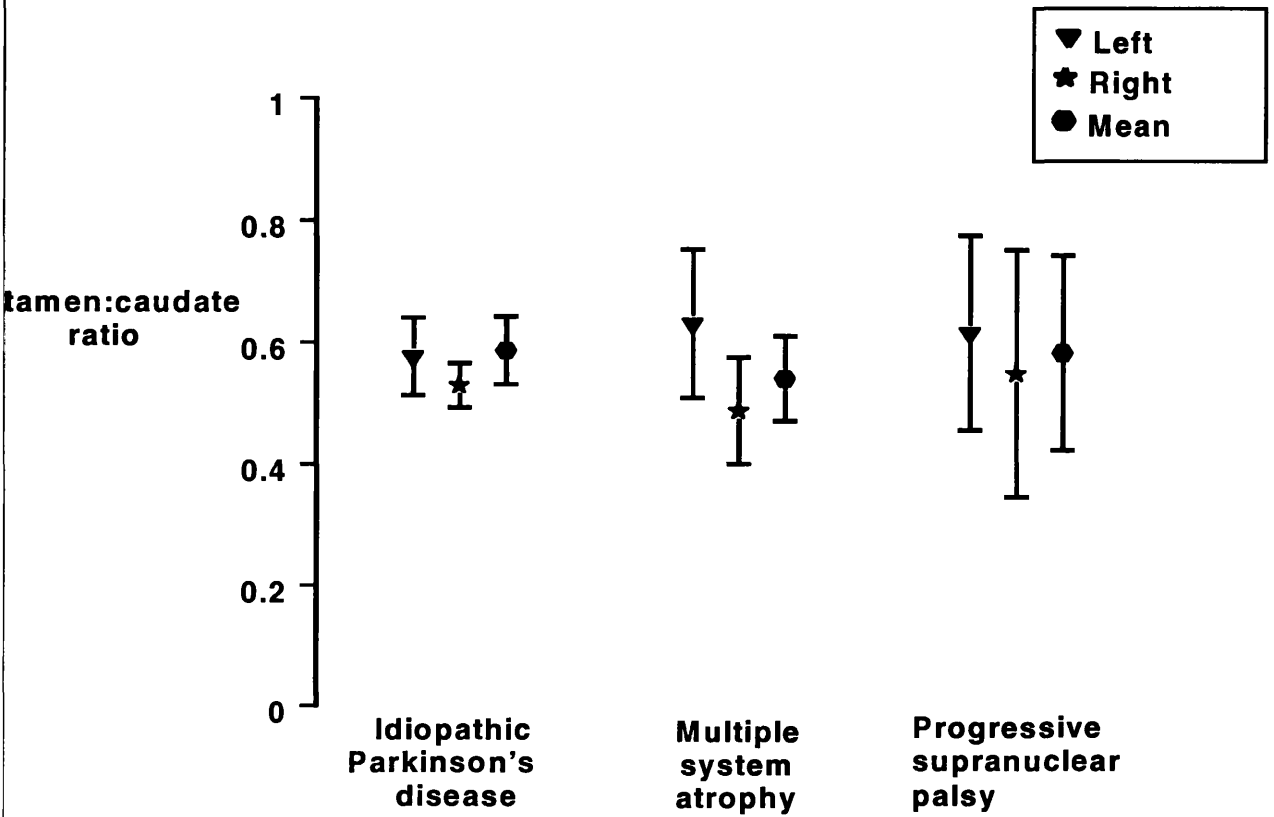


Figure 4.8 Putamen:caudate ratio in per-protocol patients with idiopathic Parkinson's disease (n=93), multiple system atrophy (n=14), and progressive supranuclear palsy (n=8).

No significant difference was found in putamen:caudate ratio in parkinsonism compared to multiple system atrophy and progressive supranuclear palsy.

Data are mean and 95% confidence interval.



4.4 DISCUSSION

A principle aim of the present study was to examine the accuracy of using a simple visual assessment of striatal uptake rather than ratio calculations to differentiate between parkinsonism and ET. This is important because visual assessment is clearly applicable in a clinical diagnostic setting.

Previous functional imaging studies have used only quantitative and semi-quantitative analysis in assessing striatal uptake. For example, Asenbaum et al (1998) reported a low specific:nonspecific uptake ratio of ^{123}I - β -CIT in 29 patients with iPD (H&Y I) compared to 32 patients with ET and 30 healthy volunteers. In the present study, there was an overall sensitivity and specificity of 96% in the two populations studied (per-protocol and intention-to-treat), so that striatal visual assessment represents a significant advance in the application of functional imaging in the diagnosis of parkinsonism and tremor disorders. Moreover, with no overall effect of age, disease severity or imaging equipment, these results should be applicable in patients at differing clinical stages and in different imaging centres.

Of the 35 iPD with mild unilateral disease (H&Y stage I) only one patient scored normal. Thus visual assessment can identify abnormalities in imaging patients in the early stages of their illness. The grading of the abnormal scans showed correlation with the H&Y staging, UPDRS and disease duration indicating that visual assessment may help in assessing disease onset and severity.

The cases where ^{123}I -FP-CIT results were discordant with the clinical diagnosis are to be expected considering that the known error rate in clinical diagnosis is 18%-24%

for iPD (Hughes et al 1992) and 10-25% for ET (Marshall et al 1962, Critchley 1972, Larsen et al 1983, Brooks et al 1992b). Given the primary assumption of the study that parkinsonism cases should have abnormal ^{123}I -FP-CIT uptake while ET should have normal uptake, these cases are of major interest. However, it is not possible within the constraints of this study to resolve these mismatches since no diagnostic gold standard, i.e. postmortem, is available. Nevertheless potential causes for the mismatch have been sought. One patient with normal ^{123}I -FP-CIT uptake had a 5 year history of tremor-predominant asymmetrical parkinsonism apparently responsive to levodopa. However, further clinical review suggested that ET was a plausible alternative clinical diagnosis. Another patient was found to have been on undeclared treatment with a neuroleptic drug, which may explain the clinical features in the presence of a normal ^{123}I -FP-CIT uptake. However Schwarz et al (1998b) have described recently two patients under neuroleptic treatment in whom IPT SPECT showed evidence of reduced dopamine transporters. One patient had left sided parkinsonism for 3 years before she was diagnosed as schizophrenic and treated with neuroleptic drugs. The second patient suffered from paranoid psychosis for 30 years before he developed parkinsonism and was treated with atypical neuroleptic drug clozapine which is less likely to cause parkinsonian symptoms. The authors concluded that these two patients have a nigrostriatal defect, which could be due to iPD rather than drug-induced parkinsonism. Further functional neuroimaging studies are needed to clarify the nature of neuroleptic induced parkinsonism.

On subsequent review of two further patients with iPD and normal SPECT scans, one had no definite diagnosis but the possibility of cerebrovascular disease was raised and

one was considered to have ET. There were no available follow-up data in the remaining patients.

Of 2 ET patients considered to have an abnormal ^{123}I -FP-CIT uptake by visual assessment, one of them was on amitriptyline (a prohibited medication as it may interfere with ^{123}I -FP-CIT uptake), and no follow-up data was available on the other.

The possibility of using ^{123}I -FP-CIT as a diagnostic tool for atypical tremor cases is raised by prior PET studies. Brooks et al (1992b) found that some patients with rest tremor without bradykinesia, therefore not fulfilling UK brain bank criteria for iPD have disruption of the nigrostriatal dopaminergic system while other patients with predominant postural tremor, who fail Findley and Koller criteria for definite ET have a normal nigrostriatal system. Thus functional imaging capable of visualising the dopaminergic system may help in diagnosing patients presenting with tremor but not fulfilling established clinical criteria. In the present study all patients fulfilled standard clinical criteria and atypical cases which are clinically more challenging were not included. Even within the present study, however, there are examples of cases fulfilling criteria but showing discordant imaging results, which is consistent with an established false positive rate of diagnosis according to clinical criteria in both parkinsonism and ET (Brooks et al 1992b, Hughes et al 1992, Ward et al 1990). (See study 3, chapter 6, for patients with tremor not fulfilling diagnostic criteria).

There is conflicting evidence from the literature about the relationship between ET and iPD, which adds to diagnostic difficulty in atypical clinical cases, especially in the presence of a family history of tremor disorder. James Parkinson (1817) attempted

to distinguish the two disorders, however Gowers drew attention to the possibility of an association between the two disorders as follows: “it is doubtful whether this senile tremor is far removed from paralysis agitans, although, as a rule, the other symptoms of shaking palsy remain absent. Some cases are met with a character intermediate between the two affections, and both may occur in different members of the same family”. Critchley (1949) however considered the association of these two disorders a chance occurrence of two relatively common disorders.

The association between ET and iPD varies amongst studies. Marttila et al (1984) studied ET in a Finnish population aged over 40 and concluded that iPD and ET are genetically independent. This was supported by Cleaves et al (1988) in a study of 137 ET patients, 100 iPD, and 100 controls, in which a higher family history of ET in iPD patients than in control subjects was not statistically significant. None of the 169 patients with typical ET reported by Martinelli et al (1987) developed iPD after a follow up period of between 2 and 5 years. A retrospective study of 266 patients with ET showed only 2% had an additional diagnosis of iPD (Rajput et al 1984b) and 6% in a study of 678 ET patients (Koller et al 1994). No case of iPD was found amongst 20 ET kindreds (Bain et al 1994). On the other hand, Geraghty et al (1985) found that iPD occurred 24 times more often than expected in patients with ET older than age 60, 19 times if all ages were included and 18 times if only patients with a duration of ET for five years or more before the onset of iPD were included. About 20% of ET patients had parkinsonian features according to Lou and Jankovic (1991) but Lang et al (1992) criticised this study as not representing the typical clinical correlates with ET. Jankovic et al (1995) found a high frequency of familial tremor among relatives of iPD patient compared with relatives of PSP patients and normal controls. In our

study all ET patients scored normal in the institutional read and only two scored abnormal in the consensus read. These results are in agreement with published postmortem (Rajput et al 1991a), ^{18}F -dopa PET (Brooks et al 1992b) and ^{123}I - β -CIT SPECT (Asenbaum et al 1998) studies indicates a normal nigrostriatal pathway in ET, therefore supporting the evidence that ET and iPD are not associated.

Semi-quantitative analysis confirmed clearly the results from visual assessment; that ^{123}I -FP-CIT can differentiate between parkinsonism and ET and healthy volunteers.

Also, semi-quantitative analysis using this ligand has the ability to recognise early loss of dopamine transporters where the symptoms are unilateral, which is in agreement with previous ^{18}F -dopa PET studies (Garnett et al 1984, Morrish et al 1995) and previous SPECT studies of dopamine transporters using ^{123}I - β -CIT and ^{123}I -FP-CIT (Marek et al 1996, Booij et al 1997c, Tissingh et al 1998, Asenbaum et al 1998). The finding of consistently reduced uptake in the ipsilateral putamen of patients with unilateral disease (H&Y I) therefore reinforces the idea of a presymptomatic phase of iPD.

The ratio of uptake between putamen and caudate has been the subject of previous studies, based on the observation of earlier impaired uptake in putamen compared to caudate in iPD and the possibility of a different pattern of loss for other parkinsonian conditions such as PSP and MSA (Brooks et al 1990). Although postmortem investigations show that there are regional differences in the degree of nigral cell loss in iPD, MSA, and PSP (Kish et al 1985, Bernheimer et al 1973), visual assessment of ^{123}I -FP-CIT SPECT imaging in this study could not visualize these differences at the

level of their striatal neuronal terminals, therefore it was not possible to differentiate between iPD, MSA, and PSP. There are several possible explanations for this. Postmortem studies tend to include patients with very advanced disease leading to biased results. The imaging of the dopamine transporter may be not sensitive enough to match the postmortem findings. However postmortem data is clearly not as a useful clinical discriminator, although it helps in understanding the pathological nature of different parkinsonian syndromes.

The asymmetry index, on the other hand, offers potential for differential diagnosis of parkinsonism on the basis of greater clinical asymmetry for iPD than other conditions (Marek et al 1996). Therefore, the asymmetry index was examined in this study as a potential measure to differentiate iPD from MSA, and PSP. Previous studies have shown a mixture of results for functional imaging as a technique to differentiate between iPD and atypical parkinsonism. ^{123}I - β -CIT SPECT did not distinguish types of parkinsonism in a study of 113 iPD, 9 MSA, and 4 PSP patients (Brucke et al 1997). In another ^{123}I - β -CIT study, head of caudate uptake showed a greater reduction in 5 PSP cases compared to 13 iPD cases, but with significant overlap (Messa et al 1998). Regional striatal ^{18}F -dopa uptake was depressed in a PET study of 16 iPD patients, with the most severe involvement in the posterior putamen, compared to a uniform severe depression of striatal uptake in 10 PSP patients, and a mixed pattern of reduced uptake within the basal ganglia in 18 MSA patients (Brooks et al 1990). Subsequent discriminant function analysis refined diagnostic groupings, in particular for PSP, but not MSA (Burn et al 1994), and this MSA result was later confirmed in another study (Antonini et al 1997). It was found in this study that only putamen asymmetry index was significantly lower in parkinsonian syndromes (MSA and PSP)

compared to iPD. No difference was found between MSA and PSP. The main drawback was the overlap between these groups for an asymmetry index value below five. However, only one patient with MSA had a value above five, so that only iPD cases had a high asymmetry index. Other ratios such as the SP:NS and P:C ratios were not able to differentiate between iPD and MSA or PSP. Obviously there are limitations in using this technique to differentiate iPD from other parkinsonian syndromes but in selected cases it may provide support to clinical clues suggesting that a patient might not have iPD.

One of the disadvantages in using ^{18}F -dopa PET is the necessity to withdraw levodopa for a least for 12 hours before scanning. This is usually associated with worsening of patients symptoms and causes some difficulties. Imaging dopamine transporters on the other hand offer an alternative where patients may not need to stop their main dopaminergic medication. Animal studies showed that acute administration of levodopa did not interfere with dopamine transporter imaging (Laruelle et al 1993). Recently Innis et al (1999) reported no significant effect of levodopa or selegiline on striatal dopamine transporters using ^{123}I - β -CIT SPECT. Although there are some limitations to their study (patients received therapy for only 6 weeks; small sample size was which may result in false negative results) their results add evidence to the lack of any significant effect of parkinson's drug on dopamine transporters. During our study patients were maintained on levodopa and/or dopamine agonist medication, so this does not have to be withdrawn prior to completion of ^{123}I -FP-CIT SPECT. Although selegiline was withdrawn, this may not prove necessary in clinical practice in view of the ^{123}I - β -CIT study (Innis et al 1999).

This study confirms the results of previous pre-clinical and clinical studies indicating that ^{123}I -FP-CIT appears safe and does not cause significant aberration in laboratory values. Adverse events were mostly transient with headache and flu-like symptoms the most frequent (Booij et al 1997 b, c 1998 a, 1999, Tissingh et al 1998).

4.5 CONCLUSIONS

- 1- ^{123}I -FP-CIT SPECT imaging identifies dysfunction of the nigrostriatal dopaminergic system even in patients with unilateral iPD.
- 2- A simple visual assessment of SPECT has a high sensitivity and specificity, thus this easily applied diagnostic test has potential utility in confirming the diagnosis in patients with parkinsonism and differentiating them from ET and healthy individuals.
- 3- Although there are limitations of using ^{123}I -FP-CIT SPECT in differentiating iPD from atypical parkinsonism (MSA, and PSP), the asymmetry index may be of use in certain patients.
- 4- This study adds evidence to the lack of any true association between iPD and ET.

CHAPTER 5

STUDY 2

***CORRELATION OF PARKINSON'S DISEASE
SEVERITY AND DURATION WITH ¹²³I-FP-CIT
SPECT STRIATAL UPTAKE.***

***PATTERNS OF DOPAMINE TRANSPORTER
LOSS IN PARKINSON'S DISEASE, MULTIPLE
SYSTEM ATROPHY AND PROGRESSIVE
SUPRANUCLEAR PALSY***

5.1 INTRODUCTION

The classical motor features of iPD (bradykinesia, rigidity, and tremor) usually present insidiously and unilaterally then gradually spread contralaterally with a slowly deteriorating course (Hoehn and Yahr 1967). These manifestations are attributed mostly to dopamine deficit secondary to progressive dopaminergic neuronal degeneration in the substantia nigra. Clinical examinations and standard rating scales give some indication of the severity of iPD but this is complicated by variability in symptoms and signs, rater reliability, and masking effects of drug therapy which are only partly overcome by assessing the patient in an “off” state. Therefore, development of an objective marker of disease severity is important and could help to understand and monitor disease onset, severity and progression.

Although iPD, MSA, and PSP are pathologically different, postmortem studies have shown the difficulty in differentiating clinically between these disorders. Of the 100 cases diagnosed as iPD only 76 was found to fulfil the pathological criteria, while the remaining patients were clinically misdiagnosed with PSP and MSA as the diagnosis in 11 of the 24 cases without Lewy bodies (Hughes et al 1992).

The aim of this study was to evaluate ^{123}I -FP-CIT as an objective marker of iPD severity, which could help to understand and monitor disease onset, severity and progression and to assess the relationship between the laterality of parkinsonism features and ^{123}I -FP-CIT uptake. Also, to evaluate the pattern of loss of dopamine transporters in patients with iPD, MSA, and PSP.

5.2 METHODS

5.2.1 Study Subjects

A subset of patients from Glasgow: Forty one patients with iPD, (33 male, 80%), mean age 64 years (SD 9.5), 6 patients with MSA, (4 male, 67%), mean age 63 years (SD 6.4), 3 PSP (3 females), mean age 67 (SD 4), and 6 age matched healthy volunteers, (3 male, 50%) mean age 63 years (SD 6.1) were included in this study.

A subgroup of 9 iPD cases, with a H&Y score of I were compared with 32 iPD patients with H&Y score of II-IV and healthy volunteers specifically to assess ^{123}I -FP-CIT uptake in relation to laterality of clinical features.

5.2.2 Study Assessments

Patients were assessed using the UPDRS motor section and H&Y rating scales in an “off” phase (Hoehn and Yahr 1967, Fahn et al 1987) by one observer. Standard clinical diagnostic criteria were applied for iPD and PS (MSA and PSP) patients as described in the study 1 (Chapter 4). Drugs with a potential to interact with striatal uptake of ^{123}I -FP-CIT were excluded, as discussed previously.

Components of UPDRS motor score representing lateralised signs for iPD patients were scored for right and left limbs, these being items for arm and leg resting and action tremor, rigidity, finger taps, hand movements, alternating movements, and leg agility. This was designated the unilateral UPDRS, which has a maximum score of 36 for each side.

In iPD patients the contralateral striatum was defined as the side opposite to that of symptom onset, and for healthy volunteers the contralateral side was arbitrarily assigned to the left striatum.

5.2.3 Imaging

In order to minimise the radiation dose, between 1 and 4 hours prior to the administration of the ^{123}I -FP-CIT 120mg of potassium iodide was administered orally to each subject to block the uptake within the thyroid of any free iodine in the original preparation, or iodine released during the metabolism of the product. Following ^{123}I -FP-CIT injection, and where it was considered appropriate, the patient was given two further tablets to take between 12 and 24 hours later.

^{123}I -FP-CIT was administered intravenously over a period of approximately 15 seconds and was followed by a saline flush. The administered activity was in the range 111 - 185 MBq in 2.5ml water.

SPECT imaging was performed (i.e. the scan both started and finished) between 3 and 6 hours after the ^{123}I -FPCIT injection. Ten axial sections, 5mm apart, were considered sufficient to cover the striatum, specifically the head of the caudate nucleus and the putamen. Each section was acquired in 4 minutes, giving a total scan time of just over 40 minutes. Total counts acquired were recorded with all per-protocol sections having a value greater than 150,000.

SPECT images were acquired using a dedicated multi-detector system (Strichman Medical Equipment SME810, Novo Systems, Denmark) linked to an Apple

Macintosh computer. This sectional scanner acquires sequential single transaxial brain sections. The whole brain is imaged using movements of the patient couch. The 12 individual point-focused radiation detectors move both tangentially and radially such that the focal point scans the brain in a "raster" pattern. This unique geometry simplifies image reconstruction which is performed by a deconvolution process, and results in a uniform resolution of approximately 8mm throughout each axial section with a slice thickness of 12 mm. Resolution in the longitudinal direction is similar to the axial value when a slice spacing of 6mm is used (*Figure 5.1*).

To account for the absorption of some photons within the brain a linear attenuation correction of 85mm (equivalent to an effective attenuation coefficient of 0.117cm^{-1}) was applied based on an automatically detected ellipse matching the outer surface of the head. A count dependent filter designed to optimise image resolution and noise was used and set at the "highest" setting provided by the manufacturer. The energy window (140-180 keV) was placed symmetrically around the iodine-123 gamma energy of 159keV.

5.24 Data Analysis

The images were stored on an Apple Macintosh computer system and data analysis was performed using pre-determined ROI templates. These templates were derived from data on human brain structure available on the "Talairach Daemon" Internet web-site (<http://ric.uthscsa.edu/projects/talairachdaemon.html>). This site allows interactive query and retrieval of a 3-dimensional database of brain structure which has as its basis the Co-planar Stereotaxic Atlas of the Human Brain described by Talairach and Tournoux in 1988. In parallel with this is a series of overlays (structure

probability maps) for a number of brain regions including the caudate and putamen. These structure probability maps were derived from a large number of Magnetic Resonance Imaging (MRI) scans (Collins et al 1995b, Mazziotta et al 1995) and delineate the areas within the Atlas window with a fifty-percent probability of being associated with each structure or region (*Figure 5.2*).

Image manipulation software (NIH Image, available from the National Institutes of Health at <ftp://zipppy.nimh.nih.gov/pub/nih-image/>) was then used to outline the brain, striatal structures and the occipital region (*Figure 5.3*) for the ROI templates. The regions of interest for the left and right putamen were divided into anterior and posterior sections at exactly half the anterior-posterior distance. The occipital regions were reduced in size to minimise the effects of slice tilt, i.e. if the patient is scanned with head tilted backwards the majority of the occipital lobe will appear in the higher axial sections and vice versa. Although most of the tilt can be corrected by SPECT software, reducing the size of the regions ensured that some occipital lobe was present even if some tilt remained.

An ROI for the outside surface of the head was also determined again using the MRI data from the International Consortium for Brain Mapping described in the Talairach web-site. In this case the ICBM305 data set an average of 305 normal MRI scans were downloaded from the web-site of the Wellcome Department of Cognitive Neurology in London (<http://www.fil.ion.ucl.ac.uk/spm/>) where it is incorporated into a software package for statistical analysis of neuroimaging data (Statistical Parametric Mapping).

The standard ROI Templates (right and left caudate, putamen, and occipital) were used on the three adjacent sections through the striatum, showing high uptake of ^{123}I -FP-CIT. It should be noted that the slice separation of the SPECT data was 5 mm compared to 4 mm for the Talairach sections. This difference is not thought to be significant.

In using the high resolution MRI data in the derivation of ROIs no assumptions are made about the ability of SPECT to delineate the same brain structures. On the contrary, it is recognised that the poorer resolution of SPECT produces "partial volume effects" which means that a proportion of the activity detected within, for example, a caudate ROI will originate from outside that region and especially from the adjacent anterior putamen. The more correct terms, caudate weighted ROI, putamen weighted ROI etc are implied in the names of the ROIs.

The image analysis software supplied with the SPECT scanner was utilised in the application of the ROIs to the images. The first part of this process involved the identification of the three slices through the striatum. While this is a fairly simple procedure when there is normal uptake it is more difficult when the uptake is low, as in more advanced iPD, and the ability of the software to re-orientate the images in all three orthogonal planes was important. Reference was made to the normal anatomical pattern of the striatum (*Figure 5.4*) where, in the sagittal plane, the caudate curves posteriorly and superiorly while the putamen, which lies lateral to the caudate, has very little superior projection. Therefore, the first axial section was defined as being the most inferior section to show caudate activity thereby ensuring that the body of

the caudate is not included in the other two sections which might mimic putamen uptake.

For each selected SPECT image the ROI template was opened and overlaid on the image. The whole template was then scaled to fit the subject's head size to allow for inter-individual differences. Individual ROIs were then moved into position with no further scaling or rotation allowed. Firstly, the caudate regions were placed such that the anterior edge of the ROI corresponded to the anterior edge of the caudate as determined visually by the area of highest anterior uptake. The putamen ROIs were then positioned immediately posterior to the caudate ROIs as in the original template while the separate anterior and posterior putamen regions were moved to the appropriate position overlying the whole putamen regions. The occipital ROIs (left and right) were allowed minimal movement to avoid areas with low activity, presumably due to atrophy in older subjects (*Figure 5.5*).

All ROI measurements were expressed as mean activity within the region i.e. reconstructed counts divided by the area of the region.

Measurements of striatal and occipital uptake of ^{123}I -FP-CIT were then used to derive a number of indices of dopamine transporter availability as follows:

Firstly, it was assumed that the detected activity within the striatum consists of ligand specifically bound to the transporter site as well as non-specifically bound ligand and free ligand. It is also assumed that the non-specific and free components are the same in all regions of the brain in which delivery of ligand is similar. Therefore a

measurement of uptake in a reference region devoid of specific transporter sites allows a correction to be made for the non-specific and free components. The occipital cortex was selected as such a region since the density of dopamine transporters is known to be negligible there (De Keyser 1989). Specific uptake in striatal regions was calculated as: Specific uptake = striatal uptake - occipital uptake.

The ratio of specific:nonspecific uptake, sometimes referred to as the equilibrium volume of distribution of the receptor compartment or the binding potential, is linearly related to the density of transporters within the region provided equilibrium has been achieved at the time of imaging (Laruelle et al 1994). This assumption is supported by other studies (Abi-Darghan et al 1996, Booij et al 1999) who showed that striatal specific uptake approached a fairly constant level after 3 hours and that between 3 and 6 hours the specific: nonspecific ratio was essentially stable. Seibyl et al (1998) found a similar plateau but also demonstrated a small decrease in the ratio of striatal uptake in iPD patients to healthy volunteers during this time window and cautioned that this may be due to an overestimation by ^{123}I -FP-CIT of receptor density in healthy subjects. Nevertheless, a direct comparison of ^{123}I -FP-CIT SPECT with ^{18}F -Dopa PET imaging (Ishikawa et al 1996) supported the use of ^{123}I -FP-CIT in the quantitative assessment of dopaminergic function.

The ratio of the specific uptake in putamen relative to caudate and an asymmetry index between hemispheres was therefore calculated.

A summary of calculated data is as follows:

Parameter	Calculation
Mean uptake	$\frac{\text{ROI uptake}}{\text{ROI area}}$
Specific uptake in striatum	Mean striatal ROI uptake - Mean occipital uptake
Specific:nonspecific ratio (SP:NS)	$\frac{\text{Specific uptake in striatal ROI}}{\text{Mean occipital ROI uptake}}$
Putamen:caudate ratio (P:C)	$\frac{\text{Specific uptake in putamen ROI}}{\text{Specific uptake in caudate ROI}}$
Asymmetry Index (AI)	$\frac{100 \times (\text{Specific uptake ipsilateral} - \text{contralateral})}{0.5 \times (\text{Specific uptake ipsilateral} + \text{contralateral})}$

Each assessment was carried out for both left and right sides of the brain and the analysis compared the data produced for each patient with the stage, severity, and duration of disease.

The patterns of striatal uptake was calculated as percentage to normal for the 41 iPD patients and compared to 6 MSA and 3 PSP cases.

5.2.5 *Statistical analysis*

Comparisons of striatal uptake in iPD patients and healthy volunteers were made by one-way analysis of variance with Bonferroni correction for multiple comparisons.

The Wilcoxon signed rank test was used to compare unilateral UPDRS for the onset side with that of the non-onset side as well as ipsilateral with contralateral caudate and putamen uptake. The relationship between ^{123}I -FP-CIT striatal uptake and staging, severity, and disease duration (which was of non-Gaussian distribution) was tested by Spearman rank correlation. All tests were two tailed with the accepted level of

significance $p < 0.05$. Comparisons of striatal uptake in iPD, MSA, PSP and healthy volunteers were made by one-way analysis of variance with Bonferroni correction for multiple comparisons.

Figure 5.1 The SPECT imaging: 12 individual point-focused radiation detectors move both tangentially and radially such that the focal point scans the brain in a "raster" pattern.

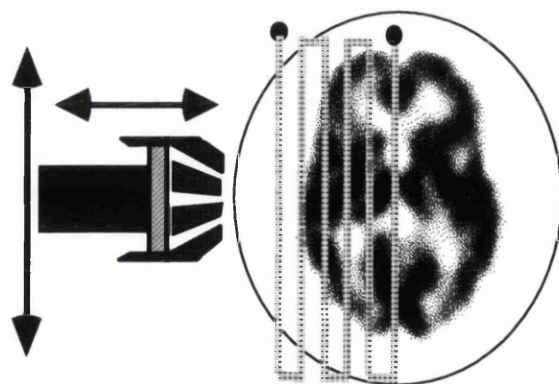



Figure 5.2 Three adjacent axial sections through the middle of the striatum.

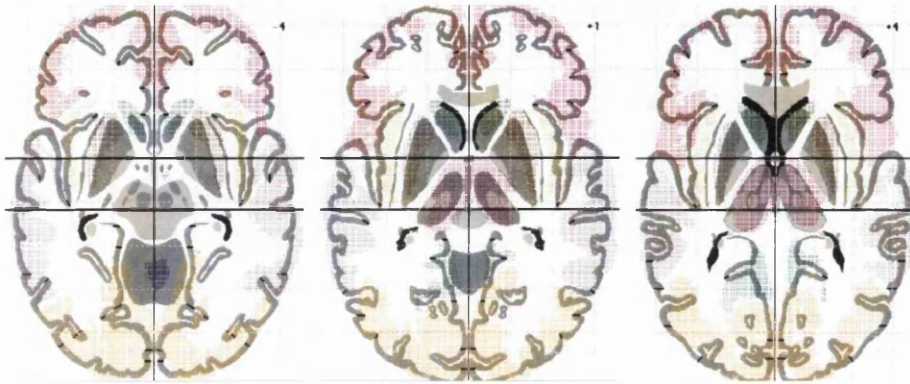


Figure 5.3 Outline of the brain, striatal structures and the occipital region of interest templates obtained using image manipulation software.




Figure 5.4 Normal anatomical pattern of the striatum where it can be seen that in the sagittal plane, the caudate curves posteriorly and superiorly while the putamen, which lies lateral to the caudate, has very little superior projection.

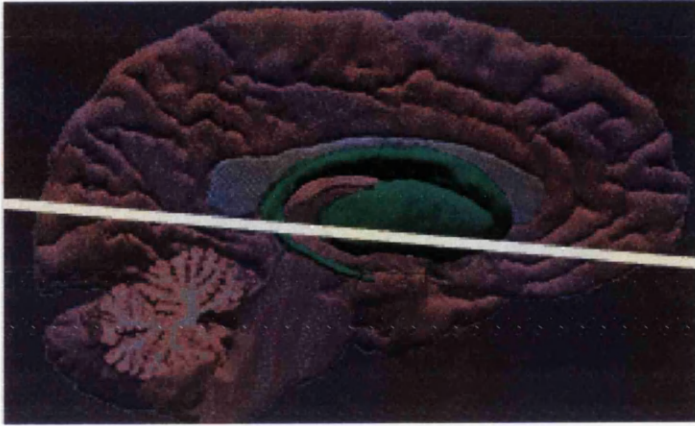
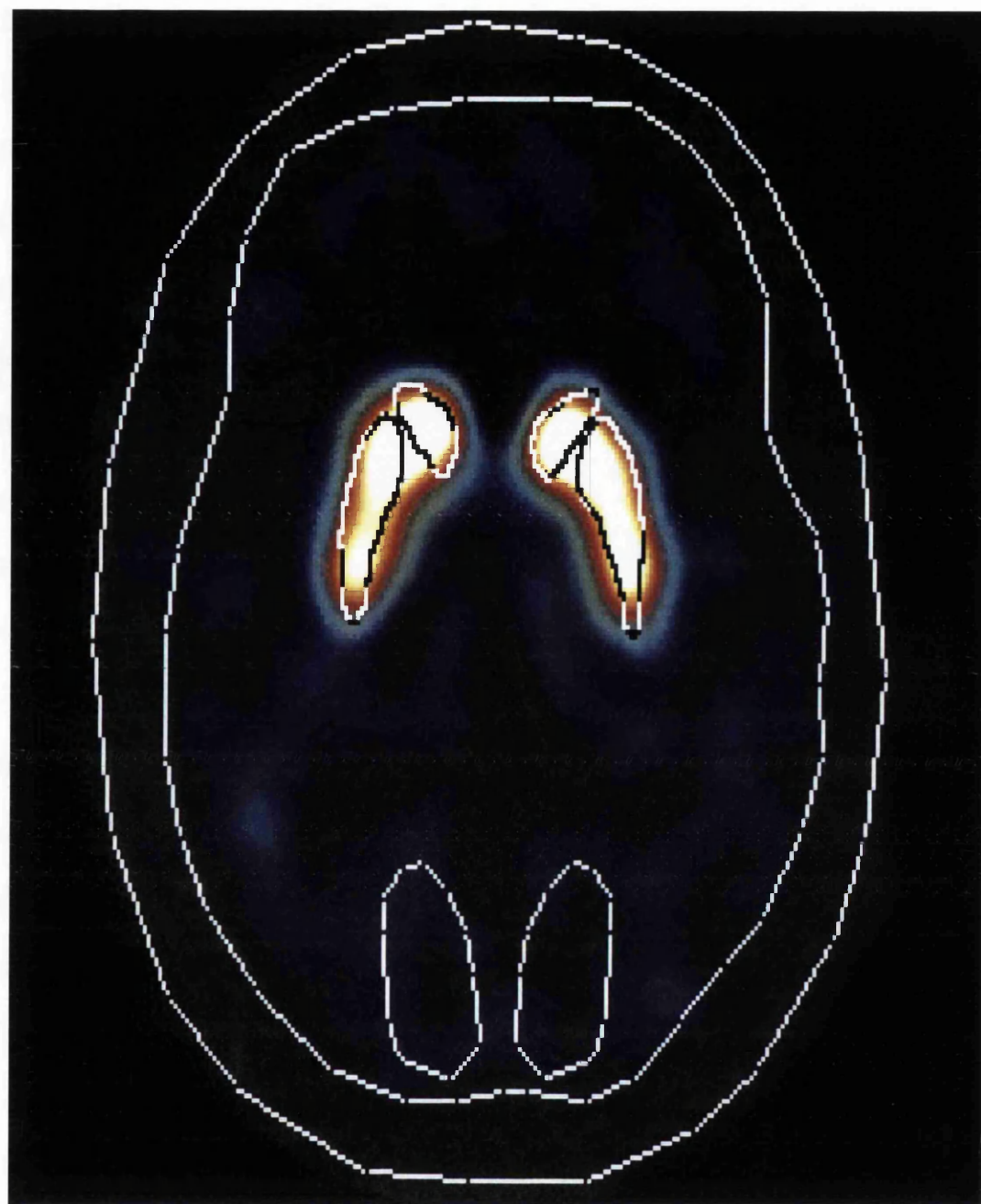

Figure 5.5 Applications of region of interest to SPECT imaging showing right and left caudate, putamen and occipital regions, as well as the whole head and the brain.



5.3 RESULTS

Twenty seven iPD patients had right sided onset and 14 had left sided onset. The H&Y score was I in 9 cases, II in 16 cases, III in 11 cases, IV in 5 cases. The mean duration of illness was 7.2 years (CI 5.1-9.3). The median UPDRS motor score for iPD was 23 (inter-quartile range 17-36) (mean 28, SD17). Median UPDRS for MSA was 60 (inter-quartile range 50-63) (mean 53, SD17), H&Y score was II in one case, III in one case, IV in one case and V in 3 cases, with mean duration of illness 5.8 years (SD 2.2). The three cases of PSP, mean was 37 (SD 18) (median and inter-quartile range not appropriate), H&Y score was III in two cases and IV in one case, with mean duration of illness of 3.3 years (SD 2.5).

Specific:nonspecific ratios in idiopathic Parkinson's disease and healthy volunteers and correlation with unilateral UPDRS

Ipsilateral and contralateral putamen SP:NS ratios were significantly reduced ($p<0.001$) for both H&Y I and H&Y II-V, compared to healthy volunteers (*Table 5.1, Figure 5.6*), as were the corresponding values for the caudate (*Table 5.1*).

Unilateral UPDRS showed a significantly higher score on the side of symptom onset compared to the non-onset side for both H&Y I, [onset side 7 (3.5-11.5); non-onset side 0.0 (0-0.5)] (*Figure 5.6 A*) and for H&Y II-V, [onset side 27.5 (21-45); non-onset side 7.5 (4.25-14)] (*Figure 5.6 B*).

Compared to this the difference between ipsilateral and contralateral caudate SP:NS ratio as well as the corresponding values for the putamen were statistically significant

for both groups of iPD patients, although there was overlap of the reading between groups (*Table 5.1, Figure 5.6*).

No significant difference was found between ipsilateral and contralateral SP:NS ratio in caudate or putamen for healthy volunteers (*Table 5.1, Figure 5.6*).

There was a correlation between ipsilateral and contralateral caudate and putamen SP:NS ratios and unilateral UPDRS (*Table 5.2*).

Correlation of motor scores and specific:nonspecific ratios

H&Y stage and UPDRS motor score were significantly correlated with mean striatum, caudate and putamen SP:NS ratios (*Table 5.3, Figure 5.7*). There was also a significant correlation between both H&Y stage and UPDRS motor score and ipsilateral as well as contralateral caudate and putamen uptake ratios (*Table 5.3*). A good correlation was also found between the bradykinesia component of UPDRS and striatum, caudate and putamen SP:NS but rigidity and tremor were poorly correlated with these values (*Table 5.3*).

Correlation of disease duration and specific:nonspecific ratios

The duration of iPD was significantly correlated with mean striatum, caudate and putamen SP:NS ratios, as well as ipsilateral and contralateral values (*Table 5.3, Figure 5.8*).

Putamen:caudate ratios

There were significant differences in P:C ratio between unilateral (H&Y I) and bilateral (H&Y II-IV) iPD patients compared to healthy volunteers ($p < 0.001$)

(Table 5.4). Correlation with disease stage, UPDRS components and duration was generally poorer than for SP:NS ratios, although the tendency was for the ratio to decrease as the disease progressed (Table 5.5).

Asymmetry indices

There were significant differences between putamen Asymmetry index in unilateral (H&Y I) iPD patients and healthy volunteers ($p < 0.001$) but no significant differences were found for caudate asymmetry index (Table 5.4). However, there were no significant differences in caudate or putamen asymmetry index between bilateral (H&Y II-IV) iPD patients compared to healthy volunteers ($p > 0.05$) (Table 5.4). Asymmetry index did not correlate with duration of the disease but the putamen asymmetry index did show some correlation with disease stage and severity (Table 5.6).

The pattern of the striatal uptake in Parkinson's disease, multiple system atrophy, progressive supranuclear palsy and healthy volunteers

The mean caudate and putamen SP:NS ratio was significantly lower in iPD, MSA, and PSP patients compared to healthy controls ($p < 0.001$) (Table 5.7).

The mean putamen SP:NS ratio was significantly reduced compared to caudate in iPD and the posterior putamen ratio also was significantly lower than anterior putamen ($p < 0.001$).

The posterior putamen SP:NS ratio in healthy volunteers was significantly lower than anterior putamen uptake ($p < 0.001$). Caudate and putamen ratios were not significantly different.

The mean caudate SP:NS ratios were depressed in a similar level for each subgroup of parkinsonian patients: iPD patients it was 50% of normal, for MSA it was 44% of normal and for PSP it was 50% of normal. Tracer uptake was severely depressed in the putamen, 29% of normal for iPD, 25% for MSA and 24% for PSP. Anterior putamen uptake was reduced by 31% in iPD, 28% in MSA, and by 28.5% in PSP. Posterior putamen uptake was reduced to 19% of normal for iPD, 18% for MSA, and 10% in PSP. No significant differences between caudate, anterior putamen and posterior putamen uptake were found between iPD, MSA, PSP.

Table 5.1 Difference between ipsilateral and contralateral uptake for both caudate and putamen in 9 unilateral, and 32 bilateral idiopathic Parkinson's disease patients, and 6 healthy volunteers.

	Caudate			Putamen		
	Ipsi	Contra	p value	Ipsi	Contra	p value
H&Y I	2.1 (1.6-2.6)	1.8 (1.4-2.2)	0.02	1.3 (1.0-1.7)	0.90 (0.73-1.1)	0.008
H&Y II-V	1.6 (1.3-1.9)	1.4 (1.1-1.9)	<0.0001	0.91 (0.70-1.1)	0.76 (0.55-0.97)	<0.0001
Healthy volunteers	3.5 (3.1-3.8)	3.5 (3.1-4.0)	0.62	3.1 (3.0-3.3)	3.1 (2.8-3.4)	0.43

Data are mean (95% confidence interval)

Ipsi = ipsilateral

Contra = contralateral

Table 5.2 Correlation coefficients (Spearman rank correlation) for ^{123}I -FP-CIT SPECT measures and unilateral UPDRS in idiopathic Parkinson's disease.

		Specific:nonspecific uptake ratio			
		Ipsi	Contra	Ipsi	Contra
		caudate	caudate	putamen	putamen
Unilateral UPDRS		-0.34	-0.36	-0.44	-0.39
(onset side)	p value	0.027	0.021	0.003	0.012
Unilateral UPDRS		-0.47	-0.47	-0.43	-0.56
(non-onset side)	p value	0.001	0.001	0.005	0.0001

UPDRS = Unified Parkinson's Disease Rating Scale

Ipsi = ipsilateral

Contra = contralateral

Table 5.3 Correlation coefficients (Spearman rank correlation) for ¹²³I-FP-CIT SPECT measures and UPDRS motor scoring and duration of illness in 41 idiopathic Parkinson's disease patients.

Specific:nonspecific uptake									
	Mean striatum	Ipsi striatum	Contra striatum	Mean caudate	Ipsi caudate	Contra caudate	Mean putamen	Ipsi putamen	Contra putamen
Disease stage	H&Y	-0.63	-0.60	-0.59	-0.58	-0.60	-0.65	-0.67	-0.59
	p value	<0.0001	<0.0001	<0.0001	<0.0001	<0.0001	<0.0001	<0.0001	<0.0001
Disease severity score	UPDRS	-0.54	-0.50	-0.50	-0.50	-0.51	-0.57	-0.62	-0.51
	p value	0.0003	0.0001	0.001	0.0008	0.0007	<0.0001	0.0001	0.007
	Bradykinesia	-0.50	-0.49	-0.43	-0.44	-0.46	-0.53	-0.56	-0.48
	p value	0.001	0.001	0.05	0.004	0.002	0.004	0.0002	0.002
	Rigidity	-0.27	-0.32	-0.27	-0.30	-0.27	-0.29	-0.34	-0.22
	p value	0.08	0.04	0.127	0.065	0.086	0.06	0.027	0.16
	Tremor	-0.30	-0.34	-0.26	-0.26	-0.27	-0.37	-0.38	-0.32
	p value	0.05	0.03	0.066	0.097	0.08	0.01	0.01	0.043
Duration		-0.67	-0.62	-0.63	-0.57	-0.66	-0.71	-0.67	-0.71
	p value	<0.0001	<0.0001	<0.0001	<0.0001	<0.0001	<0.0001	<0.0001	<0.0001

H&Y = Hoehn and Yahr

UPDRS = Unified Parkinson's Disease Rating Scale

Ipsi = ipsilateral

Contra = contralateral

Table 5.4 Asymmetry index and putamen:caudate ratio in 9 unilateral and 32 bilateral Parkinson's disease patients, and 6 healthy volunteers.

	Asymmetry index		Putamen:caudate ratio	
	Caudate	Putamen	Ipsilateral	Contralateral
H&Y I	16** (6.7,25)	37* (19,56)	0.63* (0.58,0.68)	0.51* (0.44,0.57)
H&Y II-V	14** (7,20)	16** (7.8,24)	0.56* (0.51,0.60)	0.52* (0.45,0.58)
Healthy volunteers	-1.3 (-7.3,4.6)	0.85 (-6.6,8.3)	0.90 (0.83,0.98)	0.88 (0.86,0.91)

* $p < 0.001$ compared to healthy volunteers

** $P > 0.05$ compared to healthy volunteers

Data are mean (95% confidence interval)

Table 5.5 Correlation coefficients (Spearman rank correlation) for putamen:caudate ratio of ^{123}I -FP-CIT striatal uptake and UPDRS motor scoring and duration of illness in 41 idiopathic Parkinson's disease patients.

		Putamen:caudate ratio		
		Ipsi	Contra	Mean
Disease stage	H&Y	-0.38	-0.17	-0.27
	p value	0.01	0.28	0.09
Disease severity score	UPDRS	-0.37	-0.14	0.29
	p value	0.01	0.37	0.07
	Bradykinesia	-0.34	-0.14	-0.29
	p value	0.03	0.37	0.07
	Rigidity	-0.15	-0.18	-0.07
	p value	0.33	0.26	0.65
	Tremor	-0.26	-0.03	-0.30
	p value	0.09	0.84	0.06
Duration		-0.42	-0.12	-0.34
	p value	0.007	0.46	0.01

H&Y = Hoehn and Yahr

UPDRS = Unified Parkinson's Disease Rating Scale

Ipsi = ipsilateral

Contra = contralateral

Table 5.6 Correlation coefficients (Spearman rank correlation) for Asymmetry index of ^{123}I -FP-CIT striatal uptake and UPDRS motor scoring and duration of illness in 41 idiopathic Parkinson's disease patients.

		Asymmetry index	
		Caudate	Putamen
Disease stage	H&Y	0.00	-0.43
	p value	0.97	0.005
Disease severity score	UPDRS	-0.03	-0.42
	p value	0.82	0.006
	Bradykinesia	0.00	-0.34
	p value	0.9	0.03
	Rigidity	-0.11	-0.35
	p value	0.49	0.02
	Tremor	-0.01	-0.2
	p value	0.94	0.19
Duration		-0.21	-0.09
	p value	0.19	0.56

H&Y = Hoehn and Yahr

UPDRS = Unified Parkinson's Disease Rating Scale

Table 5.7 The mean specific:nonspecific uptake in idiopathic Parkinson's disease

(41), multiple system atrophy (6), progressive supranuclear palsy (3), and controls (6).

	Caudate	Whole Putamen	Anterior putamen	Posterior putamen
Idiopathic Parkinson's disease	1.6 (1.4-1.8)	0.90 (0.73-1.1) ^a	1.1 (0.92-1.3)	0.48 (0.34-0.62) ^b
Multiple system atrophy	1.4 (0.73-2.1)	0.79 (0.37-1.2)	0.98 (0.48-1.5)	0.45 (0.14-0.77)
Progressive supranuclear palsy	1.6 (0.54-2.6)	0.76 (0.13-1.4)	1.0 (0.27-1.8)	0.27 (-0.05-0.59)
Healthy controls	3.5 (3.1-3.9)	3.1 (2.9-3.3) ^c	3.5 (3.1-3.9)	2.5 (2.3-2.7) ^d

^a $p < 0.001$ compared to caudate in Parkinson's disease

^b $p < 0.001$ compared to anterior putamen in Parkinson's disease

^c $p > 0.05$ compared to caudate of controls

^d $p < 0.001$ compared to anterior putamen of controls

Figure 5.6 Putamen specific:nonspecific ratio compared to unilateral UPDRS scores in 41 idiopathic Parkinson's disease patients and 6 healthy volunteers.

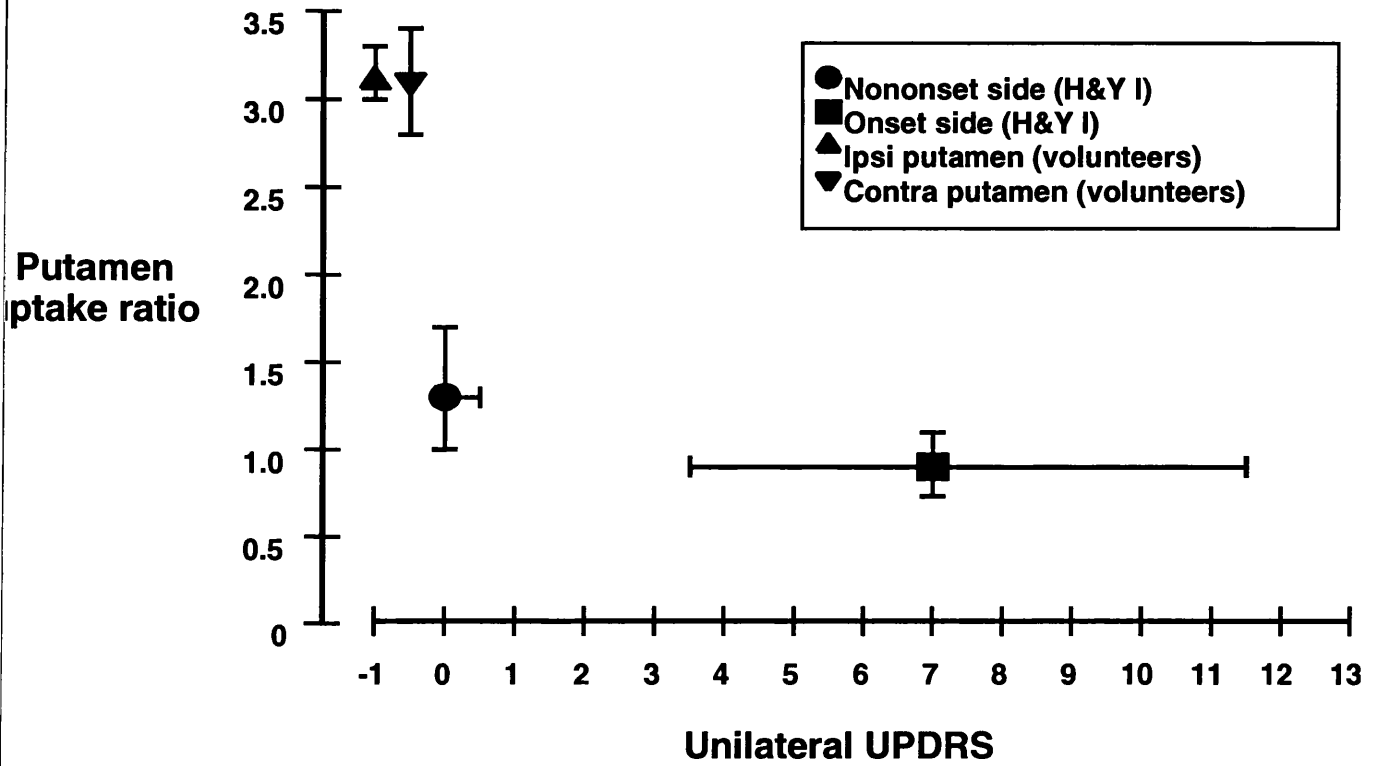
Putamen uptake was reduced in idiopathic Parkinson's disease patients to less than half the level in healthy volunteers, and there was an overlap between putamen uptake of onset and non-onset sides for H&Y I and H&Y II-V patients.

A) Results for H&Y grade I (n=9) patients. There was a significantly higher motor score in the onset side unilateral UPDRS compared to non-onset side ($p=0.004$).

B) Results for H&Y grade II-IV (n=32) patients. Unilateral UPDRS was higher in onset than non-onset side ($p<0.0001$).

Data are mean and 95% confidence interval for putamen uptake, and median and inter-quartile range for unilateral UPDRS.

A)



B)

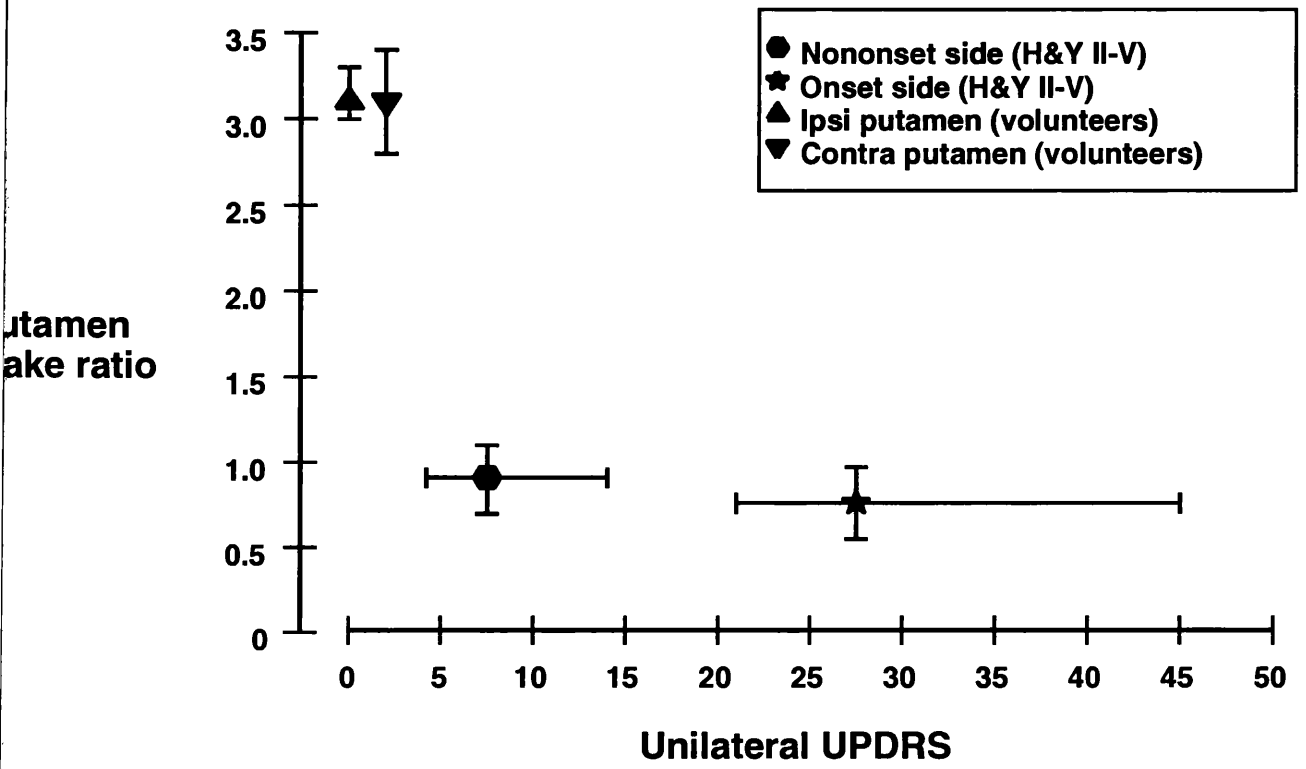


Figure 5.7 Correlation of Unified Parkinson's Disease Rating Scale motor score with mean putamen specific:nonspecific uptake ratio in 41 patients with idiopathic Parkinson's disease. One patient with an outlying observation (ratio 3.38, UPDRS 42, is not shown, but is included in statistical analysis). Regression line shown with 95% confidence limits.

specific:nonspecific
amen uptake

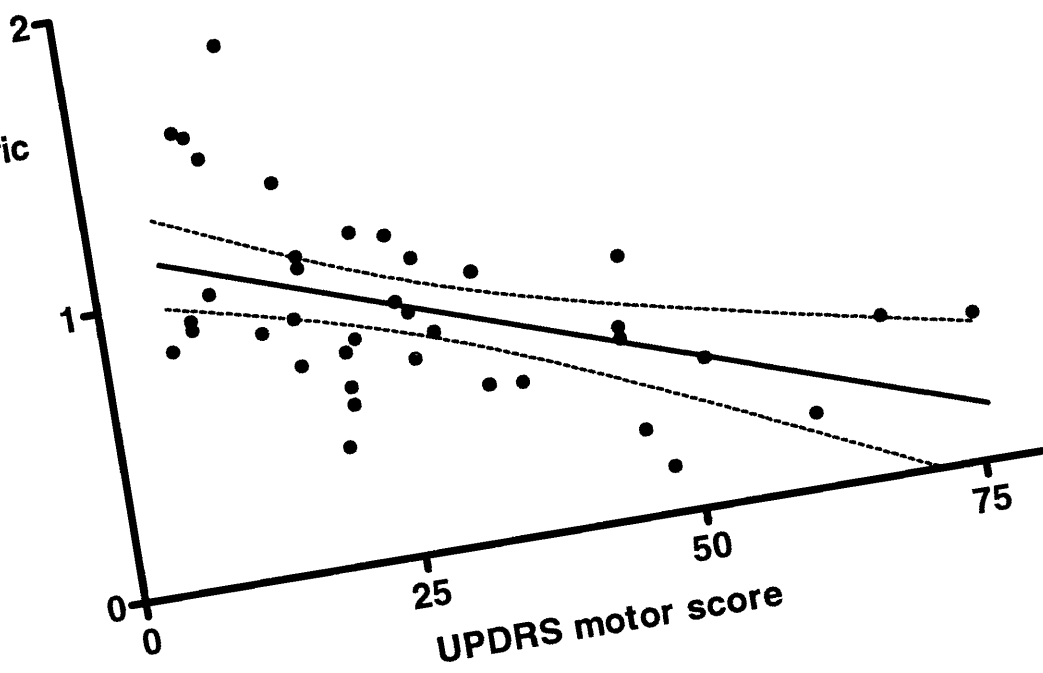
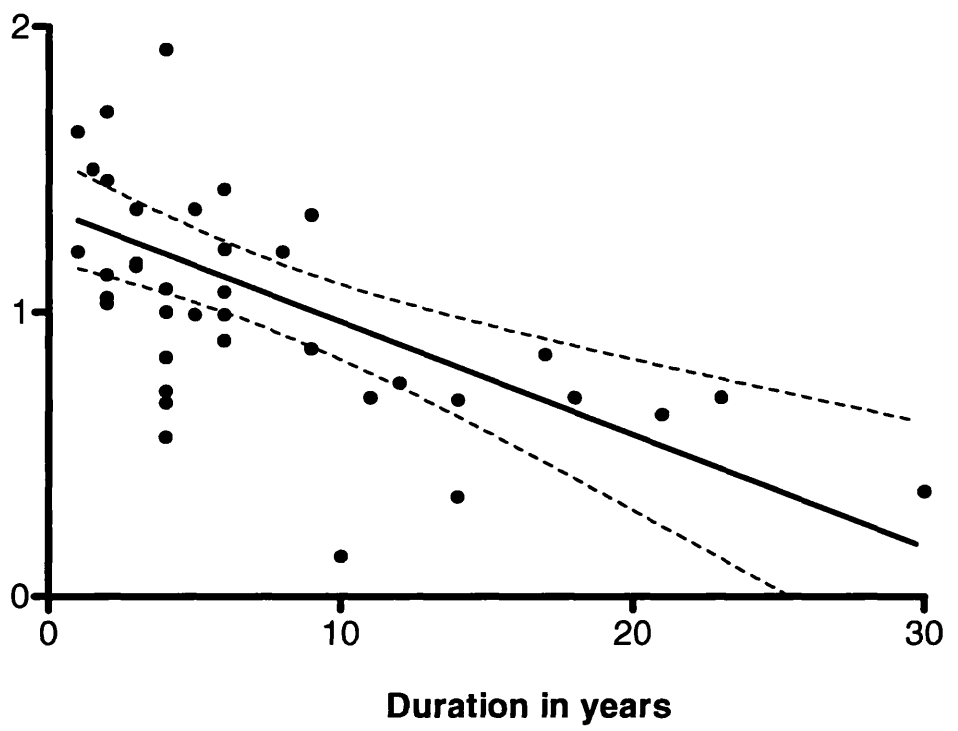


Figure 5.8 Correlation of duration of disease in 41 idiopathic Parkinson's disease patients with mean putamen specific:nonspecific uptake ratio. One patient with an outlying observation (ratio 3.38, UPDRS 42, is not shown, but is included in statistical analysis). Regression line shown with 95% confidence limits.

Specific:nonspecific
ammonia uptake



5.4 DISCUSSION

A significant relationship between global severity of iPD and functional imaging has previously been shown for ^{18}F -dopa PET and ^{123}I - β -CIT studies (Morrish et al 1996, Seibyl et al 1995, Brucke et al 1997). Morrish et al (1996) in a ^{18}F -dopa study showed a correlation between UPDRS motor score and mean striatum and putamen uptake, but not caudate uptake. Seibyl et al (1995) using ^{123}I - β -CIT SPECT demonstrated a correlation between both stage and severity of iPD and ipsilateral and contralateral caudate and putamen ratios. In two previous ^{123}I -FP-CIT studies no such correlation was shown (Booij et al 1997c, Tissingh et al 1998), but Ishikawa et al (1996) showed a correlation between striatal:occipital ratios and UPDRS motor score for H&Y I and II patients. Our results confirm this prior observation for ^{123}I -FP-CIT in early disease (H&Y I) but also extend it to later disease (H&Y II-V) showing a good correlation between the stage and severity of iPD and the decline in mean striatum, caudate and putamen SP:NS ratios as well as ipsilateral and contralateral striatum, caudate and putamen SP:NS. Further correlation was found between the striatum, caudate and putamen SP:NS ratios and disease duration. These findings imply that ^{123}I -FP-CIT has a similar capacity to PET and ^{123}I - β -CIT in monitoring severity and progression of iPD.

We examined the relationship between ^{123}I -FP-CIT and differing clinical features of parkinsonism, in light of previous reports suggesting a better correlation with bradykinesia than with tremor (Seibyl et al 1995, Brucke et al 1997). Our results for ^{123}I -FP-CIT matched these findings, and also showed a poor correlation with rigidity contrary to the finding for ^{123}I - β -CIT SPECT (Brucke et al 1997). However the degree of correlation reported by Brucke et al (1997) was also poor ($r=-0.38$). Seibyl

et al (1995) suggested that the greater weighting for bradykinesia compared to tremor within UPDRS is responsible for this correlation difference. However, in the current study rigidity and tremor showed a similarly poor correlation with SP:NP ratios ($r=-0.3$) even though rigidity is less represented in the UPDRS motor scale than tremor. A number of clinical observations support the notion that tremor origin could differ from bradykinesia, namely the slow progression of benign tremulous Parkinson's disease (Quinn 1995), the better response of bradykinesia and rigidity to dopamine replacement compared to tremor, and the improvement of tremor but not other symptoms by thalamotomy. Thus tremor severity may be linked to thalamic circuitry which is not assessed by ^{123}I -FP-CIT SPECT techniques. Others have also considered the possibility that tremor is not directly related to loss of dopamine neurones (Brucke et al 1997).

Less attention has been paid to the relationship between the laterality of symptoms and signs and functional imaging results. For example Seibyl et al (1995) found a significant correlation between *global* UPDRS and right and left basal ganglia uptake, and their finding was confirmed by another study (Brucke et al 1997). In one study using ^{11}C -nomifensine and ^{18}F -dopa PET in 9 iPD cases, Leenders et al (1990) showed a correlation between percent side-to-side differences in clinical score and percent side-to-side differences in putamen uptake, but no correlation was found between *global* clinical severity and mean specific putamen uptake. It is worth noting that Leenders et al (1990) used bradykinesia and rigidity scoring and omitted tremor, as their study preceded the universal adoption of UPDRS. Our comparison of unilateral motor features against contralateral striatal uptake ratios provides an important new message about the relationship between clinical and SPECT results.

Our finding of a significantly higher unilateral UPDRS in the onset side, for both H&Y I and H&Y II-V is of course consistent with clinical practice observation of invariably unilateral onset of iPD and persistence of worse symptoms in the onset side long after the disease becomes clinically bilateral (Lee et al 1995). The finding of a difference between ipsilateral and contralateral striatal uptake with the contralateral side being more severely affected is therefore expected (Wenning et al 1998). However, the significant overlap in the range of striatal uptakes between the ipsilateral and contralateral side, which occurs in the absence of any overlap in UPDRS values, may be an indication that other factors may contribute to the severity and the laterality of the clinical findings. For example, the degenerative process in the basal ganglia may start in one side and due to dopaminergic *interdependence* between the two nigrostriatal systems the degeneration on the other side becomes similar, but with a slight difference causing significant clinical asymmetry. This is in agreement with animal model data which showed that unilateral lesioning in the substantia nigra can cause bilateral striatal dopamine depletion (Cheramy et al 1981, Lawler et al 1995). It is supported by Doder et al (1999) who described a patient with parkinsonism as a result of unilateral striatal lesion due to head injury as shown by MRI, but with ^{18}F -dopa PET indicating bilateral striatal impairment. Another explanation could relate to prior observations that a given level of basal ganglia activity is associated with a variable range of clinical severity *between* patients (Seibyl et al 1995, Brucke et al 1997); our results suggest that this variable clinical involvement may also be present *within* individual patients, and *between* the basal ganglia of each brain hemisphere. Factors other than nigrostriatal degeneration such as abnormalities in the thalamic or subthalamic circuitry, not visualised by the SPECT technique may contribute to disease severity. Finally, imaging of the dopamine

transporters may not be as sensitive as clinical measures, although this concept is not well supported from global scoring and imaging data in this and other reports.

In our study P:C ratios distinguished iPD patients (both H&Y I and H&Y II-IV) from healthy volunteers while only putamen AI was able to do so for unilateral iPD (H&Y I) patients. There was a poor correlation for disease staging, severity and duration with P:C ratios and AI compared to SP:NS. Also, caudate and putamen AI did not differentiate bilateral iPD (H&Y II-IV) from healthy volunteers even although SP:NS ratios clearly separated bilateral iPD from healthy volunteers. However, the AI and P:C ratio were able to distinguish parkinsonism from ET and healthy volunteers. Further, poor correlation for iPD staging, severity or duration with either P:C ratio or asymmetry index was found. Putamen asymmetry index tended to correlate better with H&Y stage and disease severity as assessed by UPDRS, and even better correlation was found with disease duration. Accordingly, SP:NS is the most useful measure, as suggested by other studies (Marek et al 1996).

The pattern of involvement in the basal ganglia in our study was similar to a previous PET study (Brooks et al 1990, Ilgin et al 1999), as well as ^{123}I - β -CIT SPECT (Brucke et al 1997, Messa et al 1998) and postmortem studies (Kish et al 1985). Putamen was more severely affected than caudate, and the posterior part of putamen more affected than the anterior part. The explanation suggested by previous studies is that the ventrolateral part of the nigral cells, which project into posterior putamen is mostly affected in iPD due to relatively lower melanin in these cells, which could protect against free radical damage ((Bernheimer et al 1973, Goto et al 1989, German et al 1989, Gibb et al 1990b, Brooks et al 1990). Our interesting finding however of

significantly lower dopamine transporters in the posterior putamen of healthy people suggests that the nigrostriatal projection in posterior putamen has a relatively reduced level of dopamine transporters compared to the anterior putamen and caudate and this could be another explanation of the vulnerability of posterior putamen to Lewy body degeneration.

This study showed that the loss of dopamine transporters was 50% in iPD patients for the caudate and 70% for the putamen compared to normal volunteers, contrary to much higher figures from postmortem studies. Kaufman and Madras (1991) showed 80% reduction in the dopamine transporter density in the caudate and 96% in the putamen of 8 patients with iPD compared to 6 control brains. These results were confirmed by another postmortem study (Niznik et al 1991) and parallel the reduction of dopamine in the striatum (Kish et al 1988). The mismatch between our ^{123}I -FP-CIT SPECT results and the postmortem studies is probably because pathological studies examine severe terminal disease.

Our study showed different degrees of severity in the involvement of caudate and putamen from a previous ^{18}F -dopa PET study in which a reduction to 17% in the caudate activity, 40% in anterior putamen, and 60% in posterior putamen in iPD was found (Brooks et al 1990). These values are much lower than in our study (50% in caudate, 69% in anterior putamen and 81% in posterior putamen). However, our results are in agreement with previous PET imaging of the dopamine transporters using [11C]-WIN 35,428 (Ilgin et al 1999). The difference in results between imaging the dopamine transporters and ^{18}F -dopa PET could be due to the fact that ^{18}F -dopa uptake does not reflect a direct measure of dopamine but reflects aromatic amino acid

decarboxylase activity (Brooks et al 1990), which has been shown to fall to 88% of normal in the caudate and 37% of normal in the putamen in postmortem studies (Nagatsus et al 1979). On the other hand dopamine transporters tend to be reduced in parallel with dopamine in iPD (Kaufman et al 1991), which was reduced to 10% of the normal level when measured in postmortem subjects (Javoy-Agid et al 1986). Recent animal studies show that the change in dopamine transporters reflect more accurately the degree of neuronal loss than the levodopa levels which tend to underestimate the decrease in dopaminergic neurones (Ito et al 1999). This makes imaging of dopamine transporters with PET or SPECT more appropriate in detecting the loss of dopaminergic neurones.

Brooks et al (1990) reported similar reductions in putamen uptake in iPD, MSA and PSP, using striatal ^{18}F -dopa uptake, with PSP patients having a severe reduction in caudate and the putamen and iPD patients having significant sparing of caudate function. Patients with MSA showed a mixed pattern with resemblance to iPD in some features and to PSP in others. Also, they reported a similar degree of reduction in the posterior putamen of all three groups of patients with anterior putamen as severely involved as posterior putamen in PSP but not in iPD. Again MSA patients showed a mixed pattern. Ilgin et al (1999), using $[^{11}\text{C}]\text{-WIN35,428}$ PET to image dopamine transporters, confirmed the uniform degree of the involvement of the caudate and putamen in PSP but found more profound loss of dopamine transporter in the posterior putamen of iPD patients. $^{123}\text{I}\text{-}\beta\text{-CIT}$ SPECT studies showed mixed results with Messa et al (1998) reporting a significant reduction of caudate uptake in PSP compared to iPD and Brucke et al (1997) reporting no differences between iPD, MSA, and PSP. Our study however showed that the pattern of the reduction of

dopamine transporters in the caudate, anterior putamen and posterior putamen in iPD, MSA, PSP was similar with no significant differences but with tendency of posterior putamen to be more affected than the anterior putamen. It should be noted that in some of the above studies, even though there were differences between iPD and PSP, the uptake values showed overlap. Therefore using the pattern of distribution of tracer uptake as a tool in differentiating iPD from atypical parkinsonism is of limited use in individual patients in clinical practice.

5.5 CONCLUSIONS

- 1- This study shows that uptake of ^{123}I -FP-CIT differentiates iPD patients, and in particular unilaterally staged iPD, from healthy volunteers.
- 2- Uptake ratios correlated with staging, severity, and duration of disease, matching previous PET and ^{123}I - β -CIT reports.
- 3- The degree of asymmetry of ^{123}I -FP-CIT binding uptake is not as marked as the clinical asymmetry suggesting that factors other than nigrostriatal degeneration may contribute to disease severity.
- 4- While bradykinesia was correlated with ^{123}I -FP-CIT, tremor was not, and this supports the idea of an origin for tremor outwith the dopamine transporter system.
- 5- This study showed that the number of dopamine transporters is significantly lower in posterior putamen than anterior putamen in healthy volunteers, which could explain the well known fact of greater vulnerability of the posterior putamen to degeneration than other parts of the striatum in iPD. A similar pattern of dopamine transporters loss was found in iPD, MSA and PSP, therefore using striatal pattern distribution of dopamine transporters is of limited use in differentiating iPD from atypical parkinsonism.

6- The wide availability of SPECT and the fast kinetics of ^{123}I -FP-CIT make it an ideal technique to define nigrostriatal change in iPD, with significant potential in monitoring disease progression and putative neuroprotective therapy.

CHAPTER 6

STUDY 3

***¹²³I-FP-CIT SPECT STRIATAL UPTAKE IN
TREMOR DISORDERS***

6.1 INTRODUCTION

Bradykinesia, rigidity and resting tremor remain the standard features to diagnose iPD. However, these symptoms and signs can be subtle in the early stages of the disease reducing the level of certainty about the diagnosis, therefore delaying confirmation of the diagnosis. Also, the prevalence of subtle extrapyramidal signs in elderly subjects without a known neurological disease is 30% to 35% which could add to the problems of diagnosing parkinsonism (Richards et al 1993, Bennett et al 1996).

The presymptomatic phase of parkinsonism is well recognised, but its duration debatable. Some authors suggested up to 40-50 years (Koller 1992, Vingerhoets et al 1994), while others argued that the presymptomatic stage could be as short as 3-5 years (Fearnley and Lees 1991, Morrish et al 1996, 1998). Thus detecting nigrostriatal degeneration by functional neuroimaging in patients with very early symptoms and signs not yet fulfilling any diagnostic criteria would help in confirming parkinsonism, avoiding unnecessary delay in addressing the issue of prognosis with patients. This could also have significant implications if neuroprotective treatment becomes available in the future.

The aim of this study is to examine the potential of using ^{123}I -FP-CIT SPECT to detect nigrostriatal degeneration in patients with tremor disorders, not fulfilling standard diagnostic criteria.

6.2 METHODS

6.2.1 Study Subjects

Patients with tremor (either sex, within an age range of 40-80 years) not fulfilling either step 1 UK Brain Bank criteria for iPD (bradykinesia and rigidity and/or tremor) (Gibb et al 1988), or Findley and Koller (1994) criteria for definite or probable ET, were recruited. They were compared to 9 patients with iPD (H&Y I) diagnosed according to UK Brain Bank criteria (these 9 patients are the Glasgow cases from study 1, chapter 4; out of a total of 23 per-protocol cases scoring H&Y I), and were also compared to six healthy volunteers who were also Glasgow cases from the previous study.

Patients with clinical features suggestive of MSA, PSP, cerebrovascular disease, dementia, head injury or encephalitis were excluded. Also patients with causes of enhanced physiological tremor including hyperthyroidism, exposure to tremorogenic drugs, possible psychogenic tremor, or with any evidence of sudden onset or stepwise deterioration were excluded. Any drug intake with the potential to interact with striatal uptake of ^{123}I -FP-CIT by the dopamine transporter was disallowed, as discussed in study 1 (Chapter 4).

6.2.2 Study Assessments

Patients gave written informed consent and the study was approved by the Ethics Committee in Southern General Hospital and by the Administration of Radioactive Substances Advisory Committee. Standard safety assessments (vital signs, physical examination, laboratory tests) were conducted at baseline and repeated at least twice during the study period.

In tremor and iPD patients the contralateral (symptomatic) striatum was defined as the side opposite to that of symptom onset and for healthy volunteers the contralateral side was arbitrarily assigned to the left striatum.

6.2.3 Imaging

The patients underwent the similar imaging procedures as described in the methods section in study 2 (Chapter 5).

6.2.4 Data Analysis

Visual assessment of ^{123}I -FP-CIT SPECT consisted of the institutional read only and a consensus blinded read was not performed. The SPECT scans were graded as normal and abnormal, which was graded further to abnormal grade 1, abnormal grade 2, and abnormal grade 3 (for full detailed definition see the method section of the study 1, Chapter 4). Striatal specific:nonspecific ratios analysis was performed according to the methods described in study 2 (Chapter 5).

6.3 RESULTS

6.3.1 Study Populations

Ten patients with tremor (6 male, 60%), mean age 60 years (SD 6.6), were compared to 9 patients with iPD (8 male, 89%), mean age 56 years (SD 9.9) with H&Y I, and 6 healthy volunteers, (3 male, 50%) mean age 63 years (SD 6.1). All tremor patients were H&Y grade I. Clinical features of patients with tremor are summarised in *Tables 6.1 and 6.2*.

6.3.2 Visual Assessments

Of the 10 patients with tremor, 6 had abnormal visual ^{123}I -FP-CIT SPECT scans, while 3 (cases 6, 9 and 10) had a normal scan reading. All iPD patients (H&Y 1) had abnormal scan, while all healthy volunteers had normal scans (*Table 6.3, Figure 6.1*).

6.3.3 Specific:nonspecific Ratios

Four of the ten tremor patients (cases 1, 3, 7 and 8) had specific:nonspecific ratios for caudate and putamen within the range for patients with iPD fulfilling diagnostic criteria. All of these patients had an abnormal visual scan assessment. Cases 6, 9 and 10 had ratios within the normal range and this matched a normal visual assessment in each case. The remaining three cases (2, 4 and 5) showed reduced ratios but these were outwith the iPD range; the duration of disease in these 3 patients matched that of iPD patients fulfilling diagnostic criteria. Each of these cases had an abnormal visual scan assessment (*Table 6.4, Figures 6.1,6.2,6.3*).

Table 6.1 Characteristics and clinical features in 10 patients, not fulfilling diagnostic criteria for either idiopathic Parkinson's disease, or essential tremor.

Patient	Age	Sex	Duration (years)	Side of onset	Tremor			Medications		
					Rest	Postural	Action			
					Effect of alcohol	FH of tremor				
1 JC	45	M	2	L	Slight	Absent	Absent	No	Benzhexol	
2 MM	61	M	3	R	Mild and persistent	Mild	Absent	Yes	No	Propranolol
3 JG	59	M	4	R	Mild and persistent	Absent	Absent	No	No	Nil
4 IW	60	F	2	L	Moderate	Absent	Absent	Uncertain	No	Propranolol
5 RB	56	M	1	R	Mild and persistent	Mild	Absent	Uncertain	No	Propranolol
6 EF	67	F	2	L	Absent	Mild	Mild	Uncertain	Yes	Nil
7 LM	64	F	2	R	Mild	Mild	Absent	Uncertain	No	Nil
8 JD	55	M	2	R	Mild and persistent	Absent	Absent	Uncertain	Yes	Nil
9 JW	67	F	0.5	L	Absent	Mild	Mild	No	Yes	Nil
10 JS	63	M	20	R	Mild	Mild	Absent	Uncertain	Yes	Nil

M = Male, F = Female, FH = Family history, R = Right L = Left

Table 6.2 Further clinical features of 6 patients, not fulfilling diagnostic criteria for either idiopathic Parkinson's disease or essential tremor.

Patient	Rigidity		Bradykinesia		Leg agility	Speech	Facial expression	Arm swing	UPDRS
	Finger tapping	Hand movements	Alternating hand movements	Clumsy (L)					
1 JC	Normal	Normal	Clumsy (L)	Slightly decreased, (L)	Slow (L)	Slightly abnormal	Decreased	8	
2 MM	Clumsy (R)	Normal	Normal	Normal	Normal	Normal	Normal	5	
3 JG	Clumsy (R)	Normal	Clumsy (R)	Normal	Normal	Normal	Decreased	10	
4 IW	Normal	Normal	Normal	Slightly decreased, (R)	Normal	Normal	Normal	4	
5 RB	Normal	Normal	Normal	Slightly decreased, (R)	Normal	Normal	Normal	6	
6 EF	Normal	Normal	Normal	Normal	Normal	Normal	Decreased	3	
7 LM	Normal	Normal	Clumsy (R)	Normal	Normal	Normal	Decreased	5	
8 JD	Normal	Normal	Normal	Normal	Normal	Normal	Decreased	10	
9 JW	Normal	Normal	Normal	Normal	Normal	Normal	Normal	2	
10 JS	Normal	Normal	Normal	Normal	Normal	Normal	Normal	2	

All patients had normal gait and posture; postural instability was recorded in only 2 of 10 patient (cases 3, 4; retropulsion but recovered unaided)

+ Detectable only when activated by other movements, ++ Mild to moderate

R= Right, L= Left, N= Neck

Table 6.3 ^{123}I -FP-CIT institutional read results in tremor patients, idiopathic

Parkinson's disease and healthy volunteers.

	Normal	Abnormal		
		Grade 1	Grade 2	Grade 3
Tremor patients (n=10)	3	4	2	1
Idiopathic Parkinson's disease (n=9)	0	3	5	1
Healthy volunteers (n=6)	6	0	0	0

Normal (grade 0): Symmetrical uptake in both right and left caudate and putamen.

Abnormal (grade 1): Uptake is symmetrical with almost normal or reduced putamen activity in one hemisphere and a more marked change on the other side.

Abnormal (grade 2): Uptake is significantly reduced in the putamen on both the right and left sides.

Abnormal (grade 3): Uptake is virtually absent from both putamen and caudate nuclei on each side.

For more detailed definition of abnormal scan types, see methods section in study 1, (chapter 4).

Table 6.4 A) Specific:nonspecific ^{123}I -FP-CIT uptake ratios in ten patients with tremor.

Patient number	Caudate			Putamen		
	Ipsi	Contra	Mean	Ipsi	Contra	Mean
1	2.46	2.01 [^]	2.23 [^]	1.49 [^]	1.25 [^]	1.37 [^]
2	3.27*	2.64	2.95	2.56	1.41	1.99
3	2.45	2.12 [^]	2.33 [^]	1.38 [^]	0.92 [^]	1.15 [^]
4	3.70*	3.33*	3.52*	2.31	1.81	2.06
5	3.41*	3.83*	3.62*	2.31	2.17	2.24
6	3.36*	3.74*	3.55*	3.18*	3.32*	3.25*
7	2.68	1.99 [^]	2.34	1.86	1.11 [^]	1.48
8	1.57 [^]	1.39 [^]	1.48 [^]	0.88 [^]	0.96 [^]	0.92 [^]
9	3.80*	3.82*	3.81*	3.31*	3.26*	3.29*
10	4.47*	4.51*	4.49*	4.33*	4.50*	4.42*

Ipsi=ipsilateral, contra=contralateral

** Within normal range, [^] within parkinsonian range, the other values lie between normal and parkinsonian range*

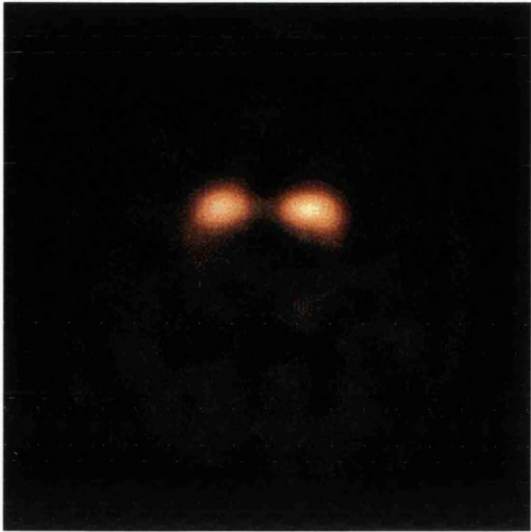Table 6.4 B) Specific:nonspecific ^{123}I -FP-CIT uptake ratios in idiopathic Parkinson's disease patients (n=9) and healthy volunteers (n=6).

	Caudate			Putamen		
	Ipsi	Contra	Mean	Ipsi	Contra	Mean
Idiopathic Parkinson's disease (H&Y I)	2.1 (1.6-2.6)	1.8 (1.4-2.2)	2.0 (1.5-2.4)	1.3 (1.0-1.7)	0.90 (0.73-1.1)	1.1 (0.88-1.4)
Healthy volunteers	3.5 (3.1-3.8)	3.5 (3.1-4.0)	3.5 (3.1-3.9)	3.1 (3.0-3.3)	3.1 (2.8-3.4)	3.1 (2.9-3.3)

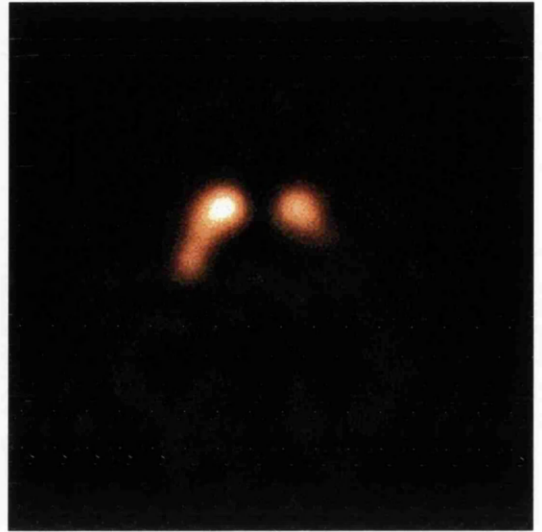Data are mean (CI)

Figure 6.1 ^{123}I -FP-CIT uptake in 10 tremor patients.


Patient 1



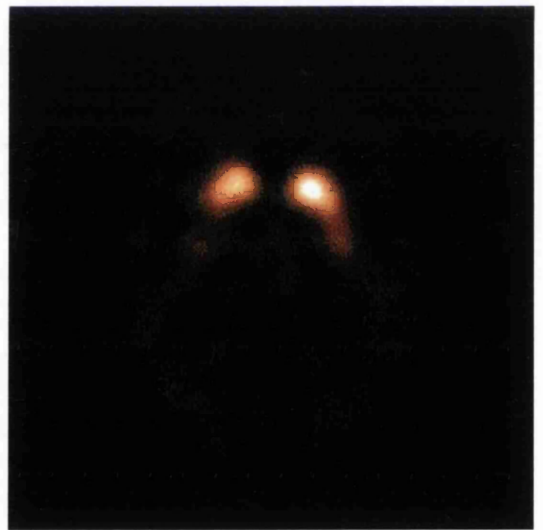
Patient 2



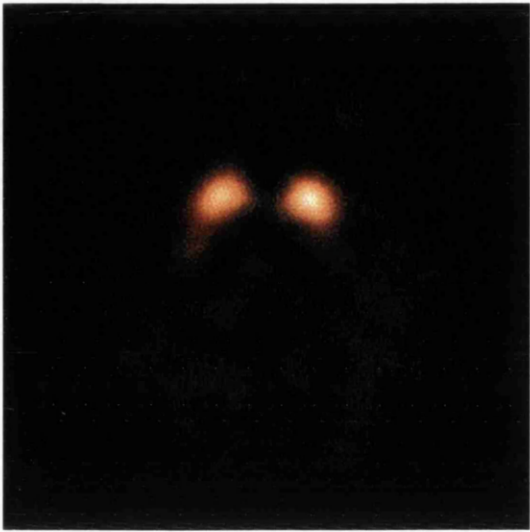Patient 3



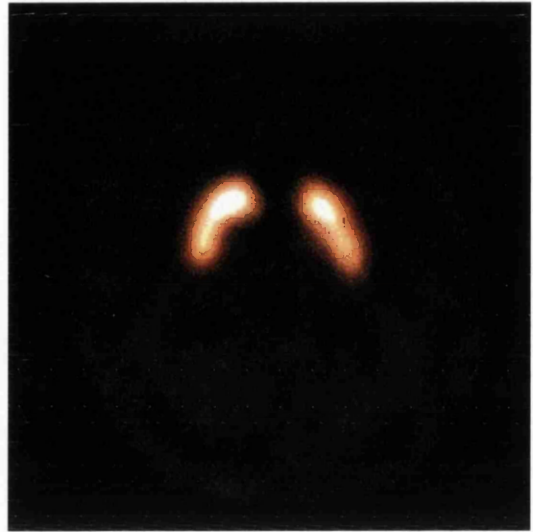Patient 4



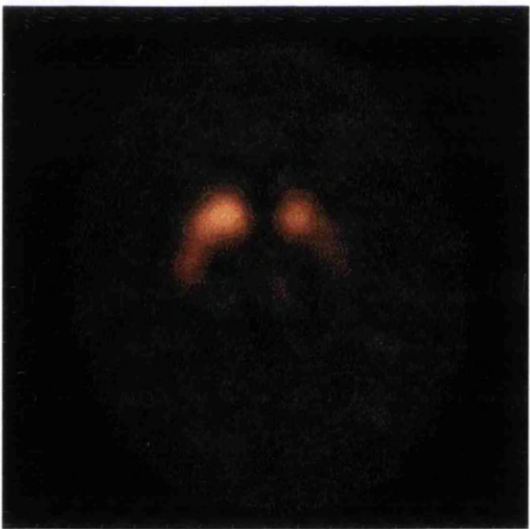
Patient 5



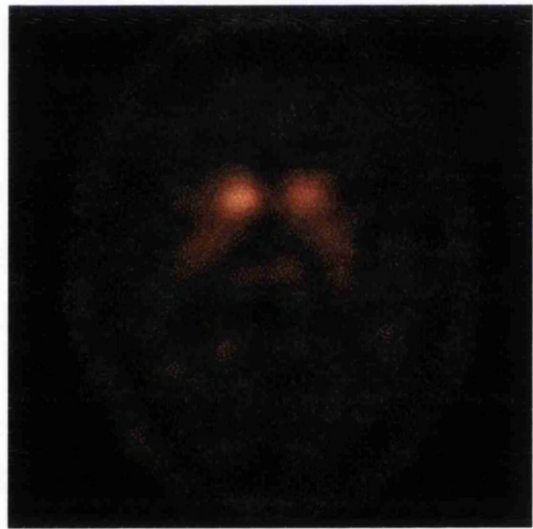
Patient 6




Patient 7



Patient 8



Patient 9



Patient 10



Figure 6.2 Specific:nonspecific ratios in 10 patients with tremor, 9 idiopathic Parkinson's disease cases, and 6 healthy volunteers.

A) Caudate specific:nonspecific ratios showing reduced uptake in the asymptomatic side of 4 of 10 patients with tremor (inverted solid triangle) and 8 of 9 patients with idiopathic Parkinson's disease (inverted solid triangle). In the symptomatic side 5 tremor patients had reduced uptake (hollow triangle) and the other 5 had uptake within normal range (hollow triangle); all idiopathic Parkinson's disease patients had abnormal uptake (hollow triangle).

B) Putamen specific:nonspecific ratios showing reduced uptake in the asymptomatic side in 7 of 10 tremor patients (inverted solid triangle). Three patients had a reduced specific:nonspecific ratio but outwith the uptake of patients fulfilling diagnostic criteria for idiopathic Parkinson's disease (inverted solid triangle). Findings were similar in the symptomatic side (hollow triangle). All idiopathic Parkinson's disease had reduced uptake bilaterally (hollow triangle).

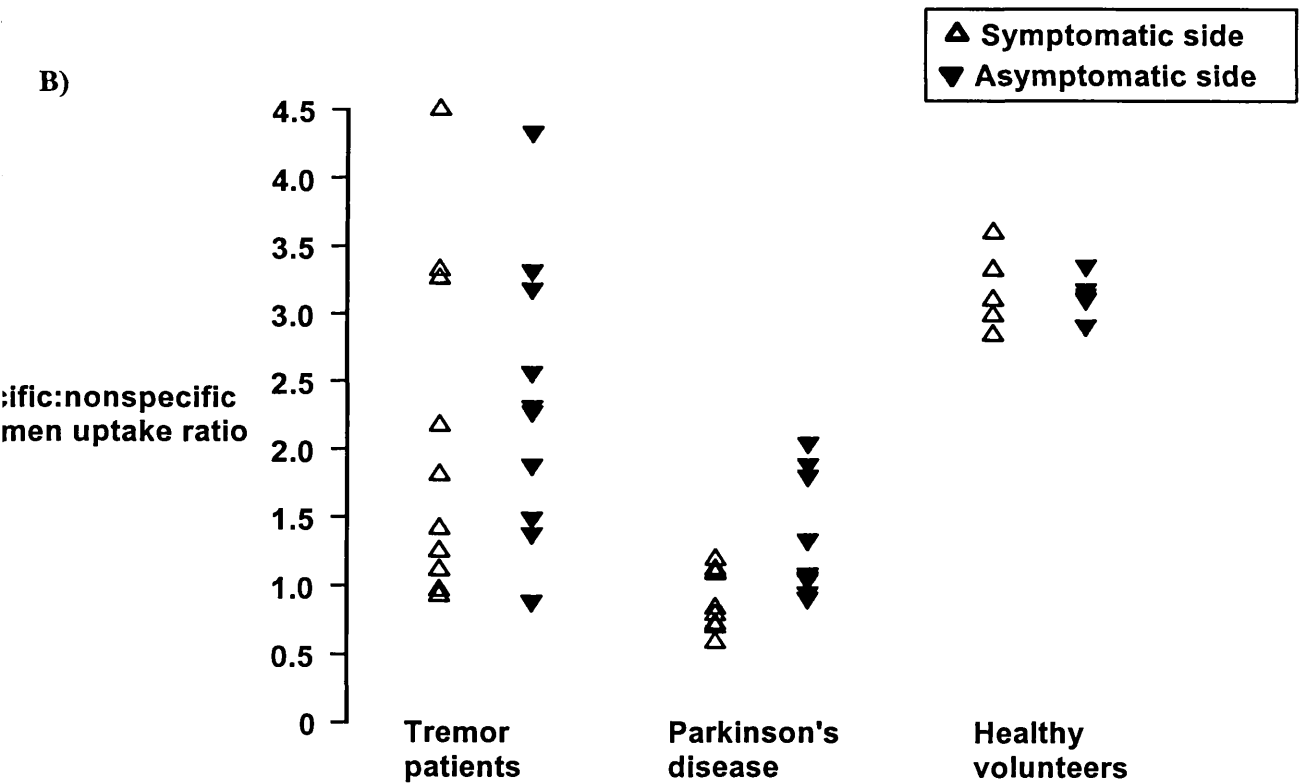
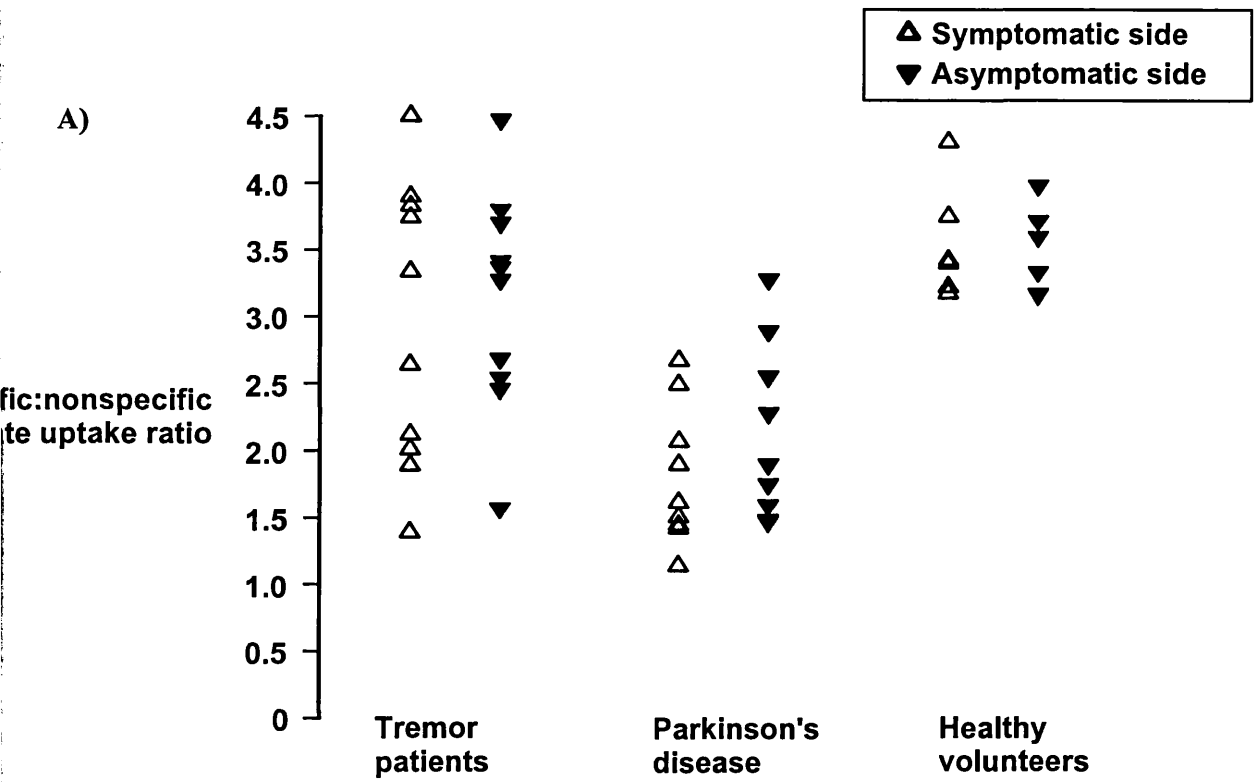
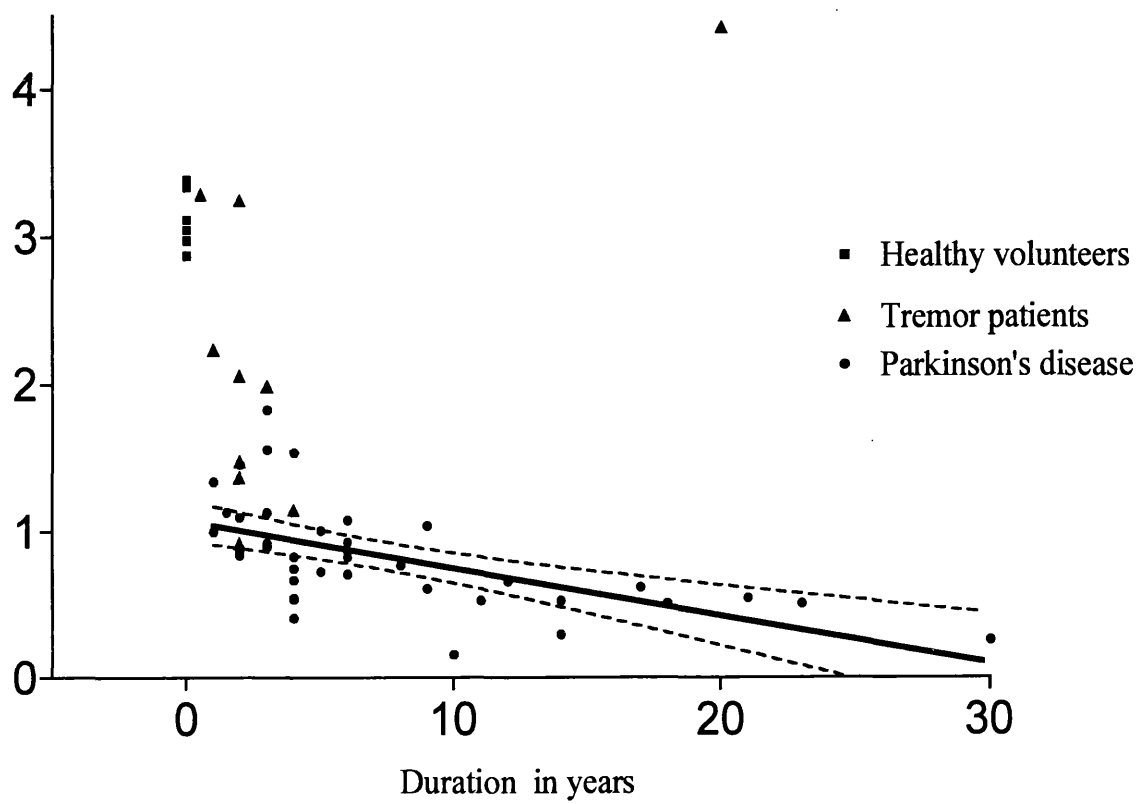


Figure 6.3 Correlation of duration of disease in idiopathic Parkinson's disease (41 cases) with mean putamen specific:nonspecific uptake ratio (study 2, chapter 5) and 10 patients with tremor. Three of the tremor patients have reduced uptake (green solid triangles, cases with putamen uptake of 1.99, 2.06 and 2.24) outwith the parkinsonian range but a similar duration of disease to cases with idiopathic Parkinson's disease fulfilling diagnostic criteria.

fic:nonspecific
en uptake ratio



6.4 DISCUSSION

The clinical features of parkinsonism have been scored for sensitivity and specificity for diagnosing iPD in several studies. Hughes et al (1992), on the basis of a clinico-pathological study, estimated that the presence of 2 of the cardinal features of parkinsonism gives a 99% sensitivity but only 9% specificity. Also they estimated that the presence of the three features reduces the sensitivity to 65% but increases the specificity to 71%. On the other hand isolated resting tremor has a sensitivity of 76% and specificity of 50%. Therefore at best clinical features provides a specificity of 70%. However, Brooks et al (1992b) using ^{18}F -dopa PET showed that the presence of resting tremor, reduced arm swing, cogwheel rigidity, and short tremor duration in patients with predominantly postural tremor does not always predict an abnormality of the nigrostriatal system. ET patients may exhibit mild signs suggesting parkinsonism such as a slightly expressionless face and a stooped posture especially in the elderly (Deuschl et al 1998a). Also, applying UK Brain Bank criteria improves the diagnostic accuracy of iPD from 76% to 82% (Hughes et al 1992). Thus relying on neurological examination and applying diagnostic criteria alone can be misleading in the diagnosis of iPD and ET. Also, it may take many years before all the clinical features emerge to make the clinical diagnosis relatively easy.

In the above mentioned ^{18}F -dopa PET study, Brooks et al (1992b) found that some patients with rest tremor and without bradykinesia, therefore not fulfilling UK brain bank criteria for iPD, have disruption of the nigrostriatal dopaminergic system while other patients with predominant postural tremor, who fail Findley and Koller criteria for definite ET, have a normal nigrostriatal system. However, one patient with sporadic postural tremor had a putamen uptake compatible with iPD, and

subsequently developed features of the disease, while another patient had abnormal putamen uptake but not severe enough to be classified as iPD and with clinical features remaining static after 2 years of follow-up. In patients with resting tremor 9 had contralateral and 8 ipsilateral reduction of putamen uptake compatible with iPD. Further evidence that tremor characteristics and other clinical features do not discriminate these conditions comes from Asenbaum et al (1998) who reported normal ^{123}I - β -CIT uptake in 32 patients with ET compared to iPD. They classified their ET patients into 3 groups, definite, probable and possible, and more than half exhibited resting tremor as well as the usual postural tremor. Patients with neurological signs additional to tremor such as lack of arm swing were however excluded from the possible ET group. Therefore, using functional neuroimaging in patients with atypical tremor could help in clarifying diagnosis.

One of the potential uses of ^{123}I -FP-CIT is to detect nigrostriatal degeneration in patients with predominant tremor who have mild and early symptoms, and subtle signs. In the present study none of the 10 patients fulfilled standard diagnostic clinical criteria and all had mild symptoms making performance and interpretation of a challenge test difficult. In all but three ^{123}I -FP-CIT SPECT was abnormal indicating disruption of the nigrostriatal pathway. Cases 6 and 9 both of whom had unilateral postural and action tremor, and in whom a diagnosis of iPD could not be excluded clinically at this stage, showed a normal scan which on present evidence is against the possibility of parkinsonism. A further three of the tremor patients had reduced striatal uptake but above the iPD range of uptake, although the duration of their symptoms matched cases fulfilling diagnostic criteria. It seems likely that these patients will enter the iPD range but it would be speculative as to when they might fulfil diagnostic

criteria. Another three patients have similar uptake and duration of illness to iPD patients but failed to fulfil diagnostic criteria for iPD. It is likely that other signs (mainly bradykinesia) will emerge soon which would then fulfil diagnostic criteria. Similar results was obtained in the asymptomatic basal ganglia in the 3 patients who had putamen uptake in the iPD range and 4 who had reduced uptake but above the iPD range. All H&Y I patients had abnormal uptake, thus confirming the ability of ^{123}I -FP-CIT SPECT in detecting the presymptomatic phase. Although this study was not designed to estimate the length of the presymptomatic stage, the abnormal uptake values above the parkinsonian range may hint at a relatively short presymptomatic stage.

Deuschl and Krack (1998b) proposed criteria to label patients with mainly resting tremor as *mono-symptomatic resting tremor*. Their criteria included pure or predominant resting tremor; no signs of bradykinesia, rigidity, or problems with stability of stance sufficient to diagnose iPD; and duration of tremor at least 2 years. The clinical features of patients 2 and 4 fulfil this criteria, and their striatal uptake is between normal and the established parkinsonian range. Also, patients 7 and 8 fulfil the mono-symptomatic resting tremor criteria but their striatal uptake is within the parkinsonian range. This adds to available evidence that some patients who exhibit only tremor have a dopaminergic deficit insufficient to produce other parkinsonian symptoms and signs. Probably the proposed title (*mono-symptomatic resting tremor*) represents patients with *benign tremulous parkinsonism*, but it is useful in emphasising that tremor need not always be associated with measurable bradykinesia.

It is important to point out that abnormal ^{123}I -FP-CIT SPECT indicates striatal degeneration and it is not diagnostic of iPD therefore patients with an abnormal scan could still have an early MSA or PSP. However resting tremor is less likely to be the key presenting feature in patients with MSA or PSP (Collins et al 1995a, Albanese et al 1995, Wenning et al 1997), making iPD the most likely diagnosis in 7 of our 10 cases (cases 1-5, 7 and 8). We intend to review the clinical progress in these patients at one and two years to confirm the expected emergence of parkinsonian features and to repeat SPECT at two years to examine progression rates both clinically and by functional imaging.

Recently, Lee et al (1999), using ^{123}I -IPT SPECT to assess the dopamine transporter compared 6 patients with isolated postural tremor (mean duration 16 years) with 6 patients with postural and rest tremor (mean duration 18 years). They found no differences between uptake ratios of patients with isolated postural tremor and controls but uptake ratios were significantly lower in patients with postural and resting tremor than controls. However, uptake ratios in patients with postural and resting tremor were significantly higher than uptake ratios in iPD patients. Although their patients have a longer duration of tremor they exhibited little rigidity or bradykinesia, so they concluded that patients with long-standing postural tremor may develop resting tremor in association with mild nigral neuronal loss. Their findings are contrary to the findings of normal substantia nigra in postmortem studies of patients with postural and rest tremor (Rajput et al 1991b) and ^{18}F -dopa SPECT reports (Brooks et al 1992b). Lee et al (1999) argued that Rajput et al (1991b) did not count the number of nigral cells and ^{18}F -dopa SPECT can be influenced by aromatic amino acid decarboxylase hyperactivity compensating for nigral neuronal loss. Our

study did not address this issue. However, patient 10 in our study has had unilateral mild postural and resting tremor for 20 years and his ^{123}I -FP-CIT SPECT showed normal uptake, indicating that longstanding tremor of this type can occur with a normal dopamine transporter system.

The present study examines the area of greatest immediate potential clinical application for basal ganglia imaging with ^{123}I -FP-CIT. The results are encouraging for valid clinical use. Patients positively identified as having a dopaminergic deficit will have clinical suspicion of parkinsonism increased, while patients with a normal dopaminergic system are identified as more definitely non-parkinsonian. A minority of patients have been identified in this study, with intermediate readings between the range for established iPD and that for healthy volunteers. This rises the need for following-up research studies as mentioned above, and may indicate a need in selected cases for repeated basal ganglia imaging studies to determine whether progression has occurred. It will be important to establish whether, in this small subgroup of patients, repeat imaging provides useful data adding to repeat clinical observations.

6.5 CONCLUSIONS

- 1- ^{123}I -FP-CIT showed reduced uptake in patients with resting tremor but not fulfilling standard diagnostic criteria confirming nigrostriatal degeneration, while excluding dopaminergic terminal damage in patients with isolated postural tremor.
- 2- Our findings indicate that ^{123}I -FP-CIT could help in clarifying the diagnosis in patients with early or non-progressive tremor.

3- This study confirms the existence of a presymptomatic phase in iPD. A larger sample of patients with repeated clinical and SPECT assessment in one and two years' time is indicated to address the issues of disease progression and the length of the presymptomatic phase.

4- Further studies are needed to clarify the nigrostriatal changes in patients with longstanding postural tremor who develop resting tremor.

CHAPTER 7

STUDY 4

***THE RELATIONSHIP BETWEEN TREMOR
DISORDERS, PARKINSONISM AND
CEREBROVASCULAR DISEASE***

7.1 INTRODUCTION

Since it was introduced by Critchley in 1929, the concept of parkinsonism caused by or associated with cerebrovascular disease has been extensively debated and several alternative terms have been used including vascular parkinsonism, lower body parkinsonism, and arteriosclerotic pseudoparkinsonism. However, there are no generally accepted clinical criteria to diagnose the condition.

Hughes et al (1992) reported, in a clinico-pathological study of 100 cases with a clinical diagnosis of iPD, 3 patients with lacunar infarcts and no Lewy bodies, and 19 iPD cases with co-existent striatal vascular pathology. This postmortem study provides evidence that iPD patients may also have cerebrovascular disease, and that patients with parkinsonism may have cerebrovascular disease but no pathological features of iPD (see chapter 1, page 19-23, for more detailed discussions of the issues relating to vascular parkinsonism).

Tremor is a rare manifestation of stroke, with only one patient reported to have tremor in a study of 2500 patients with first-ever stroke in Lausanne (Ghika-Schmid et al 1997) and only three patients reported to have tremor in a review of 240 published cases of focal lesions affecting basal ganglia, two of whom had stroke (Bhatia and Marsden 1994). Tremor as a result of stroke usually accompanies other neurological features (Ferber and Gerwig 1993, Kim 1992, Dethy et al 1993, Kim and Lee 1994, Qureshi et al 1996, Schulze-Bonhage and Ferbert 1998), but cases with isolated tremor as a result of stroke have been reported twice in the English literature (Lee et al 1993, McAuley et al 1998). An index case of isolated tremor due to cerebrovascular disease is described in this study.

No previous PET or SPECT study has addressed the issue of vascular parkinsonism. The aim of this pilot study is to examine the changes in the basal ganglia in this group of patients using ^{123}I -FP-CIT SPECT, and to explore the concept of vascular parkinsonism.

7.2 METHODS

7.2.1 Study Subjects

Twelve patients of either sex, within an range between age 40-85 years, and with vascular parkinsonism defined as the presence of any cardinal feature of parkinsonism (bradykinesia, rigidity or tremor) and a clinical vascular risk factor profile and/or with subcortical ischaemic changes in structural neuroimaging (CT or MRI Scan) were selected from patients attending the movement disorder clinic. They were compared to 6 healthy volunteers recruited from the previous study (Chapter 4).

Patients with clinical features suggestive of MSA or PSP were excluded and any drug intake with the potential to interact with striatal uptake of ^{123}I -FP-CIT by the dopamine transporter was disallowed, as discussed in the previous study (Chapter 4).

The clinical features and investigations of an index patient with isolated tremor attributed to stroke are described.

7.2.2 Study Assessments

Patients gave written informed consent and the study was approved by the Ethics Committee in Southern General Hospital and by the Administration of Radioactive Substances Advisory Committee. Standard safety assessments (vital signs, physical

examination, laboratory tests) were conducted at baseline and repeated at least twice during the study period. Patients assessed using UPDRS motor section. The structural images were assessed by a Neuroradiologist blinded to the clinical data.

7.2.3 *Imaging*

The patients underwent the similar imaging procedures as described in the methods section in study 2 (Chapter 5).

7.2.4 *Data Analysis*

Visual assessment of ^{123}I -FP-CIT SPECT consisted of institutional read only; a consensus blinded read was not performed. The SPECT scans were graded as normal and abnormal, which was graded further to abnormal grade 1, abnormal grade 2, and abnormal grade 3 (for full detailed definition see the method section of the study 1, chapter 4). Striatal specific:nonspecific uptake ratios analysis was performed according to the methods described in study 2 (Chapter 5).

7.2.5 *Statistical Analysis*

Comparisons of striatal uptake in vascular parkinsonism and healthy volunteers were made by one-way analysis of variance with Bonferroni correction for pre-specified multiple comparisons.

7.2.6 *Index case*

An index case of isolated tremor related to ischaemic stroke was studied in detail by repeated cranial imaging and neurophysiology testing, to explore the link between tremor conditions and structural cerebrovascular changes.

7.3 RESULTS

Twelve patients with VP, (8 male, 67%), mean age 68 years (SD 8.2) and with median UPDRS motor score of 21(interquartile range 8-34 (mean 15, SD 15) and 6 healthy volunteers, (4 male, 67%) mean age 63 years (SD 6.1) were recruited. For a detailed analysis of the clinical features of patients with vascular parkinsonism, see *Table 7.1*.

Of these 12 cases, 11 were abnormal. Eight of these had abnormalities which corresponded with the predefined grades (*Table 7.2, Figure 7.1, 7.3*). Three patients (cases 5, 6 and 11) had an unusual uptake pattern not conforming to the pre-defined grades, therefore their SPECT scans were not graded (*figure 7.2*). Only one patient (case 11) had a normal scan.

Specific:nonspecific ratios for both right and left caudate and putamen were significantly lower than in healthy volunteers (*Table 7.3, Figure 7.4*).

Index case

A 45 year-old right handed woman with sudden onset of tremor while walking which was initially fluctuant in the left thumb but then spread to all the digits of her left hand and became persistent. The tremor worsened with stress and excitement. There was no family history of tremor, or use of tremor-inducing drugs. She smoked 15 cigarettes per day and drank less than 2 units of alcohol per week. Initial assessment revealed a coarse mainly postural tremor affecting the left hand with no evidence of bradykinesia or rigidity. Limb reflexes were abnormally brisk in left arm and leg, otherwise the neurological examination was unremarkable. T2-weighted MRI revealed a small focal lesion in the anterolateral aspect of the right putamen and adjacent white matter

considered most likely to be an ischaemic lesion (*Figure 7.5 A*). Her tremor failed to respond to propranolol, theophylline, and benzhexol. A year later she was treated with levodopa with no benefit. Two years later, with no improvement in her tremor, the MRI scan was repeated and showed no change in the lesion size (*Figure 7.5 B*). Further investigations including cerebrospinal fluid analysis and visual evoked potentials were normal, making demyelination improbable. Laboratory tests, including full blood count, ESR, coagulation screen, thrombophilia screen, autoantibody screen, syphilis serology, urea/ electrolytes, creatinine, fasting glucose, liver function tests, calcium, phosphate, thyroid function test, serum and 24 hour urinary copper were all unremarkable. At that time, she reported that 2 units of alcohol were helpful in controlling her tremor. Five years after the onset there was no change in her tremor, which continues to be unilateral involving the left side. Although mild at rest, it worsens with changes in posture and now requires 4-5 units of alcohol to control it. On one occasion smoking cannabis produced a similar relieving effect as alcohol. Electrophysiological studies of her tremor were carried out by obtaining surface electromyography (EMG) recording from extensor digitorum communis and accelerometer recordings from the left middle finger. Recordings were made at rest and with her arm out-stretched. These revealed a 5-6 Hz tremor, which did not vary in frequency with posture. Frequency analysis of filtered rectified EMG also confirmed a dominant frequency of 5-6 Hz with additional harmonic activity seen at 11 Hz (*Figure 7.6*). She did not tolerate primidone; however her tremor improved with a single oral dose of 8mg ondansetron.

Table 7.1A Clinical features and investigation of 12 patients with vascular parkinsonism.

Patient No	Age	Sex	Side of onset	Initial presentation	Duration (years)	Clinical features	Response to L-dopa	UPDRS	*Structural imaging (CT or MRI)	Vascular risk factors
1 JR	68	F	R+L	Gait disorder	1.5	Start hesitation, little upper body abnormality	Negative L-dopa challenge	22	Focal white matter lesions	Angina Hypertension
2 ED	75	F	R+L	Gait disorder	1	Start hesitation with little upper body abnormality	Negative L-dopa challenge	9	Normal	Angina Hypertension
3 RC	77	M	L	Unilateral tremor	8	Asymmetrical bradykinesia, later rigidity	Good response to levodopa	20	Normal	TIA and Carotid endarterectomy
4 TW	71	M	R	Unilateral tremor	1.5	Bilateral bradykinesia and rigidity	No response to levodopa	39	Lacunar infarct in the right caudate.	TIA, Carotid endarterectomy and cardiac bypass surgery
5 JR	71	M	R+L	Generalised slowing	5	Hypokinetic-rigid syndrome with no tremor	No response to long-term levodopa	50	3 lacunar infarctions in the right basal ganglia. (Figure 7.2)	Stroke (left sided hemiplegia, 7 years before the onset of parkinsonism)
6 JB	65	M	R	Unilateral tremor	1.5	Isolated tremor with no bradykinesia	Not on levodopa	4	Lacunar infarct in left putamen (Figure 7.3)	Hypertension

*All patients had CT except patient 4 who had MRI, UPDRS= Unified Parkinson's Disease Rating Scale, TIA= Transient ischaemic attack
M= Male, F= Female, R= Right, R+L= Symmetrical

Table 7.1B Clinical features and investigation of 12 patients with vascular parkinsonism.

Patient No	Age	Sex	Side of onset	Initial presentation	Duration (years)	Clinical features	Response to L-dopa	UPDRS	*Structural imaging (CT or MRI)	Vascular risk factors
7 CN	56	M	R	Tremor	2	Mild action tremor with possible bilateral bradykinesia	Not on levodopa	7	Lacunar infarct in the right basal ganglia	NIDDM Hypertension Stroke
8 NG	66	M	L	Tremor	9	Left arm rest tremor and bilateral bradykinesia and rigidity	Negative L-dopa challenge	29	Lacunar infarction in left globus pallidus	Angina Stroke (right sided weakness)
9 RS	83	M	L	Unilateral tremor	2	Asymmetrical bradykinesia and rigidity	Negative L-dopa challenge	54	Diffuse white matter lesions	TIA
10BF	61	M	R+L	Shuffling gait, urge incontinence, and possible tremor	2	Hypokinetic-rigid syndrome with minimal tremor	Not on levodopa	24	2 lacunar infarctions in the right basal ganglia, and left putamen, and diffuse white matter changes	Stroke (left sided hemiplegia) and 3 episodes of TIA
11 RF	57	F	R	Unilateral tremor	14	Mainly postural and action tremor in the right hand with slight rigidity	Not on levodopa	7	Bilateral occipital and brain stem infarcts	Right side hemiplegia
12 JC	61	F	R	Lack of arm swing	2	Hypokinetic-rigid syndrome with minimal tremor	Some response to levodopa	11	Normal	Angina Hypertension

M= Male, F= Female, R= Right, R+L= Symmetrical

*All CT

Table 7.2 ^{123}I -FP-CIT institutional read results for vascular parkinsonism and healthy volunteers.

	Normal	Abnormal		
		Grade 1	Grade 2	Grade 3
Vascular parkinsonism (n=12)*	1	2	5	1
Healthy volunteers (n=6)	6	0	0	0

**3 patients (cases 5, 7 and 10) had an unusual uptake pattern, therefore their SPECT was not included in the grading.*

Normal (grade 0): Symmetrical uptake in both right and left caudate and putamen.

Abnormal (grade 1): Uptake is symmetrical with almost normal or reduced putamen activity in one hemisphere and a more marked change on the other side.

Abnormal (grade 2): Uptake is significantly reduced in the putamen on both the right and left sides.

Abnormal (grade 3): Uptake is virtually absent from both putamen and caudate nuclei on each side.

For more detailed definition of abnormal scan types, see methods section in study 1, chapter 4.

Table 7.3 A) Striatal ^{123}I -FP-CIT specific:nonspecific uptake ratios of patients with vascular parkinsonism (12) and healthy volunteers (6).

	Right	Left	Right	Left
	caudate	caudate	putamen	putamen
Vascular parkinsonism	2.2* (1.7, 2.7)	2.6** (2.0, 3.1)	1.4^ (0.86, 2.0)	1.8* (1.1, 2.4)
Healthy volunteers	3.5 (3.1,3.8)	3.5 (3.1, 4.0)	3.1 (3.0, 3.3)	3.1 (2.8, 3.4)

* $p < 0.01$ compared to healthy volunteers

** $p < 0.05$ compared to healthy volunteers

^ $p < 0.001$ compared to healthy volunteers

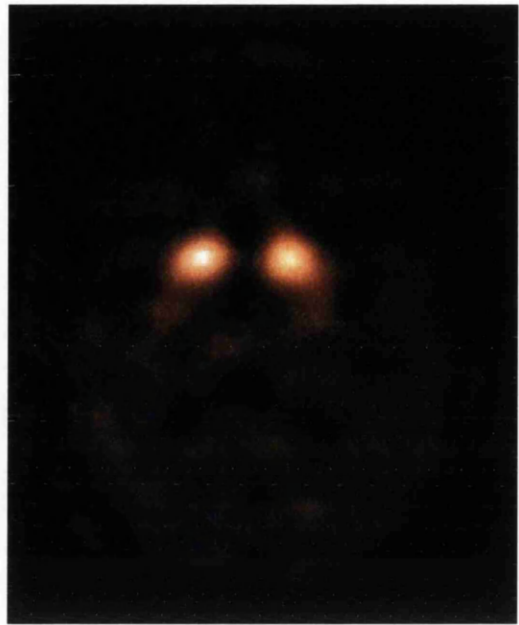Table 7.3 B) Specific:nonspecific ^{123}I -FP-CIT uptake ratios in 12 patients with vascular parkinsonism.

Patient number	Caudate		Putamen	
	Right	Left	Right	Left
1	1.84	1.87	0.78	0.72
2	1.98	2.11	0.98	1.05
3	1.33	1.93	0.65	0.65
4	1.21	0.95	0.73	0.49
5	1.21	3.25	0.87	2.63
6	2.78	2.79	2.02	1.69
7	2.01	3.05	1.35	2.73
8	2.03	2.59	0.92	1.34
9	2.32	2.16	1.31	1.14
10	2.90	3.39	2.43	3.28
11	3.91	3.97	3.73	3.64
12	2.69	2.47	1.48	1.34

Figure 7.1 Abnormal ^{123}I -FP-CIT uptake in patients with lower body parkinsonism (cases 1 and 2).



Case 1



Case 2

Figure 7.2 Structural and functional imaging in case 5

A) CT scan showing 3 lacunar infarctions in the right basal ganglia (arrows)

B) Severe reduction in ^{123}I -FP-CIT uptake in left striatum with almost normal appearance on the other side.

C) IBZM SPECT showing severe reduction in the uptake ratios.

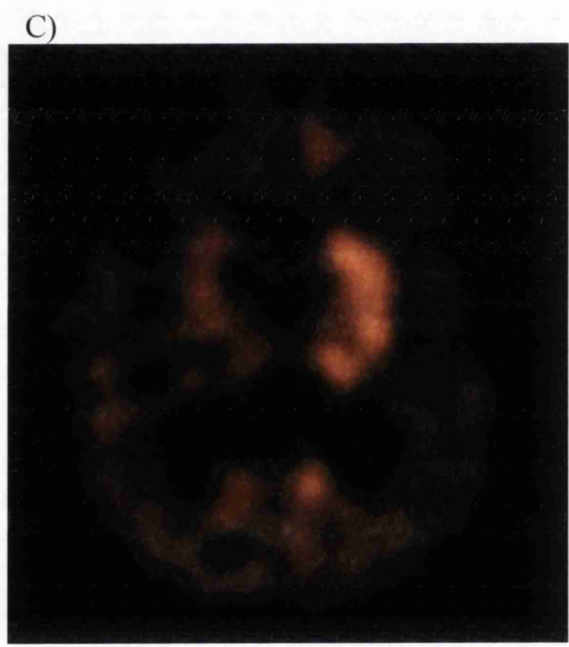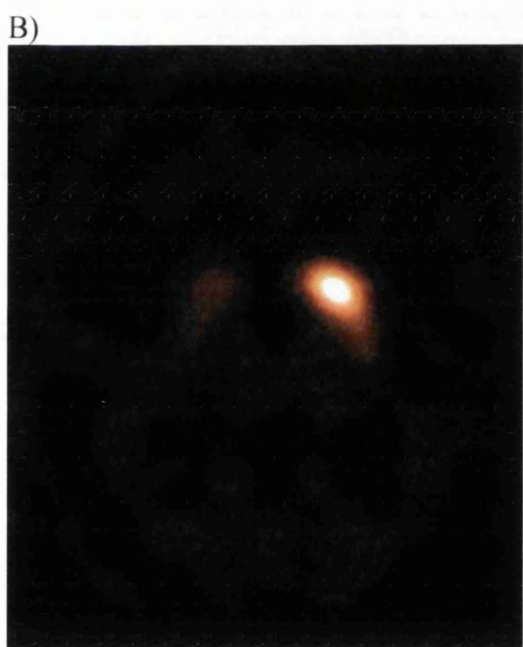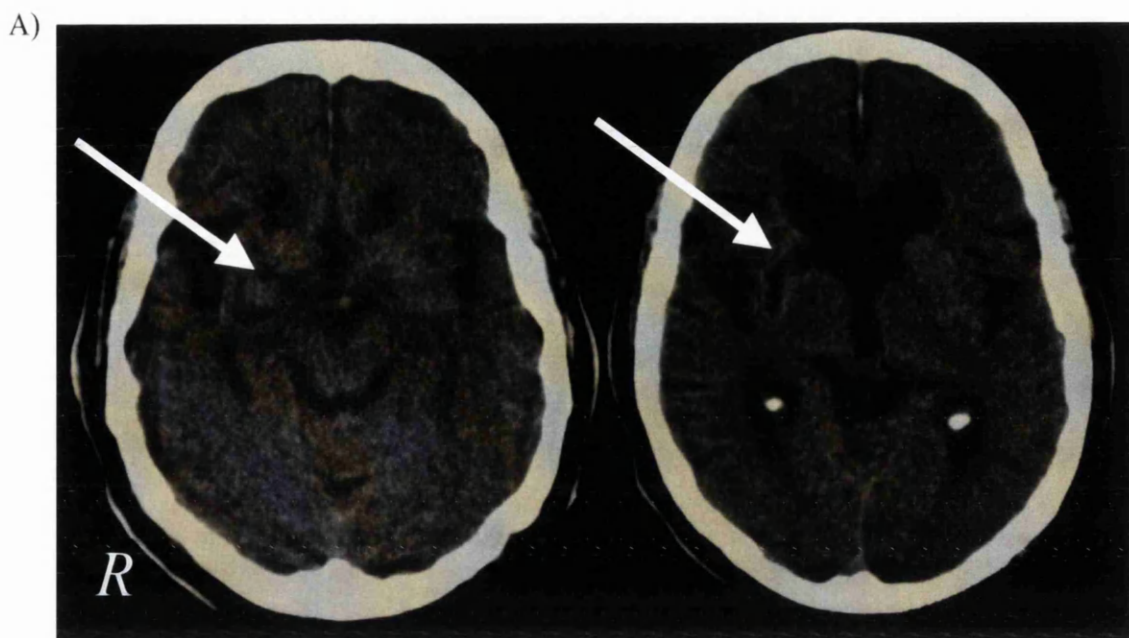
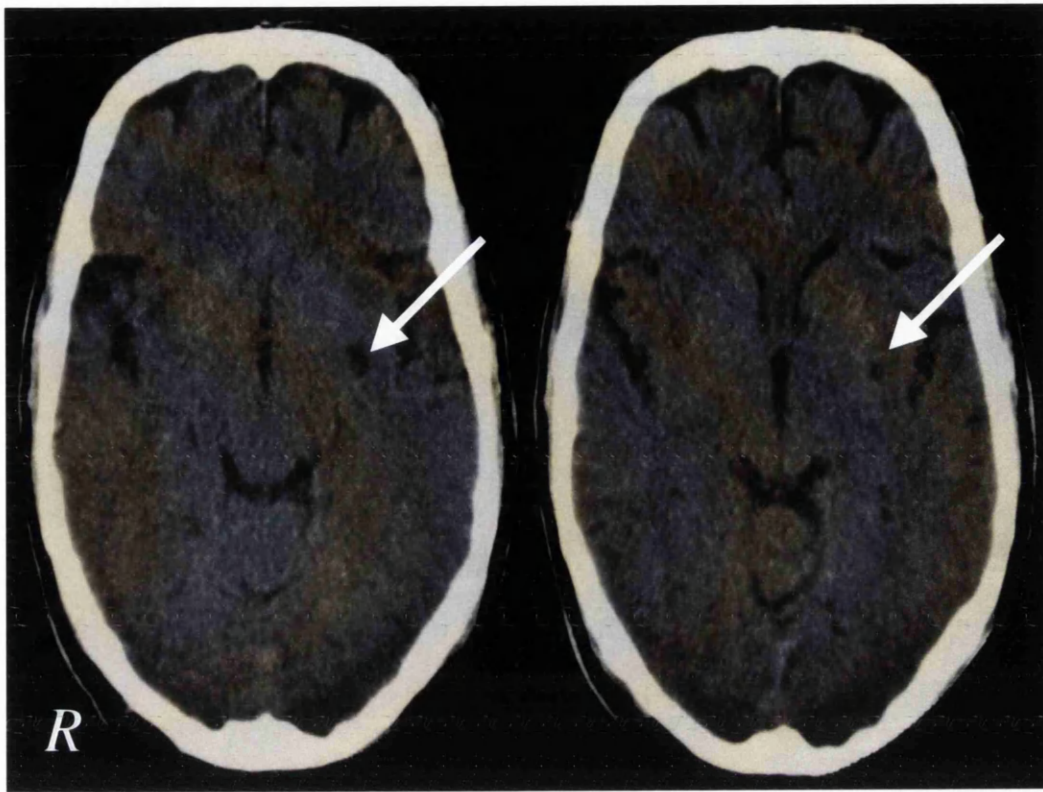


Figure 7.3 Structural and functional imaging in case 6

A) CT scan showing a lacunar infarct in left putamen (arrows).

B) Abnormal ^{123}I -FP-CIT uptake in the bilateral striatum (grade 1).

A)



B)

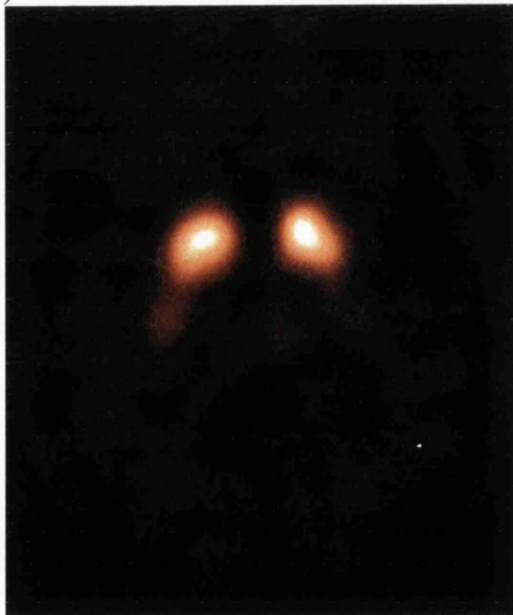

Figure 7.4 Striatal specific:nonspecific ratios in patients with vascular parkinsonism (12) and healthy volunteers (6).

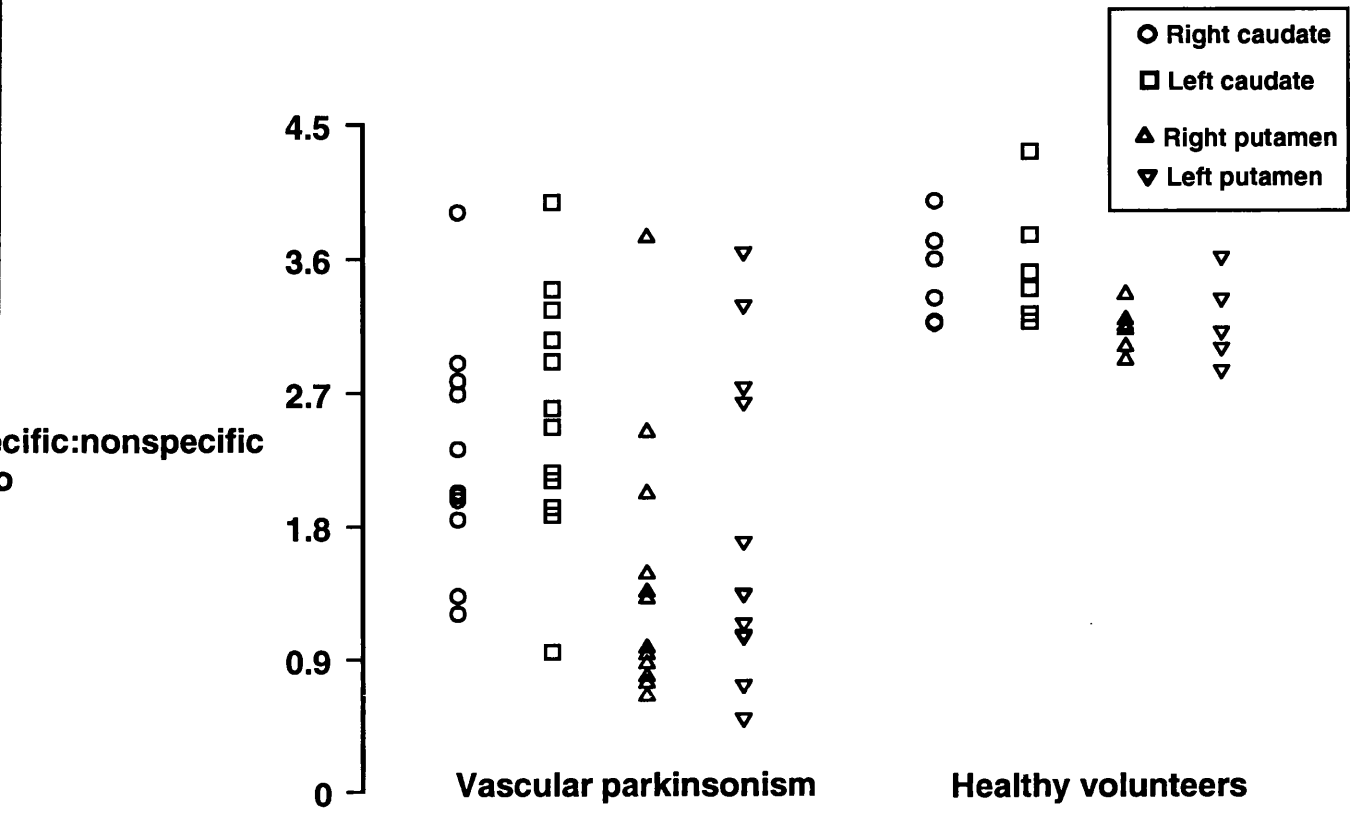
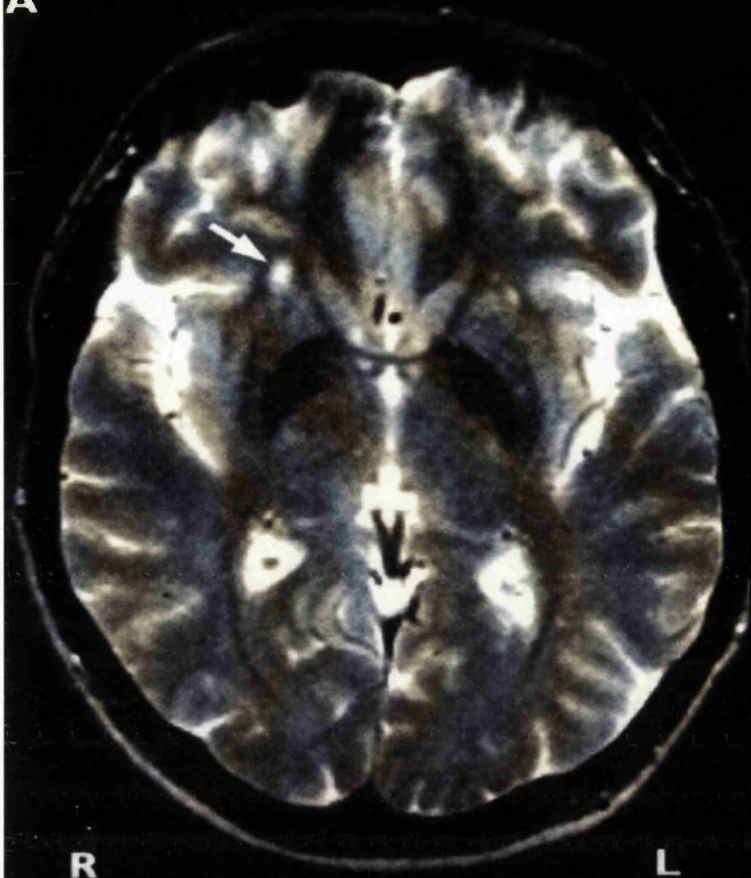


Figure 7.5: A) T2-weighted MRI, 6 months after acute onset of left arm tremor, shows an ischaemic lesion in anterolateral aspect of the right putamen (arrow).
B) Repeat MRI at 30 months shows no change (arrow).

A



B

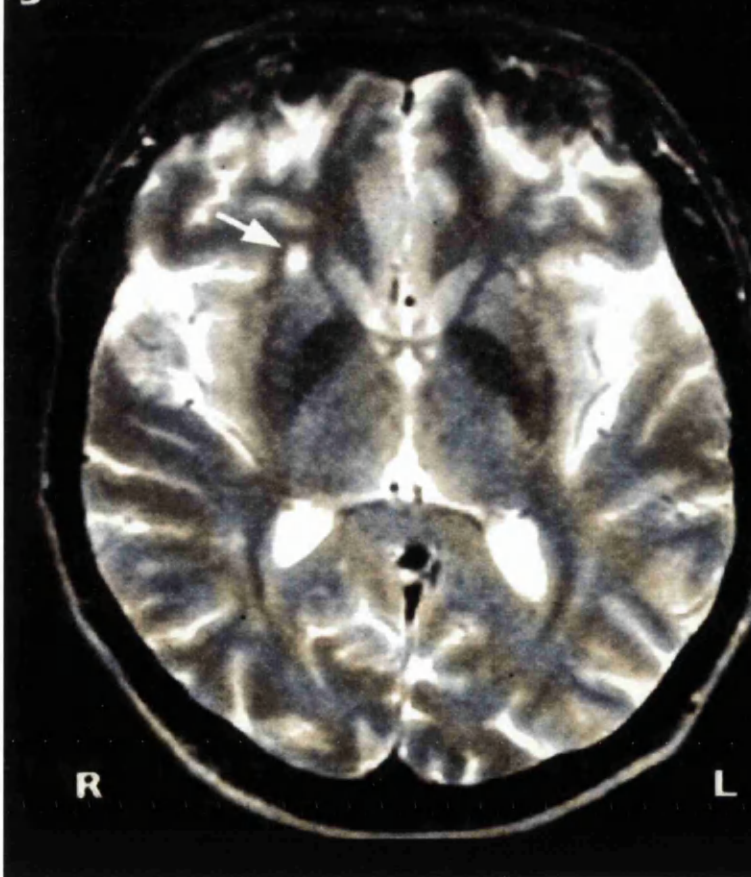
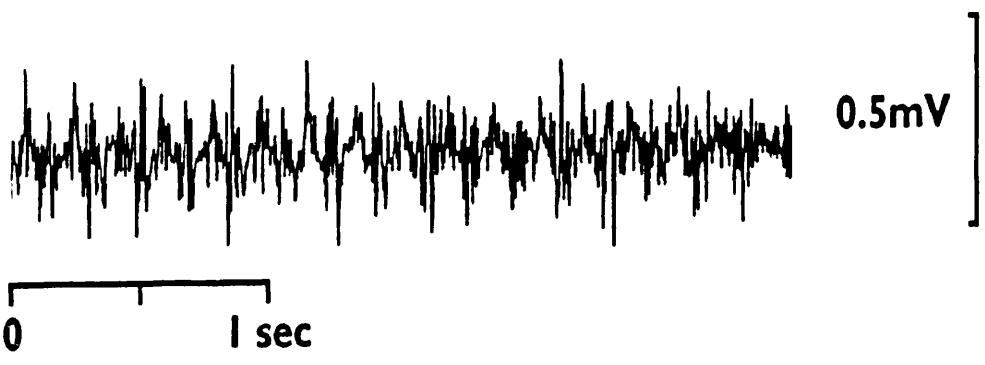


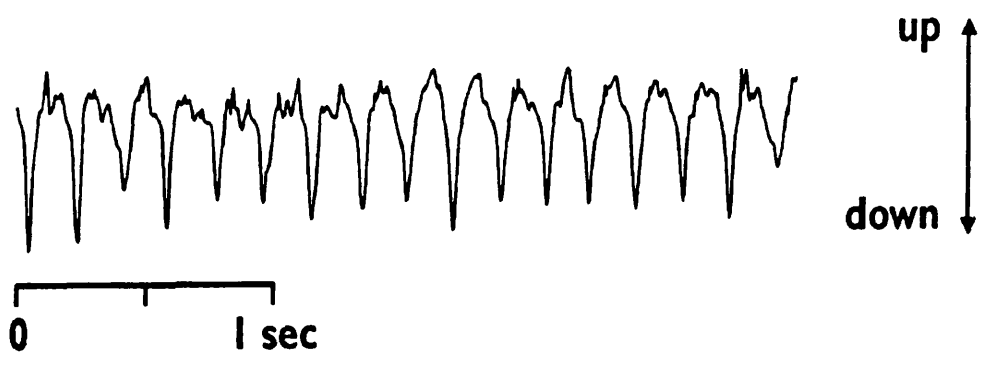
Figure 7.6: A) Surface recording EMG from left extensor digitorum communis which shows a regular 5-6 Hz tremor with arm out-stretched.

B) Simultaneous accelerometer recording from the left middle finger also demonstrating 5-6 Hz tremor.

A



B



7.4 DISCUSSION

The principal finding in the present study is of an abnormality in the dopaminergic neurones in patients with parkinsonism and vascular risk factors. This result, together with previous clinical, postmortem and structural imaging studies in such patients (Hughes et al 1990, Zijlmans et al 1995, Winikates and Jankovic 1999), indicates a basal ganglia origin for the clinical parkinsonian features in such cases and suggests that the label “pseudoparkinsonism” is no longer appropriate. Cerebrovascular parkinsonism should therefore be regarded as a parkinson’s variant, which may have clinical features distinguishing it from iPD, and which is typified (like other parkinsonian variants such as MSA and PSP) by a limited levodopa response.

Given the variability of cerebrovascular disease reported in the literature in association with parkinsonism and iPD itself, it is appropriate to review clinical and imaging data in the cases studied. Cases 1 and 2 presented with generally accepted features of VP (difficulty in gait initiation, older age, hypertension, short duration of disease, lower more than upper body features, symmetrical disease and poor response to levodopa) making iPD very unlikely (Winikates and Jonkovic 1999). It is interesting that both of these patients have a short duration of illness (less than 18 months) and mild to moderate disease severity (UPDRS 22 and 9 respectively) but ^{123}I -FP-CIT uptake was severely reduced (both grade 2 in the visual assessment with low SP:NS ratios) indicating severe degeneration in the dopaminergic terminals. In study 2 (Chapter 5) it has been shown that striatal ^{123}I -FP-CIT uptake correlates with disease severity and duration in iPD. The degree of loss of dopamine transporters in these two VP cases is greater than expected from their disease severity and duration by approximately 45%. Thus ischaemia may be associated with an accelerated rate of

basal ganglia degeneration than iPD leading to a more severe drop in the number of dopamine transporters.

An insidious onset of parkinsonism due to lacunar infarction producing clinical features similar in all aspects to iPD including a response to levodopa has been described, and is supported by postmortem studies (Tolosa and Santamaria 1984, Murrow et al 1990, Hughes et al 1991, 1992, Inzelberg et al 1994, Reider-Groswasser et al 1995, Mark et al 1995). Case 3 may be in such a diagnostic sub-group with an 8 year history of parkinsonism which presented with unilateral tremor and progressed to bradykinesia and rigidity, and a good response to levodopa. The possibility of co-existent iPD and cerebrovascular disease is raised. Cases 4, 8, 9 and 12, presented with similar features with exception of a poor response to levodopa. It is interesting to speculate whether the dominance of vascular over idiopathic Parkinson's disease determines the degree of levodopa response in individual cases.

Cases 5 and 10, who present with a hypokinetic-rigid syndrome and no tremor, showed a reduction in the SP:NS ratios in the right striatum but a almost normal SP:NS ratio in the left striatum. This pattern is not typical of iPD and it matches the structural changes seen on CT scan, namely right basal ganglia lacunar infarction and no ischaemic lesions in the contralateral striatum. The compatibility between structural and functional imaging indicates that this is a further type of vascular parkinsonism, easily distinguishable from lower body parkinsonism. However, the onset of parkinsonism in our patient was delayed for years after the initial clinical stroke event and this differs from other reports of patients with acute parkinsonian features within one month of the ischaemic event (Friedman et al 1986, Mayo et al

1986, Winikates and Jankovic 1999). The likely explanation is that this patient had several subclinical strokes leading eventually to the development of parkinsonism. The clinical features and the pattern of dopamine transporter loss make the diagnosis of iPD extremely unlikely. Further, a reduction in D2 IBZM uptake ratios in case 5 compatible with atypical parkinsonism and contrary to the normal or increased uptake in iPD patients was found (Schwarz et al 1993, van Royen et al 1993, Arnold et al 1994). Generally patients with VP do not respond to levodopa (FitzGerald and Jankovic 1989, Winikates and Jankovic 1999) and this is attributable to a reduction in post-synaptic dopamine receptors.

Lee et al (1993) reported a patient with a sudden onset of right hand, levodopa responsive resting tremor without other features of parkinsonism. MRI revealed a lacunar infarct at the border between the left thalamus and the internal capsule. The thalamic lesion was thought to be the cause of the tremor but the possibility of early Parkinson's disease could not be excluded. In contrast the tremor in the index case is of a higher frequency and did not respond to levodopa, and rigidity and bradykinesia are absent after 5 years follow-up, thus excluding iPD. Recently McAuley et al (1998) reported a patient with a sudden onset of right hand and arm tremor present at rest, and also present with posture and movement. The tremor was unresponsive to primidone, did not change in severity after 2 years, and was initially labelled psychogenic. However, electrophysiological studies revealed 7-8 Hz polyphasic bursts and MRI showed a small ischaemic lesion in the left lentiform nucleus. They concluded that the tremor resulted from the ischaemic lesion. The index patient has some clinical similarity to this case. However some of the tremor features in the index patient are suggestive of midbrain tremor: being present at rest and worsening with

posture and movement (Berkovic et al 1984, Hpfensperger et al 1995) but the higher frequency, lack of other neurological signs and site of the ischaemic lesion on MRI are against this. Also, her tremor frequency is in the ET range and shows a definite response to alcohol. However its presence at rest, with a sudden onset, and lack of later progression, indicates that she fails established diagnostic criteria for both iPD and for ET. Thus the index case of isolated tremor is likely to represent a manifestation of stroke. Case 6 also presented with isolated tremor with no other features of parkinsonism for more than 18 months and his CT showed an ischaemic lesion in the corresponding putamen making the diagnosis of isolated tremor due to stroke a possible explanation. However, his bilateral reduction in striatal ^{123}I -FP-CIT uptake would be compatible with a diagnosis of iPD although he did not exhibit features such as rigidity and bradykinesia to support this. The likelihood may be of co-existent iPD and cerebrovascular disease, with the ischaemic lesion in the basal ganglia accelerating the presentation of the tremor.

Only one of the 12 patients (case 11) in the vascular group, with unilateral tremor for 14 years, had normal striatal ^{123}I -FP-CIT uptake. The clinical features of the tremor, its duration and the appearance of the SPECT scan are against the diagnosis of parkinsonism. Also, it is unlikely to be ET or related to the ischaemic lesions. Case 7 presented with right sided tremor, but both structural and ^{123}I -FP-CIT imaging showed abnormalities in the right basal ganglia which cannot explain his clinical features. A long-term clinical and imaging follow-up may be the only way to clarify the nature of the tremor in these patients.

The findings in the present study of preganglionic dopamine loss in cases of cerebrovascular lesions with parkinsonian features need to be examined in light of the varying mechanisms suggested for this disorder. Ischaemic basal ganglia lesions or white matter lesions disrupting the sensorimotor integration have been suggested (Tolosa and Santamaria 1984, Mayo et al 1986, Murrow et al 1990, Reider-Groswasser et al 1995, Zijlmans et al 1995 Baloh and Vinters 1995, Baloh et al 1995). The gait disorder in Binswanger's disease was attributed to diffuse vascular lesions disrupting basal ganglia-motor cortex connections (Thompson and Marsden 1987) and Winikates and Jankovic (1999) proposed a similar mechanism for VP. Our study suggested that both of these purported mechanisms occur: in striatal infarction pre-synaptic dopamine neurones are directly affected, but these abnormalities also occur in patients without white matter changes.

We deliberately included cases with variations in vascular risk factors, structural imaging, and levodopa responsiveness in this study, because of the persisting uncertainty of an association between cerebrovascular disease and parkinsonism. Our study justifies the concept of vascular parkinsonism and shows two patterns of dopaminergic loss which differ from iPD, namely significant symmetry in cases of lower body parkinsonism, and an asymmetric loss at the site of focal infarction seen on structural imaging. Further evaluation of vascular parkinsonism with preganglionic dopamine transporter imaging to examine clinical, structural imaging, and therapy response, is justified by the present novel and significant results. Also, postmortem data would be helpful in this category of patients, to define the presence of Lewy bodies. However prior postmortem studies have already found an overlap between

Lewy bodies and cerebrovascular disease, as well as Lewy body negative vascular parkinsonism (Hughes et al 1992).

7.5 CONCLUSION

1- This study shows that striatal ^{123}I -FP-CIT uptake differentiates VP from healthy volunteers.

2- This is the first functional neuroimaging study in VP patients and supports the concept of vascular parkinsonism by showing striatal degeneration, indicating that disruption of the dopaminergic nerve terminals by vascular lesions is a possible mechanism for producing parkinsonian symptoms and signs.

3- Our study showed two patterns of dopaminergic loss in VP which differ from iPD namely a significantly symmetric pattern in cases of lower body parkinsonism, and an asymmetric loss at the site of focal infarction seen on structural imaging.

4- This exploratory study suggests heterogeneity in patients with vascular parkinsonism and justifies a larger sample to examine clinical and therapy correlates with preganglionic dopamine transporters in more detail.

REFERENCES

Abi-Dargham A, Gandelman MS, DeErausquin GA, Zea-Ponce Y, Zoghbi SS, Baldwin RM, Laruelle M, Charney DS, Hoffer PB, Neumeyer JL, Innis RB (1996). SPECT imaging of dopamine transporters in human brain with iodine-123-fluoroalkyl analogs of β -CIT.

J Nucl Med, 37:1129-1133.

Adam P, Fabre N, Guell A, Bessoles G, Roulleau J, Bes A (1983).

Cortical atrophy in Parkinson's disease: correlation between clinical and CT findings with special emphasis on prefrontal atrophy.

Am J Neuroradiol, 4:442-445.

Agamonolis DP, Greenstein JI (1979).

Ataxia-telangiectasia. Report of a case with Lewy bodies and vascular abnormalities with cerebral tissue.

J Neuropathol Exp Neurol, 38:475-489.

Amara SG, Kuhar MJ (1993).

Neurotransmitter transporters: Recent progress.

Ann Rev Neurosci, 16:73-93.

Antonini A, Leenders KL, Meier D, Oertel WH, Boesiger P, Anliker M (1993).

T2 relaxation time in patients with Parkinson's disease.

Neurology, 43:697-700.

Antonini A, Leenders KL, Vontobel P, Maguire RP, Missimer J, Psylla M, Gunther I (1997).

Complementary PET studies of striatal neuronal function in differential diagnosis between multiple system atrophy and Parkinson's disease.

Brain, 120:2187-2195.

Antonini A, Kazumata K, Feigin A, Maddel F, Dhawan V, Margouleff C, Eidelberg D (1998).

Differential diagnosis of Parkinsonism with [¹⁸F] Fluorodeoxyglucose and PET.

Mov Disord, 13:268-274.

Arnold G, Tatsch K, Oertel WH, Vogl T, Schwarz J, Kraft E, Kirsch CM (1994).

Clinical progressive supranuclear palsy: differential diagnosis by IBZM-SPECT and MRI.

J Neural Transm, 42(suppl):111-118.

Asenbaum S, Pirker W, Angelberger P, Bencsits G, Pruckmayer M, Brucke T (1998).

[¹²³I] β-CIT and SPECT in essential tremor and Parkinson's disease.

J Neural Transm, 105:1213-1228.

Association of British Neurologists (1992).

Neurological rehabilitation in the United Kingdom.

Report of a working party, London: ABN.

Bain PG (1993).

A combined clinical and neurophysiological approach to the study of patients with tremor.

J Neurol Neurosurg Psychiatry, 69:839-844.

Bain PG, Findley LJ, Thompson PD, Gresty MA, Rothwell JC, Harding AE, Marsden CD (1994).

A study of hereditary essential tremor.

Brain, 117:805-824.

Baloh RW, Vinters HV (1995).

White matter lesions and disequilibrium in older people, I: case-control comparison.

Arch Neurol, 52:970-974.

Baloh RW, Yue Q, Socotch TM, Jacobson KM (1995).

White matter lesions and disequilibrium in older people, II: clinicopathological correlation.

Arch Neurol, 52:975-981.

Bamford J, Sandercock P, Dennis M, Warlow C, Jones L, McPherson K, Vessey M, Fowler G, Molyneux A, Hughes T, Burn J, Wade D (1988).

A prospective study of acute cerebrovascular disease in the community: the Oxfordshire community stroke project 1981-1986 I. Methodology, demography and incident cases of first-ever stroke.

J Neurol Neurosurg Psychiatry, 51:1373-1380.

Becker H, Schneider E, Hacker H, Fischer PA (1979).

Cerebral atrophy in Parkinson's disease - represented in CT.

Arch Psychiatr Nervenkr 277:81-88.

Bennett DA, Beckett LA, Murray AM, Shannon KM, Goetz CG, Pilgrim DM, Evans DA (1996).

Prevalence of parkinsonian signs and associated mortality in a community population of older people.

N Engl J Med, 334:71-71.

Berkovic SF, Bladin PF (1984).

Rubral tremor: clinical features and treatment of three cases.

Clinical and Experimental Neurology, 20:119-128.

Bernheimer H, Birkmayer W, Hornykiewicz O, Jellinger K, Seitelberger F (1973).

Brain dopamine and the syndromes of Parkinson's and Huntington. Clinical, morphological and neurochemical correlations.

J Neurol Sci, 20:415-455.

Bhatia KP, Marsden CD (1994).

The behavioural and motor consequences of focal lesions of the basal ganglia in man.

Brain, 117:859-876.

Booij J, Andringa G, Rijks LJM, Vermeulen RJ, de Bruin K, Boer J, Janssen AGM, van Royen EA (1997a).

[¹²³I]FP-CIT binds to the dopamine transporter as assessed by biodistribution studies in rats and SPECT studies in MPTP-lesioned monkeys.

Synapse, 27:183-190.

Booij J, Tissingh G, Winogrodzka A, Boer GJ, Stoof JC, Wolter E Ch, van Royen EA (1997b).

Practical benefit of [¹²³I]FP-CIT SPET in the demonstration of the dopaminergic deficit in Parkinson's disease.

Eur J Nucl Med, 24:68-71.

Booij J, Tissingh G, Boer GJ, Speelman JD, Stoof JC, Janssen AGM, Wolter E Ch, van Royen EA (1997c).

[¹²³I]FP-CIT SPECT shows a pronounced decline of striatal dopamine transporter labelling in early and advanced Parkinson's disease.

J Neurol Neurosurg Psychiatry, 62:133-140.

Booij J, Habraken JBA, Bergmans P, Tissingh G, Winogrodzka A, Wolter E, Janssen AGM, Stoof JC, van Royen E (1998a).

Imaging of dopamine transporters with iodine-123-FP-CIT SPECT in healthy controls and patients with Parkinson's disease.

J Nucl Med, 39:1879-1884.

Booij J, Sokole EB, Stabin MG, Janssen AGM, de Bruin K, van Royen EA (1998b).
Human biodistribution and dosimetry of [^{123}I]FP-CIT: a potent radioligand for
imaging of dopamine transporters.

Eur J Nucl Med, 25:24-30.

Booij J, Hemelaar TGM, Speelman JD, de Bruin K, Janssen AGM, van Royen EA
(1999).

One-day protocol for imaging of the nigrostriatal dopaminergic pathway in
Parkinson's disease by [^{123}I]FP-CIT SPECT.

J Nucl Med, 40:753-761.

Braffman BH, Grossman RI, Goldberg HI, Stern MB, Hurtig HI, Hackney DB,
Bilaniuk LT, Zimmerman RA (1988).

MR imaging of Parkinson disease with spin-echo and gradient-echo sequences.

Am J Roentgenol, 9:1093-1099.

Britton TC (1995).

Essential tremor and its variants.

Current Opinion in Neurology, 8:314-319.

Brooks DJ, Ibanez V, Sawle GV, Quinn N, Lees AJ, Mathias CJ, Bannister R,
Marsden CD, Frackowiak SJ (1990).

Differing patterns of striatal ^{18}F -dopa uptake in Parkinson's disease, multiple system
atrophy, and progressive supranuclear palsy.

Ann Neurol, 28:547-555.

Brooks DJ, Ibanez V, Sawle GV, Playford ED, Quinn N, Mathias CJ, Lees AJ, Marsden CD, Bannister R, Frackowiak SJ (1992a).

Striatal D2 receptors status in patients with Parkinson's disease, striatonigral degeneration, and progressive supranuclear palsy, measured with ^{11}C -raclopride and positron emission tomography.

Ann Neurol, 31:184-192.

Brooks DJ, Playford ED, Ibanez V, Sawle GV, Thompson PD, Findley LJ, Marsden CD (1992b).

Isolated tremor and disruption of the nigrostriatal dopaminergic system: An ^{18}F -dopa PET study.

Neurology, 42:1554-1560.

Brooks DJ (1993).

Functional imaging in relation to parkinsonian syndromes.

J Neurol Sci, 115:1-17.

Brown J, Lantos P, Stratton M, Rogues P, Rossor M (1993).

Familial progressive supranuclear palsy.

J Neurol Neurosurg Psychiatry, 56:473-476.

Brucke T, Asenbaum S, Pirker W, Djamshidian S, Wenger S, Wober Ch, Muller Ch, Podreka I (1997).

Measurement of the dopaminergic degeneration in Parkinson's disease with [¹²³I]β-CIT and SPECT. Correlation with clinical findings and comparison with multiple system atrophy and progressive supranuclear palsy.

J Neurol Transm, (suppl 50) 9-24.

Burn DJ, Sawle GV, Brooks DJ (1994).

Differential diagnosis of Parkinson's disease, multiple system atrophy, and Steele-Richardson-Olszewski syndrome: discriminant analysis of striatal ¹⁸F-dopa PET data.

J Neurol Neurosurg Psychiatry, 57:287-284.

Busenbark KL, Nash J, Nash S, Hubble JP, Koller WC (1991).

Is essential tremor benign?

Neurology, 41:1982-1983.

Busenbark K, Barnes P, Lyons K, Ince D, Villagra F, Koller WC (1996).

Accuracy of reported family histories of essential tremor.

Neurology, 47:264-265.

Chang CM, Yu YL, Leung SY, Fong KY (1992).

Vascular pseudoparkinsonism.

Acta Neurol Scand, 86:588-592.

Cleeves L, Findley L, Koller W (1998).

Lack of association between essential tremor and Parkinson's disease.

Ann Neurol, 24:23-26.

Collins SJ, Ahlskog JE, Parisi JE, Maraganore DM (1995a).

Progressive Supranuclear Palsy: neuropathologically based diagnostic clinical criteria.

J Neurol Neurosurg Psychiatry, 58:167-173.

Collins L, Holmes C, Peters TM, Evans C (1995b).

Automatic 3D model-based neuroanatomical segmentation.

Human Brain Mapping, 3;190-208.

Critchley E (1972).

Clinical manifestations of essential tremor.

J Neurol Neurosurg Psychiatry, 35:365-372.

Critchley M (1929).

Arteriosclerotic Parkinsonism.

Brain, 1929;52:23-83.

Critchley M (1949).

Observations on essential (Heredofamilial) tremor.

Brain, 72:113-139.

Critchley M (1981).

Arteriosclerotic pseudo-parkinsonism.

In Rose C, Capildeo R (Eds) Research progress in Parkinson's disease. London:
Pitman Medical, 40-42.

D'Costa DF, Abbott RJ, Pye IF, Millac PAH (1991).

The apomorphine test in Parkinsonian syndromes.

J Neurol Neurosurg Psychiatry, 54:870-872.

De Bruin VM, Lees AJ (1994).

Subcortical neurofibrillary degeneration presenting as Steele-Richardson-Olsewski
and other related syndromes: A review of 90 pathological verified cases.

Mov Disord, 9:381-389.

De Keyser J, De Baecker JP, Ebinger G, Vauquelin (1989).

G3H GBR 12935 binding to dopamine transporters in the human brain.

J Neurochem, 53:1400-1404.

Dethy S, Luxen A, Bidaut LM, Goldman S (1993).

Hemibody tremor related to stroke.

Stroke, 24:2094-2096.

Deuschl G, Bain P, Brin M, Ad Hoc Scientific Committee (1998a).

Consensus statement of the Movement Disorder Society on tremor.

Mov Disord, 13(suppl 3)2-23.

Deuschl G, Krack P (1998b).

Tremors: Differential diagnosis, neurophysiology, and pharmacology.

In: Jankovic J, Tolosa E (Eds). Parkinson's Disease and Movement Disorders.

Williams & Wilkins.

De Volder AG, Francart J, Latterre C, Doods G, Bol A, Michel C, Goffinet AM (1989).

Decreased glucose utilization in the striatum and frontal lobe in probable striatonigral degeneration.

Ann Neurol, 26:239-247.

de Yebenes JG, Sarasa JL, Daniel SE, Lees AJ (1995).

Familial progressive supranuclear palsy: Description of a pedigree and review of the literature.

Brain, 118:1095-1103.

Drayer P, Olanow W, Burger P, Johnson GA, Herfkens R, Riederer S (1986).

Parkinson plus syndrome: Diagnosis using high field MR imaging of brain iron.

Radiology, 159:493-498.

Duguid JR, De La Paz R, DeGroot J (1986).

Magnetic resonance imaging of the midbrain in Parkinson's disease.

Ann Neurol, 20:744-747.

Duvoisin RC, Golbe LI, Lepore FE (1987).

Progressive Supranuclear Palsy.

Can J Neuro Sci, 14:547-554.

Eadie MJ, Sutherland JM (1964).

Arteriosclerosis in Parkinsonism.

J Neurol Neurosurg Psychiatry, 27:237-240.

Eidelberg D, Takikawa S, Moeller R, Dhawan V, Redington K, Chaly T, Robeson W,

Dahl JR, Margouleff D, Fazzini E, Przedborski S, Fahn S (1993).

Striatal hypometabolism distinguishes striatonigral degeneration from Parkinson's disease.

Ann Neurol, 33:518-527.

Fahn S, Elton R, and Members of the UPDRS development committee (1987).

Unified Parkinson's disease rating scale.

In: Fahn S, Marsden CD, Calne DB, Goldstein M (Eds). Recent developments in Parkinson's disease. New York: Macmillan.

Fearnley JM, Lees AJ.

Aging and Parkinson's disease: substantia nigra regional selectivity (1991).

Brain, 114:2283-2301.

Ferbert A, Gerwig M (1993).

Tremor due to stroke.

Mov Disord, 8:179-182.

Findley LJ, Koller WC (1995).

Definitions and behavioural classifications.

In: Findley and Koller (Eds). Handbook of tremor disorders. New York: Marcel Dekker, 1-5.

Findley LJ (1996).

Classification of tremors.

J Clinical Neurophysiol, 13:122-132.

Forno LS (1969).

Concentric hyalin intraneural inclusions of Lewy type in the brains of elderly persons (50 incidental cases). Relationship to Parkinsonism.

J Am Geriatric Soc, 17:557-75.

Friedman A, Kang UJ, Tatemichi TK, Burke R (1986).

A case of parkinsonism following striatal lacunar infarction (Letter).

J Neurol Neurosurg Psychiatry, 49:1087-1088.

Frost JJ, Rosier AJ, Reich SG, Smith JS, Ehlers MD, Snyder BS, Ravert HT, Dannals RF (1993).

Positron emission tomographic imaging of the dopamine transporter with ¹¹C-WIN35,428 reveals marked decline in mild Parkinson's disease.

Ann Neurol, 34:423-431.

FitzGerald PM, Jankovic J (1989).

Lower Body Parkinsonism: Evidence for vascular etiology.

Mov Disord, 4:249-260.

Garnett ES, Nahmias C, Firnau G (1984).

Central dopaminergic pathways in hemiparkinsonism examined by positron emission tomography.

Can J Neurol Sci, 11:174-179.

Gasser T, Schwarz J, Arnold G, Trenkwalder C, Oertel WH (1992).

Apomorphine test for dopaminergic responsiveness in patients with previously untreated Parkinson's disease.

Arch Neurol, 49:1131-1134.

Geraghty JJ, Jankovic J, Zetuský WJ (1985).

Association between essential tremor and Parkinson's disease.

Ann Neurol, 17:329-333.

German DC, Manaye K, Smith WK, Woodward DJ, Saper CB (1989).

Midbrain dopaminergic cell loss in Parkinson's disease: computer visualisation.

Ann Neurol, 26:507-514.

Ghika-Schmid F, Regli F, Bogousslavsky J (1997).

Hyperkinetic movement disorders during and after acute stroke: The Lausanne stroke registry.

J Neurol Sci, 146:109-116.

Gibb WRG, Esiri MM, Lees AJ (1985).

Clinical and pathological features of diffuse Lewy body dementia.

Brain, 110:1131-1153.

Gibb WRG, Lees AJ (1988).

The relevance of the Lewy body to the pathogenesis of idiopathic Parkinson's disease.

J Neurol Neurosurg Psychiatry, 51:745-752.

Gibb WRG (1988).

The Lewy body in autonomic failure.

In Bannister R (Ed): Autonomic failure; Oxford University Press, 484-497.

Gibb WRG (1989a).

Neuropathology in movement disorders.

J Neurol Neurosurg Psychiatry, (special suppl) 55-67.

Gibb WRG, Mountjoy CQ, Mann DMA, Lees AJ (1989b).

A pathological study of the association between Lewy body disease and Alzheimer's disease.

J Neurol Neurosurg Psychiatry, 52:701-708.

Gibb WRG, Scaravilli F, Michand J (1990a).

Lewy body and subacute sclerosing panencephalitis.

J Neurol Neurosurg Psychiatry, 52:710-711.

Gibb WRG, Fearnley JM, Lees AJ (1990b).

The anatomy and pigmentation of the human substantia nigra in relation to selective neuronal vulnerability.

Adv Neurol, 53:31-34.

Golbe LI, Davis PH, Schoenberg BS, Dr PH, Duvoisin RC (1988).

Prevalence and natural history of progressive supranuclear palsy.

Neurology, 38:1031-1034.

Gomori AJ, Sima AAF (1984).

An atypical case of progressive supranuclear palsy.

Can J Neurol Sci, 11:48-52.

Goto S, Hirano A, Matsumoto S (1989).

Subdivisional involvement of nigrostriatal loop in idiopathic Parkinson's disease and striatonigral degeneration.

Ann Neurol, 26:766-770.

Gowers WR (1907).

Manual of diseases of the nervous system.

Philadelphia, Blakiston, 608.

Graham JG, Oppenheimer DR (1969).

Orthostatic hypotension and nicotine sensitivity in a case of multiple system atrophy.

J Neurol Neurosurg Psychiatry, 32:28-34.

Guttman M, Burkholder J, Kish SJ, Hussey D, Wilson A, DaSilva J, Houle S (1997).

[¹¹C] RTI-32 PET studies of the dopamine transporter in early dopa-naive Parkinson's disease: implications for symptomatic threshold.

Neurology, 48:1578-1583.

Hauw JJ, Daniel SE, Dickson D, Horoupian DS, Jellinger K, Lantos PL, McKee A, Tabaton M, Litvan I (1994).

Preliminary NINDS neuropathologic criteria for Steele-Richardson-Olszewski Syndrome (Progressive Supranuclear Palsy).

Neurology, 44:2015-2019.

Hoehn M, Yahr D (1967).

Parkinsonism: onset, progression, and mortality.

Neurology, 17:427-442.

Hpfensperger HJ, Busenbark K, Koller WC (1995).

Midbrain tremor.

In: Findley LJ, Koller WC (Eds). Handbook of tremor disorders. New York: Marcel

Dekker Inc, 455-459.

Huber SJ, Chakeres DW, Paulson GW, Khanna R (1990).

Magnetic resonance imaging in Parkinson's disease.

Arch Neurol, 47:735-737.

Hughes AJ, Lees AJ, Stern GM (1990).

Apomorphine test to predict dopaminergic responsiveness in parkinsonian syndromes.

Lancet, 336:32-34.

Hughes AJ, Lees AJ, Stern GM (1991)

Challenge tests to predict dopaminergic response in untreated Parkinson's disease.

Neurology, 41:1723-1725.

Hughes AJ, Daniel SE, Kilford L, Lees AJ (1992).

Accuracy of clinical diagnosis of idiopathic Parkinson's disease: a clinico-pathological study of 100 cases.

J Neurol Neurosurg Psychiatry, 55:181-184.

Hughes AJ, Daniel SE, Blankson S, Lees AJ (1993).

A clinico-pathological study of 100 cases of Parkinson's disease.

Arch Neurol, 50:140-148.

Ilgin N, Zubieta J, Reich SG, Dannals RF, Ravert HT, Frost JJ (1999).

PET imaging of the dopamine transporter in progressive supranuclear palsy and Parkinson's disease.

Neurology, 52:1221-1226.

Innis RB, Marek KL, Sheff K, Zoghbi S, Castronuovo J, Feigin A, Seibyl JP (1999).

Effect of treatment with L-dopa/Carbidopa or selegiline on striatal dopamine transporter SPECT imaging with [¹²³I]-β-CIT.

Mov Disord, 14:436-442.

Inznelberg R, Bornstein NM, Reider I, Korczyn AD (1994).

Basal ganglia lacunes and parkinsonism.

Neuroepidemiology, 13:108-112.

Ishikawa T, Dhawan V, Kazumata K, Chaly T, Mandel F, Neumeyer J, Margouleff C,

Babchuck B, Zanzi I, Eidelberg D (1996).

Comparative nigrostriatal dopaminergic imaging with iodine-123-βCIT-FP/SPECT and fluorine-18-FDOPA/PET.

J Nucl Med, 37:1760-1765.

Ito Y, Fujita M, Shimada S, Watanabe Y, Okada T, Kusuoka H, Tohyama M, Nishimura T (1999).

Comparison between the decrease of dopamine transporter and that of L-dopa uptake for detection of early to advanced stage of Parkinson's disease in animal models. Synapse, 31:178-185.

Jaber M, Jones S, Giros B, Caron MG (1997).

The dopamine transporter: A crucial component regulating dopamine transmission. Mov Disord, 12:629-633.

Jankovic J (1984).

Progressive supranuclear palsy.

Neurol Clinics, 2:473-486.

Jankovic J, Beach J, Schwartz K, Contant C (1995).

Tremor and longevity in relatives of patients with Parkinson's disease, essential tremor, and control subjects.

Neurology, 45:645-648.

Javoy-Agid F, Ruberg M, Hirsh E, Cash R et al, Raisman, Taquet H, Epelbaum J, Scatton B, Duyckaerts C, Agid Y (1986).

Recent progress in the neurochemistry of Parkinson's disease.

In: Fahn S, Marsden CD, Jenner P, Teychenne P (Eds). Recent developments in Parkinson's disease. New York: Raven Press, 67-83.

Jellinger K, Riederer P, Tomonaga M (1980).

Progressive supranuclear palsy: clinico-pathological and biochemical studies.

J Neural Transm, 16 (suppl):111-128.

Kaufman MJ, Madras BK (1991).

Severe depletion of cocaine recognition sites associated with the dopamine transporter in Parkinson's disease striatum.

Synapse, 9:43-49.

Kim JS (1992).

Delayed onset hand tremor caused by cerebral infarction.

Stroke 23:292-294.

Kim JS, Lee MC (1994).

Writing tremor after discrete cortical infarction.

Stroke, 25:2280-2282.

Kish SJ, Chang LJ, Mirchandani L, Shannak K, Hornykiewicz O (1985).

Progressive supranuclear palsy: relationship between extrapyramidal disturbances, dementia, and brain neurotransmitter markers.

Ann Neurol, 18:530-536.

Koller WC (1983).

Alcoholism in essential tremor.

Neurology, 33:1074-1076.

Koller WC, Biary N (1984).

Effect of alcohol on tremors: Comparison with propranolol.

Neurology, 34:221-222.

Koller WC (1984).

The diagnosis of Parkinson's disease.

Arch Intern Med, 33:1074-1076.

Koller W, Biary N, Cone S (1986).

Disability in essential tremor: effect of treatment.

Neurology, 36:1001-1004.

Koller WC (1992).

When does Parkinson's disease begin?

Neurology, 42 (suppl 4):27-31.

Koller WC, Busenbark K, Miner K, and the essential tremor study group (1994).

The relationship of essential tremor to other movement disorders: Report on 678 patients.

Ann Neurol, 35:717-723.

Lang A, Quinn N, Marsden CD, Findley L, Koller W, Brin M, Fahn S (1992).

Essential tremor.

Neurology, (letter) 42:1432-1433.

Larsen TA, Calne DB (1983).

Essential tremor.

Clin Neuropharmacol, 6:185-206.

Laruelle M, Bladwin RM, Malison RT, Zea-Pone Y, Zoghbi SS, al-Tirriti MS, Sybirska EH, Zimmermann RC, Wisniewski G, Neumeier JL, et al (1993).

SPECT imaging of dopamine and serotonin transporters with [¹²³I] β-CIT: pharmacological characterisation of brain uptake in nonhuman primates.

Synapses, 13:295-309.

Laruelle M, Wallace E, Seibyl JP, Bladwin RM, Zea-Ponce Y, Zoghbi SS, Neumeier JL, Charney DS, Hoffer PB, Innis RB (1994).

Graphical, kinetic, and equilibrium analyses of the in vivo [¹²³I] β-CIT binding to dopamine transporters in healthy human subjects.

J Cereb Blood Flow Metab, 14:982-994.

Lee CS, Schulzer M, Mak E, Hammerstad JP, Calne S, Calne DB (1995).

Patterns of asymmetry do not change over the course of idiopathic parkinsonism.

Neurology, 45:435-439.

Lee MS, Lee SA, Heo JH, Choi IS (1993).

A patient with a resting tremor and a lacunar infarction at the border between the thalamus and the internal capsule.

Mov Disord, 8:244-246.

Lee MS, Marsden CD (1994).

Movement disorders following lesions of thalamus or subthalamic region.

Mov Disord, 9:439-507.

Lee MS, Kim YD, Im JH, Kim HJ, Rinne JO, Bhatia KP (1999).

¹²³I-IPT brain SPECT study in essential tremor and Parkinson's disease.

Neurology, 52:1422:1426.

Lees AJ (1987).

The Steele-Richardson-Olszewski Syndrome (progressive supranuclear palsy).

In Marsden CD and Fahn S (Eds). Movement disorders 2. Butterworths, 272-284.

Leenders KL, Palmer AJ, Quinn N, Clark JC, Firnau G, Garnett ES, Nahmias C, Jones T, Marsden CD (1986).

Brain dopamine metabolism in patients with Parkinson's disease measured with positron emission tomography.

J Neurol Neurosurg Psychiatry, 49:853-860.

Leenders KL, Salmon EP, Tyrrell P, Perani D, Brooks DJ, Sager H, Jones T, Marsden CD, Frackowiak RSJ (1990).

The nigrostriatal dopaminergic system assessed in vivo by positron emission tomography in healthy volunteer subjects and patients with Parkinson's disease.

Arch Neurol, 47:1290-1298.

Levine RL, Jones JC, Bee N (1992).

Stroke and Parkinson's disease.

Stroke 23:839-842.

Litvan I, Mangone CA, Mckee A, Verny M, Parsa A, Jellinger K, D'Olhaberriague L, Chaudhuri KR, Pearce RKB (1996a).

Natural history of progressive supranuclear palsy (Steele-Richardson-Olszewski Syndrome) and clinical predictors of survival: a clinicopathological study.

J Neurol Neurosurg Psychiatry, 61:615-620.

Litvan I, Agid Y, Calne D, Campbell G, Dubois B, Duvoisin RC, Goetz CG, Golbe LI, Grafman J, Growdon JH, Hallett M, Jankovic J, Quinn NP, Tolosa E, Zee DS (1996b).

Clinical research criteria for the diagnosis of progressive supranuclear palsy (Steele-Richardson-Olszewski syndrome): Report of the NINDS-SPSP international workshop. Neurology, 47:1-9.

Litvan I, Goetz CG, Jankovic J, Wenning GK, Booth V, Bartko JJ, McKee A, Jellinger K, Lai EC, Brandel JP, Verny M, Chaudhuri R, Pearce KB, Agid Y (1997).

What is the accuracy of the clinical diagnosis of multiple system atrophy? A clinicopathologic study.

Arch Neurol, 54:937-944.

Lou J, Jankovic J (1991).

Essential tremor: clinical correlates in 350 patients.

Neurology, 41:234-238.

Louis ED, Ottman R (1996).

How familial is familial tremor? The genetic epidemiology of essential tremor.

Neurology, 46:1200-1205.

Louis ED, Ottman R, Hauser WA (1998).

How common is the most common adult movement disorders? Estimates of the prevalence of essential tremor throughout the world.

Mov Disord, 13:5-10.

Marek KL, Seibyl JP, Zoghbi SS, Zea-Ponce Y, Bladwin RM, Fussell RN, Charney DS, van Dyck C, Hoffer PB, Innis RB (1996).

[¹²³I] β-CIT/SPECT imaging demonstrates bilateral loss of dopamine transporters in hemi-Parkinson's disease.

Neurology, 46:231-237.

Mark MH, Sage JI, Walters AS, Duvoisin RC, Miller DC (1995).

Binswanger's disease presenting as levodopa-responsive parkinsonism: clinicopathologic study of three cases.

Mov Disord, 10:450-454.

Marsden CD (1994).

Parkinson's disease.

J Neurol Neurosurg Psychiatry, 57:672-681.

Marshall J (1962).

Observations on essential tremor.

J Neurol Neurosurg Psychiatry, 5:122-125.

Martinelli P, Gabellini AS, Gulli MR, Lugaresi E (1987).

Different clinical features of essential tremor: a 200-patients study.

Acta Neurol Scand, 75:106-111.

Marttila RJ, Rinne UK (1976a).

Epidemiology of Parkinson's disease in Finland.

Acta Neurol Scand, 53:81-102.

Marttila RJ, Rinne UK (1976b).

Arteriosclerosis, heredity, and some other previous infections in etiology of Parkinson's disease: A case control study.

Clin Neurol Neurosurg, 79:46-56.

Marttila RJ, Rautakorpi IL, Rinne UK (1984).

The relation of essential tremor to Parkinson's disease.

J Neurol Neurosurg Psychiatry, 47:734-735.

Matsui T, Hirano A (1978).

An atlas of the human brain for computed tomography.

Gustav Fischer Verlag: Stuttgart.

Mayo J, Arias M, Leno C, Berciano J (1986).

Vascular parkinsonism and periarthritis nodosa (Letter).

Neurology, 36:874.

Mazziotta JC, Toga AW, Evans A, Fox P, Lancaster J (1995).

A probabilistic atlas of the human brain: theory and rationale for its development. The International Consortium for Brain Mapping (ICBM).

Neuroimage, 2:89-101

McAuley JH, Rothwell JC, Marsden CD, Findley LJ (1998).

Electrophysiological aids in distinguishing organic from psychogenic tremor.

Neurology, 50:1882-1884.

Messa C, Volonte MA, Fazio F, Zito F, Carpinelli A, d'Amico A, Rizzo G, Moresco RM, Paulesu E, Franceschi M, Lucignani G (1998).

Differential distribution of striatal [¹²³I] β-CIT in Parkinson's disease and progressive supranuclear palsy, evaluated with single-photon emission tomography.

Eur J Nucl Med, 25:1270-1276.

Morrish PK, Sawle GV, Brooks DJ (1995).

Clinical and [¹⁸F]dopa PET findings in early Parkinson's disease.

J Neurol Neurosurg Psychiatry, 59:597-600.

Morrish PK, Sawle GV, Brooks DJ (1996).

An [¹⁸F] dopa-PET and clinical study of the rate of progression in Parkinson's disease.

Brain, 119:585-591.

Morrish PK, Sawle GV, Brooks DJ (1998).

Measuring the rate of progression and estimating the preclinical period of Parkinson's disease with [¹⁸F] dopa PET.

J Neurol Neurosurg Psychiatry, 64:314-319.

Mutch WJ, Dingwell-Fordyce I, Downie AW, Paterson JG, Roy SK. (1986)

Parkinson's Disease in a Scottish city.

British Med J, 292:534-536.

Murrow RW, Schweiger GD, Kepes JJ, Koller WC (1990).

Parkinsonism due to a basal ganglia lacunar state: Clinicopathologic correlation.

Neurology, 40:897-900.

Nagatsus T, Kato T, Nagatsu I, Kondo Y, Inagaki S, Lizuka R, Naretabayashi H
(1979)

Catecholamine-related enzymes in the brain of patients with parkinsonism and
Wilson's disease.

Adv Neurol, 24:283-292.

Nahmias C, Garnett S, Firnau G, Lang A (1985).

Striatal dopamine distribution in parkinsonian patients during life.

J Neurol Sci, 69:223-230

Niznik HB, Fogel EF, Fassos FF, Seeman P (1991).

The dopamine transporter is absent in parkinsonian putamen and reduced in caudate
nucleus.

J Neurochem, 56:192-198.

Oertel W, Quinn N (1996).

Movement disorders.

In Brandt T, Caplan LR, Dichgans J, Diener HC, and Kennard C (Eds). Neurological
disorders course and treatment. Academic Press, 64:715-772.

Olanow CW, Brayer B (1987).

Brain iron: MRI studies in parkinson syndroms.

In Fahn S, Marsden D, Calne D (Eds). Recent developments in Parkinson's disease.

Macmillan 135-143.

Olanow CW (1992).

Magnetic resonance imaging in parkinsonism.

Neurology clinics, 2:405-420.

Otsuka M, Ichiya Y, Hosokawa S, Kumabara Y, Sasaki M, Tahara T, Fukumura M,

Kato M, Masuda K, Goto I (1991).

Striatal blood flow, glucose metabolism and ^{18}F -dopa uptake: difference in Parkinson's disease and atypical parkinsonism.

J Neurol Neurosurg Psychiatry, 54:898-904.

Otsuka M, Ichiya Y, Kumabara Y, Hosokawa S, Sasaki M, Yoshida T, Fukumura T,

Kato M, Masuda K (1996).

Glucose metabolism in the cortical and subcortical brain structures in multiple system atrophy and Parkinson's disease: a positron emission tomographic study.

J Neurol Sci, 144:77-83.

Otsuka M, Kumabara Y, Ichiya Y, Hosokawa S, Sasaki M, Yoshida T, Fukumura T,

Kato M, Masuda K (1997).

Differentiating between multiple system atrophy and Parkinson's disease by positron emission tomography with ^{18}F -dopa and ^{18}F -FDG.

Ann Nucl Med, 3:251-257.

Parkes JD, Marsden CD, Rees JE, Curzon G, Kantamaneni BD, Knill-Jones R, Akbar A, Das S, Kataria M (1974).

Parkinson's disease, cerebral arteriosclerosis, and senile dementia.

Quarterly J Med, 169:49-61.

Parkinson J (1817).

An Essay on the Shaking palsy.

London Sherwood, Neely, and Jones.

Pastakia B, Polinsky R, Di Chiro G, Simmons T, Brown R, Wener L (1986).

Multiple system atrophy (Shy-Drager syndrome): MR imaging.

Radiology, 159:499-502.

Pearce JMS (1989).

Aspects of the history of Parkinson's disease.

J Neurol Neurosurg Psychiatry, (special suppl) 6-10.

Quinn N (1994).

Multiple system atrophy.

In Marsden CD and Fahn S (Eds) Movement disorders 3. Butterworths, 262-281.

Quinn N (1995).

Parkinsonism - recognition and differential diagnosis.

British Med J, 310:447-452.

Qureshi F, Morales A, Elble RJ (1996).

Tremor due to infarction in the ventrolateral thalamus.

Mov Disord, 11:440-444.

Rajput AH, Jamieson H, Hirsh S, Quraishi A (1975).

Relative efficacy of alcohol and propranolol in action tremor.

Can J Neurol Sci, 2:31-35.

Rajput AH, Offord KP, Beard MC, Kurland LT, Dr PH (1984a).

Epidemiology of Parkinsonism: Incidence, classification, and mortality.

Ann Neurol, 16:278-282.

Rajput AH, Offord KP, Beard CM, Kurland LT (1984b).

Essential tremor in Rochester, Minnesota: a 45-year study.

J Neurol Neurosurg Psychiatry, 47:466-470.

Rajput AH, Rozdilsky B, Rajput A (1991a).

Accuracy of clinical diagnosis in parkinsonism - A prospective study.

Can J Neurol Sci, 18:275-278.

Rajput AH, Rozdilsky B, Ang L, Rajput A (1991b).

Clinicopathologic observations in essential tremor.

Neurology, 41:1422-1424.

Rautakorpi I, Takala J, Marttila RJ, Sievers K, Rinne UK (1982).

Essential tremor in a Finnish population.

Acta Neurol Scand, 66:58-67.

Reider-Groswasser I, Bornstein NM, Korczyn AD (1995).

Parkinsonism in patients with lacunar infarcts of the basal ganglia.

Eur Neurol, 35:46-49.

Richards M, Stern Y, Mayeux R (1993).

Subtle extrapyramidal signs can predict the development of dementia in elderly individuals.

Neurology, 43:2184-2188.

Rinne JO, Laihinen A, Rinne UK, Nagren K, Bergman J, Ruotsalainen U (1993).

PET study on striatal dopamine D2 receptor changes during the progression of early Parkinson's disease.

Mov Disord, 8:134-138.

Rinne JO, Laihinen A, Ruottinen H, Ruotsalainen U, Nagren K, Lehtonen P, Oikonen V, Rinne UK (1995).

Increased density of dopamine D2 receptors in the putamen, but not in the caudate nucleus in early Parkinson's disease: a PET study with [¹¹C] raclopride.

J Neurol Sci, 132:156-161.

Rudnick G, Clark J (1993).

From synapse to vesicle: the reuptake and storage of biogenic amine neurotransmitters.

Biochim Biophys Acta, 1144:249-263.

Rutledge JN, Hilal SK, Silver AJ, Defendini R, Fahn S (1987).

Study of movement disorders and brain iron by MR.

Am J Neuroradiol, 8:397-411.

Ryvlin P, Broussolle E, Piollet H, Viallet F, Khalfallah Y, Chazot G (1995).

Magnetic resonance imaging evidence of decreased putamenal iron content in idiopathic Parkinson's disease.

Arch Neurol, 52:583-588.

Salemi G, Savettieri G, Rocca WA, Meneghini F, Saporito V, Morgante L, Reggio A, Grigoletto F, Di Perri R, for the Sicilian Neuro-Epidemiologic study group (1994).

Prevalence of essential tremor: A door-to-door survey in Terrasini, Sicily.

Neurology, 44:61-64.

Schonfeld SM, Golbe LI, Sage JI, Safer JN, Duvoisin RC (1987).

Computed tomographic finding in progressive supranuclear palsy: correlation with clinical grade.

Mov Disord, 2: 263-278.

Schrag A, Kingsley D, Phatouros C, Mathias CJ, Lees AJ, Daniel SE, Quinn NP (1998).

Clinical usefulness of magnetic resonance imaging in multiple system atrophy.

J Neurol Neurosurg Psychiatry, 65:71.

Schroeder D, Nasrallah H (1982).

High alcoholism rate in patients with essential tremor.

Am J Psychiatry, 139:1471-1473.

Schulze-Bonhage A, Ferbert A (1998).

Cortical action tremor and focal motor seizures after parietal infarction.

Mov Disord, 13:356-358.

Schwarz J, Tatsch K, Arnold G, Ott M, Trenkwalder C, Kirsch CM, Oertel WH (1993).

¹²³I-Iodobenzamide-SPECT in 83 patients with de novo parkinsonism.

Neurology, 43(suppl 6):17-20.

Schwarz J, Antonini A, Tatsch K, Kirsch CM, Oertel WH, Leenders KL (1994).

Comparison of ¹²³I-Iodobenzamide-SPECT and ¹¹C-raclopride PET finding in patients with parkinsonism.

Nucl Med Commun, 15:806-813.

Schwarz J, Tatsch K, Gasser T, Arnold G, Oertel WH (1997).

[¹²³I]IBZM binding predicts dopaminergic responsiveness in patients with parkinsonism and previous dopaminomimetic therapy.

Med Disord, 12:898-902.

Schwarz J, Tatsch K, Gasser T, Arnold G, Pogarell O, Kunig G, Oertel WH (1998a).

¹²³I-IBMZ binding compared with long-term clinical follow up in patients with de novo parkinsonism.

Mov Disord, 13:16-19.

Schwarz J, Scherer J, Trenkwalder C, Mozley PD, Tatsch K (1998b).

Reduced striatal dopaminergic innervation shown by IPT and SPECT in patients under neuroleptic treatment: need for levodopa therapy?

Psychiatry Res, 15;83:23-8

Seibyl JP, Marek KL, Quinlan D, Sheff K, Zoghbi S, Zea-Ponce Y, Baldwin RM, Fussell B, Smith EO, Charney DS, Hoffer PB, Innis RB (1995).

Decreased single-photon emission computed tomographic [¹²³I] β-CIT striatal uptake correlates with symptom severity in Parkinson's disease.

Ann Neurol, 38:589-598.

Seibyl JP, Marek KL, Sheff K, Baldwin RM, Zoghbi S, Zea-Ponce Y, Dennis S, Charney DS, van Dyck CH, Hoffer PB, Innis RB (1997).

Test/retest reproducibility of iodine-123βCIT SPECT brain measurement of dopamine transporters in Parkinson's patients.

J Nucl Med, 38:1453-1459.

Seibyl JP, Marek K, Sheff K, Zoghbi S, Baldwin RM, Charney DS, van Dyck CH, Innis RB (1998).

Iodine-123-beta-CIT and iodine-123-FPCIT SPECT measurement of dopamine transporters in healthy subjects and Parkinson's patients.

J Nucl Med, 39:1500-1508

Shinotoh H, Hirayama K, Tateno Y (1993).

Dopamine D1 and D2 receptors in Parkinson's disease and striatonigral degeneration determined by PET.

In: Narabayashi H, Nagatsu T, Yanagisawa N, Mizuno Y (Eds). *Advances in Neurology*. Raven Press, New York, 60:488-493.

Shy GM, Drager GA (1960).

A neurological syndrome associated with orthostatic hypotension.

Arch Neurol, 2:511-527.

Steele JC, Richardson JC, Olszewski J (1964).

Progressive supranuclear palsy.

Arch Neurol, 10:333-359.

Stell R, Bronstein AM (1994).

Eye movement abnormalities in extrapyramidal disease.

In Marsden CD and Fahn S (Eds). Movement disorders 3. Butterworths, 88-113.

Steiner I, Gomori JM, Melamed E (1985)

Features of brain atrophy in Parkinson's disease. A CT scan study.

Neuroradiology, 27:158-160.

Stern MB, Braffman BH, Skolnick BE, Hurtig HI, Grossman RI (1989)

Magnetic resonance imaging in Parkinson's disease and parkinsonian syndromes.

Neurology, 39:1524-1526.

Strange PG (1993).

Dopamine receptors in the basal ganglia: relevance to Parkinson's disease.

Mov Disord, 3:263-270.

Struck LK, Rodnitzky L, Dobson JK (1990).

Stroke and its modification in Parkinson's disease.

Stroke, 21:1395-1399

Talairach J, Tournoux P (1988).

Co-planar stereotactic atlas of the human brain. 3-dimensional proportional system:

In Georg, Thieme, Verlag (Eds) An approach to cerebral imaging. Stuttgart

Tedroff J, Aquilonius S, Hartvig P, Lundqvist H, Gee G, Uhlin J, Langstrom B (1988).

Monoamine re-uptake sites in the human brain evaluated in vivo by means of ¹¹C-nomifensine and positron emission tomography: the effects of age and Parkinson's disease.

Acta Neurol Scand, 77:192-201.

The consensus committee of the American Autonomic Society and the American Academy of Neurology (1996).

Consensus statement on the definition of orthostatic hypotension, pure autonomic failure, and multiple system atrophy.

Neurology, 46:147.

Thompson PD, Marsden CD (1987).

Gait disorder of subcortical arteriosclerotic encephalopathy: Binswanger's disease.

Mov Disord, 2:1-8.

Tissingh G, Booij J, Bergmans P, Winogrodzka A, Janssen AG, van Royen EA, Stoof J, Wolter E Ch (1998).

Iodine-123-N-omega-fluoropropyl-2beta-carbomethoxy-3beta-(4-iodophenyl)-tropane SPECT in healthy controls and early stage, drug-naive Parkinson's disease.

J Nucl Med, 37:1143-1148.

Tolosa ES, Santamaria J (1984).

Parkinsonism and basal ganglia infarcts.

Neurology, 34:1516-1518.

van Royen E, Verhoeff N, Speelman J, Wolter E Ch, Kuiper MA, Janssen AGM (1993).

Multiple system atrophy and progressive supranuclear palsy. Diminished striatal D2 receptor activity demonstrated by ¹²³I-IBZM single photon emission computed tomography.

Arch Neurol, 50:513-516.

Vingerhoets FJG, Snow BJ, Lee CS, Schulzer M, Mak E, Calne DB (1994).

Longitudinal fluorodopa positron emission tomographic studies of the evolution of idiopathic parkinsonism.

Ann Neurol, 36:759-764.

Wakai MK, Kume A, Takahashi A, Ando T, Hashizume Y (1994).

A study of parkinsonism in multiple system atrophy: clinical and MRI correlation.

Acta Neurol Scand, 90: 225-231.

Ward CD, Gibb WR (1990).

Research diagnostic criteria for Parkinson's disease.

In: Streifler MB, Korczyn AD, Melamed E, Youdim MB (Eds).

Advances in Neurology. Raven Press. New York:1990;53:245-249.

Warlow C (1991)

Cerebrovascular disease.

In Warlow C (Ed) Handbook of neurology. Blackwell Scientific publications. 205-245.

Wenning GK, Ben-Shlomo Y, Magalhaes M, Daniel SE, Quinn NP (1994a).

Clinical features and natural history of multiple system atrophy.

Brain, 117:835-845.

Wenning GK, Jager R, Kendall B, Kingsley D, Daniel SE, Quinn NP (1994b).

Is cranial computerised tomography useful in the diagnosis of multiple system atrophy?

Mov Disord, 9:333-336.

Wenning GK, Ben-Shlomo Y, Magalhaes M, Daniel SE, Quinn NP (1995).

Clinicopathological study of 35 cases of multiple system atrophy.

J Neurol Neurosurg Psychiatry, 58:160-166.

Wenning GK, Tison F, Ben-Shlomo Y, Daniel SE, Quinn NP (1997).

Multiple system atrophy: A review of 203 pathologically proven cases.

Mov Disord, 12:133-147.

Wenning GK, Donnemiller E, Granata R, Riccabona G, Poewe W (1998).

¹²³I-β-CIT and ¹²³I-IBZM-SPECT scanning in levodopa-naïve Parkinson's disease.

Mov Disord, 13:438-445.

Winikates J, Jankovic J (1999).

Clinical correlates of vascular parkinsonism.

Arch Neurol, 56:98-102.

Yagishita A, Oda M (1996).

Progressive supranuclear palsy: MRI and pathological findings.

Neuroradiology, 38:S60-S66.

Zijlmans JC, Thijssen HO, Vogels OJ, Kremer HP, Poels PJ, Schoonderwaldt HC,

Merx JL, Van Hof MA, Thien T, Horstink MW (1995).

MRI in patients with suspected vascular parkinsonism.

Arch Neurol, 52:1017-1022.

