



University of Groningen

## Volumetric Effect of Pregnancy on a Unilateral Facial Fat Graft

Tuin, A. Jorien; Schepers, Rutger H.; Spijkervet, Frederik K. L.; Vissink, Arjan; Jansma, Johan

*Published in:*

Plastic and Reconstructive Surgery. Global Open

*DOI:*

[10.1097/GOX.0000000000002358](https://doi.org/10.1097/GOX.0000000000002358)

**IMPORTANT NOTE: You are advised to consult the publisher's version (publisher's PDF) if you wish to cite from it. Please check the document version below.**

*Document Version*

Publisher's PDF, also known as Version of record

*Publication date:*

2019

[Link to publication in University of Groningen/UMCG research database](#)

*Citation for published version (APA):*

Tuin, A. J., Schepers, R. H., Spijkervet, F. K. L., Vissink, A., & Jansma, J. (2019). Volumetric Effect of Pregnancy on a Unilateral Facial Fat Graft. *Plastic and Reconstructive Surgery. Global Open*, 7(9), [e2358]. <https://doi.org/10.1097/GOX.0000000000002358>

### Copyright

Other than for strictly personal use, it is not permitted to download or to forward/distribute the text or part of it without the consent of the author(s) and/or copyright holder(s), unless the work is under an open content license (like Creative Commons).

### Take-down policy

If you believe that this document breaches copyright please contact us providing details, and we will remove access to the work immediately and investigate your claim.

Downloaded from the University of Groningen/UMCG research database (Pure): <http://www.rug.nl/research/portal>. For technical reasons the number of authors shown on this cover page is limited to 10 maximum.

# Volumetric Effect of Pregnancy on a Unilateral Facial Fat Graft

A. Jorien Tuin, MD  
Rutger H. Schepers, MD,  
DMD, PhD  
Frederik K. L. Spijkervet, DMD,  
PhD  
Arjan Vissink, MD, DMD, PhD  
Johan Jansma, MD, DMD, PhD

**Summary:** Weight gain can affect the volume of a facial fat graft, resulting in unfavorable asymmetries. Weight gain during pregnancy is more complex and does not just entail an increase in adipose tissue. This case report objectifies whether pregnancy results in volume changes of a facial fat graft. A 24-year-old woman received a fat graft (7 ml) in the mandibular area to mask a volume deficiency. This deficiency occurred after a fibula reconstruction of a mandibular defect resulting from the removal of an ameloblastoma. The patient became pregnant 3 weeks after the fat graft procedure. Standardized 3-dimensional photographs (3dMD) were available preoperatively and at 7 weeks (first trimester), 6 months (second trimester), 9 months (third trimester), and 14 months (4 months after delivery) postoperatively. Three-dimensional analysis revealed that no substantial volume changes of the fat graft occurred during pregnancy other than the overall proportional gain in facial volume. Pregnancy apparently does not affect the volume of a small unilateral fat graft applied in the facial region. (*Plast Reconstr Surg Glob Open* 2019;7:2358; doi: 10.1097/GOX.0000000000002358; Published online 30 September 2019.)

Weight gain is associated with an increase of the facial fat graft volume in young patients.<sup>1</sup> In case of unilateral fat grafting, volume changes of the fat graft can result in new undesirable asymmetry. In young female patients, pregnancy can be expected. Weight gain during pregnancy is more complex and does not just entail an increase in adipose tissue.<sup>2</sup> The aim of this case report was to objectify the volumetric effect of pregnancy on a facial fat graft.

## CASE PRESENTATION

A 24-year-old woman was diagnosed with an ameloblastoma on the right side of the mandible at the age of 20 years. After reconstruction with a free vascularized fibula graft with dental implants,<sup>1</sup> a soft tissue deficiency remained in the region of the right mandibular body and angle (Fig. 1; T0).

### Fat Graft Procedure

Fat grafting was performed under local anesthesia. The donor site, the inner knee on both sides, was infiltrated

with tumescent solution (5-ml xylocaine 2% in 45-ml Ringers lactate). Adipose tissue was harvested manually using a Sorensen cannula (Tulip Medical, San Diego, Calif.) under negative pressure. The harvested tissue was processed with Puregraft 50 (Cytosol, San Diego, Calif.) according to the manufacturer's protocol. A total of 7 ml of processed adipose tissue was injected with a 0.9 mm blunt cannula subcutaneously in the right mandibular region. Preoperative photographs and 3-dimensional stereophotogrammetry (3dMD, London, United Kingdom) pictures were taken (Table 1).

### Follow-up

At the first routine control visit, 7 weeks after the procedure, the patient reported that she was approximately 3 weeks pregnant. Additional regular and 3-dimensional photographs were taken at 7 weeks (first trimester, T1), 6 months (second trimester, T2), 9 months (third trimester, T3), and 14 months (4 months after delivery, T4) after grafting. The patient's weight changed from 64 kg preoperatively to 61 kg (T2), 74 kg (T3), 79 kg (T4), and 70 kg (T5) (Table 1). Weight gain and general facial volume gain were most evident in the second and third trimesters. The fat graft in the mandibular region was detectable on all postoperative images that were projected over the preoperative 3-dimensional photograph (not shown). The gain in volume of the fat graft was equal to the gain in other areas such as the zygomatic region during pregnancy (Fig. 1).

## DISCUSSION

Despite hormonal and weight changes during pregnancy, substantial volume changes were not detected

**Disclosure:** The authors have no financial interest to declare in relation to the content of this article.

From the Department of Oral & Maxillofacial Surgery, University Medical Center Groningen, University of Groningen, Groningen, The Netherlands.

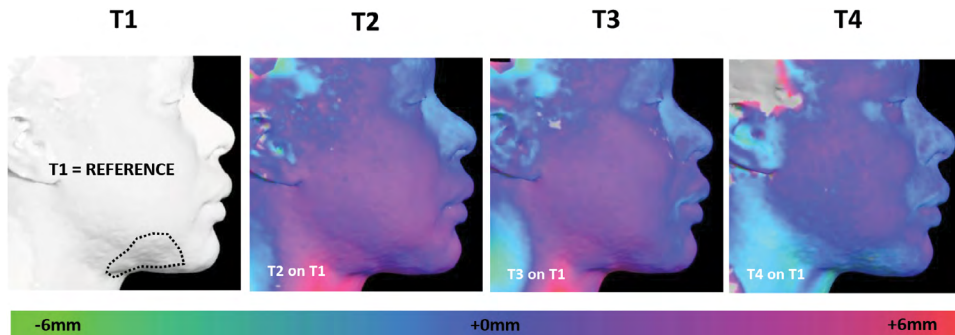
Received for publication January 18, 2019; accepted June 3, 2019.

Copyright © 2019 The Authors. Published by Wolters Kluwer Health, Inc. on behalf of The American Society of Plastic Surgeons. This is an open-access article distributed under the terms of the Creative Commons Attribution-Non Commercial-No Derivatives License 4.0 (CCBY-NC-ND), where it is permissible to download and share the work provided it is properly cited. The work cannot be changed in any way or used commercially without permission from the journal.  
DOI: 10.1097/GOX.0000000000002358

**Table 1. Follow-up Details**

Time	Visit	Time in Relation to Pregnancy	Days after Procedure	Weight (kg)	17β Estradiol Level Serum (nmol/L)	Accuracy 3D Analysis: RMS to T2 (Fig. 2)
T0	Preoperative	-3 wk	0	64	0.0179*	-
T1	First trimester	+3 wk	42	61		-
T2	Second trimester	+22 wk	175	74		0.31
T3	Third trimester	+37 wk	280	79		0.43
T4	After delivery	8wk after delivery	357	70		0.38

The matches of the 3dMD photographs were based on a T-shaped area of the forehead and nose. A RMS under 0.50 was assumed to represent an accurate match. \*Not pregnant: reference first trimester level 0.563–11.6 nmol/L. RMS, root mean square.



**Fig. 1.** Three-dimensional volumetric analysis of the facial fat graft during pregnancy. Color map of the postoperative 3D photographs projected over the first trimester 3D photograph (T1). The matches of the 3dMD. Color scale: green is -6 mm distance in relation to the T0 3D photograph; blue is no difference in relation to T1 the 3dMD photograph; and red is +6 mm distance in relation to the T1 3D photograph. No extra red-/purple-colored areas were detected in the area of the fat graft in relation to the cheek area. Matching of photographs was based on a T-shaped area of the forehead and nose. All RMS scores were lower than 0.5. RMS under 0.50 was assumed to represent an accurate match.

in the facial fat graft applied in the mandibular region. The changes in the fat graft area were comparable to the changes in other tissues in the facial region during pregnancy in terms of volume gain.

As mentioned earlier, Taupin et al<sup>1</sup> reported that young patients with unilateral fat grafts are at risk of undesirable volume changes of a fat graft after weight gain. Growth in length and width cannot always be predicted for future life. Nevertheless, knowledge about weight gain and pregnancy in relation to fat grafting would be helpful to prevent undesirable asymmetries in young patients. Based on our case, pregnancy does not seem to be a major factor.

The average gain in body weight during pregnancy is 10.8–12 kg, with an estimated increase of 6%–7% of body fat.<sup>3</sup> The percentage of fat tissue increases slowly until the 24th week of gestation and remains stable after that until the time of delivery.<sup>2</sup> In contrast to fat percentage gain, extracellular fluid increases from the 24th week until the 40th week of gestation, resulting in a weight gain of approximately 1.5 kg.<sup>2</sup> In our case, the extra volume gain around the cheeks on both sides was observed in the second and third trimesters. It is unclear whether the fat or the extracellular fluid caused this bilateral volume gain in the face.

In our case, subcutaneous adipose tissue from the inner knee was used for fat grafting. In women, femoral subcutaneous adipose tissue is comparable to abdominal subcutaneous adipose tissue with regard to fat local

thickness and number of adipocytes.<sup>4,5</sup> Although no literature is available about changes in subcutaneous femoral adipose tissue during pregnancy, if any, it has been shown that the increase of abdominal fat during pregnancy is a result of an accumulation of visceral adipose tissue and not caused by accumulation of subcutaneous abdominal adipose tissue during pregnancy.<sup>6,7</sup> This conclusion is in line with our finding that the subcutaneous fat graft did not increase in volume during pregnancy.

An animal study by Mok et al<sup>8</sup> stated that high estrogen levels during fat graft transplantation did not lead to higher volume retention in mice. High estrogen is related to a lower acute inflammation response because it inhibits neutrophils and M1 macrophages. However, in their study, some mice had low and some high estrogen levels at the time of transplantation and were followed up at 4 and 12 weeks. In our case, high estrogen levels occurred 3 weeks after the transplantation due to pregnancy onset at that time. We presume that the acute inflammation response was not lower due to this 3-week gap between injection of the fat graft and the conception.

The fat graft did not increase disproportionately during pregnancy, but this observation can be criticized. First, it is possible that the fat graft increased in volume due to pregnancy, but at the same time, it decreased due to physiologic fat graft remodeling. It is known that during the first months after transplantation, volume of a fat graft will decrease.<sup>9–11</sup> Second, a low amount of 7 ml of fat was injected and changes

within the graft might not become visible. However, with the very accurate 3-dimensional imaging techniques, we applied minor changes that were detected in this case. Finally, the unnoticeable difference in volume could be a result of the presence of scar tissue of the reconstructed area.

Our case showed that a unilateral small facial fat graft did not undergo noticeable volumetric changes during pregnancy. This presumption is based on a single case, however. To improve scientific evidence, larger studies are needed to objectify possible volume changes of facial fat grafts during pregnancy.

**A. Jorien Tuin, MD**

Department of Oral & Maxillofacial Surgery  
University Medical Center Groningen  
University of Groningen  
Postbus 30.001  
9700 RB Groningen, The Netherlands  
E-mail: a.j.tuin@umcg.nl

### PATIENT CONSENT

The patient was included in the prospective study “predictors of volumetric outcome and patient satisfaction of lipofilling” registered under number NTR5325 in the Dutch Trial Register. The patient signed an extra informed consent to publish photographs in this article.

### REFERENCES

1. Taupin A, Labbé D, Nicolas J, et al. [Lipofilling and weight gain. Case report and review of the literature]. *Ann Chir Plast Esthet*. 2010;55:238–242.
2. Widen EM, Gallagher D. Body composition changes in pregnancy: measurement, predictors and outcomes. *Eur J Clin Nutr*. 2014;68:643–652.
3. To WW, Wong MW. Body fat composition and weight changes during pregnancy and 6-8 months post-partum in primiparous and multiparous women. *Aust NZ J Obstet Gynaecol*. 2009;49:34–38.
4. Krotkiewski M, Björntorp P, Sjöström L, et al. Impact of obesity on metabolism in men and women. Importance of regional adipose tissue distribution. *J Clin Invest*. 1983;72:1150–1162.
5. Krotkiewski M, Sjöström L, Björntorp P, et al. Regional adipose tissue cellularity in relation to metabolism in young and middle-aged women. *Metabolism*. 1975;24:703–710.
6. Selovic A, Sarac J, Missoni S. Changes in adipose tissue distribution during pregnancy estimated by ultrasonography. *J Matern Fetal Neonatal Med*. 2016;29:2131–2137.
7. Gunderson EP, Sternfeld B, Wellons MF, et al. Childbearing may increase visceral adipose tissue independent of overall increase in body fat. *Obesity (Silver Spring)*. 2008;16:1078–1084.
8. Mok H, Feng J, Hu W, et al. Decreased serum estrogen improves fat graft retention by enhancing early macrophage infiltration and inducing adipocyte hypertrophy. *Biochem Biophys Res Commun*. 2018;501:266–272.
9. Zhu M, Xie Y, Zhu Y, et al. A novel noninvasive three-dimensional volumetric analysis for fat-graft survival in facial recontouring using the 3L and 3M technique. *J Plast Reconstr Aesthet Surg*. 2016;69:248–254.
10. Wu R, Yang X, Jin X, et al. Three-dimensional volumetric analysis of 3 fat-processing techniques for facial fat grafting: a randomized clinical trial. *JAMA Facial Plast Surg*. 2018;20:222–229.
11. Pu LL. Mechanisms of fat graft survival. *Ann Plast Surg*. 2016;77(suppl 1):84.