

Submitted: 07/03/2016

Accepted: 15/06/2016

Published: 28/06/2016

## ***Cryptosporidium varanii* infection in leopard geckos (*Eublepharis macularius*) in Argentina**

A. Dellarupe<sup>1,2</sup>, J.M. Unzaga<sup>1,\*</sup>, G. Moré<sup>1,2</sup>, M. Kienast<sup>3</sup>, A. Larsen<sup>4</sup>, C. Stiebel<sup>5</sup>, M. Rambeaud<sup>1,2</sup> and M.C. Venturini<sup>1</sup>

<sup>1</sup>Laboratorio de Inmunoparasitología, Facultad de Ciencias Veterinarias, Universidad Nacional de La Plata, 60 y 118, 1900 La Plata, Argentina

<sup>2</sup>Consejo Nacional de Investigaciones Científicas y Técnicas (CONICET), Buenos Aires, Argentina

<sup>3</sup>Instituto de Genética Veterinaria (IGEVET), CCT La Plata, CONICET, Facultad de Ciencias Veterinarias, Universidad Nacional de La Plata, La Plata, Argentina

<sup>4</sup>Cátedra de Inmunología Veterinaria, Facultad de Ciencias Veterinarias, Universidad Nacional de La Plata, La Plata, Argentina

<sup>5</sup>Dpto. Zoonosis, Municipalidad Gral. San Martín, Prov. de Buenos Aires, Argentina

### **Abstract**

Cryptosporidiosis is observed in reptiles with high morbidity and considerable mortality. The objective of this study was to achieve the molecular identification of *Cryptosporidium* spp. in pet leopard geckos (*Eublepharis macularius*) from a breeder colony in Buenos Aires, Argentina. Oocysts comparable to those of *Cryptosporidium* spp. were detected in three geckos with a history of diarrhea, anorexia and cachexia. Molecular identification methods confirmed the presence of *Cryptosporidium varanii* (syn. *C. saurophilum*). This agent was considered to be the primary cause of the observed clinical disease. This is the first description of *C. varanii* infection in pet reptiles in Argentina.

**Keywords:** Argentina, *Cryptosporidium* spp., Leopard gecko (*Eublepharis macularius*), PCR, Sequencing.

### **Introduction**

*Cryptosporidium* infection (referred as cryptosporidiosis) is a zoonosis of worldwide distribution that affects the gastrointestinal tract of a range of vertebrate hosts, including mammals, reptiles, birds and fish (Fayer, 2010). Cryptosporidiosis in humans is a cause of diarrhea, mainly in children, and could cause a severe disease in immunocompromised patients (Xiao *et al.*, 2004a). Cryptosporidiosis has been described in many different reptile species, and is especially important in snakes and lizards. Two main *Cryptosporidium* species have been identified in reptiles: *C. serpentis* and *C. varanii* (syn. *C. saurophilum*). *C. serpentis* is a gastric parasite found mainly in snakes, and frequently associated with prominent clinical signs like anorexia, postprandial regurgitation, lethargy, mid-body swelling, and weight loss, while infections in lizards are usually asymptomatic (Fayer *et al.*, 1997). *C. varanii* is an intestinal parasite found primarily in lizards (Pavlassek and Ryan, 2008; Xiao *et al.*, 2004b) and can cause anorexia, progressive weight loss, abdominal swelling and high mortality, particularly in juvenile lizards (Koudela and Modry, 1998). Other *Cryptosporidium* spp. have been described in reptiles like *C. muris*, *C. parvum*, *C. parvum* mouse genotype (syn. *C. tyzzeri*). However, these *Cryptosporidium* spp. oocyst could represent a passage of parasites from ingested prey or feeder mice (Xiao *et al.*, 2004b). Reptiles are becoming popular pets worldwide;

however, little is known about the presence and control of cryptosporidiosis in this animal population. In the last several years, cryptosporidiosis has caused important economic losses for commercial reptile breeders. Therefore, the objective of this study was to perform molecular characterization of *Cryptosporidium* spp. from naturally infected leopard geckos (*Eublepharis macularius*) in Argentina.

### **Materials and Methods**

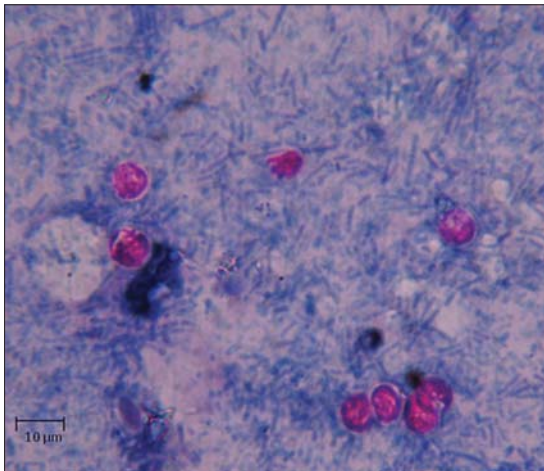
#### **Animals and samples**

A pooled stool sample from 3 leopard geckos (*E. macularius*) was collected and submitted to La Plata University for molecular studies. Three geckos (two females and 1 male) (Fig. 1) were received by veterinary practitioners from a breeder colony in Buenos Aires, Argentina with a history of diarrhea, anorexia and cachexia. Faecal samples were first placed in a 15-ml tube. The tube was partially filled with sucrose solution and mixed in a vortex for approximately 5 sec each tube was centrifuged at 252 g for 10 min. An aliquot was taken from the surface and spread on a slide and examined for the presence of *Cryptosporidium* spp. oocysts by light microscopy (Deming *et al.*, 2008). The modified Ziehl-Neelsen stain for fecal smears was performed essentially as described previously (Henriksen and Pohlenz, 1981); were evidenced several round oocysts of 4-5 µm in diameter compatible with *Cryptosporidium* spp. (Fig. 2). The pooled sample was subjected to a sugar flotation technique (sucrose solution

\*Corresponding Author: Juan Manuel Unzaga. Laboratorio de Inmunoparasitología, Facultad de Ciencias Veterinarias, Universidad Nacional de La Plata, 60 y 118, 1900, La Plata, Argentina. Email: [junzaga@fcv.unlp.edu.ar](mailto:junzaga@fcv.unlp.edu.ar)



**Fig. 1.** Three leopard geckos (two females and 1 male) received by veterinary practitioners from a breeder colony in Buenos Aires, Argentina with a history of diarrhea, anorexia and cachexia.



**Fig. 2.** Fecal smear of leopard geckos (Modified Ziehl-Neelsen technique): round oocysts of 4-5  $\mu$ m diameter compatible with *Cryptosporidium* spp.

without formaldehyde) and water sedimentation as described previously for concentration of coccidian oocysts (Ortega-Mora *et al.*, 2007). Concentrated oocysts were re-suspended in 450  $\mu$ l of nuclease free water.

#### **DNA extraction**

Oocyst disruption and DNA purification from the faecal sample (processed in triplicate) was performed with a DNA stool commercial kit (QIAamp DNA Stool Mini Kit, Qiagen, Hilden, Germany) according to the manufacturer's recommendations. A process control sample (extraction kit solutions and 150  $\mu$ l of nuclease free water) was evaluated together with the stool samples.

#### **Molecular identification**

A nested PCR technique was performed for amplification of a polymorphic fragment of the 18S rDNA gene (Xiao *et al.*, 1999). Five  $\mu$ l aliquot of the internal PCR products was examined by electrophoresis

in 1% agarose gels and stained with ethidium bromide. Two of the amplicons obtained (which reach a gel estimated concentration of about 40 ng/ $\mu$ l), were purified using polyethylene glycol and sequenced in both directions using the Megabace 1000 Sequencing (GE Health care) at IGEVET, FCV, UNLP. Sequences were aligned and analyzed using GENEIOUS software (free available version 7.1, <http://www.geneious.com>). Consensus sequences obtained were compared with others published in GenBank by BLASTn megablast analysis.

#### **Results and Discussion**

Reptiles have become popular pets worldwide in recent years. The leopard gecko is a crepuscular ground-dwelling lizard naturally found in the deserts of Asia and throughout Pakistan, to the northwestern parts of India (Henkel *et al.*, 1995).

Upon ingestion of *Cryptosporidium* spp. oocysts by the host, sporozoites are released and invade epithelial cells. The protozoans multiply asexually and sexually causing death of the host cells. *Cryptosporidium* spp. infection is associated with hyperplastic and inflammatory lesions of the gastrointestinal tract in different animal species including geckos (Terrell *et al.*, 2003). Thus, Cryptosporidiosis has been associated with a wasting syndrome or "going light" in leopard geckos, characterized by chronic weight loss, diarrhea, lethargy, followed by anorexia and death (Deming *et al.*, 2008). In the present study, three leopard geckos from a breeder colony in Argentina showed a wasting syndrome and oocysts compatible with *Cryptosporidium* spp. were detected by Ziehl-Neelsen staining. Previous studies highlight the importance of molecular diagnostic methods to identify species level within the genus *Cryptosporidium* (Richter *et al.*, 2011). In Spain, Pedraza-Diaz *et al.* (2009) performed PCR and sequencing from seven leopard geckos stool samples with *Cryptosporidium* spp. oocysts, identifying *C. varanii* (n = 3), *C. serpentis* (n = 2) and *C. parvum* (n = 2). A similar study performed in Austria, detected *C. varanii* and *C. serpentis* (32/74 and 8/74 leopard geckos, respectively) (Richter *et al.*, 2011).

In the present study, molecular identification of *Cryptosporidium* spp. was performed by sequencing of a polymorphic fragment of the 18s rRNA gene. The nested PCR was positive (all 3 replicates), evidencing a product of around 830 bp. A consensus sequence of 748 bp was obtained and registered on GenBank under accession number KM610237. This sequence was compared with others published in GenBank by BLASTn megablast analysis and revealed a 99% sequence identity with *C. saurophilum* (GenBank EU553551, EU553552 and EF502042) from asymptomatic leopard geckos (*E. macularius*) and one snake (*Boa constrictor*) in Spain (Pedraza-Diaz *et al.*, 2009), and from symptomatic a adult snake

(*Elaphe guttata guttata*) from a private snake breeding colony from Japan (Plutzer and Karanis, 2007), respectively. The sequence evidenced similar identity (99%) with *C. varanii* (GenBank KJ000485) from an asymptomatic adult snake (*Pantherophis guttatus*) from the serpentarium of the Butantan Institute in São Paulo, Brazil (da Silva et al., 2014), and *Cryptosporidium* spp. from a desert monitor (GenBank AF112573) from Missouri, USA (Xiao et al., 1999).

*C. varanii* was initially named in 1995 by Pavlásek et al. (1995) to describe oocysts obtained from an Emerald monitor (*Varanus prasinus*) in the Prague Zoo. The description was based on oocyst morphology, histology of endogenous stages in the intestine, and failure to infect mice. The same species was subsequently identified in other lizards and in snakes (Pavlasek and Ryan, 2008). The nomenclature *C. saurophilum* was used in 1998 by Koudela and Modry (1998) for oocysts obtained from a Schneider's skink (*Eumeces schneideri*). Molecular comparison between *C. saurophilum* and *C. varanii* at the 18S rRNA and actin loci showed that they are genetically identical, but as *C. varanii* was described previously, it takes precedence over *C. saurophilum* which should be considered a junior synonym of *C. varanii* (Pavlasek and Ryan, 2008; Xiao et al., 2004b). Considering the previous studies, the detected protozoan from leopard geckos in Argentina was identified as *C. varanii* (syn. *C. saurophilum*).

*Cryptosporidium* spp. obtained from a desert monitor was originally reported by Xiao et al. (1999). Morphologically, oocysts of the *Cryptosporidium* spp. desert monitor genotype were very similar to those of *C. varanii* in shape and size and significantly smaller than oocysts of *C. serpentis*. Molecular and biologic characterizations conducted in later studies identified the parasite as *C. saurophilum* (Xiao et al., 2004b). This could explain why the sequence obtained in the present study evidenced 99% homology with the sequence GenBank AF112573 (Xiao et al., 1999). The sequence names reported in GenBank should be revised in order to avoid further misinterpretations.

This is the first case report and molecular identification of *C. varanii* in leopard geckos in Argentina. Even though it was not possible to determine whether all three animals were infected with *C. varanii* since a pooled sample was received in the laboratory, it is possible to assume that all animals were infected by *C. varanii* as they all evidenced similar clinical signs compatible with cryptosporidiosis. Further studies should be conducted to identify the prevalence and implications of cryptosporidiosis in pet lizards from Argentina in order to generate awareness among commercial breeders, pet owners and clinical practitioners in Argentina. The present study evidenced the existence of clinical cryptosporidiosis in captive leopard geckos in Argentina and highlights the importance of molecular

identification to species level of *Cryptosporidium* spp.-like oocysts found in fecal samples.

#### Acknowledgements

We gratefully acknowledge the technical support of Isidoro Ercoli.

#### Conflict of interest

The authors declare that there is no conflict of interest.

#### References

- da Silva, D.C., Paiva, P.R., Nakamura, A.A., Homem, C.G., de Souza, M.S., Grego, K.F. and Meireles, M.V. 2014. The detection of *Cryptosporidium serpentis* in snake fecal samples by real-time PCR. *Vet. Parasitol.* 204, 134-138.
- Deming, C., Greiner, E. and Uhl, E.W. 2008. Prevalence of cryptosporidium infection and characteristics of oocyst shedding in a breeding colony of leopard geckos (*Eublepharis macularius*). *J. Zoo Wildl. Med.* 39, 600-607.
- Fayer, R. 2010. Taxonomy and species delimitation in *Cryptosporidium*. *Exp. Parasitol.* 124, 90-97.
- Fayer, R., Speer, C.A. and Dubey, J.P. 1997. The general biology of *Cryptosporidium*. In: Fayer, R. (Ed.), *Cryptosporidium and Cryptosporidiosis*. Press, Boca Raton.
- Henkel, F.W., Schmidt, J. and Hackworth, J. 1995. Geckoes: biology, husbandry, and reproduction. (Malabar, Florida, Krieger Publishing Co.).
- Henriksen, S.A. and Pohlenz, J.F., 1981. Staining of cryptosporidia by a modified Ziehl-Neelsen technique. *Acta Vet. Scand.* 22, 594-596.
- Koudela, B. and Modry, D. 1998. New species of *Cryptosporidium* (*Apicomplexa, Cryptosporidiidae*) from lizards. *Folia Parasitologica* 45, 93-100.
- Levine, N.D., 1980. Some corrections of coccidian (*Apicomplexa: Protozoa*) nomenclature. *J. Parasitol.* 66, 830-834.
- Ortega-Mora, L.M., Gottstein, B., Conraths, F.J. and Buxton, D., 2007. Protozoal Abortion in Farm Ruminants: Guidelines for Diagnosis and Control. CABI International, Wallingford (United Kingdom).
- Pavlásek, I., Lávicová, M., Horák, P., Král, J. and Král, B. 1995. *Cryptosporidium varanii* n.sp. (*Apicomplexa: Cryptosporidiidae*) in Emerald monitor (*Varanus prasinus* Schlegel, 1893) in captivity in Prague zoo. *Gazella, Zoo Praha.* 22, 99-108.
- Pavlasek, I. and Ryan, U. 2008. *Cryptosporidium varanii* takes precedence over *C. saurophilum*. *Exp. Parasitol.* 118, 434-437.
- Pedraza-Diaz, S., Ortega-Mora, L.M., Carrion, B.A., Navarro, V. and Gomez-Bautista, M. 2009. Molecular characterisation of *Cryptosporidium* isolates from pet reptiles. *Vet. Parasitol.* 160, 204-210.
- Plutzer, J. and Karanis, P. 2007. Molecular identification of a *Cryptosporidium saurophilum* from corn snake

- (*Elaphe guttata guttata*). Parasitol. Res. 101, 1141-1145.
- Richter, B., Nedorost, N., Maderner, A. and Weissenbock, H. 2011. Detection of *Cryptosporidium* species in feces or gastric contents from snakes and lizards as determined by polymerase chain reaction analysis and partial sequencing of the 18S ribosomal RNA gene. J. Vet. Diagn. Invest. 23, 430-435.
- Terrell, S.P., Uhl, E.W. and Funk, R.S. 2003. Proliferative enteritis in leopard geckos (*Eublepharis macularius*) associated with *Cryptosporidium* sp. infection. J. Zoo Wildl. Med. 34, 69-75.
- Xiao, L., Fayer, R., Ryan, U. and Upton, S.J. 2004a. *Cryptosporidium* taxonomy: recent advances and implications for public health. Clin. Microbiol. Rev. 17, 72-97.
- Xiao, L., Morgan, U.M., Limor, J., Escalante, A., Arrowood, M., Shulaw, W., Thompson, R.C., Fayer, R. and Lal, A.A. 1999. Genetic diversity within *Cryptosporidium parvum* and related *Cryptosporidium* species. Appl. Environ. Microbiol. 65, 3386-3391.
- Xiao, L., Ryan, U.M., Graczyk, T.K., Limor, J., Li, L., Kombert, M., Junge, R., Sulaiman, I.M., Zhou, L., Arrowood, M.J., Koudela, B., Modry, D. and Lal, A.A. 2004b. Genetic diversity of *Cryptosporidium* spp. in captive reptiles. Appl. Environ. Microbiol. 70, 891-899.