

Dragana Kovačević,^{1,2} Dženana A. Detanac,³ Vujica Marković,^{1,2} Aleksandra Radosavljević,¹
Krstina Doklešić,⁴ Džemail S. Detanac,³ Svetislav Milenković^{1,2}

TREATMENT WITH CYCLOSPORINE A IN SERPIGINOUS CHOROIDITIS: A CASE REPORT

Primljen/Received 23. 09. 2012. god.

Prihvaćen/Accepted 01. 11. 2012. god.

Summary: Serpiginous choroiditis is a rare clinical entity. The clinical course of serpiginous choroiditis is very variable, there is no universal marker of treatment success, and even among experts there is debate about what is the most appropriate treatment. The aim of this paper is to describe a case of serpiginous choroiditis treated with Cyclosporine A at a tertiary uveitis referral centre.

Key words: serpiginous choroiditis, Cyclosporine A, serpiginous choroidopathy, fluorescein angiography.

Introduction

Serpiginous choroiditis (SC) is a clinically defined disorder characterized by destruction of the inner choroid and the retinal pigment epithelium (RPE), as well as, secondary involvement of the retina. It is a rare, usually bilateral, chronic, progressive, recurrent inflammation of the RPE, choriocapillaris and choroid of unknown etiology (1). It generally constitutes less than 5% of posterior uveitis in most epidemiological reports (2). The disease primarily affects healthy young to middle-aged adults, with a higher prevalence reported in males than females (3). There is no clear racial predilection and no familial association (4). Most cases of serpiginous choroiditis are not associated with systemic disease although there are isolated reports of serpiginous choroiditis occurring in the presence of systemic diseases such as Crohn's disease (5), celiac disease (6), extrapyramidal dystonia (7), polyarteritis nodosa

(8), and sarcoidosis (9) that are most likely coincidental. The pathogenesis of serpiginous choroiditis remains unknown. An infectious etiology, immunological derangements, and vascular disorders have been studied in order to find the connection with this condition. Disease presentation and course are variable, and an incomplete understanding of its etiology hinders attempts at formulating an effective treatment strategy. The goals of any successful therapy should be the rapid control of active lesions during recurrences, and the prevention of further recurrences and progression of the disease. As it is a rare condition with an insidious clinical progression, the conduct of any clinical trial with sufficient power would be difficult.

Case report

A 55-year-old woman presented to the Eye Clinic (Clinical Center of Serbia, Belgrade), in November 2010, with a one month history of blurred vision on her right eye. The patient had gradual deterioration of vision on her left eye for 20 years. She had sought multiple consultations before she came to the Clinic, but had no defined diagnosis. She denied any family history of ocular disease.

Ophthalmological examination revealed a visual acuity of 6/60 in the right eye and counting fingers on 0.5 meters in the left eye. Intraocular pressure was 14 mmHg in both eyes. Anterior segment findings were within normal. Fundus examination of the right eye revealed an area of chorioretinal geographic atrophy at the posterior pole which involved the lower half of the fovea. There was an active lesion in infero-temporal macula. Fundus examination of the left eye revealed a lar-

1 Clinic for Eye Diseases, Clinical Center of Serbia, Belgrade, Serbia

2 Belgrade University, School of Medicine, Serbia

3 General hospital Novi Pazar, Serbia

4 Clinic of Emergency Surgery, Clinical Center of Serbia, Belgrade, Serbia

ge, geographic chorioretinal scar at the posterior pole which involved macula, with no signs of active disease.

The old lesion in the left eye demonstrated blockage of fluorescence corresponding to the areas of RPE hypertrophy with staining on the edges (Figure 1). Fluorescein angiography (FA) of the right eye revealed a large hypofluorescent lesion which, in the late phases of the angiogram, had a hyperfluorescent margins — findings typical of an inactive serpiginous lesion and presence of a small area of active disease in infero-temporal macula (Figure 2).

A clinical examination revealed an erythrocyte sedimentation rate of 30 mm in the first hour (normal range 1–12 mm), white blood cells count of $14.5 \cdot 10^9/L$ ($3.4\text{--}9.7 \cdot 10^9/L$) with neutrophilia $11.7 \cdot 10^9/L$ ($2.1\text{--}6.5 \cdot 10^9/L$) and raised levels of urea 10.2 mmol/L ($2.5\text{--}7.5$ mmol/L). Tests for connective tissue disorders were negative, serum angiotensin converting enzyme was within the normal range and chest X-ray was normal. Infectious serologies (toxoplasmosis, *Borrelia burgdorferi*, HIV, herpesvirus, cytomegalovirus, varicella-zoster virus) were within the normal limits.

Based on the clinical presentation, fluorescein angiography, and negative work up for systemic or infectious disease, a diagnosis of serpiginous choroiditis was made.

The patient's medical history was reviewed for liver disease or other contraindications to immunosuppressive therapy. Baseline complete blood count and liver function tests were performed before recommending the treatment options. Risks, benefits, and alternatives were discussed thoroughly, and patient was given an opportunity to consider her therapeutic options.

Treatment with oral Cyclosporine A 300 mg (3×100 mg) per day and 8 mg of intravenous (IV) dexamethasone per day was initiated. After five days, dose of dexa-

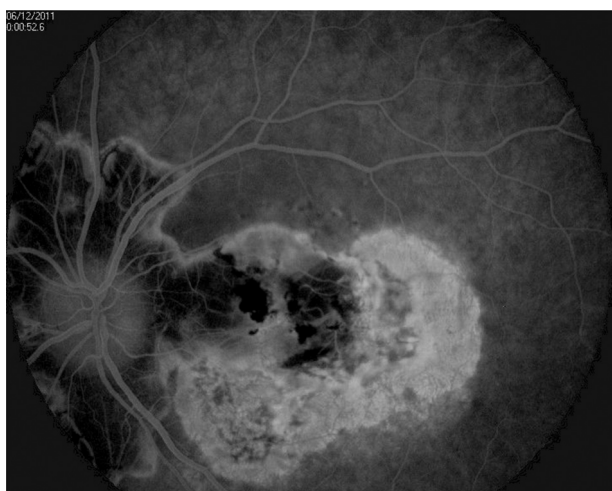


Fig. 1. Inactive lesion showing early hypofluorescence secondary to atrophy of choriocapillaris and progressive hyperfluorescence at the margins of the lesion

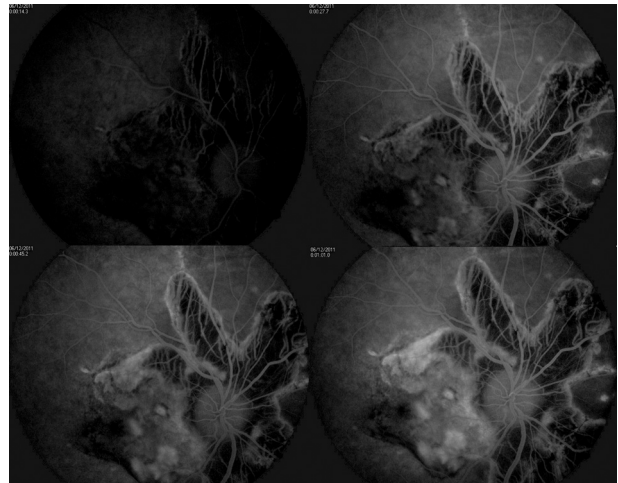


Fig. 2. Fundus fluorescein angiography of an active lesion (early and late phase): active lesion in macula is represented by the blockage of the fluorescence in the early phase and the indistinct margins and more diffuse staining and leakage progressively in the late phase

methasone was reduced to 4 mg IV for the next three days, followed by oral prednisone 40 mg as a single dose in the morning. The patient was discharged with visual acuity of 6/10 in the right eye, and unchanged visual acuity in the left. She continued the treatment with Cyclosporine A 300 mg/day and oral prednisone 40 mg/day.

In the follow-up period, patient underwent Snellen visual acuity (VA) testing, slit-lamp examination, and fundus examination with indirect ophthalmoscopy and a 78-diopter lens.

The first follow-up visit was 3 weeks after initiation of therapy and every 6 to 8 weeks thereafter. The patient was monitored with a complete blood count, Cyclosporine A blood level and liver function test (aspartate aminotransferase and alanine aminotransferase levels) every 2 months. Cyclosporine blood levels were obtained to monitor patient compliance and potential toxicity. The patient was also specifically queried at each visit about the presence of potential adverse reactions associated with Cyclosporine A. Drug dosage was adjusted according to the therapeutic response and side effects. Once the choroiditis appeared not active, oral prednisone was tapered to a lower dosage and finally discontinued. The goal of cyclosporine treatment was inactivity of the lesions for approximately 12 to 24 months, after which the drug was tapered and discontinued.

Patient had decreased ocular inflammation in the right eye within 2 weeks of the initiation of the treatment. She was able to taper and discontinue oral prednisone within 3 months when the visual acuity was 6/9 in the right eye. The patient continued to be under Cyclosporine A 300 mg (3×100 mg) per day, and after 4 months, dose of Cyclosporine A was reduced to 200

mg (2 x 100 mg) per day. The visual acuity was 6/9, and the best-corrected vision was 6/6 (-0.75 Dsph) in the right eye, in that period. Cyclosporine A blood level after nine months of treatment, was 536.6 ng/ml (recommended blood level after 6–12 months of treatment is 100–150 ng/ml), which was the reason for discontinuing of that immunosuppressive agent. The oral prednisone dosage was then increased to the initial level of 60 mg/d. Four weeks later, patient had deterioration of the best-corrected vision to 6/8 (-0.75 Dsph) in the right eye. For that period she tapered the oral prednisone to 40 mg/day. After 1 month the best-corrected vision dropped to 6/12 (-0.75 Dsph). Oral Cyclosporine A (200 mg/d) was added with triamcinolone acetate injections subconjunctivally. The patient is currently on 10 mg/day oral prednisone and 200 mg/day Cyclosporine A, and the clinical status is stable. The visual acuity in the right eye is 6/30 and the best-corrected vision is 6/12 (-0.75 Dsph). To the date, the patient has not presented with choroidal neovascularization (CNV) as a complication of SC and no serious adverse reactions related to Cyclosporine A, such as hepatotoxicity and nephrotoxicity were noted.

Discussion

Our patient was a healthy 55-year-old female, with no comorbidities, whose blurring of central vision in the right eye started one month before she came to the Clinic. Her past, twenty years long ocular history was significant for a gradual blurring of vision in the left eye before blurring of central vision started in the right eye. Although disease involvement is usually bilateral, the typical presentation is asymmetric, including our patient, starting first in the one eye, with a decrease in central vision, metamorphopsia or the development of scotomata that correspond exquisitely with visible fundus lesions. As with our patient, there are typically no inflammatory cells or flare seen in the anterior segment or anterior vitreous. Classic (peripapillary geographic) variant, including our patient, accounts for about 80% of the cases of serpiginous choroiditis reported in the literature (10). The active disease begins with ill-defined patches of grayish or creamy yellow subretinal infiltrates originating in the peripapillary region and progressing centrifugally in an irregular serpentine fashion.

The disease is characterized by multiple recurrences at variable intervals, ranging from months to years. About two-thirds of patients with serpiginous choroiditis have scars in one or both eyes at initial presentation, and most patients are asymptomatic until the macula is involved (11). Visual loss is directly correlated with the proximity of the lesion to the fovea.

Histopathological studies have demonstrated diffuse and focal infiltrates of lymphocytes in the choroid, particularly at the margin of the serpiginous lesions, which implies an inflammatory component to the disease (12). This is the rationale for the use of anti-inflammatory and immunosuppressive therapies for SC. Some authors believe that systemic and periocular corticosteroids may be helpful in the active phase of the disease (13). On the other hand, recent long-term follow-up studies have suggested that therapy with immunosuppressive agents is the best option to treat active SC, as steroids alone did not prevent recurrences (14). The spectrum of alternative immunosuppressive therapies for serpiginous chorioretinitis ranges from monotherapy with corticosteroids or other agents alone to triple therapy with multiple agents. Prognosis regarding the visual function is generally thought to be poor in this disease. Macular involvement, with consequent decreased visual acuity, occurs in up to 88% of patients and approximately 50% could be expected to have recurrence in 5 years (15). Based on the studies reported so far, the rapid control of any active lesions with aggressive immunosuppression and thereafter the maintenance on appropriate immunosuppression for at least 6 months to prevent any immediate recurrence can be considered for the initial management of patients with serpiginous choroiditis. Subsequent treatment will depend not only on the severity of the disease, e.g., foveal threatening lesions in an only seeing eye, but also on the general health of the patient and other concerns such as fertility and the response to initial immunosuppressive therapy (16). One of the treatment algorithm based on current knowledge is using systemic corticosteroids and periocular steroidal injections as the first line to control active lesions, with immunosuppressive therapy such as cyclosporine A, azathioprine or mycophenolate mofetil used concurrently as monotherapy for maintenance of remission (17). Cases that don not respond to this approach may then be candidates for a combination therapy similar to triple-therapy or alkylating agents (18).

In our patient with active SC, Cyclosporine A appears to be an effective and safe drug for preventing the disease progression and inducing the remission. She had a recurrence after 9 months of treatment, when Cyclosporine A has been discontinued because of the high blood level. The oral prednisone dosage was then increased, but the patient had the worsening of the best-corrected vision in the right eye, and after 1 month Cyclosporine A was included in treatment again. The inflammatory process was successfully controlled within 1 month, and the patient was able to taper oral prednisone without recurrence of SC. It is important to note that CNV, a long-term complication of SC seen in up to 35% of cases (19), did not occur in either of patient's eye. The

patient is currently on 10 mg/day oral prednisone and 200 mg/day Cyclosporine A, visual acuity and inflammation are stable and she had no constitutional symptoms severe enough to necessitate ceasing cyclosporine A.

Conclusion

Our results suggest that Cyclosporine A used in combination with corticosteroids is a safe and accepta-

ble option for treating patients with active SC. To demonstrate the success of any therapeutic approach for serpiginous choroiditis, a long-term follow-up with serial fundus photographs and fluorescein angiograms to show disease non-progression is required. Further multicentric studies are required to evaluate the etiology, pathogenesis, natural history and the efficacy of different treatment strategies for this rare disease.

Sažetak

CIKLOSPORIN A U TERAPIJI SERPIGINOZNOG HOROIDITISA: PRIKAZ SLUČAJA

Dragana Kovačević,^{1,2} Dženana A. Detanac,³ Vujica Marković,^{1,2} Aleksandra Radosavljević,¹ Krstina Doklešić,⁴ Džemail S. Detanac,³ Svetislav Milenković^{1,2}

1 — Klinika za očne bolesti, Klinički centar Srbije, Beograd; 2 — Medicinski fakultet Univerziteta u Beogradu; 3 — Opšta bolnica Novi Pazar; 4 — Klinika za urgentnu hirurgiju, Klinički centar Srbije, Beograd

Serpiginozni horoiditis je redak klinički entitet. Prirodni tok bolesti je veoma promenljiv, ne postoji univerzalni pokazatelj terapijskog uspeha, čak i među ekspertima još uvek postoji debata oko najprikladnijeg terapijskog pristupa. Cilj ovog rada je da opiše slučaj

serpiginoznog horoiditisa primarno lečenog Ciklosporinom A u tercijarnoj referentnoj ustanovi.

Ključne reči: serpiginozni horoiditis, Ciklosporin A, serpiginozna horoidopatija, fluoresceinska angiografija.

REFERENCE

1. Abu el-Asrar AM: Serpiginous (geographical) choroiditis. *Int Ophthalmol Clin.* 1995; 35: 87–91.
2. Chang JH, Wakefield D. Uveitis: a global perspective. *Ocul Immunol Inflamm.* 2002; 10: 263–79.
3. Akpek EK, Jabs DA, Tessler HH, et al. Successful treatment of serpiginous choroiditis with alkylating agents. *Ophthalmology.* 2002; 109: 1506–13.
4. Gupta V, Agarwal A, Gupta A, et al. Clinical characteristics of serpiginous choroidopathy in North India. *Am J Ophthalmol.* 2002; 134: 47–56.
5. Ugarte M, Wearne IM. Serpiginous choroidopathy: an unusual association with Crohn's disease. *Clin Exp Ophthalmol.* 2002; 30: 437–39.
6. Mulder CJ, Pena AS, Jansen J, Oosterhuis JA. Celiac disease and geographic (serpiginous) choroidopathy with occurrence of thrombocytopenic purpura. *Arch Intern Med.* 1983; 143: 842.
7. Richardson RR, Cooper IS, Smith JL. Serpiginous choroiditis and unilateral extrapyramidal dystonia. *Ann Ophthalmol.* 1981; 13: 15–19.
8. Pinto Ferreira F, Faria A, Ganhao F. Periarteritis nodosa with initial ocular involvement. *J Fr Ophtalmol.* 1995; 18: 788–93.
9. Edelsten C, Stanford MR, Graham EM. Serpiginous choroiditis: an unusual presentation of ocular sarcoidosis. *Br J Ophthalmol.* 1994; 78: 70–71.
10. Nussenblatt RB, Whitcup SM. Uveitis: fundamentals and clinical practice. 4th ed. St. Louis: Mosby; 2010.
11. Lim WK, Buggage RR, Nussenblatt RB. Serpiginous choroidopathy: major review. *Surv Ophthalmol.* 2005; 50: 231–44.
12. Wu JS, Lewis H, Fine SL, et al. Clinicopathologic findings in a patient with serpiginous choroiditis and treated choroidal neovascularization. *Retina.* 1989; 9: 292–301.
13. Akpek EK, Jabs DA, Tessler HH, Joondeph BC, Foster CS. Successful treatment of serpiginous choroiditis with alkylating agents. *Ophthalmology.* 2002; 109: 1506–13.
14. Munteanu G, Munteanu M, Zolog I. Serpiginous choroiditis — clinical study. *Oftalmologia.* 2001; 52: 72–80.
15. Christmas NJ, Oh KT, Oh DM, Folk JC. Long-term follow-up of patients with serpiginous choroiditis. *Retina.* 2002; 22: 550–56.
16. Svetislav Milenkovic, Vesna Jaksic, Natalija Jakovic, Ivan Stefanovic, Dijana Risimic, Jelena Paovic, James C Folk. Diagnostic and therapeutic challenges. *Retina.* 2010; 30(9): 1546–48.
17. Araujo AAQ, Wells AP, Dick AD, Forrester JV. Early treatment with cyclosporin in serpiginous choroidopathy maintains remission and good visual outcome. *Br J Ophthalmol.* 2000; 84: 979–82.
18. Hooper PL, Kaplan HJ. Triple agent immunosuppression in serpiginous choroiditis. *Ophthalmology.* 1991; 98: 944–51.
19. Lee DK, Suhler EB, Augustin W, Buggage RR. Serpiginous choroidopathy presenting as choroidal neovascularization. *Br J Ophthalmol.* 2003; 87: 1184–97.

Correspondence to/Autor za korespondenciju

dr Dženana Detanac

Sutjeska bb, Novi Pazar

E-mail: dzenana.detanac@gmail.com