

Case Report:**Tuberculosis of the sella masquerading as pituitary adenoma****J.V. Mascarenhas, S. Vageesh Ayyar***Department of Endocrinology, St.John's Medical College, Bangalore***ABSTRACT**

Tuberculosis of the central nervous system is an ominous consequence of disseminated tuberculosis which usually manifests as meningitis, an abscess or rarely as a tuberculoma. Though infrequent, intracranial tuberculomas especially within the sella, are notorious for simulating as pituitary tumors, by jeopardising pituitary hormonal function and exerting compressive effects on adjacent intracranial structures. However, a prompt evaluation can help tackle this diagnostic challenge with timely institution of anti-tuberculosis treatment, (ATT). Although in rare instances surgery may be a favourable option especially for managing extensive intrasellar masses, ATT usually facilitates resolution of such lesions. Long term hormonal replacement therapy may be required for established endocrine dysfunction.

Key Words: *Sellar mass, Tuberculosis, Hypopituitarism, Hormone replacement, Antituberculosis treatment*

Mascarenhas JV, Vageesh Ayyar S. Tuberculosis of the sella masquerading as pituitary adenoma. *J Clin Sci Res* 2013;2:42-4.

INTRODUCTION

Inflammatory and granulomatous lesions of the pituitary gland, which constitute a minor fraction of non-functioning sellar masses (NFSM), have been known to behave like pituitary tumors. Of these, tuberculosis (TB) is a rare pathological factor, accounting for 0.15% - 4% of all intracranial lesions.¹ Tuberculous involvement of the sella eventually leads to permanent endocrine dysfunction, if discovered late. Therefore, the need to investigate it early during diagnostic evaluation is of a major concern, since the condition is reversible with anti-tubercular therapy (ATT). We hereby report the presentation of an adult male who displayed features of pituitary insufficiency as evidenced by clinical and biochemical parameters. Initial diagnosis revealed a pituitary macroadenoma which was later proven to be tuberculosis (TB) on histopathological examination. The narration below is aimed at reinforcing the awareness among clinicians for considering TB as a possible aetiological factor for NFSM.

CASE REPORT

A 45-year-old male, known to have diabetes mellitus since 18 months, presented to our Endocrinology clinic with progressive symptoms of lethargy, reduced libido, reduced shaving

frequency, weight gain and generalized bodyaches since 1 year. On examination, his body weight was 70.2 Kg, height was 165 cm, blood pressure (BP) was 140/90 mmHg. His skin was dry with bulky musculature. Systemic examination was otherwise unremarkable except for a delayed deep tendon reflexes. Laboratory examination revealed fasting blood glucose (FBG) = 105 mg/dL (normal, 70 – 100 mg/dL); glycosylated haemoglobin (HbA1c) 5.9 % (normal, 4.4 – 6.4%); thyroid stimulating hormone (TSH) 0.003 mIU/L (normal, 0.34 – 5.6 mIU/L); free thyroxine (FT4) 0.61 µg/dL (normal, 0.61 – 1.12 ng/dL); anti-thyroid peroxidase (anti-TPO) and body were negative; and 8 am serum cortisol 2.26 µg/dL (normal 6.7 – 22.6 µg/dL). As his thyroid profile was suggestive of central hypothyroidism with hypocortisolism, he was further evaluated for other pituitary hormones which revealed serum follicle stimulating hormone (FSH) 3.14 mIU/mL (normal, 1.27 – 19.26 mIU/mL); serum leutinizing hormone (LH) 0.54 mIU/mL (normal, 1.24 – 8.62 mIU/mL); serum prolactin (PRL) 5.6 ng/mL (2.64 – 13.13 ng/mL); serum testosterone was not detectable. Subsequently, a diagnosis of combined pituitary hormone deficiency (CPHD) was made. Perimetry revealed early temporal feild defect. Magnetic resonance imaging (MRI) of the sella

Received: 25 August, 2012.

Corresponding Author: Dr S. Vageesh Ayyar, Associate Professor, Department of Endocrinology, St.John's Medical College and Hospital, Bangalore. **e-mail:** vagayyar@yahoo.com

showed finding suggestive of a pituitary macroadenoma, measuring $22 \times 18 \times 16$ mm, with suprasellar extension (Figure 1). There was homogeneous enhancement and mass effect on the optic chiasma. Patient was initially started on oral corticosteroids and subsequently L-thyroxine was added. The patient was taken up for surgery, the pituitary mass was approached via transphenoidal exploration (TSS) and was resected and the resected material was sent for histopathological examination (HPE) which revealed fragments of adenohypophysis, multiple epithelioid cell granulomas with giant cells and early necrosis, suggestive of granulomatous hypophysitis of probable tuberculosis aetiology. Perioperative period was uneventful except for transient diabetes insipidus. Following surgery, the patient received ATT along with long term hormonal replacement therapy.

DISCUSSION

TB of the pituitary, although extremely infrequent, is a cause of secondary granulomatous hypophysitis which is sometimes reported in developing countries. TB accounts for 0.15 - 4% of all intracranial lesions.¹ It primarily manifests as a tuberculoma (tumour-like masses of tuberculous granulation tissue ranging from 2 to 12 mm in diameter that forms in the parenchyma of the brain associated with widening of the pituitary stalk (TB hypophysitis). It can undergo caseation resulting in a pituitary abscess, or haemorrhagic infarction

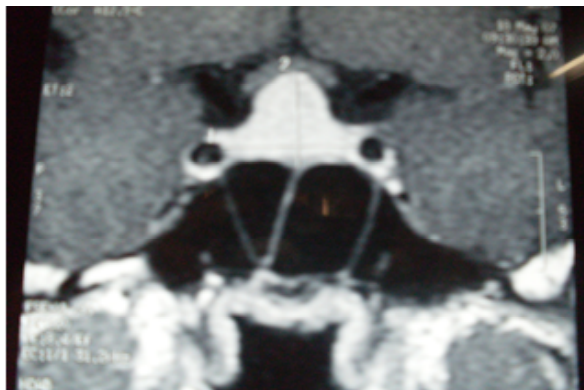


Figure 1: MRI of sella displaying a homogeneous mass suggestive of a pituitary macroadenoma measuring $22 \times 18 \times 16$ mm³, with suprasellar extension and mass effect on the optic chiasma

MRI=magnetic resonance imaging

leading to pituitary apoplexy. Tuberculomas usually occur as part of a systemic infection, following hematogenous spread; however isolated lesions have been reported.² Earlier studies have reported intrasellar tuberculomas arising from direct extension of infection from paranasal sinuses, especially in females.³ Other signs of active TB are generally but not invariably present. Headache is the most common symptom occurring earlier and is accompanied by visual disturbances. Owing to their compressive effects, varying degrees of anterior pituitary dysfunction can develop later with or without central diabetes insipidus. Hypopituitarism with hyperprolactinaemia occurs, that causes galactorrhoea and amenorrhoea in females and decreased libido in males. Imaging studies show involvement of paranasal sinuses and pituitary fossa, along with thickening and nodularity of the pituitary stalk. Simultaneous involvement of clivus may be an additional imaging feature of this disease. On MRI, TB pituitary abscesses appear isointense to hypointense on T1-weighted images and hyperintense on T2-weighted images. They may occasionally appear hyperintense on T1-weighted images owing to their high protein content. These signal characteristics are nonspecific and overlap those of pituitary adenomas and other granulomatous lesions. TB abscesses may show peripheral contrast enhancement and adjacent meningeal enhancement on contrast-enhanced MRI. There may be suprasellar extension or impingement upon the optic chiasm.^{4,5} Histopathologically, they are classically characterized by a central area of caseation necrosis surrounded by epithelioid cells, lymphocytes, plasma cells and Langhans's giant cells. Differential diagnosis includes sarcoidosis, syphilis and other granulomatous inflammations. Acid-fast bacilli (AFB) are usually not demonstrable.⁶

Surgery is not usually indicated, except for obtaining biopsies to confirm diagnosis, as these lesions tend to resolve with appropriate ATT;⁷ nevertheless our patient in review required surgery due to established hypopituitarism and radiological evidence of mass extension. Trans-sphenoidal

route is the safest approach to avoid cerebrospinal fluid contamination. Intraoperative findings of a thickened hypophyseal stalk, a greyish firm non suckable mass with caseation and a thickened dura, serve as tell-tale signs of a tuberculoma.^{8,9} ATT is mandatory, and hormone replacement therapy may need to be instituted in cases that present with signs and symptoms of hypopituitarism.¹⁰

Intrasellar tuberculomas are well-known for masquerading as pituitary adenomas and hence it should be considered in the differential diagnosis of suprasellar masses. Restricting the extent of surgery can help avert the anticipated occurrence of hormonal deficiencies following surgery.

ACKNOWLEDGEMENTS

We would like to extend our gratitude to the Department of Neuroimaging, St John's Medical College and the Departments of Neurosurgery and Neuropathology, National Institute of Mental Health and Neurosciences (NIMHANS), Bengaluru for their contribution to the aforementioned case report.

REFERENCES

1. Glezer A, Paraiba DB, Bronstein MD. Rare sellar lesions. *Endocrinology and Metabolism Clinics of North America* 2008;37:195-211.
2. Freda PU. Tuberculosis of the pituitary and sellar region. *Pituitary* 2002;5:147-8.
3. Sharma MC, Arora R, Mahapatra AK, Sarat-Chandra P, Gaikwad SB, Sarkar C. Intrasellar tuberculoma - an enigmatic pituitary infection: a series of 18 cases. *Clinical Neurology and Neurosurgery* 2000;102:72-7.
4. Domingues FS, de Souza JM, Chagas H, Chimelli L, Vaisman M. Pituitary tuberculoma: an unusual lesion of sellar region. *Pituitary* 2002;5:149-53.
5. Patankar T, Patkar D, Bunting T, Castillo M, Mukherji SK. Imaging in pituitary tuberculosis. *Clin Imaging* 2000;242:89-92.
6. Petrossians P, Delvenne P, Flandroy P, Jopart P, Stevenaert A, Beckers A. An unusual pituitary pathology. *J Clin Endocrinol Metab* 1998;83:3454-8.
7. Dutta P, Bhansali A, Singh P, Bhat MH. Suprasellar tubercular abscess presenting as panhypopituitarism: a common lesion in an uncommon site with a brief review of literature. *Pituitary* 2006;9:73-7.
8. Ghosh S, Chandy MJ. Intrasellar tuberculoma. *Clin Neurol Neurosurg* 1992;94:251-2.
9. Taparia SC, Tyagi G, Singh AK, Gondal R, Prakash B. Sellar tuberculoma. *J Neurol Neurosurg Psychiatry* 1992;55:629.
10. Husain N, Husain M, Rao P. Pituitary tuberculosis mimicking idiopathic granulomatous hypophysitis. *Pituitary* 2008;11:313-5.