

Cutaneous leukocytoclastic vasculitis associated with levofloxacin therapy

Dana M. Blyth,¹ Elizabeth Markelz,²
Jason F. Okulicz²

¹Department of Internal Medicine and
²Infectious Disease Service, San Antonio
Military Medical Center, San Antonio, TX,
USA

Abstract

Many cases of cutaneous vasculitis are drug-induced with histology revealing leukocytoclastic vasculitis (LCV). We present a case of levofloxacin-associated LCV successfully treated with prednisone and cessation of the offending drug. Although case reports describe a link between LCV and older fluoroquinolones, such as ciprofloxacin and ofloxacin, recent reports have implicated the newer fluoroquinolone levofloxacin. Recognition of fluoroquinolone-induced cutaneous vasculitis is important as continuation or re-exposure of the offending agent may have life-threatening consequences.

Introduction

The presentation of vasculitis is highly variable, with more severe cases resulting in hemorrhage, ischemia, or other complications depending on the degree of inflammation and to what extent the vascular architecture is compromised.¹ For cutaneous vasculitis, up to 20% of cases are drug-induced with histology demonstrating leukocytoclastic vasculitis (LCV).² The classic presentation of cutaneous vasculitis is palpable purpura, but ranges from erythematous lesions to deep ulcers or digital gangrene.³ A high index of suspicion is necessary for diagnosis and successful treatment. The identification of drug-induced LCV is critical since withdrawal of the offending agent can be life-saving.⁴ We describe a case of levofloxacin-associated LCV and review the pertinent literature involving the association of fluoroquinolones with cutaneous vasculitis.

Case Report

A 64-year old man presented for evaluation of a painful, erythematous, and violaceous rash on his left leg that had developed over the previous 24 h. The day before presentation, the patient had completed a 5-day-course of levofloxacin 500 mg twice daily for a presumed respiratory infection. The patient had a history of severe varicose veins in his lower extremities which had led to chronic lower extremity edema after undergoing elective vein removal procedures. Other past medical history included benign prostatic hypertrophy, erectile dysfunction, and a distant history of left great toe osteomyelitis. Medications included felodipine 5 mg daily, hydrochlorothiazide 25 mg daily, terazosin 1 mg daily, vardenafil 5 mg as needed, and the recently prescribed levofloxacin. He denied any use of over the counter or herbal medications.

Patient's vital signs on presentation were body temperature 96.8°F, pulse 63/min, respiratory rate 18/min, blood pressure 155/95 mmHg, and pulse oximetry 98% on room air. Examination of his left lower extremity revealed 3-4+ pitting edema. Numerous purpuric papules coalescing into large plaques were present on the medial and anterior distal left leg with dark purple coloration centrally and non-blanching erythema around the periphery of the lesions. There was an approximately 2 cm in diameter coalesced plaque of palpable purpura on the proximal left lateral leg with a few small bullae centrally as well as scattered purpuric papules on the left thigh. On the dorsum of the left foot there were numerous petechiae that were becoming confluent. He had significant tenderness to palpation on the medial and anterior distal left leg. Several scattered purpuric papules were also present on the right lower extremity. The rest of his physical examination was normal.

Laboratory analysis revealed white blood cell count (WBC) $8.16 \times 10^9/L$ (normal range $3.4-9.8 \times 10^9/L$) with 71% neutrophils (normal range 41-73%), 20% lymphocytes (18-46%), and 1% eosinophils (0-3.2%). Hemoglobin and hematocrit were 14.1 g/dL (14-18 g/dL) and 42.2% (41-52%), respectively, while platelet count was $296 \times 10^9/L$ ($142-362 \times 10^9/L$). His renal function and serum electrolytes were within normal limits. Since cutaneous vasculitis was suspected, based on clinical appearance of palpable purpura, diagnostic testing was carried out to determine the etiology. Complement levels were normal and other tests for potential causes of vasculitis were also negative, including ANA, rheumatoid factor, anti-streptolysin-O, C-ANCA, P-ANCA, and testing for hepatitis B and C. Serum protein electrophoresis demonstrated a normal electrophoresis pattern.

A punch biopsy was performed (Figure 1) and was consistent with leukocytoclastic vasculitis. Upon review of the patient's recent medications, levofloxacin-induced vasculitis was suspected. After the patient confirmed that he was no longer taking levofloxacin, he was prescribed a 7-day course of prednisone 60 mg daily followed by a 14-day taper. A 2-week course of clindamycin was also given for possible cellulitis due to bacterial super-infection of the area involving LCV. Fluoroquinolones were avoided due to suspicion of levofloxacin-induced vasculitis and a concern for a potential cross-reaction among other agents in the same drug class. At follow up one month after his initial presentation, the patient had significant improvement in his lower extremity lesions. In the area of his left lower extremity with the greatest skin involvement, a large but shallow ulceration remained and was treated with local wound care. The rest of the patient's dermatological manifestations had completely resolved.

After evaluation of the patient's clinical history and physical examination findings, a drug-induced cutaneous vasculitis was suspected and later confirmed by biopsy. The interval between the first exposure to the drug and the initial onset of symptoms can range between hours and years, with onset occurring following an increased dose or re-challenge. In cases of drug-induced hypersensitivity vasculitis, discontinuation of the offending agent is

Correspondence: Dana M. Blyth, MD, Brooke Army Medical Center, 3851 Roger Brooke Drive, Fort Sam Houston, TX 78234-6200, USA.
Tel: +1.210.916.4355 - Fax: +1.210.916-5900.
E-mail: dana.m.blyth@us.af.mil

Key words: levofloxacin, drug induced cutaneous vasculitis, leukocytoclastic vasculitis, fluoroquinolone.

Contributions: DMB, manuscript preparation, literature research; EM, images providing, case discussion, manuscript review; JFO, manuscript conception, preparation, supervision.

Conflict of interest: the authors do not declare any potential conflicts of interest with this publication.

The views expressed in this article are those of the authors and do not reflect the official policy of the Department of the Army, the Department of Defense, or the U. S. Government.

Received for publication: 23 August 2011.

Revision received: 6 November 2011.

Accepted for publication: 14 November 2011.

This work is licensed under a Creative Commons Attribution NonCommercial 3.0 License (CC BY-NC 3.0).

©Copyright D.M. Blyth et al., 2012
Licensee PAGEPress, Italy
Infectious Disease Reports 2012; 4:e11
doi:10.4081/idr.2012.e11

course of clindamycin was also given for possible cellulitis due to bacterial super-infection of the area involving LCV. Fluoroquinolones were avoided due to suspicion of levofloxacin-induced vasculitis and a concern for a potential cross-reaction among other agents in the same drug class. At follow up one month after his initial presentation, the patient had significant improvement in his lower extremity lesions. In the area of his left lower extremity with the greatest skin involvement, a large but shallow ulceration remained and was treated with local wound care. The rest of the patient's dermatological manifestations had completely resolved.

Discussion

After evaluation of the patient's clinical history and physical examination findings, a drug-induced cutaneous vasculitis was suspected and later confirmed by biopsy. The interval between the first exposure to the drug and the initial onset of symptoms can range between hours and years, with onset occurring following an increased dose or re-challenge. In cases of drug-induced hypersensitivity vasculitis, discontinuation of the offending agent is

usually followed by a rapid improvement in symptoms. Re-challenge is not recommended due to the potential of recurrence with increased severity.²

Evaluation of a patient with suspected cutaneous vasculitis should include history, physical examination, and laboratory and histological evaluations.⁵ The first step in classifying the lesion is based on caliber of the vessels involved (small, medium, or large) by performing a skin biopsy. LCV involves small vessels and punch biopsy is the diagnostic method of choice.² Since neutrophils are replaced by lymphocytes and macrophages within 48 h after the appearance of a lesion, early biopsy is of highest diagnostic yield.³ Tissue eosinophilia is also suggestive of a drug etiology but is not always present. Direct immunofluorescence confirms and further classifies the presence of vasculitis by identifying specific immunoglobulins.⁶

In drug-induced vasculitis, the offending drug can be hard to identify, and further laboratory tests can be helpful. An ANCA testing is

positive in some cases of drug induced vasculitis, including propylthiouracil, hydralazine, allopurinol, minocycline, penicillamine, and phenytoin which may induce systemic vasculitis syndromes with a life-threatening visceral involvement.¹ Our patient was not prescribed any of the above agents and ANCA testing was

negative. According to the Naranjo adverse drug reaction probability scale with a score of 6, levofloxacin was a probable cause of LCV in our case as the adverse event occurred after the suspected drug was administered, improved after discontinuation with addition of steroids, was proven by biopsy to be LCV, and

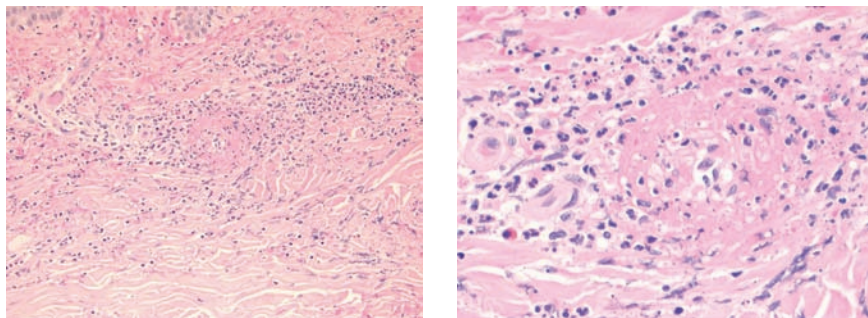


Figure 1. Skin biopsy of left lower extremity with hematoxylin and eosin staining under A) low and B) high power demonstrating a predominant neutrophilic infiltration, presence of eosinophils, and the formation of subepidermal bullae consistent with leukocytoclastic vasculitis.

Table 1. Prior case reports of fluoroquinolone-associated vasculitis.

Fluoroquinolone (FQ)	Dose	Time to symptom onset	Other medications	Clinical diagnosis or biopsy proven	Final diagnosis	Treatment	Year Published
Ciprofloxacin ¹⁷	500 mg po BID	3 days	None	Skin biopsy	Perivascular mononuclear-cell infiltrate	Withdrawal of FQ	1989
Ciprofloxacin ¹⁸	500 po mg/day	4 days	Cephadrine	Skin biopsy	LCV	Withdrawal of FQ	1992
Ciprofloxacin ¹⁸	Unknown	10 days	Diuretic	Clinical diagnosis	Haemorrhagic vasculitis	None	1992
Ciprofloxacin ¹⁹	500 mg po BID	4 days	Fluoxetine	Clinical diagnosis	Cutaneous vasculitis	Withdrawal of FQ; fluoxetine continued	1997
Ciprofloxacin ²⁰	Unknown	10 days	None	Clinical diagnosis; subsequent renal biopsy	Cutaneous vasculitis	Withdrawal of FQ; prednisone	2007
Ciprofloxacin ⁴	Unknown	7 days	Rifampin	Clinical diagnosis	Drug-induced vasculitis	Withdrawal of FQ; rifampin given without recurrence	2009
Ciprofloxacin ⁴	Unknown	8 days	Flucloxacillin	Clinical diagnosis	Drug hypersensitivity	Withdrawal of FQ; flucloxacillin continued	2009
Ofloxacin ²¹	200 mg po BID	1 day	None	Skin biopsy and mast cell degranulation test for ofloxacin	Leukocytoclastic angiitis	Withdrawal of FQ; prednisone	1989
Ofloxacin ²²	200 mg po BID	5 days	Bumetanide, spirinolactone 2 weeks prior	Skin biopsy	Vasculitis	Unknown	1989
Ofloxacin ²³	200 mg po BID	3 days	Aspirin, digoxin	Skin biopsy	Leukocytoclastic vasculitis	Withdrawal of FQ; prednisolone	1995
Ofloxacin ²⁴	200 mg po BID	3 days	None	Skin biopsy	Leukocytoclastic angiitis	Withdrawal of FQ	1996
Levofloxacin ²⁵	500 mg po daily	3 days	None	Clinical diagnosis	Nephrotoxicity and purpura	Withdrawal of FQ; prednisone	2002
Levofloxacin ²⁶	500 mg po daily	5 days	Azithromycine, piperacilline-tazobactam	Clinical diagnosis	LCV	Withdrawal of FQ; prednisone	2006
Levofloxacin ⁴	Unknown	3 days	Rifampin	Skin biopsy	LCV	Withdrawal of FQ and rifampin changed to rifampicin	2009
Levofloxacin	500 mg po BID	5 days	None	Skin biopsy	LCV	Withdrawal of FQ; prednisone	Current case

no other alternative causes for the reaction were identified.⁷ Levofloxacin is a commonly prescribed antibiotic and is indicated for a number of infections, including community acquired and nosocomial pneumonia, uncomplicated or complicated urinary tract infections and pyelonephritis, acute bacterial sinusitis, acute or chronic bronchitis, as well as skin and skin structure infections.⁸⁻¹⁰

Adverse events commonly associated with fluoroquinolones as a class include: gastrointestinal and CNS toxicity, EKG abnormalities including QT prolongation, dysglycemia, phototoxicity, tendon and joint disorders, hypersensitivity reactions, and hepatotoxicity.¹¹⁻¹³ While some structural components are clearly associated with adverse reactions, such as phototoxicity with the addition of chlorine or fluorine at the 8-position, and CNS effects which are seen more commonly with the unsubstituted 7-piperazine derivatives, others do not appear to have any obvious structural associations including QT prolongation¹⁴ and tendon rupture.¹² In previous studies, ciprofloxacin, ofloxacin, levofloxacin, moxifloxacin and gatifloxacin have been associated with torsades de pointes.¹⁵ However, the development of torsades de pointes is likely influenced by multiple risk factors in a patient already at risk.¹⁶ In other reports, ciprofloxacin has been the predominant fluoroquinolone associated with cutaneous vasculitis.

All reported cases of fluoroquinolone-associated LCV in the literature involve ciprofloxacin, ofloxacin, and levofloxacin (Table 1). This association may be due to structural similarities between these agents. For example, levofloxacin is the L-enantiomer of ofloxacin.²⁷ Ciprofloxacin is distinguished by a cyclopropyl group at position 1 of the molecule and has other structural differences compared to ofloxacin and levofloxacin. While ciprofloxacin has an unsubstituted piperazine ring and levofloxacin and ofloxacin have a 4-methyl piperazine at position 7, there is great variability at position 7 in other fluoroquinolones.^{28,29} Despite some similarities in structure, the association of LCV with ciprofloxacin, ofloxacin and levofloxacin may also be attributed to their predominant use in clinical practice.

For all reported cases in the literature, the duration of fluoroquinolone therapy was 4-10 days. Many were clinically diagnosed without histological confirmation, but they reveal a theme of recovery following withdrawal of the agent as seen in our case. Cutaneous vasculitis may be limited to skin which offers a better prognosis, but can involve other organs with small-vessels including the kidney,³⁰ as has been reported in one case report involving ciprofloxacin²⁰ and another involving levofloxacin.²⁶ In comparison to previous reports of levofloxacin-induced vasculitis, our case had several additional elements that may have con-

tributed to the patient's risk of developing LCV. Following review of medical records, the patient had previously been prescribed 2 courses of ciprofloxacin, eight months and five years prior to his course of levofloxacin, with no reported adverse effects. It is not known whether previous courses of ciprofloxacin could have been sensitizing events for later development of LCV upon challenge with levofloxacin. Levofloxacin was noted as an allergy in the patient's medical record and the patient was counseled to avoid fluoroquinolones in the future.

Conclusion

Consistent with previous case reports involving ciprofloxacin and ofloxacin, levofloxacin was a probable cause of LCV in our patient according to the Naranjo adverse drug reaction probability scale.⁷ As in previous case reports, our patient had a full recovery with prednisone treatment and withdrawal of levofloxacin. Recognition of drug-induced vasculitis is critical as LCV can be life-threatening without discontinuation of the offending agent. Review of current literature shows that LCV has been associated with fluoroquinolones including ciprofloxacin, ofloxacin, and levofloxacin, but has yet to be reported in association with other agents in the fluoroquinolone class.

References

- Carlson JA, Cavaliere LF, Grant-Kels JM. Cutaneous vasculitis: diagnosis and management. *Clin Dermatol* 2006;24:414-29.
- Chen KR, Carlson JA. Clinical approach to cutaneous vasculitis. *Am J Clin Dermatol* 2008;9:71-92.
- Carlson JA. The histological assessment of cutaneous vasculitis. *Histopathology* 2010; 56:3-23.
- Maunz G, Conzett T, Zimmerli W. Cutaneous vasculitis associated with fluoroquinolones. *Infection* 2009;37:466-8.
- Gibson LE, Su WP. Cutaneous vasculitis. *Rheum Dis Clin North Am* 1995;21:1097-113.
- Gibson LE. Cutaneous vasculitis update. *Clin Dermatol* 2001;19:603-15.
- Naranjo CA, Busto U, Sellers EM. A method for estimating the probability of adverse drug reactions. *Clin Pharmacol Ther* 1981; 30:239-45.
- Schaeffer AJ. The expanding role of fluoroquinolones. *Am J Med* 2002;113:45S-54S.
- Garrison J, Hooton TM. Fluoroquinolones in the treatment of acute uncomplicated urinary tract infections in adult women. *Expert Opin Pharmacother* 2001;2:1227-37.
- Noreddin AM, Elkhatib WF. Levofloxacin in the treatment of community acquired pneumonia. *Expert Rev Anti Infect Ther* 2010;8:505-14.
- Bolon MK. The newer fluoroquinolones. *Infect Dis Clin N Am* 2009;23:1027-1051.
- Liu, Hans H. Safety profile of the fluoroquinolones focus on levofloxacin. *Drug Safety* 2010;33:353-69.
- Owens RC, Ambrose PG. Antimicrobial safety: focus on fluoroquinolones. *Clin Infect Dis* 2005;41:S144-57.
- Ball P. Quinolone generations: natural history or natural selection? *J Antimicrob Chemother* 2000;46:17-24.
- Frothingham R. Rates of torsades de pointes associated with ciprofloxacin, ofloxacin, levofloxacin, gatifloxacin, and moxifloxacin. *Pharmacotherapy* 2001;21: 1468-72.
- Owens RC, Ambrose PG. Torsades de pointes associated with fluoroquinolones. *Pharmacotherapy* 2002; 22:663-72.
- Choe U, Rothschild BM, Laitman L. Ciprofloxacin-induced vasculitis (Letter). *N Engl J Med* 1989;320:257.
- Stubbings J, Sheehan-Dare R, Walton S. Cutaneous vasculitis due to ciprofloxacin. *Br Med J* volume 1992;305:29.
- Lieu PK, Tok SC, Ismail NH, Chng HH. Ciprofloxacin-induced cutaneous vasculitis. *Allergy* 1997;52:593-600.
- Storsley L, Gerdenhuys L. Ciprofloxacin-induced ANCA-negative cutaneous and renal vasculitis-resolution with drug withdrawal. *Nephrol Dial Transpl* 2007;22:660-72.
- Huminer D, Cohen J, Majadla R, Dux S. Hypersensitivity vasculitis due to ofloxacin. *Br Med J* 1989;299:303.
- Pace JL, Gatt P. Fatal vasculitis associated with ofloxacin. *Br Med J* 1989;299:658.
- Berrin BC, Lawrence R, Sungur M, et al. Ofloxacin-induced vasculitis. *Internal Medicine* 1995;34:872-4.
- Pipek, Ruben, et al. Ofloxacin-induced hypersensitivity vasculitis. *Am J Med Sci* 1996; 311:82-3.
- Famularo G, De Simone C. Nephrotoxicity and purpura associated with levofloxacin. *Ann Pharmacother* 2002;36:1380-2.
- Zaigraykin N, Kovalev J, Elias N, Naschitz J. Levofloxacin-induced interstitial nephritis in an elderly woman. *Isr Med Assoc J* 2006;8:726-7.
- Walker RC. The fluoroquinolones. *Mayo Clin Proc* 1999;74:1030-7.
- Van Bambeke F, Michot JM, Tulkens PM. Quinolones in 2005: an update. *Clin Microbiol Infect*. 2005;11:256-80.
- Appelbaum PC, Hunter PA. The fluoroquinolone antibacterials: past, present, and future perspectives. *Int J Antimicrob Agents* 2000;16:5-15.
- Gonzales-Gay MA, Garcia-Porrúa C, Pujol RM. Clinical approach to cutaneous vasculitis. *Current Opin Rheumatol* 2004;17: 56-61.