

ORIGINAL ARTICLE

Congenital Pouch Colon: A Preliminary Report from Pakistan

Bilal Mirza,* Sarfraz Ahmad, Afzal Sheikh

Department of Pediatric Surgery, The Children's Hospital and the Institute of Child Health Lahore, Pakistan.

ABSTRACT

Background: Congenital pouch colon (CPC) is a rare entity in patients of anorectal malformations (ARM) requiring special consideration as to the management. This study is aimed at evaluating the presentation, management, and the outcome of initial surgery in patients with CPC.

Materials & Methods: This retrospective study was conducted in the department of Pediatric Surgery of our institute during May 2007- May 2010. The Information about the demography, clinical features, investigations, management, and the outcome of initial surgery was retrieved and analyzed.

Results: There were 21 patients of CPC managed during the study period. Sixteen (76%) were males and five (24%) females (M:F 3.2:1). Mean age of presentation was 4.8 days with a range of 12 hours to 45 days. In 18 (85.7%) patients, CPC was found with high ARMs, whereas, in 3 (14.3%) patients it was associated with low ARMs. Imperforate anus with moderate to massive abdominal distension was the presentation in 16 (76%) patients. Abdominal radiographs helped in preoperative diagnosis in 8 patients. Two patients had pneumoperitoneum on abdominal radiographs. At operation, type I CPC was found in 9 (42.8%) patients, type II in 5 (23.8%), type III in 2 (9.5%) patients, and type IV CPC in 5 (23.8%) patients. In 11 (52.4%) patients, pouch was emptied and retained with proximal enterostomy. In 7 (33.3%) patients, end enterostomy with pouch excision was done. In two patients, a window colostomy was formed. In one patient, pouch was disconnected from the normal bowel and Hartmann's pouch with end ileostomy was formed. There were 2 (9.5%) deaths in our series.

Conclusion: CPC is a rare malformation. Massive abdominal distension with imperforate anus is the common presentation. Optimum management can reduce the morbidity and mortality.

Key words: Imperforate anus, congenital pouch colon, urogenital anomalies

INTRODUCTION

Congenital pouch colon is a variant of ARM, characterized by replacement of a variable length of normal colon by a pouch like structure associated with short length of the total colon along with fistulous communication with the genitourinary system. Interestingly, the entity has a special predilection for the northern

areas of India and most of the literature regarding its embryology, etiology, anatomy, and management has been reported from the same region [1]. Sporadic cases or case series have been documented from rest of the world [2].

In Pakistan, a term "football colon" is attributed to complete congenital pouch colon. The condition is equally prevalent in Pakistan; however,

* Corresponding Author

no published literature on case series could be retrieved in spite of extensive search. Herein, we present our experience of managing the index entity in a tertiary care centre of Pakistan. The objective of the study was to identify various presentations, management provided, and the outcome of these patients in our hospital.

MATERIALS AND METHODS

This is a retrospective review of patients of CPC, managed in the department of Pediatric Surgery, The Children’s Hospital and the Institute of Child Health Lahore, Pakistan; during May 2007 through May 2010. The medical record of these patients was reviewed for demographic information, clinical features, investigations performed, operative notes, postoperative events, and the outcome of initial surgery. For descriptive purpose, CPC was classified into 4 types as per Rao et al classification (Table 1) [4].

Table 1: Classification of Pouch colon as per Rao et al [4].

Type	Description
Type I	Ileum directly opens into the pouch colon- no normal colon available
Type II	Cecum is present and rest of colon is in pouch configuration
Type III	Considerable length of normal colon is present proximal to pouch colon.
Type IV	Only sigmoid colon and rectum are in the shape of pouch colon, rest of colon is normal.

RESULTS

Demography: Of the 312 cases of ARM, 21 (6.73%) had associated pouch colon, male: female ratio being 3.2:1 (16 males and 5 fe-

males). The age of initial presentation ranged between 12 hours and 45 days with a mean of 4.8 days (SD ±9.8). The mean weight at presentation was 2.3 kg (SD±0.43) with a range of 1.8kg to 3.8kg.

Presentation: Nine patients presented with imperforate anus and abdominal distension. Table 2 describes clinical presentation of the study group. Of 21 patients, 18 (85.7%) were associated with high variety ARM and 3 (14.3%) with low ARM.

Investigations: In 8 (38%) patients abdominal radiograph (erect and invertogram) delineated typical findings consistent with the diagnosis of CPC (Fig.1). Air vesicogram and pneumoperitoneum was noted on radiographs in two patients each. Ultrasound was diagnostic of CPC in 5 patients only (23.8%).

Operation: All the 21 patients underwent preliminary operations. Eight (38%) patients underwent exploratory laparotomy through a right supra-umbilical transverse incision. They all belonged to high ARM and were diagnosed preoperatively. In rest of the patients, preoperative diagnosis could not be made.

In 13 (62%) patients, CPC was diagnosed during colostomy formation. In 3 of these 13 patients, cecum was found in the left iliac region while constructing colostomy for ARM (Fig. 2,3); In another patient with colostomy for cloaca, type IV CPC was found on re-exploration for massive mucosal prolapse. In 9 patients, ileum directly opened into the pouch colon (Type I CPC). Various types of CPC encountered in the study population are tabulated here (Table 3).

Table 2: Showing clinical presentation with respect to frequency, proportions and gender.

Clinical presentation with respect to frequency and gender			
Male		Female	
Presentation	Frequency	Presentation	Frequency
Imperforate anus with abdominal distension	9	Cloaca and abdominal distension	2
Imperforate anus with meconuria and abdominal distension	7	Vestibular fistula + intractable constipation + abdominal distension	1
		Vestibular fistula + perineal rashes + abdominal distension	1
		Anteriorly placed anus + abdominal distension + intractable constipation	1

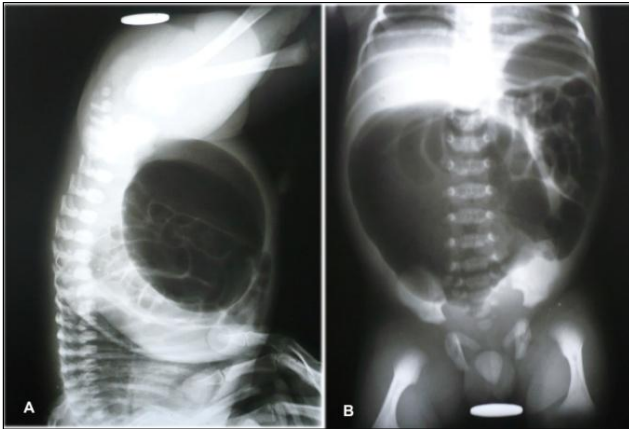


Figure 1: (A) Abdominal radiograph (invertogram) showing a large loop of bowel filled with meconium and air, occupying more than half of the abdominal cavity. (B) Erect radiograph of the same patient.

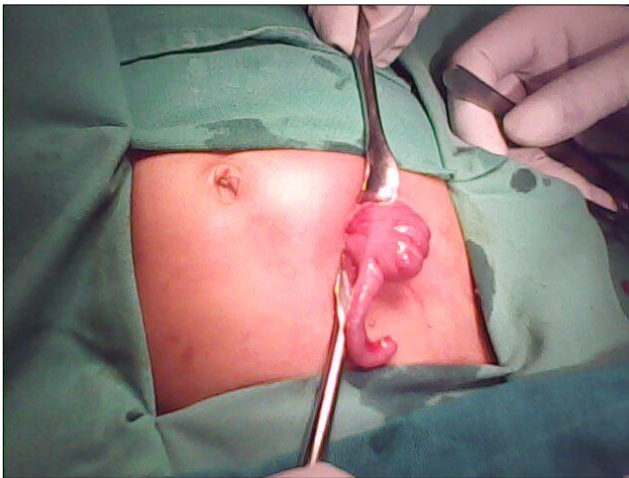


Figure 2: Cecum and appendix lying at abnormal position, observed during colostomy formation in a patient of ARM that later proved to have type IV CPC.

In two patients with type I CPC, there was perforation of the pouches at lower end of CPC (Fig.4,5).

In all the male patients there was a fistula with the posterior wall of urinary bladder (Fig. 6), whereas in female patients the fistula was with the cloaca in 2, and with vestibule in 2, and in one patient the pouch was continuous with anteriorly placed anus.

Table 3: Types of CPC as per Rao et al with type of ARM.

Type of CPC	Frequency	Type of ARM
Type I	9	High
Type II	5	High
Type III	2	High
Type IV	5	Low /high, 3/2

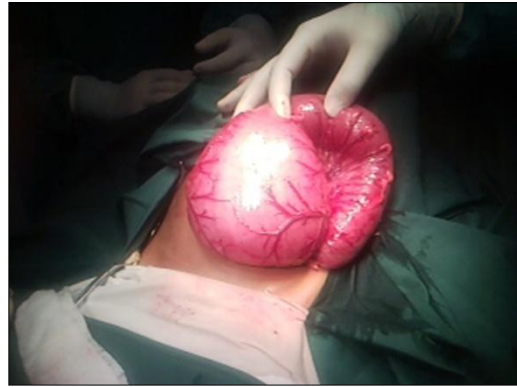

Figure 3: Pouch colon in another patient in whom cecum and appendix were observed in left iliac region.

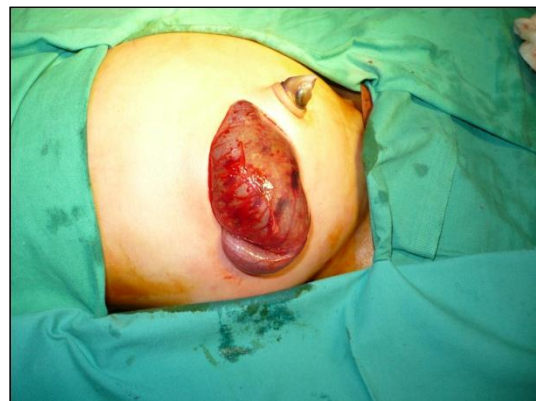

Figure 4: Operative view of Type I CPC; the ileum is directly opening into the CPC from right side.

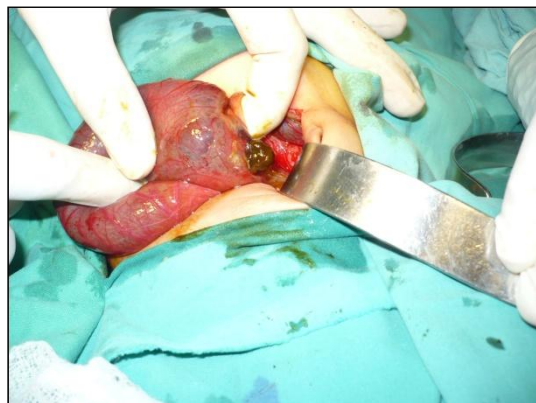

Figure 5: Operative view of a Type I CPC which was perforated at one side.

In 4 of 9 patients with type I CPC, the pouch was emptied and retained with proximal ileostomy. In 3/9 patients with type I CPC the pouch was excised with end ileostomy. In 1 critical patient with type I pouch colon, the pouch was exteriorized as window colostomy. In one patient with type I CPC, the pouch was disconnected from the normal bowel and Hartmann's pouch with end ileostomy was formed.

The surgical treatment in the rest of study group is tabulated as under (Table 4).

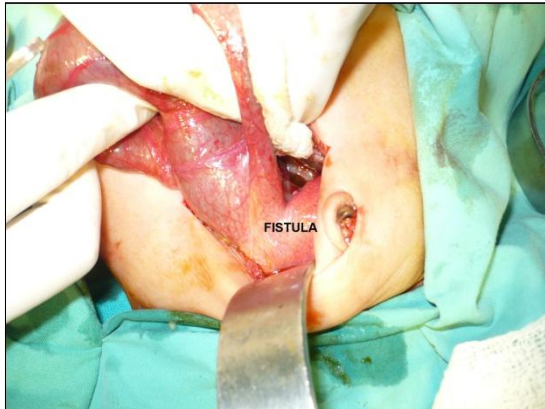


Figure 6: Operative view of a long and wide fistula with the posterior wall of urinary bladder.

Table 4: Summary of surgical procedures.

Type I CPC	
Initial Procedure	Frequency
Proximal ileostomy (pouch retained)	4
Pouch excision and end ileostomy	3
Window colostomy	1
End ileostomy with Hartmann pouch	1
Type II CPC	
Initial Procedure	Frequency
Proximal ileostomy (pouch retained)	3
Pouch excision and end ileostomy	1
Window colostomy	1
Type III CPC	
Initial Procedure	Frequency
Pouch excision and end colostomy	2
Type IV CPC	
Initial Procedure	Frequency
Proximal colostomy (pouch retained)	4
Pouch excision and end colostomy	1

Associated Anomalies: Associated anomalies were mainly from genitourinary and gastrointestinal tract. Malrotation was observed in 5 patients, hydroureter in 2, and left renal agenesis in 1 patient. Table 5 describes the associated anomalies encountered in our series.

Complications: Postoperative complications encountered during initial surgery were wound infection in 4, mild wound dehiscence in 2, and enterostomy prolapse in 3 patients. The mortality in our series was 9.5% (2 patients); both the patients were critically sick since the presentation and one patient had associated esophageal atresia and tracheoesophageal fistula.

Table 5: Showing frequency of associated anomalies

Associated anomalies	Frequency
Malrotation	5
Hydroureter	2
Vesicoureteric reflux	2
Meckel's diverticulum	1
Esophageal atresia and TEF	1
Duplex appendix	1
Renal agenesis	1
Undescended testes	1
Lumbar hernia	1
Scoliosis	1
Bicornuate uterus	1
Vaginal septum	1

DISCUSSION

The incidence of CPC in our series was 6.73% of all the cases of ARM. The reported incidence of CPC in other series from India lies between 5-18% of all the cases of ARM [1-4]. The incidence of CPC in the western world is less than 1%. The exact incidence of this anomaly in Pakistan cannot be commented on as to scarce published data from this country. Similarly the sex distribution (M:F = 3.2:1) in our study was also in agreement with the reported male to female ratio (3-7:1) [1-7].

The presentation may be early or delayed depending upon gender, size of fistula and the type of the CPC. In males, massive abdominal distension with imperforate anus during first or second day of life is the usual early presentation, however in case of a wide fistula the patient may be decompressed and present with mild abdominal distension and muconuria. The presentation in females is usually delayed to their early infancy with intractable constipation, recurrent attacks of enterocolitis and persistent abdominal distension. The delayed presentation in females correlates with the type of ARM; the patients with associated cloaca usually present early as compared to vestibular fistula or other low ARM, where they are deliberately deferred to some later age for definitive surgery [1,5-8]. Two out of 5 female subjects with CPC in our series had presented early with cloaca. Of the other 3 patients, 2 presented

with intractable constipation and one patient with perineal rashes due to recurrent attacks of enterocolitis and soiling of fecal matter. All the male patients presented early.

Preoperative diagnosis of CPC can be easily made with the help of radiographs (erect and invertogram). A large loop of bowel filled with air and meconium, occupying more than half of the abdominal cavity, is usually diagnostic of CPC in a patient with ARM. Sometimes additionally air vesicogram may be evident on radiographs [9]. In our series abdominal radiographs were performed in 10 patients that showed typical features of CPC in 8 and pneumoperitonium in 2 patients. In male patients with visible meconuria, and in female patients with common channel, radiographs were not performed on account of the clinical features depicting their type of ARM and straightforward decision of colostomy.

In the index study, type I CPC is frequent variety which corroborates with the previously published series [4,10-12]. The recent studies however documented type IV CPC being more prevalent than Type I or II varieties. This can be attributed to an increased awareness of the entity as to its morphology, pathology, and management in the evolving years [1,2,8].

The fistula with the genitourinary tract is characteristic of the index entity. Fistulous communication in males occurs with the urinary tract most often with the urinary bladder [1,9,13] as in our series, and in females the site of fistula varies from perineum to the vestibule to the cloacal malformation [5-7].

A number of genitourinary and gastrointestinal anomalies have been associated with CPC. Most common anomalies are hydroureteronephrosis, vesicouretric reflux, renal dysplasia/agenesis, bicornuate uterus, hypospadias, followed by malrotation, and appendicular duplex or agenesis, and prune belly syndrome [1,14]. In our series, 11 patients had associated anomalies, the commonest being malrotation. In one female patient of type IV CPC (anteriorly placed anus) there was associated scoliosis and lumber hernia.

CPC can be managed as a primary one stage procedure or as staged procedure. Single stage procedure ideally consists of repair of fistula, excision of the pouch, and primary abdominoperineal-PSARP/pull through [1,12]. Multi-staged procedures are variable and range from merely window colostomy to complete excision of CPC, repair of the recto-vesical fistula, and end enterostomy in the first stage followed by pull through of the normal bowel with/without covering enterostomy as a second stage procedure. Initially single stage procedures were not considered safe but recent reports emerged with good results. Pouch colon patch over the pulled through segment is also advocated [1,12, 16-19]. Window colostomy is indicated in critical patients, but it is often associated with high morbidity and mortality. The problems with window colostomy are massive mucosal prolapse, urinary tract infections, incomplete emptying of the CPC resulting in persistent abdominal distension etc. [1]. The outcome in CPC has improved with mortality reduced from >40% to less than 10% [1,5].

To summarize, CPC is rare malformation in patients of ARM though the incidence in the Asian subcontinent is higher than in the western world. Imperforate anus with massive abdominal distension is a common presentation of this anomaly. An erect plain abdominal radiograph is diagnostic and should be done in all patients of ARM with abdominal distension. If one encounters cecum and appendix in the left lower quadrant while colostomy formation for ARM, it is mandatory to look for CPC.

REFERENCES

1. Gupta DK, Sharma S. Congenital pouch colon - Then and now. *J Indian Assoc Pediatr Surg.* 2007; 12: 5-12.
2. Bhat NA. Congenital pouch colon syndrome: A report of 17 cases. *Ann Saudi Med.* 2007; 27: 79-83.
3. Gupta DK. Congenital pouch colon: Present lacunae. *J Indian Assoc Pediatr Surg.* 2007; 12: 1-2.
4. Narsimha Rao KL, Yadav K, Mitra SK, Pathak IG. Congenital short colon with imperforate anus (pouch colon syndrome). *Ann Pediatr Surg.* 1984; 1: 59.
5. Sarin YK, Nagdeve NG, Sengar M. Congenital pouch colon in female subjects. *J Indian Assoc Pediatr Surg.* 2007; 12: 17-21.

6. Chadha R, Gupta S, Mahajan JK, Bagga D, Kumar A. Congenital pouch colon in females. *Pediatr Surg Int.* 1999; 15: 336-42.
7. Gharpure V. Our experience in congenital pouch colon. *J Indian Assoc Pediatr Surg.* 2007; 12: 22-4.
8. Pavai A, Pillai SD, Shanthakumari S, Sam CJ, Shylaja M, Sabarivinoth R. Congenital pouch colon: Increasing association with low anorectal anomalies. *J Indian Assoc Pediatr Surg.* 2009; 14: 218-20.
9. Mirza B, Ijaz L, Sheikh A. Congenital pouch colon. *Ann Saudi Med.* 2011; 31: 546-7.
10. Wakhlu AK, Wakhlu A, Pandey A, Agarwal R, Tandon RK, Kureel SN. Congenital short colon. *World J Surg.* 1996; 20: 107-14.
11. Budhiraja S, Pandit SK, Rattan KN. A report of 27 cases of congenital short colon with an imperforated anus: So called 'pouch colon syndrome'. *Trop Doctor.* 1997; 27: 217-20.
12. Gangopadhyay AN, Shilpa S, Mohan TV, Gopal SC. Single-stage management of all pouch colon (anorectal malformation) in newborns. *J Pediatr Surg.* 2005; 40: 1151-5.
13. Mirza B, Ijaz L, Zaman M, Sheikh A. Congenital pouch colon with ileovesical and colovesical fistulae: A new variant. *J Indian Assoc Pediatr Surg.* 2011; 16: 167-8.
14. Baba AA, Hussain SA, Shera AH, Patnaik R. Prune belly syndrome with pouch colon and absent dermatome. *Afr J Paediatr Surg.* 2010; 7: 25-7.
15. Ratan SK, Rattan KN. "Pouch colon patch graft": An alternative treatment for congenital short colon. *Pediatr Surg Int.* 2004; 20: 801-3.
16. Gupta DK. Anorectal malformations-Wingspread to Krickenbeck. *J Indian Assoc Ped Surg.* 2005; 10: 79.
17. Luzzatto C, Zanardao V, Guglielmi M. Imperforate anus with congenital short colon: Combined abdominal and posterior sagittal approach. *Pediatr Surg Int.* 1990; 5: 375-6.
18. Sharma AK, Harjai MM. Simplified colorrhaphy and posterior sagittal anorectoplasty for the management of congenital short colon with imperforate anus. *Br J Surg.* 1997; 84: 389.
19. Puri A, Chadha R, Choudhury SR, Garg A. Congenital pouch colon: Follow-up and functional results after definitive surgery. *J Pediatr Surg.* 2006; 41: 1413-9.

Address for correspondence

Muhammad Bilal Mirza,
428 Nishter Block, Allama Iqbal Town Lahore, Pakistan.

E mail: blmirza@yahoo.com

© Mirza et al, 2012

Submitted on: 15-04-2012

Accepted on: 30-05-2012

Published on: 01-07-2012

Conflict of interest: The first author is a Joint Editor of the journal. But he did not take part in the evaluation or decision making of this manuscript. The manuscript has been independently handled by two other editors.

Source of Support: Nil



This work is licensed under a [Creative Commons Attribution 3.0 Unported License](http://creativecommons.org/licenses/by-sa/3.0/)

Available at <http://www.jneonatsurg.com>

How to cite:

Mirza B, Ahmad S, Sheikh A. Congenital pouch colon: a preliminary report from Pakistan. *J Neonat Surg* 2012; 1: 37.