

Review article

ENDOFTALMITIS*Dragan Veselinović and Aleksandar Veselinović*

Endophthalmitis is one of the most urgent conditions in ophthalmology, characterized by the inflammation of the anterior and posterior eye segments, occurring as the consequence of bacterial or fungal infections. The paper presents the clinical manifestations of endophthalmitis, classifications of endophthalmitis in respect to etiological and other factors which can cause this condition. A special emphasis is given to the occurrence of endophthalmitis after cataract surgery. In addition, the paper presents the clinical features of post-traumatic, endogenous and fungal endophthalmitis cases, as well as the risk factors for the occurrence of post-operative endophthalmitis, the importance of post-operative endophthalmitis prevention, with given recommendations for appropriate prophylaxis. Great importance was attached to the therapy of acute endophthalmitis based on the recommendations of the European Society of Cataract and Refractive Surgery. *Acta Medica Medianae* 2009;48(1):56-62.

Key words: *endophthalmitis, etiology, prophylaxis, therapy*

Contact: Dragan Veselinović
Ophthalmology Clinic, Clinical Center Niš

Bulevar Zorana Đinđića 48
18000 Niš, Serbia
E-mail: veselinovicdr@yahoo.com

Introduction

Endophthalmitis is characterized by the inflammation of the anterior and posterior eye segments, occurring as the consequence of bacterial or fungal infections.

Some authors define it as bacterial or fungal infections of the vitreous body and eye chamber fluid. It is never caused by viral or parasitic infections, as these agents primarily cause the inflammation of the retina and uvea, causing retinitis and uveitis (1-3).

The majority of endophthalmitis cases is caused by bacteria, and appears in the acute form. The presence of acute endophthalmitis stands for one of the most urgent conditions in ophthalmology.

Experience has shown that majority of endophthalmitis cases is of exogenous origin, occurring as the consequence of intraocular surgery (62%), after penetrating eye injuries (20%), as a complication after filtration anti-glaucoma surgeries (10%), while smaller number of cases has been described to occur after performing other surgeries (keratoplasty, vitrectomy, secondary intraocular lens implantation). Only 2-8% of endophthalmitis cases are thought to be the consequence of endogenous infection (4,5).

Endogenous or metastatic endophthalmitis cases occur when primary site of infection is located anywhere in the organism, via migration of the infectious agent through hematogenous pathways to the eye. Endogenous endophthalmitis cases are usually caused by fungal infections (62%);

bacterial infections usually occur after the action of gram-positive bacteria (33%) compared to gram-negative bacteria (5%) (6-8).

Clinical manifestations depend on the virulence of infectious agent, host immune status and speed of the adequate therapy.

Endophthalmitis can be divided into six categories:

- Acute endophthalmitis after cataract surgery;
- Chronic pseudo-endophthalmitis;
- endophthalmitis after filtration anti-glaucoma surgeries;
- post-traumatic endophthalmitis;
- endogenous endophthalmitis, and
- fungal endophthalmitis

Postoperative endophthalmitis

This group of endophthalmitis cases comprises acute and chronic endophthalmitis after cataract surgery, endophthalmitis after filtration anti-glaucoma surgeries, infrequent, yet present endophthalmitis cases after secondary intraocular lens implantation into the aphakic eye, after keratoplasty and vitreoretinal surgery. The highest frequency of post-operative endophthalmitis cases is after cataract surgery, as that is the most frequent operation in ophthalmology, ranging from 0.01 to 0.3%.

The second place by the occurrence frequency is occupied by endophthalmitis cases after filtration glaucoma surgeries (0.1%). The incidence of postoperative endophthalmitis after perforating keratoplasty ranges from 0.08% to 0.2%, while the occurrence of endophthalmitis after vitreoretinal surgery was reported in 0.05-0.14 patients (3,4,9,10).

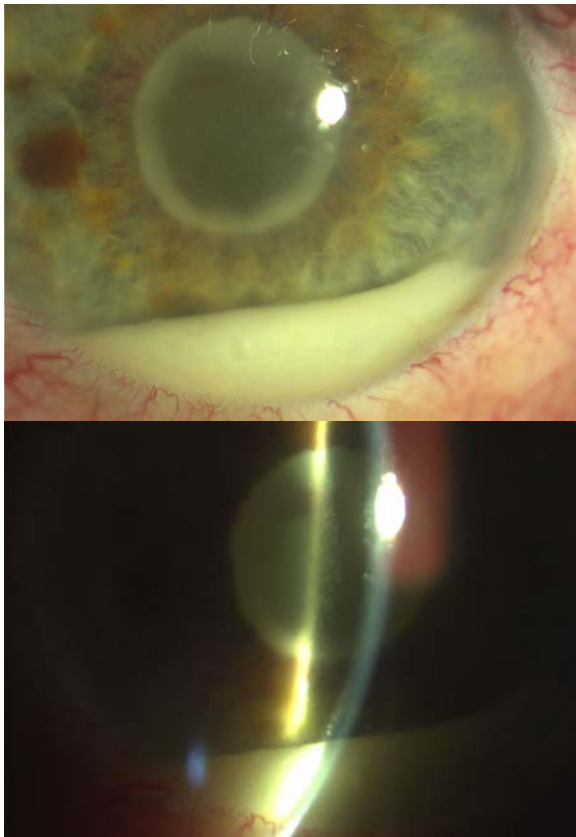
This group of endophthalmitis cases is usually caused by bacterial infection, in the event of which the signs of inflammation appear after the incubation phase.

Mean time of the incubation of bacteria in the eye is 16-18 h, but it definitely depends on the species of bacteria. It is considered that *Staphylococcus aureus* and *Pseudomonas aeruginosa* give the first signs of inflammation quite soon, even after 10 minutes. As for *Propionibacterium*, the first signs appear after 5 hours, and *Staphylococcus aureus* and *Staphylococcus epidermidis* three days after the infection (11,12).

Acute endophthalmitis after cataract surgery

It stands for the most frequent form of endophthalmitis, and is almost always caused by bacterial infection. The signs of infection can appear within six weeks from the operation; however, in 75-80% of cases they appear in the first postoperative week.

Around 56-90% of bacteria causing acute endophthalmitis are gram-positive, of which the most frequent are *Staphylococcus epidermidis*, *Staphylococcus aureus* and *Streptococcus*. Gram-negative bacteria account for 7-29% of endophthalmitis cases, and *Proteus aeruginosa* and *Haemophilus* have been reported as the most frequent agents (2,9,12,13).



Endophthalmitis in pseudophakic eye

Endophthalmitis in pseudophakic eye

Data on frequency of acute endophthalmitis after cataract surgery using modern methods of phaco surgery vary, but in the recent years, despite applying modern measures, it has equalled 0.1%. The majority of studies indicate that there is no significant difference in the frequency of

endophthalmitis in patients with extracapsular cataract extraction and phacoemulsification surgery (14-16).

Clinical characteristics of acute endophthalmitis after cataract surgery are manifested by the appearance of pain and unexpected decrease in visual acuity, followed by eyelid swelling of various degree as well as marked signs of ciliary hyperemia and photophobia.

The appearance of infiltration and corneal precipitation, along with marked signs of fibrinous exudate and hypopyon, also represent the characteristic signs of endophthalmitis. Eye pain and hypopyon occur in 75% of cases. Fibrinous exudate is especially visible in the iris, and is usually associated with the appearance of posterior synechiae (1-3).

Frequent clinical signs are the loss of afferent pupillary reflex, presence of blur in the vitreous body (vitritis) of various degree, which usually cause the loss of red reflex. In cases when transparency of vitreous body is preserved, the occurrence of retinitis, periphlebitis, retinal edema, as well as inflammatory edema of the optic nerve papilla can be noted on the fundus (3,6,9).

Marked signs of inflammation can be noted on the cornea, anterior chamber, lens and vitreous body, in the situation of which the retina is usually hard to reach for examination. The inflammation which affects the structures of trabeculum and ciliary body can cause secondary glaucoma, or vice versa, it can lead to ocular hypotony.

The most serious problem arises because of the damage of neurosensory retina and retinal pigment epithelium, which can cause the permanent damage of the basic photochemical processes in vision formation.

While retina is richly vascularized, the vitreous body and anterior chamber are avascular and separated from systemic circulation by blood-ocular barrier, the existence of which poses barrier not only to cellular and humoral mediators of inflammation but also to the action of many antimicrobial and anti-inflammatory drugs administered systemically. Another problem is the sensitivity of retinal photoreceptor cells to drugs directly applied into the vitreous body. These cells are extremely sensitive not only to pathogenic agents which cause inflammation but also to high doses of antibacterial agents applied locally for infection treatment (11).

Nowadays, intravitreal antibiotic application is considered to be the most important therapy option in the treatment of endophthalmitis. Therefore, it is of vital importance to determine the concentration of antibiotics which will produce the corresponding therapeutic effect, without having toxic effects on the retinal photoreceptors. Three most used antibiotics for intravitreal administration are Vancomycin (9.1 mg), Amikacin (0.4 mg) and Ceftazidim (2.2 mg). Recently, many authors have preferred Ceftazidim to Amikacin, having in mind possible aminoglycoside toxic effects. In practice, usually two antibiotics are applied in combination with

Vancomycin and Amikacin, or Vancomycin and Ceftazidim (18,19).

In that way, antibiotics such as Amikacin and Ceftazidim, act against gram-positive and gram-negative bacteria, while the application of Vancomycin provides the effects on coagulase-positive and coagulase-negative Cocci. The application of topical antibiotic therapy is equally meaningful, especially when the mechanisms of blood-ocular barrier change during inflammation. In practice, gentamicin and vancomycin eye drops are frequently applied, every 30-60 min, and in the recent years there has been a focus on the application of the third- and fourth-generation fluoroquinolones. In cases of suspected or proved fungal infection, Amfotericin B or Fluconazol should be included into the therapy.

Besides significant application of fluoroquinolones in the recent years, they are still used for intravitreal administration because of possible toxic effects.

Ocular inflammatory reaction to the presence of gram-positive bacteria is initiated by their growth and presence of metabolic products of the said bacteria. Intravitreal lipopolysaccharide injection induces inflammatory cell infiltration and moving of proteins into the chamber fluid. Antibiotics that initiate the changes in the permeability of the cell wall or its components can cause the enhanced intraocular inflammation during the treatment of endophthalmitis.

In laboratory settings, the treatment with antibiotics, which act at the level of cell membrane of *Bacillus subtilis*, induces the cell inflammation and results in the loss of retinal electrical response. This condition is described as «antibiotic-induced inflammation phenomenon» (11).

The treatment of endophthalmitis also points to benefits from the application of systemic therapy and corticosteroids. Intravitreal corticosteroid application is still controversial; however, the experimental model showed that intravitreal administration of dexamethasone associated with the application of antibiotics gives positive therapeutic effects (20, 21).

Even though the intravitreal application of antibiotics provides good recovery in majority of cases, in advanced cases vitrectomy is quite indispensable.

Surgical fragmentation and suction of vitreous body and its replacement by balanced solution, provides removal of bacteria, inflammatory cells and toxic substances from the inner eye structures. Also, during surgery, it is possible to remove, with antibiotic infusion, inflammatory membranes, to provide better visualization of retina as well quick vision recovery (4, 10).

Chronic pseudophakic endophthalmitis

Chronic endophthalmitis in the pseudophakic eye usually develops one month after the surgery, or, according to some definitions, after six weeks. Usually, a patient notices mild or moderate signs of eye redness, decreased visual acuity and pronounced photophobia. In the anterior chamber, the signs of serous and fibrinous exudate of

various degrees can be observed, associated with the presence of hypopyon and moderate signs of blur and opacity in the vitreous body (22).

Specificity of chronic pseudophakic endophthalmitis is the presence of white capsular plaques and proportionally lower degree of blur in the vitreous body compared to acute endophthalmitis.

It is considered that the cause of chronic pseudophakic endophthalmitis is the presence of some bacteria having low virulence, with delayed signs of inflammation. The most frequent causes of chronic endophthalmitis are *Propionibacterium acnes* and *Corynebacterium* species.

As in case of acute endophthalmitis, it is necessary to establish correct diagnosis based on detailed clinical examination and ultrasound findings, as there are numerous conditions with similar characteristics (23). It is further recommended to perform the puncture of the anterior chamber and sampling of the chamber fluid for microbiological analysis. In cases of marked vitritis, it is necessary to perform the puncture of the vitreous body for establishing more precise diagnosis. If therapy is ineffective, it is indispensable to excise the implanted intraocular lens and send it to appropriate bacteriological analysis.

In the therapy of chronic endophthalmitis, the administration of erythromycin is recommended. Clarithromycin 250 mg per day in duration of two weeks is very effective, as is characterized by good penetration into the vitreous body and acting against gram-positive bacteria and haemophilus. If good anti-inflammatory response is not obtained, the removal of intraocular lens is recommended as well as vitrectomy combined with posterior capsulotomy. Before making this decision, intravitreal application of vancomycin and cefazolin is possible in duration of one week.

Endophthalmitis following filtration antiglaucoma surgeries

Among all cases of postoperative endophthalmitis, this complication occurs after filtration glaucoma surgery in 10% of cases. Of the total number of cases with filtration glaucoma surgery, endophthalmitis occurs in similar percentage as in cataract (0.1%). Trabeculectomy and trepan-trabeculectomy, as the most usual surgical methods, mean the formation of filtration fistula which directs the chamber fluid under the conjunctiva. This fluid accumulation stands for a possible site of inflammation which can be caused by bacteria inoculation during the surgery, or can occur in the course of postoperative period when damages or cystic changes might appear on the conjunctiva (24).

The signs of endophthalmitis appear four weeks after surgery in 19% of patients, or even later in the majority of cases. Infection of the fluid accumulation can start one year following the surgery.

Clinical presentation is very similar to the one of acute endophthalmitis with the signs of purulent collection in the area of the fluid accumulation and necrotic damages of the sclera as the consequence of toxic effects. More frequently,

this kind of endophthalmitis occurs after the application of antimetabolites during the surgery or during wearing therapeutic contact lenses in the patients suffering from postoperative keratopathy. The most usual causative agents of this kind of endophthalmitis are *Streptococcus* and *Staphylococcus*, while the most frequent causative agent is *Haemophilus influenzae*.

The therapy for this kind of endophthalmitis is identical to the therapy for acute form of endophthalmitis.

Post-traumatic endophthalmitis

After penetrating eye injuries, endophthalmitis occurs in high percentage (20%), especially if these injuries are associated with the presence of intraocular foreign body. With the clinical finding of perforating injury, infection develops rapidly. The signs of infection usually develop soon after sustaining the injury, but are usually followed by post-traumatic reaction of the damaged eye tissue.

Very important information in anamnesis is whether the patient comes from rural or urban environment, as injuries in the rural environment are more frequently followed by endophthalmitis (30%) compared to the patients from urban environment (11%).

Clinically, post-traumatic endophthalmitis is characterized by pain, marked ciliary hyperemia, the appearance of hypopyon and blur in the vitreous body.

In cases of post-traumatic endophthalmitis, the most usual causative agents are bacteria from the groups of *Bacillus* and *Staphylococcus*. Similar to post-operative endophthalmitis cases, 2/3 of bacteria are from the group of gram-positive bacteria, while 1-15% belong to the group of gram-negative bacteria.

Contrary to post-operative endophthalmitis cases, the virulent bacterium *Bacillus* species is the most usual cause of post-traumatic endophthalmitis (20%). In the rural environment, this bacterium causes as high as 42% of post-traumatic endophthalmitis cases. This endophthalmitis is characterized by strong signs of inflammation and rapid loss of vision.

After ocular trauma, endophthalmitis can also be associated with fungal infection in 10-15% of cases. Fungal endophthalmitis cases usually develop one week to one month after sustaining injury, and can be associated with bacterial infection as well.

In post-traumatic endophthalmitis, especially with a foreign body present, it is essential to perform vitrectomy as soon as possible, with the removal of intraocular foreign body and application of proper antibiotic therapy (25, 26).

If intraocular foreign body is absent, the therapy is similar to the ones in acute post-operative endophthalmitis cases, but with considerably worse prognosis. Visual acuity of 0.2 or more can be attained in 26-54% of post-traumatic endophthalmitis cases, while in cases of post-operative endophthalmitis this percentage is noticeably higher (85%).

Endogenous endophthalmitis

In this form of endophthalmitis there is neither history of ocular surgery nor any eye trauma. What is usually present is some systemic disease exerting influence either through decreased defence host mechanisms or the presence of focus as a potential site of infection. In this group of patients, we registered the following: the presence of septicemia, patients with weaker immunity, chronic use of catheters and intravenous cannulas (6, 27).

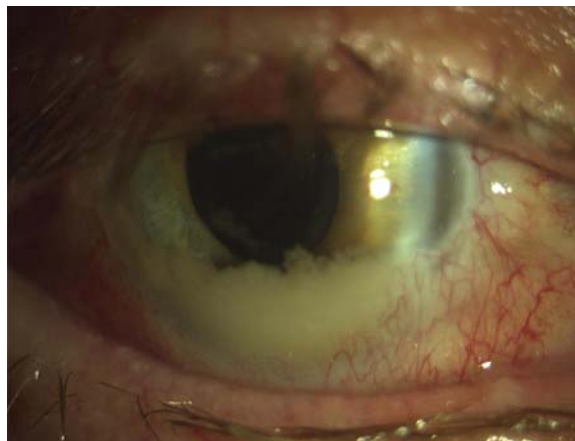
Bacterial agents are usually *Staphylococcus aureus*, *Escherichia coli* and *Streptococcus* species. However, the most frequent agents causing endogenous endophthalmitis are fungi (62%), gram-positive bacteria (33%), and gram-negative bacteria in 5% of cases.

Fungal endophthalmitis

Even though the main topic of this article is bacterial endophthalmitis, fungal endophthalmitis can be observed as a separate disease which, when joined with bacterial infection, can be very important for differential diagnosis and therapeutic procedures.

Fungal endophthalmitis can develop via endogenous mechanisms after some trauma or surgical procedure by direct inoculation into the anterior chamber or vitreous body, or by hematogenous transmission in the form of candidemia.

Unlike fungal chorioretinitis caused by candidiasis, which is accompanied with minimal signs of inflammation of the vitreous body, fungal endophthalmitis stands for a serious disease with characteristic signs of acute endophthalmitis (8).



Fungal endophthalmitis

Fungal endophthalmitis

The therapy for fungal endophthalmitis includes systemic antifungal therapy as well as the application of intravitreal injections of amphotericin B.

Risk factors for endophthalmitis

The vitreous body represents an extraordinary medium for development of bacterial infections. In the past, it was used for cultivating some bacterial cultures. Bearing this in mind, the appearance of bacteria in such environment is not desirable.

Surgical risk factors for endophthalmitis development are numerous: prolongation of the usual time of surgery, rupture of the posterior lens capsule and prolapse of the vitreous body, remnants of the lens fragments in the vitreous body, bad accumulation fluid in glaucoma surgery, inadequate sterilization of operative field as well as the contamination of surgical instruments and air in the operating theater.

The presence of a foreign body after penetrating injuries of the eyeball greatly increases the risk of endophthalmitis development.

Bacterial corneal ulcers can be a predisposing factor for development of endophthalmitis in 2-3% of all patients.

Also, endogenous endophthalmitis cases are the consequence of some risk factors which will enable the entrance of microorganisms into the circulation, such as: the use of immunosuppressive drugs, prolonged use of intravenous lines, puerperal sepsis, complications of abdominal surgery, malignancies, hemodialysis. Diseases of remote organs or some systemic diseases, such as: diabetes, cirrhosis, septic arthritis can also be the risk factors for endogenous endophthalmitis development.

Of the total number of patients with post-operative endophthalmitis, about 14-21% suffer from diabetes mellitus. It has been described that endophthalmitis in diabetic patients is more frequently caused by gram-negative bacteria compared to the non-diabetic population.

Some authors have added inadequate corneoscleral incision to the list of risk factors, pointing that the number of endophthalmitis cases has increased in the recent years, i.e. since corneal incision gained primacy over tunel scleral incision (15,28,29).

There are attitudes that endophthalmitis is more common after the implantation of silicon flexible lenses compared to acril lenses. It has been accepted that haptic intraocular lenses, which are made of polypropylene, more frequently cause inflammatory reactions as bacteria exhibit higher affinity towards these materials. It is well known that bacteria exhibit affinity towards fluorinated and heparin-coated PMMA lenses. Lately, the supremacy has been given to the implantation of flexible lenses by means of injector, in the case of which the risk of intraocular lens contamination is decreased.

Correlation between bacterial virulence and endophthalmitis

One of the most explosive, most prompt form of endophthalmitis is caused by *Bacillus cereus*. This bacterium is more commonly the cause of post-traumatic endophthalmitis. In 70% of endophthalmitis cases caused by *Bacillus cereus* there is a permanent vision damage, while 48% of cases end with evisceration and enucleation. Besides the administration of antibiotic therapy, there occurs an extremely strong inflammatory response which results in the loss of vision. This bacterium produces very strong toxin, Hemolysin BL, which contains three kinds of toxins (hemolytic, dermonecrotic and emetic).

Escherichia faecalis has been reported to cause about 4-8% of post-operative endophthalmitis cases; it is usually the consequence of infiltration glaucoma surgery. This bacterium exerts great toxic effect on the retina, producing extremely strong cytotoxin whose presence can cause a permanent photoreceptor damage within few hours (30-32).

A special problem in the therapy of endophthalmitis cases caused by *Escherichia faecalis* is high resistance of this bacterium to many antibiotics, even to vancomycin.

In practice, there occur some non-cytolytic forms of *Escherichia faecalis* with much better prognosis; they can be treated more successfully by intravitreal ampicillin, gentamycin with a simultaneous administration of dexamethasone.

Staphylococcus aureus is the most frequent cause of post-operative endophthalmitis cases, the prognosis of which is also poor in the sense of the eyesight function. *Staphylococcus aureus* produces several strong toxins being released during the decomposition of bacterial cell wall (protease, lipase, fibronectin, protein A). When these become free, considerable damages occur in the vitreous body, causing permanent vision loss.

Endophthalmitis prophylaxis

The seriousness and consequences which can be caused by endophthalmitis require the application of a wide scope of preventive procedures. A large number of studies have shown that the existence of infection in the adjacent tissue is the most common risk factor for endophthalmitis development. The study investigating the eyelid bacterial flora by the method of electrophoresis has revealed after examining 105 subjects the presence of various types of bacteria in 71 (67%) of them. There is a great possibility that this eyelid saprophytic bacterial flora can also be found in the anterior chamber during the cataract surgery (2, 7, 11).

Still, the most frequent infections are the following: chronic inflammation of the eyelid edges, chronic conjunctivitis, and chronic dacryocystitis. These results point to the necessity of preoperative taking conjunctival swab, with the aim of isolation, identification and determining the antibiogram in case of positive bacteriological finding.

Some authors recommend the rinsing of lacrimal canaliculi before cataract surgery in order to register chronic dacryocystitis cases. Nowadays, the opinions on the necessity of lacrimal canaliculi rinsing are divided, however, it is not recommended before surgery because of possible contamination by bacteria from the lacrimal sac.

In the large prospective study involving 700 patients operated for cataract, the analysis of the chamber fluid revealed the positive culture in 14.1% at the beginning of surgery, and 13.7% after the surgery. The most frequent bacteria were coagulase-negative *Staphylococcus* as well as corynebacteria. This and similar studies have showed that various bacteria can be found in the

anterior chamber during surgery, however, without further development of endophthalmitis (12-14).

Certain operative complications leading to the posterior capsule lesion and vitreous body prolapse are considered to be the predisposing factors for development of endophthalmitis (10,11).

It is hard to elaborate the issue of endophthalmitis prevention, as this disease is relatively rare, and the data necessary for a large, multi-centric, controlled randomized study are missing. Experience of a large number of authors has shown that the most important procedure in the prevention of operative field preparation is the application of povidone iodine into conjunctival sac immediately before surgery.

The second important prophylactic procedure is the intracameral application of antibiotic, usually nilacef, at the very end of the surgery. Lately, sterile compresses providing higher degree of sterility have been used in a large number of eye surgeries (33-35).

The application of some other preventive procedures, such as post-operative administration of subconjunctival antibiotic injection, intraoperative use of heparin, administration of antibiotics into balanced solution during phaco surgery, is of lesser importance today, as their effect has been proved to be weaker.

The European Association for Cataract Refraction Surgery has recommended the procedures

and suggestions for the prevention of endophthalmitis based on numerous studies on prevention of endophthalmitis in open-eye surgeries:

Topical application of quinolone drops (levofloxacin or ofloxacin). It is recommended to apply 1 drop four times per day 24-48 hours before surgery.

Application of one drop of ofloxacin one hour and half an hour before surgery.

Application of one drop of 5% povidone iodine onto the cornea and conjunctiva 3 min before surgery.

Cleaning of the skin of eyelids and periorbital region with 10% povidone iodine.

Surgeons are recommended to wash their hands with antiseptic solution of 10% povidone iodine or chlorhexidine solution. The use of sterile gloves and masks is recommended as well as providing adequate sterile air conditions in the operating theater.

It is recommended to perform the implantation of intraocular lens after phacosurgery with the application of sterile injector.

At the end of surgery, 1 mg cefuroxime diluted with 0.1 ml (0.9%) solution should be applied into the anterior chamber.

After the surgery, before closing the eye with sterile gauze, one drop of ofloxacin should be applied into the conjunctival sac.

References

- Scheidler V, Scott IU, Flunn HW. Culture-proven endogenous endophthalmitis: Clinical features and visual acuity outcomes. *Am J Ophthalmol* 2004; 137:4: 725-31.
- Kalamalarajah S, Silvestri G, Sharma N. Surveillance of endophthalmitis following cataract surgery in the UK. *Eye* 2004; 18:6: 580-7.
- Hanscom TA. Postoperative endophthalmitis. *Clin Infect Dis* 2004; 38:4:542-6.
- Bannerman TI, Rhoden D, McAllister SK, Miller JM, Wilson LA. The source of coagulase negative staphylococci in the Endophthalmitis Vitrectomy Study. A comparison of eyelid and intraocular isolates using pulsed field gel electrophoresis. *Arch Ophthalmol* 1997; 115: 357-61.
- Cooper Ba, Holecamp Nm, Bohigian G, Thompson PA. Case-control study of endophthalmitis after cataract surgery comparing scleral and corneal wounds. *Am J Ophthalmol* 2003; 136: 300-5.
- Smith SR, Kroll AJ, Lou PL, Ryan EA. Endogenous bacterial and fungal endophthalmitis. *Int Ophthalmol Clin* 2007;47(2):173-83.
- Callegan MC, Elenbert M, Parke DW. Bacterial endophthalmitis: Epidemiology, therapeutics, and bacterial host interactions. *Clin Microbiol Rev* 2002;15:1:111-24.
- Trofa D, Gácsér A, Nosanchuk JD. *Candida parapsilosis*, an emerging fungal pathogen. *Clin Microbiol Rev* 2008;21(4):606-25.
- Wejde G, Montan P, Lundström M, Stenevi U, Thorburn W. Endophthalmitis following cataract surgery in Sweden: national prospective survey 1999-2001. *Acta Ophthalmol Scand* 2005;83(1):7-10.
- Maguire JJ. Postoperative endophthalmitis: optimal management and the role and timing of vitrectomy surgery. *Eye* 2008;22(10):1290-300.
- Benz MS, Scott IU, Flunn HW. Endophthalmitis isolates and antibiotic sensitivities: A 6 years review of culture proven cases. *Am J Ophthalmol* 2004; 137:1:38-42.
- Prajna NV, Sathish S, Rajalakshmi PC, George C. Microbiological profile of anterior chamber aspirates following uncomplicated cataract surgery. *Indian J Ophthalmol* 1998;46(4):229-32.
- Mistlberger A, Ruckhofer J, Raithel E. Anterior chamber contamination during cataract surgery with intraocular lens implantation. *J Cataract Refract Surg* 1997;23:1064-9.
- Sherwood Dr, Rich WJ, Jacob JS. Bacterial contamination of intraocular and extraocular fluids during extracapsular cataract extraction. *Eye* 1989;3:308-12.
- Lunstrom M, Wejde G, Stenevi U. Endophthalmitis after cataract surgery: a nationwide prospective study evaluating incidence in relation to incision type and location. *Ophthalmology* 2007;114: 1004-9.
- Hatch WV, Cernat G, Wong D, Devenyi R, Bell CM. Risk factors for acute endophthalmitis after cataract surgery: a population-based study. *Ophthalmology* 2009;116(3):425-30.
- Miller JJ, Scott IU, Flynn HW. Endophthalmitis caused by *Streptococcus pneumoniae*. *Am J Ophthalmol* 2004; 138:2:231-6.
- Smith MA, Sorenson JA, D'Aversa G, Mandelbaum S, Udell I, Harrison W. Treatment of experimental methicillin-resistant *Staphylococcus epidermidis* endophthalmitis with intravitreal vancomycin and intravitreal dexamethasone. *J Infect Dis* 1997; 175(2):462-6.
- Gordon Y. Vancomycin prophylaxis and emerging resistance: Are ophthalmologists the villains? The heroes? *Am J Ophthalmol* 2001; 131:3:371-6.
- Gan IM, Ugahary LC, van Dissel JT, Feron E, Peperkamp E, Veckeneer M et al. Intravitreal dexamethasone as adjuvant in the treatment of postoperative endophthalmitis: a prospective randomized trial. *Graefes Arch Clin Exp Ophthalmol*. 2005;243(12):1200-5.

21. De Kaspar HM, Ta CN, Engelbert M, Mette M, Thiel M, Kampik A. Effects of intravitreal corticosteroid in the treatment of Staphylococcus aureus-induced experimental endophthalmitis. *Retina*. 2008 Feb; 28(2):326-32.
22. Clark WL, Kaiser PK, Flynn HW Jr, Belfort A, Miller D, Meisler DM. Treatment strategies and visual acuity outcomes in chronic postoperative Propionibacterium acnes endophthalmitis. *Ophthalmology* 1999;106(9): 1665-70.
23. Veselinović D, Jovanović P. Sarcoidosis - the cause of optic nerve neuropathy. *Acta Medica Medianae* 2007;46(1):41-4.
24. DeBry PW, Perkins TW, Heatley G, Kaufman P, Brumback LC. Incidence of late-onset bleb-related complications following trabeculectomy with mitomycin. *Arch Ophthalmol*. 2002 Mar;120(3):297-300.
25. Jonas JB, Knorr HL, Budde WM. Prognostic factors in ocular injuries caused by intraocular or retrobulbar foreign bodies. *Ophthalmology* 2000;107(5):823-8.
26. Al-Omran AM, Abboud EB, Abu El-Asrar AM. Microbiologic spectrum and visual outcome of posttraumatic endophthalmitis. *Retina* 2007;27(2): 236-42.
27. Piczenik Y, Kjer B, Fledelius HC. Metastatic bacterial endophthalmitis. A report of four cases all leading to blindness. *Acta Ophthalmol Scand* 1997;75(4):466-9.
28. Mc Donnell PJ, Taban M, Sarayba M. Dynamic morphology of clear corneal incision. *Ophthalmology* 2003;110: 2342-8.
29. Nagaki Y, Hiyasaka S, Kaadoi C. Bacterial endophthalmitis after small-incision cataract surgery: Effect of incision placement and intraocular lens type. *J Cataract Refract Surg* 2003;29:1:20-6.
30. Lemley CA, Han DP. Endophthalmitis: a review of current evaluation and management. *Retina* 2007; 27(6):662-80.
31. Engelbert M, Miño de Kaspar H, Thiel M, Grasbon T, Ta CN, Schulze-Schwering M et al. Intravitreal vancomycin and amikacin versus intravenous imipenem in the treatment of experimental Staphylococcus aureus endophthalmitis. *Graefes Arch Clin Exp Ophthalmol* 2004;42(4):313-20.
32. Jackson TL, Eykyn SJ, Graham EM, Stanford MR. Endogenous bacterial endophthalmitis: a 17-year prospective series and review of 267 reported cases. *Surv Ophthalmol* 2003;48(4):403-23.
33. Lundström M, Wejde G, Stenevi U, Thorburn W, Montan P. Endophthalmitis after cataract surgery: a nationwide prospective study evaluating incidence in relation to incision type and location. *Ophthalmology* 2007;114(5):866-70.
34. Montan PG, Wejde G, Koranyi G, Rylander M. Prophylactic intracameral cefuroxime. Efficacy in preventing endophthalmitis after cataract surgery. *J Cataract Refract Surg* 2002;28(6):977-81.
35. Montan PG, Wejde G, Setterquist H, Rylander M, Zetterström C. Prophylactic intracameral cefuroxime. Evaluation of safety and kinetics in cataract surgery. *J Cataract Refract Surg* 2002;28(6):982-7.

ENDOFTALMITIS

Dragan Veselinović i Aleksandar Veselinović

Endoftalmitis predstavlja jedno od najurgentnijih stanja u oftalmologiji, a karakteriše se inflamacijom prednjeg i zadnjeg segmenta oka, kao posledica bakterijske ili gljivične infekcije.

U radu se opisuju kliničke manifestacije endoftalmitisa, klasifikacije endoftalmitisa u odnosu na etiološke faktore i različiti etiološki faktorimi koji mogu da ga prouzrokuju. Poseban akcenat dat je na pojavu endoftalmitisa nakon različitih hirurških intervencija na oku, pri čemu se ukazuje na pojavu endoftalmitisa nakon operacije katarakte.

Opisuju se i kliničke karakteristike postraumatskog, endogenog i gljivičnog endoftalmitisa.

Ukazuje se na faktore rizika za nastanak postoperativnog endoftalmitisa i značaj prevencije postoperativnog endoftalmitisa i preporučuju se postupci u profilaksi.

Posebno važan deo rada posvećen je terapiji akutnog endoftalmitisa na osnovu preporuka Evropskog udruženja za kataraktu i refraktivnu hirurgiju. *Acta Medica Medianae* 2009;48(1):56-62.

Ključne reči: endoftalmitis, etiologija, profilaksa, terapija