

Combined therapy with bevacizumab and photodynamic therapy for myopic choroidal neovascularization: A one-year follow-up controlled study

Sandro Saviano¹, Rita Piermarocchi¹, Pia E. Leon¹, Alessandro Mangogna¹, Andrea Zanei¹, Fabiano Cavarzeran Sc², Daniele Tognetto¹

¹University Eye Clinic, University of Trieste, Ospedale Maggiore, Trieste 34129, Italy

²Eye Clinic of Padova, University of Padova, Padova 35128, Italy

Correspondence to: Pia E. Leon. University Eye Clinic, University of Trieste, Ospedale Maggiore, Piazza dell'Ospitale 2, Trieste 34129, Italy. pialeon@libero.it

Received: 2013-03-01

Accepted: 2013-12-19

Abstract

• **AIM:** To evaluate the efficacy and safety of a combined treatment for myopic choroidal neovascularization (CNV) using photodynamic therapy (PDT) and intravitreal bevacizumab and to compare it with intravitreal bevacizumab monotherapy.

• **METHODS:** Thirty-four eyes with angiographic evidence of myopic CNV were randomly divided into two groups: 17 were treated with one intravitreal bevacizumab injection (1.25 mg) and low-fluence-rate PDT within seven days of the injection (Group A). The other 17 received monotherapy with bevacizumab injections (Group B). Clinical evidence of complications, best corrected visual acuity (BCVA) and fluorescein leakage were evaluated. BCVA and optical coherence tomography (OCT) were evaluated monthly. The timepoints follow-up was established at 6 and 12mo. All patients were retreated following a PRN protocol.

• **RESULTS:** A total of 34 eyes of 34 patients (26 women and 8 men) with a mean age of 62.35 years were included. In Group A (17 eyes) the mean BCVA increased from 0.55 ± 0.13 logMAR before the treatment to 0.40 ± 0.09 logMAR at the 12mo follow-up ($P < 0.01$). In Group B (17 eyes) the mean BCVA increased from 0.60 ± 0.11 logMAR before the treatment to 0.55 ± 0.12 logMAR at the 12mo follow-up ($P < 0.01$). There was no statistically significant difference between the two groups in terms of LogMar visual acuity. In Group A the mean number of combined treatments was 1.8 ± 0.11 per patient; in Group B the mean number of intravitreal bevacizumab injections was 3.1 ± 0.08 per patient. The number of treatments was significantly fewer in Group A ($P < 0.01$). No local or systemic side effects occurred among any of the patients treated in this study.

• **CONCLUSION:** The combination of anti-angiogenic injections and PDT appears to be a safe and effective option for myopic CNV treatment and allows for a significant reduction of intravitreal injections.

• **KEYWORDS:** bevacizumab; combined therapy; myopia; neovascularization; photodynamic therapy

DOI:10.3980/j.issn.2222-3959.2014.02.26

Saviano S, Piermarocchi R, Leon P, Mangogna A, Zanei A, Cavarzeran F, Tognetto D. Combined therapy with bevacizumab and photodynamic therapy for myopic choroidal neovascularization: A one-year follow-up controlled study. *Int J Ophthalmol* 2014;7(2):335-339

INTRODUCTION

Choroidal neovascularization (CNV) is one of the most vision-threatening complications in young and middle-aged patients^[1] second to pathologic myopia (PM). Nearly 10% of patients with degenerative retinal findings due to PM develop CNV. The natural course of myopic CNV is variable and the long term prognosis is known to be poor.

Laser photocoagulation is a non-selective treatment which involves the full retinal thickness. Use of a laser results in a retinal scar and for this reason it can be used in extra or juxtafoveal CNV (both lesions represent less than 50% of the total cases of CNV). Moreover, laser treatment is related to a high frequency of relapses and enlargement of laser scars and for these reasons it is no longer used for treating CNV^[1,2].

Photodynamic therapy (PDT) with verteporfin is an effective, secure and approved treatment because of its selective action on neovascular lesions which spares the surrounding healthy retina. The VIP study^[3] analyzed the beneficial effects of PDT compared to a placebo group and documented the stabilization or improvement of visual acuity after one year. This result is not maintained at the 24mo follow-up because of the spread of macular atrophy^[3-6].

The widespread use of intravitreal injections of anti-VEGF drugs in the treatment of CNV due to age related macular degeneration (AMD) has led to the development of new therapeutic strategies. The use of anti-VEGF drugs to treat CNV secondary to PM is currently off-label and it has been evaluated in a few non-randomized, uncontrolled clinical

trials^[1]. The study groups of Lai and Yamamoto demonstrated that this therapy is an effective treatment for myopic lesions^[7,8]. Gharbiya *et al*^[9] also evaluated the safety of intravitreal bevacizumab (1.25 mg) in myopic CNV and obtained a significant anatomic and functional improvement after a two year follow-up. Chan *et al*^[10] analyzed a group of 17 patients who underwent three monthly intravitreal injections of bevacizumab and reported a gain of visual acuity from 0.62 logMAR to 0.38 logMAR with a mean improvement of 2.4 ETDRS lines^[10]. Parodi *et al*^[12] compared the visual acuity of three groups receiving different treatments such as laser therapy, PDT and intravitreal bevacizumab. Overall, the bevacizumab group achieved the best functional results during the two-year follow-up^[2].

Intravitreal injection of anti-angiogenic drugs has specifically been considered the first line therapy for sub or juxtafoveal neovascularization since 2009, because of the safety of the procedure, good visual outcomes reported in several pilot studies and finally, for the encouraging long term results^[4,5].

Recent studies have shown that combined PDT with anti-VEGF injections may be a good alternative for the treatment of choroidal neovascularization secondary to pathological myopia. In addition, an increased percentage of macular atrophy was noted after treatment^[11].

Combined therapy for myopic CNV has only begun to be adopted in the last two years. Han *et al*^[12] used anti-VEGF and PDT to treat a small and heterogeneous group of patients with extra or juxtafoveal neovascular membranes. Different studies dealing with combined therapy for pathological myopia were carried out with different therapeutic protocols, in particular with varying intervals of treatment^[13,14]. These different protocols may lead to different functional outcomes.

This study was carried out in patients affected by myopic CNV who were treated with a combined therapy using intravitreal bevacizumab and low-fluence-rate PDT, or intravitreal bevacizumab monotherapy. The aim was to evaluate the safety and the efficacy of the combined treatment by comparing it to bevacizumab. Moreover, we wanted to evaluate whether combined treatment could decrease the number of intravitreal injections. Follow-up lasted one year.

SUBJECTS AND METHODS

Subjects This was a prospective, consecutive, comparative, interventional case series study in which we analyzed the outcomes of two therapeutic strategies.

Thirty-four patients were included in the study and then randomized into two different treatment groups.

Group A was composed of 17 eyes which received the combined therapy: one intravitreal injection of 1.25 mg of bevacizumab followed by low-fluence-rate PDT within 7d of the injection. Group B was composed of 17 eyes which received intravitreal bevacizumab injections as monotherapy. Follow-up lasted 12mo for all patients.

Methods Inclusion criteria was myopic patients with active

CNV (juxtafoveal or subfoveal) diagnosed with the use of fluorescein angiography and optical coherence tomography. Pathological myopia has been defined as a spherical equivalent refractive error of -6.0 diopters (D) or more in phakic eyes, and an axial length of >25 mm in pseudophakic eyes. Both naïve and patients previously treated with anti-VEGF drugs or laser and PDT treatment in the extrafoveal area were included in the study. The exclusion criteria were membranes not correlated to pathologic myopia or larger than one diameter of optical disc previously laser and PDT treatment involving the foveal or juxtafoveal area, glaucoma not controlled by therapy and intolerance to medication used.

A careful medical history, complete ophthalmic evaluation with OCT (Stratus OCT; Carl Zeiss Meditec, Dublin, CA) and fluorescein angiography were performed during the screening visit. Patients were evaluated monthly for visual acuity and the central retinal thickness was measured using the OCT exam. We used Stratus OCT with a 6-mm linear cross-hair pattern that was centered on the fovea (512 A-scans; scan length, 6.0 mm) and a fast macular thickness map pattern. Moreover visual acuity, fundus examination, fluorescein angiography and optical coherence tomography were performed at the fixed intervals of 6 and 12mo during the follow-up. The best corrected visual acuity (BCVA) was determined using the Early Treatment Diabetic Retinopathy Study (ETDRS) charts and then converted to logMAR for data analysis.

Group A was treated with one injection of bevacizumab (1.25 mg) followed by low-fluence-rate PDT within 7d of the injection. Bevacizumab (1.25 mg) was prepared by the hospital pharmacy and placed in a 1 mL syringe under sterile conditions. Injections were performed under strict aseptic conditions under topical anesthesia, using a 27G needle. A dose of 0.05 mL of bevacizumab (Avastin; Roche, Basel, Switzerland) was injected into the vitreous cavity. Topical Ofloxacin was prescribed four times daily for seven days after each injection. Patients were seen the first and fourth day after every injection. The same protocol was used for PDT treatment controls.

Group B was treated with three monthly intravitreal bevacizumab (1.25 mg) injections. The identical procedure described above was used for each injection.

Patients received additional treatment when evidence of active leakage at fluorescein angiography or intraretinal edema was detected at the OCT exam. The retreatment criteria were: loss of visual acuity, increase or permanence of intraretinal edema and the presence of leakage at fluorescein angiography (PRN protocol).

The study also evaluated the development of sub-retinal fibrosis (SRF) or atrophy at the end of the 12mo follow up observing the presence of hyper-reflective formation under the retina at the OCT exam and the absence of blood or exudates which showed staining in late angiographic frames

without fluorescein leakage.

At the end of the follow-up, there were no active lesions in any patients.

The study was performed in accordance with the tenets of the Declaration of Helsinki, and informed consent was obtained from all subjects.

Statistical Analysis Statistical analysis was performed using SAS (version 9.2) statistical software (SAS institute. SAS-STAT V9.2, Cary, NC, USA, 2008).

Group A and Group B were compared at baseline for mean age, baseline BCVA (analyzed with Student *t*-test), gender and previous treatments (analyzed with the Chi-quadro test). The variation of VA after 6 and 12mo was analyzed using a paired Student *t*-test. The mean number of injections in each group was analyzed using the Mann-Whitney test. The correlation between baseline BCVA and visual acuity variation was evaluated using the Pearson correlation coefficient. The level of statistical significance was taken as 5% ($P < 0.05$).

RESULTS

A total of 34 patients with myopic CNV were divided in two treatment groups. Group A included 17 eyes (17 patients): 14 women and 3 men. The mean age was 61.7 years (age range from 50 to 75). Eleven eyes received previous treatments following the inclusion criteria. The other six had never received any prior treatment. Group B included 17 eyes (17 patients): 12 women and 5 men. The mean age was 63 years (age range from 57 to 69). Five eyes had received previous treatments; the rest of the group (12 eyes) had never received any prior treatment. The two groups were homogeneous for mean age, sex, previous treatment and baseline BCVA. There was no statistical significant difference ($P < 0.05$) between Group A and Group B. The means of BCVA and number of injections for Group a and B were summarized in Tables 1 and 2. Statistical analysis showed that the difference between the mean number of injections given to the two groups was statistically significant ($P < 0.01$).

At the end of the follow-up, there were no active lesions in any patients.

Both groups showed an improvement of visual acuity in the first year of follow-up ($P < 0.01$). The evolution of the BCVA data is summarized in Table 1 and Figure 1. Figure 1 shows a progressive decrease in logMAR values which corresponds to a gain of visual acuity.

Although the variation in visual acuity at the sixth and twelfth months seems to be greater in Group A, statistical analysis did not demonstrate a significant difference ($P > 0.05$). Further analyses of the data were undertaken and the logMAR variations were put into correlation with other variables such as age, baseline BCVA and previous treatments for each group. There was no statistical correlation between the BCVA improvement and the three variables considered in both groups at the end of the follow-up. The only significant correlation ($P < 0.05$) noted was the one

Table 1 Visual acuity (BCVA) of the two groups at baseline, after 6 and 12 mo of follow-up. All data are expressed in logMAR

Visual acuity (BCVA)	BCVA baseline	BCVA 6 mo	BCVA 12 mo
Group A	0.55±0.13	0.42±0.12	0.40±0.09
Group B	0.60±0.11	0.54±0.10	0.55±0.12

Table 2 Number of injections of bevacizumab (1.25mg) for each group

No. of injections	Group A	Group B
Mean	1.8±0.11	3.1±0.08
Minimal value	1	1
Maximal value	3	8

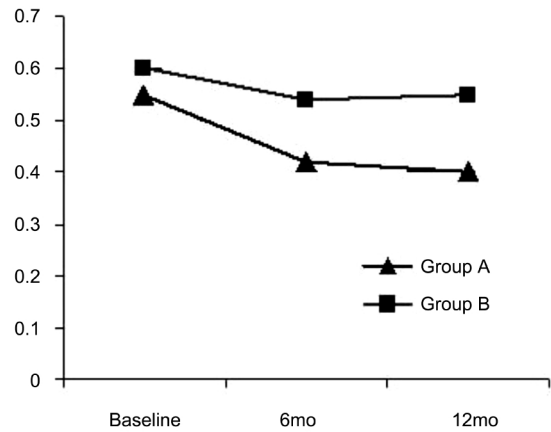


Figure 1 Evolution of visual acuity (BCVA) of the two groups during one year of follow-up. Data are expressed in LogMAR.

between baseline logMAR and the visual gain at the end of the follow-up in Group A. This result means that in Group A, the lower baseline visual acuity corresponds to a greater improvement of function after one year (negative Pearson correlation coefficient).

The BCVA variations during the follow-up were taken into consideration in order to test and compare the efficacy of the two treatments. The outcomes were divided into three categories following the trends of visual acuity: improved, stable or decreased. The logMAR data in the first category was equal to or lower than -0.1, for the stables a range from -0.1 to 0.1 logMAR was taken into consideration and finally in the last category values equal to or greater than 0.1 logMAR were included.

Figure 2 illustrates the distribution of the visual outcome for each group expressed in percentages. In Group A was registered at 47.06% of both stable and improved categories; the rest of the cases (5.88%) demonstrated a loss of visual acuity. In Group B the majority of patients (88.24%) showed a stable visual outcome after 12mo and the rest of the group (11.76%) reported an improvement. There were no cases of visual loss in this group. The results obtained in Group A and B were statistically significant different ($P < 0.05$ using Fisher's exact test).

Another outcome considered in this study was the development of SRF or atrophy at the FA and OCT examinations. SRF or atrophy was seen as the presence of a

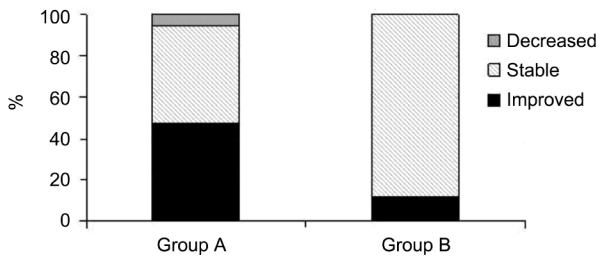


Figure 2 Visual outcomes at the 12th month divided into three categories: improved, stable and decreased.

hyper-reflective formation under the retina at the OCT exam and the absence of blood or exudates which showed staining in late angiographic frames without leakage of fluorescein. The observation of all angiographic frames and OCT scans demonstrated that previously treated eyes showed a greater presence of fibrosis. Moreover SRF appeared more frequently in those patients with worse BCVA at the end of the follow-up. Both Group A and Group B presented a fibrotic or atrophic evolution of the CNV treated. A considerable difference was not noticed between Group A and Group B in terms of the presence of SRF and atrophy after one year from baseline. Longer follow-up studies and specific investigations (taking into consideration age, sex, lesion size and type etc.) are required in order to determine the influence of PDT treatment in correlation to visual acuity. No local or systemic side effects occurred among any of the patients treated in this study.

Finally, Figures 3 and 4 show the two groups (Group A and Group B) before and after therapy.

DISCUSSION

The purpose of this study is to evaluate the safety and the efficacy of a combined treatment using low-fluence-rate PDT and intravitreal bevacizumab in myopic CNV by comparing it to bevacizumab monotherapy.

In our study the visual outcome was significantly improved in both groups with no significant difference at the 12mo follow-up. In Figure 1 it is possible to notice a different course between the two groups during the first and second semesters. Group A demonstrates a linear improvement in the first semester which, in the second semester reached a plateau, while Group B revealed a similar course but with a smaller improvement in the first semester compared to Group A. Despite a lack in statistically significant difference, the trends suggest a faster functional response in Group A in the first months after the treatment compared to Group B. However, the two groups demonstrated a similar functional evolution in the first year of follow-up.

We also observed that in Group A, patients with poorer visual acuity at baseline gained better functional results. This trend may be explained as a ceiling effect such as the one found in Descio's study.

Patients were divided into three categories based on the results of visual acuity: improved, stable or decreased (Figure 2).

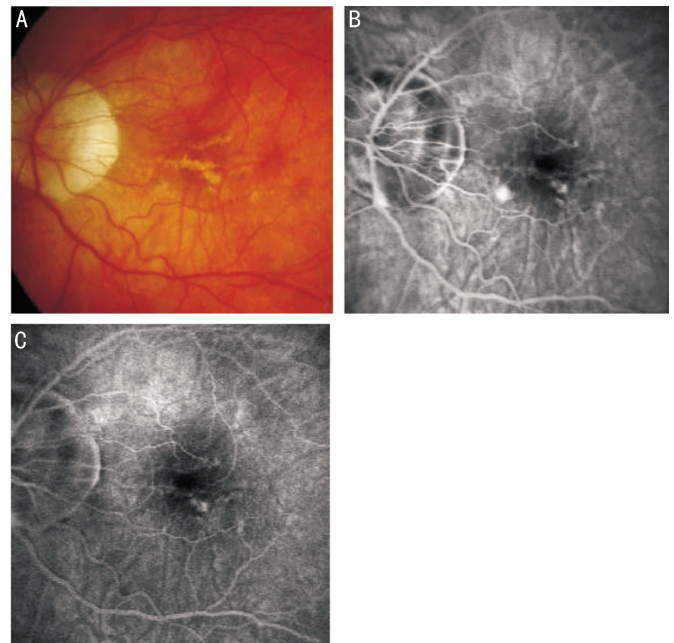


Figure 3 Case of combined treatment PDT plus bevacizumab injection (Group A) A: Color fundus photography; B: Angiographic image at baseline; C: Angiographic image at the end of the follow-up.

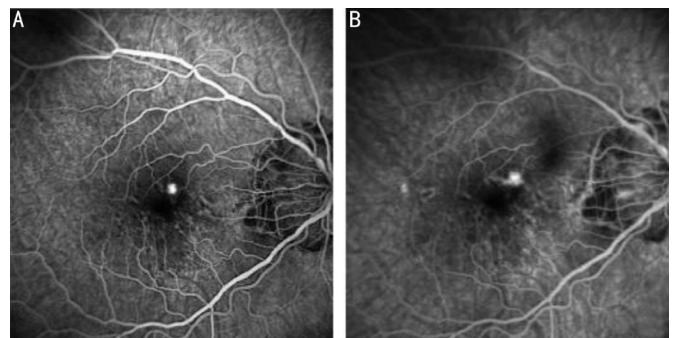


Figure 4 Case of bevacizumab monotherapy (Group B) A: Angiographic image at baseline; B: After a loading phase with 3 intravitreal injections.

The percentage of improved vision was clearly higher in patients who received combined treatment (47.06%) compared to the group treated with only intravitreal bevacizumab (11.76%). On the contrary, stable cases were more frequent in the bevacizumab group (88.24%) while in the combined group there were 47.06%. Finally, in Group B there were no patients who demonstrated a loss of visual acuity. These data suggest that the combination treatment offers a higher possibility of improved visual acuity when compared to the bevacizumab monotherapy while the treatment with antiangiogenic drugs shows a superior possibility of stable visual outcome without decreasing.

According to the literature, repeated intravitreal injections are necessary to stop the neovascular membrane and to maintain visual improvement in the majority of cases.

During the one year of follow-up, Hayashi *et al*^[15] administered from 1 to 4 intravitreal injections (mean 1.8) per patient in order to obtain a good functional response.

Ikuno *et al*^[16] administered 2.4 +/- 1.4 injections, Chan *et al*^[10]

used a range of 3-12 injections (mean 3.6) and finally Gharbiya *et al*^[9] administered between 3-7 injections with a mean number of 4 doses per patient^[10,15-17]. From the reported studies one can note a great variation in the range of the number of injections. In our opinion, this result is connected to the absence of a standard therapeutic protocol and to the variation of retreatment criteria.

The importance of adding low-fluence-rate PDT to bevacizumab injections^[14,15,18-20] is supported by the necessity of reducing the mean number of injections in order to decrease the risk of intraocular complications related to surgical procedure. In fact, highly myopic eyes are predisposed to peripheral vitreo-retinal degenerations which increase the risk of retinal rupture and detachments.

In our study, the range of injections was from 1 to 3 for Group A with a mean number of 1.8±0.11 treatments, while in Group B the range was from 1 to 8 and the mean number of injections was 3.1±0.08 (Table 2). The results of the number of injections in Group B are concordant with those reported in the literature and are more than those performed in Group A (*P*<0.01).

Possible limitations of this study could be the relatively small number of patients in the groups; moreover the follow-up time may be too brief to take into account the long-term efficacy of treatment.

Although preliminary, our findings are encouraging when compared with the results of clinical trials evaluating bevacizumab monotherapy injections in myopic CNV. When comparing intravitreal bevacizumab to combined therapy, the latter appears to be a useful therapeutic choice to preserve or improve visual acuity with a reduced number of intraocular injections. Patients may also benefit from a reduction of discomfort and the risk of complications as well as the benefit of the lower cost of the procedures.

A larger, controlled prospective, randomized, comparative study with a longer follow-up period will be required in order to fully compare the differences between anti-VEGF monotherapy and combination therapy in the efficacy of treatment.

ACKNOWLEDGEMENTS

Conflicts of Interest: Saviano S, None; Piermarocchi R, None; Leon P, None; Mangogna A, None; Zanei A, None; Cavarzeran F, None; Tognetto D, None.

REFERENCES

- 1 Montero JA, Ruiz-Moreno JM. Treatment of choroidal neovascularization in high myopia. *Current Drug Targets* 2010;11(5):630-644
- 2 Parodi MB, Iacono P, Papayannis A, Sheth S, Bandello F. Laser photocoagulation, photodynamic therapy, and intravitreal bevacizumab for the treatment of juxtafoveal choroidal neovascularization secondary to pathologic myopia. *Arch Ophthalmol* 2010;128(4):437-444
- 3 Verteporfin in Photodynamic Therapy Study Group. Photodynamic therapy of subfoveal choroidal neovascularization in pathologic myopia with verteporfin. 1-year results of a randomized clinical trial-VIP report no.1. *Ophthalmology* 2001;108(5): 841-852
- 4 Cohen SY. Anti-VEGF drugs as the 2009 first-line therapy for choroidal

- neovascularization in pathologic myopia. *Retina* 2009;29(8):1062-1066
- 5 Desco MC, Mataix J, Garcia-Pous M, Palacios-Pozo E, Navea A. Combined therapy: photodynamic therapy and bevacizumab to treat myopic neovascular membranes. One-year follow-up. *Retina* 2011;31(3):475-481
- 6 Smith BT, Dhalla MS, Shah GK, Blinder KJ, Ryan EH Jr, Mitra RA. Intravitreal injection of bevacizumab combined with verteporfin photodynamic therapy for choroidal neovascularization in age related macular degeneration. *Retina* 2008;28(5):675-681
- 7 Lai TY, Chan WM, Liu DT, Lam DS. Intravitreal ranibizumab for the primary treatment of choroidal neovascularization secondary to pathologic myopia. *Retina* 2009;29(6):750-756
- 8 Yamamoto I, Rogers AH, Reichel E, Yates PA, Duker JS. Intravitreal bevacizumab (Avastin) as treatment for subfoveal choroidal neovascularization secondary to pathologic myopia. *Br J Ophthalmol* 2007; 91(2):157-160
- 9 Gharbiya M, Giustolisi R, Allievi F, Fantozzi N, Mazzeo L, Scavella V, Gabrieli CB. Choroidal neovascularization in pathologic myopia: intravitreal ranibizumab versus bevacizumab-A randomized controlled trial. *Am J Ophthalmol* 2010;149(3):458-464
- 10 Chan WM, Lai TY, Liu DT, Lam DS. Intravitreal bevacizumab (Avastin) for myopic choroidal neovascularization: 1-year results of a prospective pilot study. *Br J Ophthalmol* 2009;93(2):150-154
- 11 Potter MJ, Szabo SM, Ho T. Combined photodynamic therapy and intravitreal Triamcinolone for the treatment of myopic choroidal neovascularization in a 13-year-old girl. *Graefes Arch Clin Exp Ophthalmol* 2006;244(5):639-641
- 12 Han DP, Mc Allister JT, Weinberg DV, Kim JE, Wirosko WJ. Combined intravitreal anti-VEGF and verteporfin therapy for juxtafoveal and extrafoveal choroidal neovascularization as an alternative to laser photocoagulation. *Eye* 2010;24(4):713-716
- 13 Voykov B, Gelisken F, Inhoffen W, Voelker M, Ulrich Bartz-Schmidt K, Ziemssen F. Bevacizumab for choroidal neovascularization secondary to pathologic myopia: is there a decline of the treatment efficacy after 2 years? *Graefes Arch Clin Exp Ophthalmol* 2010;248(4):543-550
- 14 Yoon JU, Byun YJ, Koh HJ. Intravitreal anti-VEGF versus photodynamic therapy with verteporfin for treatment of myopic choroidal neovascularization. *Retina* 2010;30(3):418-424
- 15 Hayashi K, Ohno-Matsui K, Shimada N, Moriyama M, Hara W, Yoshida T, Tokoro T, Mochizuki M. Intravitreal bevacizumab on myopic choroidal neovascularization that was refractory to or had recurred after photodynamic therapy. *Graefes Arch Clin Exp Ophthalmol* 2009;247(5) 609-618
- 16 Ikuno Y, Sayanagi K, Soga K, Sawa M, Tsujikawa M, Gomi F, Tano Y. Intravitreal bevacizumab for choroidal neovascularization attributable to pathological myopia: one-year results. *Am J Ophthalmol* 2009;147 (1): 94-100.e1
- 17 Gharbiya M, Allievi F, Mazzeo L, Gabrieli CB. Intravitreal bevacizumab treatment for choroidal neovascularization in pathologic myopia: 12-month results. *Am J Ophthalmol* 2009;14 (1):84-93.e1
- 18 Wang E, Chen Y. Intravitreal anti-vascular endothelial growth factor for choroidal neovascularization secondary to pathologic myopia: systematic review and meta-analysis. *Retina* 2013; 33(7):1375-1392
- 19 Wakabayashi T, Ikuno Y, Gomi F. Different dosing of intravitreal bevacizumab for choroidal neovascularization because of pathologic myopia. *Retina* 2011;31(5):880-886
- 20 Lai TY, Luk FO, Lee GK, Lam DS. Long-term outcome of intravitreal anti-vascular endothelial growth factor therapy with bevacizumab or ranibizumab as primary treatment for subfoveal myopic choroidal neovascularization. *Eye* 2012;26(7):1004-1011