

Short Communication

HELMINTHIASIS IN A BENGAL TIGER (*PANTHERA TIGRIS TIGRIS*) - A CASE REPORT

Shivaji Bhattacharya¹, B. Dutta, U. Mondal², J. Mukherjee and Malay Mitra

Helminthiasis is common in wild animals but report on both *Toxocara cati* and *Teania hydatigena* infestation in Bengal Tiger (*Panthera tigris tigris*) from wild nature is scanty. Many parasites have a broad host range and are a threat in mixed species exhibits (Miller and Fowler 2012). Studies on captive tigers have also been done (Garner *et al.* 1996, Jakob and Wesemeier 1996) however, little is known about parasites of wild *Panthera tigris tigris* (Mandal and Choudhury 1985, Patton and Rabinowitz 1994, Marathe *et al.* 2002).

A wild male adult Bengal Tiger was observed lying alive on forest floor in core area near Pirkhali of Sundarban Tiger Reserve, West Bengal, India, about 100 feet away from river bank since noon on 9th June, 2012 with the symptoms of severe weakness, unable to stand properly, staggering gait along with dull and depressed appearance. Its reflexes were poor and not interested to take food. Ultimately the big cat succumbed at that night.

The male tiger was aged about 16 years having body weight 72 kg, length (tip of the nostril to end of the tail) 2 m 52 cm, height 93 cm. The carcass was emaciated, dehydrated, having rough hair coat, shrunken eyes and there was no external injury (Fig.1) except some lacerated superficial wounds on inner side of thigh and abdomen. Teeth including canines were broken, eroded and having caries in some of them. Stomatitis in upper palate and gingivitis were also observed along with retracted claws.

Postmortem examination revealed anaemic mucous membrane and liver was slightly enlarged, mottled, congested partly with milliary necrotic foci (Fig.2). Heart was slightly enlarged with thickening of heart muscles. Kidneys were congested, hard with hemorrhagic lesions in cortico-medullary junction. Mesenteric lymph nodes were hyperemic. A plenty of live round worms were present in stomach (Fig.3) and duodenum and

Institute of Animal Health & Veterinary Biologicals(R&T), 37, Belgachia Road, Kolkata - 700037, West Bengal, India.

¹ *Assistant Director, ARD, New Secretariat Building, 1, K. S. Roy Road, Kolkata - 700001, West Bengal, India.*

² *Veterinary Officer, Sundarban Tiger Reserve, Canning, South 24 Parganas, West Bengal, India.*



Fig.1: Physical observation of dead tiger before PM.

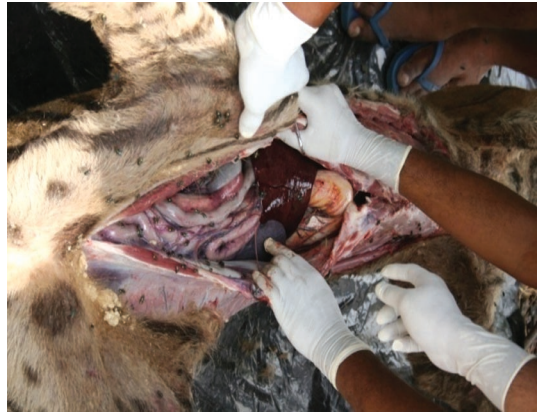

Fig.2: Gross-pathological changes of dead tiger during PM.

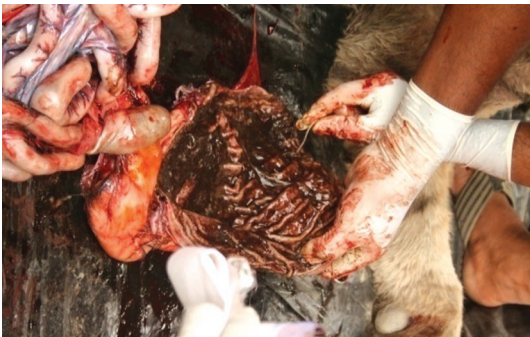

Fig.3: *Toxocara cati* found in stomach of dead tiger.

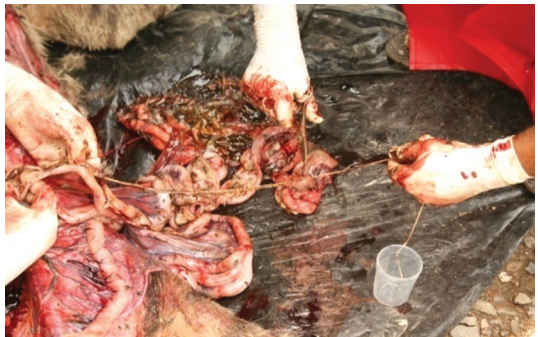

Fig.4: *Teania hydatigena* in intestine of tiger.

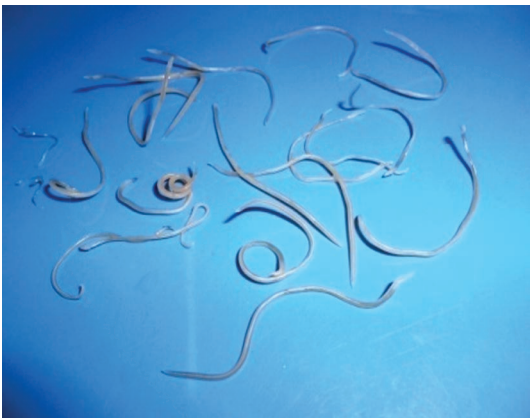

Fig.5: *Toxocara cati* obtained from intestine of tiger.

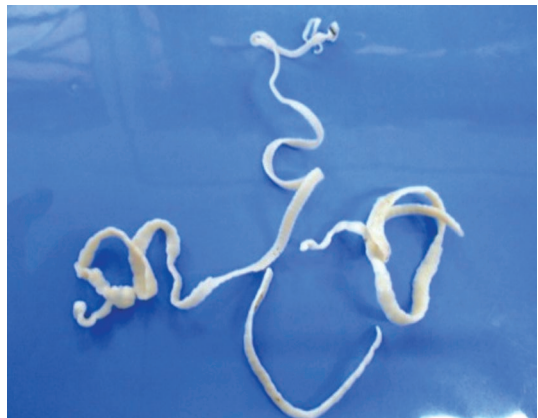


Fig.6: *Teania hydatigena* obtained from intestine of tiger.

few tape worms were found in ileum (Fig.4). Altogether there were 121 numbers of round worms and 07 numbers of long tape worms. Intestinal mucous membrane was inflamed and thickened sporadically with presence of semi-digested faecal materials.

Histopathological examination revealed chronic interstitial hepatitis and fibrosis in liver, exudative pneumonia in lung, oedema and infarction in heart, chronic interstitial nephritis in kidney and focal cholecystitis in gall bladder.

Microscopical examination of impression smear of different tissues like liver, heart, kidney did not revealed any specific bacterial organism. Culturally, it was also found negative for any specific bacterial growth on blood agar and nutrient agar media.

Microscopical examination of the faecal materials revealed few spherical eggs and shells were markedly pitted (Rao *et al.* 2002), diameter of the eggs were 65 - 75 μm and few eggs were oval and measuring 36 -39 μm by 31-35 (Soulsby 2005) which were indistinguishable from the eggs of *Toxocara spp.* and *Taenia spp.* respectively.

Parasites were identified according to size and morphology of the forms present in faeces (Hartwich 1974, Khalil *et al.* 1994, Bowman 1995) and in G.I tract. Detail morphological study revealed all the round worms were indistinguishable from *Toxocara cati*. The cervical alae were very broad and are striated. The males were 3 - 6 cm and females were 4 - 10 cm long (Fig.5). The spicules were 1.63 - 2.08 mm long (Soulsby 2005). Detail morphological study revealed that all tape worms were indistinguishable from *Taenia hydatigena*. Measurements were made on gravid worm, scolex, rostellum, sucker, and large and small rostellar hooks of adult *Taenia*

hydatigena (Edwards and Herbert 1981). Adults were 75 - 500 cm long having two rows of 26 and 46 rostellar hooks (Fig.6). Gravid proglottids measured about 12 mm by 6 mm and uterus had 6 to 10 lateral branches (Soulsby 2005).

Toxocara cati is a worldwide parasite that occurs in the small intestine of felids and occurs also in humans, causing the disease referred as visceral or ocular larva migrans. *Toxocara spp.* infestation in Indian Tiger in high altitude zoo in Darjeeling, West Bengal was reported by Pradhan *et al.* (2011). The higher prevalence of *Toxocara cati* was reported in Siberian tiger by Gonza' lez *et al.* (2007). *Toxocara cati* infestation with other helminthic infestation was reported by Shirbhate (2008). *Toxocara cati* along with *Taenia spp.* infestation in leopard was also reported by Youssefi *et al.* (2010).

Taenia hydatigena is cosmopolitan in distribution and occurs in small intestine of dogs, wolves and other wild carnivores. Among the many metacestodes recognized in this country, most commonly known one in wild ruminants are the larval metacestodes of *Taenia hydatigena* (*Cysticercus tenuicollis*) in the liver of the deer (Rao *et al.* 2003). The intermediate hosts are domestic and wild ruminants, particularly sheep and pig may also be infected (Soulsby 2005). In Sundarban of West Bengal, spotted deer and wild boar are major prey base of tiger. Prey animals occupying the Sundarban tiger niche are the Cheetal (Spotted deer, *Axis axis*), wild pig (*Sus scrofa*) and Rhesus macaque (*Macaca mulata*) among other large animals (Bhattacharya 2001). *Taenia hydatigena* was reported from a lion in Nigeria that had originated from the Leipzig Zoological Gardens, Germany, where

it had been fed raw goat meat (Ogungbade and Ogunrinade 1984). Tiger may be infected from wild ruminants and wild boars by feeding of them. The understanding of these parasites found in wild animals allows us to increase the knowledge about the ecology of wild felids and to establish correct programs of prophylaxis (Gonza' lez *et al.* 2007).

ACKNOWLEDGEMENT

Authors are thankful to the Director of Animal Husbandry & Veterinary Services, West Bengal and Joint Director, ARD, IAH & VB, Kolkata for providing necessary facilities for this work and Forest department for providing materials.

REFERENCES

Bhattacharya S.(2001). A report of project on Eco-husbandry management of tiger *in situ* at Sundarban Tiger reserve, West Bengal. NDZWA project work (2000-2001). IVRI. Izatnagar. India. p.13-16.

Bowman DD.(1995). Geogis' parasitology for veterinarians. 6th edn. W.B. Saunders Company. Philadelphia. Pennsylvania. p.430.

Edwards GT, Herbert IV.(1981). Some quantitative characters used in the identification of *Taenia hydatigena*, *T. ovis*, *T. pisiformis* and *T. multiceps* adult worms, and *T. multiceps* metacestodes. *J. Helminthol.* 55(1) : 1-7.

Garner MM, Lung NP, Citino S, Greiner EC, Harvey JW and Homer BL.(1996). Fatal cytauxzoonosis in a captive-reared white tiger (*Panthera tigris*). *Vet. Pathol.* 33: 82-86.

Gonza' lez P, Carbonell E, Urios V and Rozhnov V.V.(2007). Coprology of *Panthera tigris altaica* and *Felis bengalensis euphilurus* From the Russian Far East. *J. Parasitol.* 93(4) : 948 - 950.

Hartwich G.(1974). Keys to genera of the Ascaridoidea, No. 2. In CIH keys to the nematode parasites of vertebrates, R. C. Anderson, A.G. Chabaud, S. Willmott, Commonwealth Agricultural Bureaux. Farnham Royal Bucks. U.K. p. 1-15.

Jakob W and Wesemeier HH.(1996). A fatal infection in a Bengal tiger resembling cytauxzoonosis in domestic cats. *J. Comparative Path.* 114: 439-444.

Khalil LF, Jones A and Bray RA.(1994). Keys to the cestode parasites of vertebrates. CAB International. Oxon. U.K. p.751.

Mandal D and Choudhury A.(1985). Helminth parasites of wild tiger of Sundarbans Forest, West Bengal, India. *Proc. Int. Symp. Dis. Zoo Anim.* 27: 499-501.

Marathe RR, Goel SS, Ranade SP, Jog MM and Watve MG.(2002). Patterns in abundance and diversity of fecally dispersed parasites of tiger in Tadoba National Park, Central India. *BMC Ecology.* 2: 6.

Miller R.Eric and Fowler Murray.(2012). Fowler's Zoo and Wild Animal Medicine. Elsevier Saunders. Missouri. Vol.7. p.28.

Ogungbade SG and Ogunrinade AF.(1984). Tapeworm infection (*Taenia hydatigena*) in lion (*Panthera leo*) in captivity- A case report. *Revue D'élevage et de Médecine Vétérinaire Des Pays Tropicaux.* 37: 30-31.

- Patton S and Rabinowitz AR.(1994).** Parasites of wild felidae in Thailand-A coprological survey. *J. Wildlife Dis.* 30: 472-475.
- Rao AT and Acharjyo LN.(2002).** Diseases of Wild Felids. 1st edn. Reprint (P) Ltd. p.56.
- Rao AT and Acharjyo LN.(2003).** Diseases of Wild Ruminants. 1st edn. Reprint (P) Ltd. p.62.
- Schmidt GD.(1986).** Handbook of tapeworm identification. CRC Press. Inc. Boca Raton. Florida. p.675.
- Shirbhate MV.(2008).** Quantification of predation and incidence of parasitic infestation in Melghat Tiger reserve with special reference to tiger (*Panthera tigris*). *The Ecoscan.* 2(2) : 229 - 235.
- Soulsby E.JL.(2005).** Helminths Arthropods and Protozoa o Domesticated Animals. 7th edn. Bailliere Tindall. London. p.113, 152.
- Sunita Pradhan, Deepak Sharma, Bharkha Subba and Vikash Chettri. (2011).** Preliminary investigation on the parasites of mammals at Padmaja Naidu Himalayan Zoological Park , Darjeeling. *Zoo's Print.* Vol.26 (8) : 11 - 13.
- Youssefi MR, Hoseini SH and Esfandiari B.(2010).** Intestinal parasite of Persian leopard (*Panthera pardus saxicolor*) in Iran. *World J. Zoology.* 5(2) : 122 - 124.