

## 1

## A Case of Postpartum Cerebral Angiopathy

Seo Hyun Kim, M.D., Kyung Yul Lee, M.D., Il Nam Sunwoo, M.D.,  
Hyun Sook Kim, M.D.\*, Jin Il Jung, M.D.\*, Dong Ik Kim, M.D.\*

Department of Neurology, Neuroradiology\*, Yonsei University College of Medicine

Postpartum cerebral angiopathy is a benign, reversible clinicoradiologic syndrome. The clinical significance of this syndrome is the difficulty in differentiating it from other severe disorders such as subarachnoid hemorrhage and cerebral vasculitis. A 25-year-old woman who developed a severe headache, transient total blindness, and generalized tonic clonic seizures 14 days postpartum was admitted to our hospital. A MRI of the brain revealed a bilateral anterior cerebral artery (ACA) infarction. A cerebral angiography showed the narrowing of the M1 and M2 segments of the left middle cerebral artery (MCA), the right MCA M1 segment, and the A1 and proximal A2 segments of the right ACA. Also, it showed the narrowing of the proximal basilar artery portion from which the anterior inferior cerebellar artery arose, P1, P2, and P3 segments of the left posterior cerebral artery (PCA), and the right PCA P1 segment. With the treatment of nimodipine, the abnormalities on these studies were markedly improved two weeks later.

J Korean Neurol Assoc 18(3):353~355, 2000

**Key Words :** Cerebrovascular disorders, Pregnancy complications, Cerebral angiography

(postpartum cerebral angiopathy;  
PCA)  
가 100/70 mmHg  
2  
(oxytocin)  
가  
1-5 13  
14  
(cerebral vasculitis)  
150/100 mmHg  
가  
PCA 1 6 2  
25 가 2

(Fig. 1A).

110 mmH<sub>2</sub>O, 0/mm<sup>3</sup>, 49 mg/dl, 48  
mg/dl( 124 mg/dl) 가  
3 150, 110, 100/mm<sup>3</sup>  
Phenytoin 3 . Solucortef  
( 17 )

Manuscript received October 13, 1999.

Accepted in final form March 3, 2000.

\* Address for correspondence

**Il-Nam Sunwoo, M.D.**

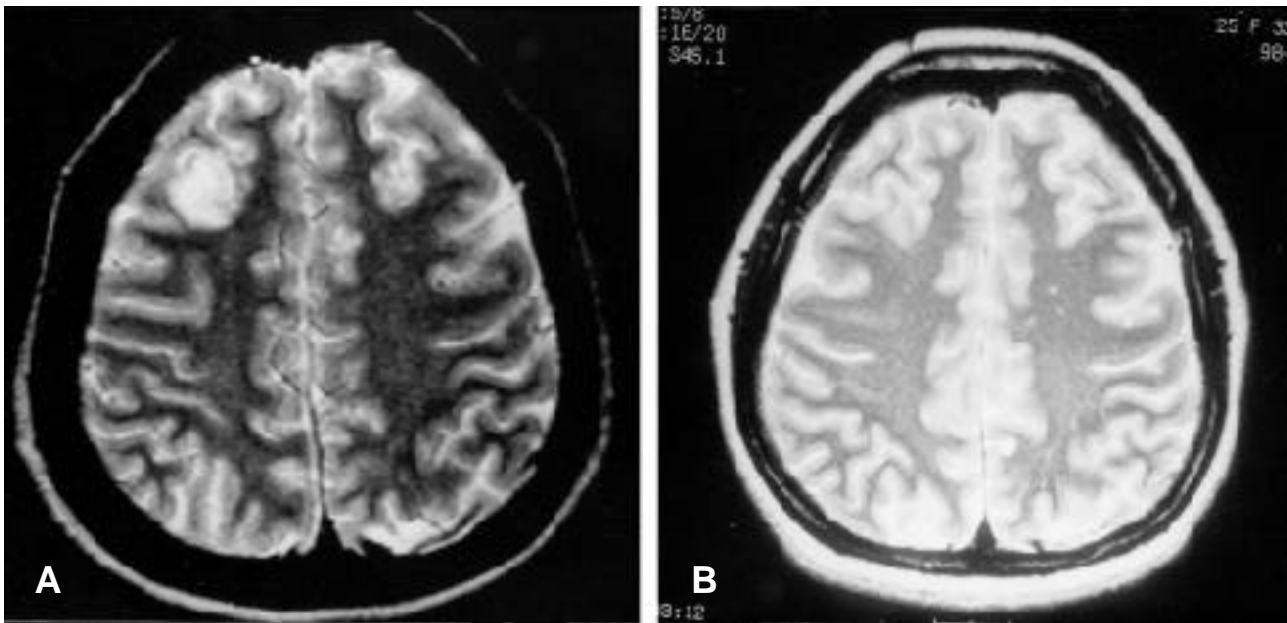
Department of Neurology,

Yonsei University College of Medicine,

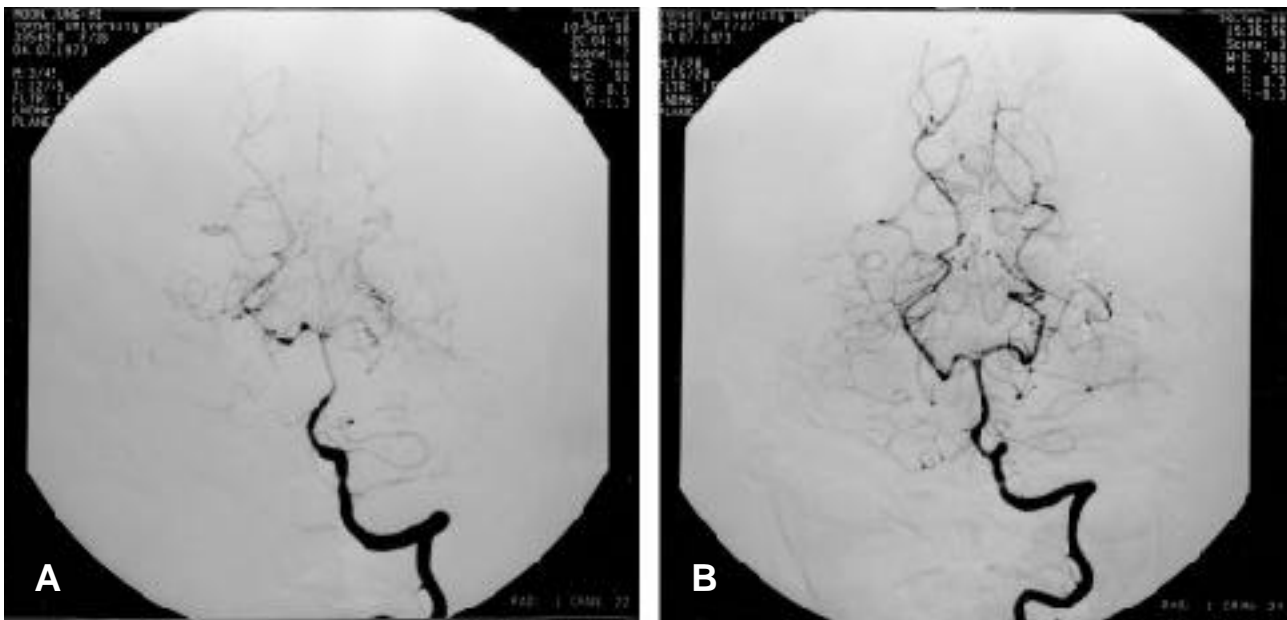
C.P.O. Box 8044, Seoul, 120-752, Korea

Tel : +82-2-361-5460, Fax : +82-2-393-0705

E-mail : sunwooin@yumc. Yonsei. ac. kr



**Figure 1.** Axial T2 weighted MRI performed 2 days after onset shows bilateral frontal lobe high-signal intensity lesions (A). MRI 4 days later, shows markedly decreased high-signal intensity lesions (B)



**Figure 2.** Left vertebral arteriogram performed 4 days after onset, anteroposterior views, shows multiple segmental narrowing of arteries (A). 19 days later, marked improvement (B) is seen.

150/90 mmHg  
 ESR 16 mm/hr, protein C 167%, protein S 85%, antithrombin III 123%, VDRL (-), RF 20 IU/ml, CRP 1.87 mg/dL, ANA (-), ANCA (-)

2 ( 18 )

M1, M2, A1, A2, P1, P2, P3, M1, P1

(Fig. 2A). 21

가 (Fig. 1B).

nimodipine 2, 35

(Fig. 2B).

thrombosis) (cerebral venous PCA

PCA<sup>1,2,5</sup>

48

postpartum eclampsia)<sup>6</sup> (late

occipital area) (parieto-<sup>7</sup>

가

“ (isolat-  
ed benign cerebral vasculitis) ”<sup>8</sup>

5 50

PCA

PCA

1994 1999

41 2 PCA

bromocriptine, ergonovine, isomethepten,  
lisuride, phenylpropanolamine<sup>1-4</sup>

<sup>9</sup>(pregnancy induced hypertension)

(vasomotor response)

가가

가 가<sup>1-4</sup>

PCA

ergot

가

<sup>5</sup>

PCA

magnesium sulfate<sup>1</sup> nimodipine<sup>10</sup>

hypervolemic therapy

PCA 가

25 2

PCA 1

REFERENCES

1. Comabella M, Alvarez-Sabin J, Rovira A, Codina A. Bromocriptine and postpartum cerebral angiography: a casual relationship? *Neurology* 1996;46:1754-1756.
2. Barinagarrementeria F, Cantu C, Balderrama J. Postpartum cerebral angiopathy with cerebral infarction due to ergonovine use. *Stroke* 1992;23:1364-1366.
3. Raroque HG, Tesfa G, Purdy P. Postpartum cerebral angiopathy: is there a role for sympathomimetic drug? *Stroke* 1993;24:2108-2110.
4. Roh JK, Park KS. Postpartum cerebral angiopathy with intracerebral hemorrhage in a patient receiving lisuride. *Neurology* 1998;50:1152-1154.
5. Bogousslavsky J, Despland PA, Regli F, Dubuis PY. Postpartum cerebral angiopathy: Reversible vasoconstriction assessed by transcranial doppler ultrasounds. *Eur Neurol* 1989;29:102-105.
6. Lubarsky SL, Barton JR, Friedman SA, Nasreddine S, Ramadan MK, Sibai BM. Late postpartum eclampsia revisited. *Obstet Gynecol* 1994;83:502-505.
7. Kim BK, Lee YS, Lee HB, Park SH. Cerebral vasospasm in eclampsia: report of a case. *J Korean Neurol Assoc* 1997; 15:394-398.
8. Raps EC, Galetta SL, Broderick M, Atlas SW. Delayed peripartum vasculopathy: cerebral eclampsia revisited. *Ann Neurol* 1993;33:222-225.
9. Kwon KH, Suk SH, Sunwoo IN, Bae JC, Cheong KH, Cho PZ. CT findings in eclampsia. *J Korean Neurol Assoc* 1993; 11:533-540.
10. Akins PT, Levy KJ, Cross AH, Goldberg MP, Schieber MH. Postpartum cerebral vasospasm treated with hypervolemic therapy. *Am J Obstet Gynecol* 1996;175:1386-1387.