

Aus der Klinik für Neurologie
Direktor: Prof. Dr. med. G. Deuschl
im Universitätsklinikum Schleswig-Holstein, Campus Kiel
an der Christian-Albrechts-Universität zu Kiel

**FUNCTIONAL AND STRUCTURAL CONNECTIVITY IN THE MOTOR SYSTEM IN
HEALTHY PEOPLE AND IN PATIENTS WITH PARKINSON'S DISEASE**

Inauguraldissertation
zur
Erlangung der Doktorwürde
der Medizinischen Fakultät
der Christian-Albrechts-Universität zu Kiel

vorgelegt von

ALEXANDRU HANGANU

Kiel 2014

1. Referent: Prof. Dr. Sergiu Groppa
2. Koreferent: Prof. Dr. J. P. Kutz-Buschbeck

Tag der mündlichen Prüfung: 18.04.2016

Zum Druck genehmigt, Kiel, den 18.04.2016

CONTENTS

Chapter 1	Introduction	
1.1	Parkinson's disease	6
1.2	Motor system	6
1.2.1	Primary motor cortex	8
1.2.2	Premotor cortex	9
1.2.3	Supplementary motor area	11
1.2.4	Cingulate motor area	12
1.3	Connectivity	13
1.3.1	General aspects of connectivity	13
1.3.2	Connectivity in Parkinson's disease	14
1.3.3	Connectivity research method. Transcranial magnetic stimulation	15
1.4	Concepts of the study	16
Chapter 2	Hypothesis and concepts	18
Chapter 3	Participants and methods	
3.1	Inclusion and exclusion criteria	19
3.2	Study design	
3.2.1	Reaction time in patients with Parkinson's disease	19
3.2.2	Changes of cortical thickness, cortical area and correlation with reaction time	22
3.2.3	Correlation between regional cortical area and the volumes of subcortical structures in patients with Parkinson's disease	24
Chapter 4	Results	
4.1	Reaction time in patients with Parkinson's disease	26
4.2	Correlation between reaction time and cortical thickness	28
4.3	Changes of cortical thickness and cortical area in patients with Parkinson's disease	30
4.4	Correlation between regional cortical area and the volumes of subcortical structures in patients with Parkinson's disease	32
Chapter 5	Discussion	
5.1	General considerations	34
5.2	Reaction time. Correlation between reaction time and cortical thickness. Functional connectivity	34
5.3	Cortical thickness and cortical area in PD. Correlation between cortical area and volumes of subcortical structures. Structural connectivity.	37
5.4	Hypothesis discussion	40
5.5	Summarizing remarks	42
5.6	Conclusions	42
Chapter 6	Summary	43
Chapter 7	Annex	
7.1	Bibliography	45
7.2	Informed consent, Information letter	56
7.3	Acknowledgements	57
7.4	Curriculum vitae	58

List of abbreviations

ANOVA – analysis of variance

CCZ – caudal cingulate zone

CMA – cingulate motor area

ISI – interstimulus interval

M1 – primary motor cortex

MEP – motor evoked potential

PMd – dorsal premotor cortex

PMv – ventral premotor cortex

RCZa – anterior rostral cingulate zone

RCZp – posterior rostral cingulate zone

RT – reaction time

MRI – magnetic resonance imaging

PD – Parkinson's disease

RMT – rest motor threshold

SA – stimulation asynchrony

SMA – supplementary motor area

TMS – transcranial magnetic stimulation

TP – testing pulse

VA –nucleus thalamicus ventralis anterior

VPLo –nucleus thalamicus ventralis posteriolateralis pars oralis

VL – nucleus thalamicus ventralis lateralis

VLc – nucleus thalamicus ventralis pars caudalis

VLo – nucleus thalamicus ventralis pars oralis

List of figures

Figure 1.1 – The human motor system	7
Figure 1.2 – Cortical connectivity patterns in healthy controls and patients with Parkinson’s disease	15
Figure 3.1 – Reaction time research paradigm	21
Figure 4.1 – ANOVA for <i>Group</i> x <i>Hand</i> x <i>SA</i> x <i>Pulse</i>	26
Figure 4.2 – ANOVA <i>Pulse</i>	27
Figure 4.3 – Correlation between reaction time and cortical thickness in healthy controls	29
Figure 4.4 – Correlation between cortical thickness and reaction time in patients with Parkinson’s disease	29
Figure 4.5 – Correlation between cortical thickness and reaction time in PD patients compared to healthy controls	30
Figure 4.6 – Regions with changed cortical thickness in patients with Parkinson’s disease compared to healthy controls	31
Figure 4.7 – Regions with changed cortical area in patients with Parkinson’s disease compared to healthy controls	32

List of tables

Table 3.1 – Changes of cortical thickness in patients with Parkinson’s disease compared to healthy controls	31
Table 3.2 – Correlation matrix between volumes of subcortical segmentations and regions of cortical area	33

Chapter 1 INTRODUCTION

1.1 Parkinson's disease

Parkinson's disease (PD) is the second most frequent neurodegenerative disorder, affecting up to 2 percent of individuals 65 years and older and nearly 10 percent of people older than 80 years (Rijk et al., 1997; von Campenhausen et al., 2005). PD is characterised by the loss of specific subsets of dopaminergic neurons in the substantia nigra pars compacta which project to the dorsal striatum (McGeer et al., 2004). However, PD is considered a multisystemic disorder in which predisposed neuronal types in specific regions of the peripheral, enteric and central nervous systems become progressively involved by presenting neuronal loss, Lewy bodies and Lewy neuritis (Del Tredici et al., 2002).

The neuropathology of PD is associated with alpha-synuclein-containing Lewy-Bodies (Sabbagh et al., 2009). The distribution pattern of alpha-synuclein develops in a topographically predictable sequence in six stages, during which components of the olfactory, autonomic, limbic and somatomotor systems become progressively involved. In the final stages (Braak V-VI) the pathological process might reach the sensory association cortex, prefrontal cortex and finally the entire neocortex (Braak et al., 2006).

Main clinical symptoms of PD are motor: tremor, rigidity, slowness of movement and postural instability. Yet, non-motor symptoms are also common: up to 40% of patients suffer from depression, up to 40% have mild cognitive impairment in the early phase of the disease and up to 80% of PD patients will develop dementia (Aarsland et al., 2011; Buter et al., 2008; Williams-Gray et al., 2007). Other symptoms include sensory, sleep and emotional impairments.

Modern treatment methods are effective in managing the early motor symptoms by using levodopa and dopamine agonists. Yet, as the disease progresses the medication eventually becomes ineffective and the last resort are surgical interventions like deep brain stimulation procedures.

1.2 Motor system

The clinically manifest phase of PD reveals itself mainly with motor impairments (tremor, rigidity) and changes in the motor system. Initial research on the function of motor cortex have started around 1950's with the invasive mapping of the motor cortex (Penfield et al., 1950). This led to the description of a motoric map along the precentral gyrus known as the primary motor cortex (M1). Further research showed that stimulation of regions anterior

to M1 causes more complex movements. Today the cortical motor system can be divided as follows (Figure 1.1):

- Primary motor cortex, responsible for generating nervous impulses that control movement's execution.
- Premotor cortex, responsible for motor guidance of movements and controlling proximal muscles of the body and trunk.
 - dorsal premotor cortex (PMd)
 - ventral premotor cortex (PMv)
- Supplementary motor area (SMA), responsible for planning and coordinating complex movements like those that need both hands.
- Cingulate motor areas (CMA), responsible for preparing and executing movements that have been practiced and memorised (Picard et al., 1996).
- Posterior parietal cortex, responsible for transformation of visual information in motor commands.
- Other regions involved in motor activity – cerebellum, basal ganglia.

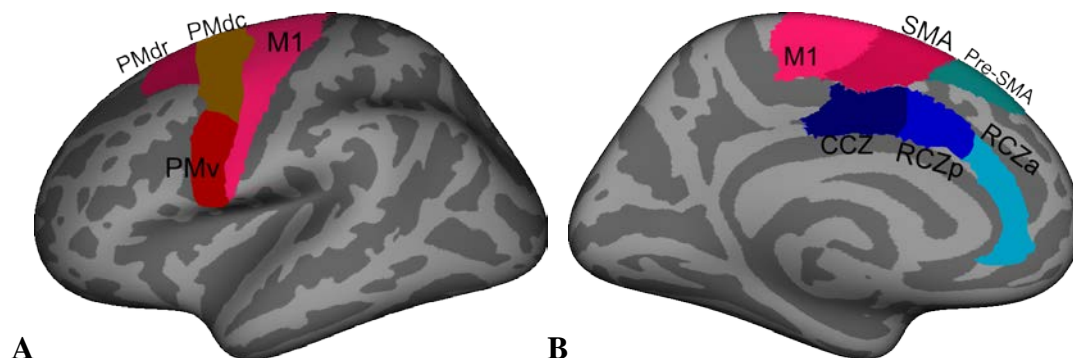


Fig. 1.1. The human motor system. Inflated left hemisphere of the brain in lateral (A) and medial view (B). M1 = primary motor cortex; PMdr = rostral dorsal premotor cortex; PMdc = caudal dorsal premotor cortex; PMv = ventral premotor cortex SMA = supplementary motor area; CCZ = caudal cingulate zone RCZp = posterior rostral cingulate zone; RCZa = anterior rostral cingulate zone. CMA = CCZ+RCZp+RCZa. Figure based on Brodmann area maps in FreeSurfer. Figure adapted (Picard et al., 2001; Rizzolatti et al., 1998b).

The functional organization of motor regions is based on two gradients (Geyer et al., 2000a; Passingham, 1995; Rizzolatti et al., 1998b):

- A. Posterior-to-Anterior („Simple” – to – „Complex”). Posterior areas are active in case of ”simple” movements (when movement is a routine) while more anterior areas become active in case of more ”complex” movements (when movement is not a routine).

B. Ventrolateral-to-Dorsomedial („Exteroceptive guidance” – to – „interoceptive guidance”). Ventrolateral areas are used when the movement is guided by exteroceptive triggers (visual, auditory) while dorsomedial areas are used when movement is guided by ”internal triggers” that can represent internal feedback circuits (e.g., basal ganglia) and/or proprioceptive.

1.2.1 Primary motor cortex

Structure. The primary motor cortex (M1) is situated in the precentral gyrus. M1 is somatotopically organized and the volume of cerebral matter assigned for a specific body part represents the volume of control that M1 performs over these areas. M1 is subdivided into a rostral area (M1r) and a caudal area (M1c), but this division does not apply to the face area (Stepniewska et al., 1993). These two regions show differences with respect to cytoarchitectonic (pyramidal cells in M1r are smaller than in M1c), connectivity and electrophysiological properties (intracortical micro-stimulation thresholds are higher in M1r) (Matelli et al., 1989; Strick et al., 1982). These two areas have each a somatotopic representation of the first finger, index and possibly the middle finger (Geyer et al., 1996). Morphologically M1 is divided into 6 layers: supragranular, internal granular, two infragranular, internal pyramidal and fusiform (multiform) layer. Pyramidal cells are the main type of cells within the infragranular and internal pyramidal layers and these cells emit the majority of corticobulbar and corticospinal fibres.

Connectivity. The main output of the motor cortex is the corticospinal tract which has several origins: 50% of fibres start from M1, 10-20% from PMd and PMv, 10-20% from SMA and 15-20% from CMA (Dum et al., 1991). Subcortically, M1 projects to the striatum, mesencephalon, brainstem and the spinal cord (Jones et al., 1977). The majority of inputs to M1 come from the parietal cortex (37%, including direct projections from the primary and secondary somatosensory cortices, and especially to M1c) and from secondary motor areas (27%, including somatotopic projections from PMd, SMA and CMA, and especially to M1r) (Ghosh et al., 1987). M1 also receives subcortical inputs (36%) from the basal ganglia (via the ventro-anterior thalamic nucleus, VA) and the cerebellum (via the ventro-lateral thalamic nucleus, VL) (Matelli et al., 1989; Strick et al., 1974). The posterior parietal cortex (PE, area 5) provides M1 with information about the location of body parts – the PE-M1 skeletomotor circuit (Caminiti et al., 1996).

Function. The basic function of M1 is to control the movement execution. It is assumed that M1r is preferentially involved in early stages of the movement, which include postural adjustment for maintaining balance in order to reach the objects, while M1c is involved

predominantly in the late stages of the movement, when the cutaneous and kinaesthetic feedback is crucial and a fine finger adjustment is needed (Stepniewska et al., 1993). But in order to perform a movement, the neurons within M1 have to choose the direction to be reached. A single M1 neuron forms synapses and embranchments with multiple groups of spinal neurons and can determine the contraction of multiple muscles (Penfield et al., 1950). Thus, in order to perform a directed movement, the neuronal population vector initially denotes the target, then it rotates until the necessary target is reached and the final reach direction is chosen as a sum of vectors of the direction to be reached and the neurons to be stimulated (Georgopoulos et al., 1988). As a result, the outputs from a big M1 area converge at the level of spinal neurons that control muscles and determine the movement of only one body part (Geyer et al., 2000a). This way, the function of M1 represents the activity of each cell as a singular "vote" for a specific direction of movement (Bear et al., 2007).

1.2.2 Premotor cortex

Structure. Anterior from M1 is situated the premotor cortex, which is subdivided in dorsal premotor (PMd) and ventral premotor (PMv) and each of them is further subdivided in rostral (PMdr, PMvr) and caudal (PMdc, PMvc) areas (Picard et al., 2001). PMvr was further subdivided into PMvrab (located on bank of the arcuate sulcus in primates) and PMvrc (on the cortical convexity of the arcuate sulcus). Specifically in PMdr, when compared to M1, there is a decreased number of Betz giant cells and an increased intra-cortical micro-stimulation threshold (Gabernet et al., 1999; Geyer et al., 2000b; Petrides et al., 2000). PMv is totally agranular and has somatotopic representations of the arm, neck, face and mouth (Gentilucci et al., 1988; Grèzes et al., 2001). PMvc comprises neurons that are primarily bimodal (56%) somatosensory and visual receptive fields, and unimodal (44%) which are typically tactile field (Graziano et al., 1994). Also, PMvr is specific for the presence of "canonic" neurons (in PMvrab) and "mirror" neurons (in PMvrc) with very specialized functions (Geyer et al., 2000a; Rizzolatti et al., 1998b).

Connectivity. PMdc sends projections to M1 and descending projections to the spinal cord (Dum et al., 1991; He et al., 1995). PMdr projects to the superior colliculus, reticular formation in the brainstem and strong connections to the prefrontal cortex (Geyer et al., 2000a; Lu et al., 1994). PMdr doesn't project to M1 or spinal cord and has almost no connections with PMdc (Dum et al., 1991; He et al., 1993; Kurata, 1991; Luppino et al., 1993; Wang et al., 2001). PMv send projections to M1 from nearly all the PMvc and a small part of PMvr (Luppino et al., 1993). Also dorsal PMvc (hand representation) sends projections to

reticular formation and spinal cord, while ventral PMvc (face representation) sends projections to facial nucleus (Dum et al., 1991; He et al., 1995). Both PMd and PMv receive inputs from posterior parietal cortex, from associative sensory cortex as well as feedback from basal ganglia through thalamic VA and VL nuclei (Matelli et al., 1998; Rizzolatti et al., 1998b). PMdc is the target of connections from putamen and pallidum, the ventral part of PMdr receives afferents from nucleus caudatus and the dorsal area of PMdr is part of the subcortical oculomotor circuit (Matelli et al., 1996). PMvrc receives inputs from prefrontal cortex strong connections from pre-SMA, while PMvc has more connections from SMA. Subcortically, PMvr receives cerebellar inputs through area X Olszewski, as part of the cerebellar-thalamic-cortical loop and additional projections from VPLo and VLc, while PMvc receives thalamo-cortical and strio-pallidary inputs from VLo, VLc and VPLo (Geyer et al., 2000a).

Function. Premotor areas are involved in action planning (together with basal ganglia) and refinement of movements based on sensory information (together with cerebellum) (Dum et al., 1991). Specifically PMd is involved in preparing and generating the movement, but it depends on the observational signals (Boussaoud, 1995; Horwitz et al., 2000; van Mier et al., 1998). PMdc has a dominant function for movement initiation and memorizing after analysing proprioceptive, tactile and visual responses, while PMdr is activated only during visual stimulus (Halsband et al., 1982; Kurata et al., 1994; Petrides, 1982). Also PMd activity evolves when learning a new selection mapping, and especially PMdr is involved in the cognitive process (Boussaoud, 2001; Mitz et al., 1991). PMd is also involved in localizing the stimulus, even if the stimulus location isn't task-relevant, thus it's more associated with choosing the target direction, while M1 with limb's direction (Boussaoud et al., 1993; di Pellegrino et al., 1993; Shen et al., 1997).

PMv is involved in planning and executing hand movements (Schubotz et al., 2003). PMvc is activated mainly during proximal hand movements while PMvr during distal movements (Gentilucci et al., 1988). Also PMvc codifies a space of specific coordinates for the body parts, which are associated with the somatosensory fields of the bimodal neurons (Gentilucci et al., 1988; Graziano et al., 1994). The canonic neurons in PMvrab have four different functions: grasping, holding, tearing, manipulating (Rizzolatti et al., 1988). Specifically, canonic neurons are involved in the transformation of 3D objects in a certain hand construction (Gallese et al., 1994; Murata et al., 1997). The mirror neurons in PMvrc are active when observing a person performing a specific action and afterwards performing that similar action. Simple observation of the person, the object or grasping the object with

another object (e.g. forceps) does not reveal any discharges in the mirror neurons. Additionally, mirror neurons are active when grasping the object in darkness (Rizzolatti et al., 1998a).

1.2.3 Supplementary Motor Area

Structure. As part of the motor system, the supplementary motor area (SMA) is located on the medial part of the frontal lobe, as a continuity to M1 and PMd, and is divided into SMA proper and pre-SMA based on histochemical, cytoarchitectonical, connectivity and physiological criteria (Luppino et al., 1990; Matelli et al., 1985; Matelli et al., 1991; Matsuzaka et al., 1992). SMA has an increase of cellular density in the inferior IIIrd layer and superior part of Vth layer, while pre-SMA is clearly laminated and one of its features is the Vth layer which is dark and well delimited from IIIrd and VIth layers. SMA has a somatotopic representation: caudally the leg area and rostrally the hand area and a small oro-facial representation. Pre-SMA contains only a somatotopic representation for the hand (Luppino et al., 1991). SMA proper has been further suggested to be divided in rostral and caudal SMA (Kaas, 1995; Vorobiev et al., 1998).

Connectivity. SMA sends projections to M1, the spinal cord – thoraco-lumbar (from the caudal part of SMA) and cervico-thoracic segments (from the rostral part of SMA), and to the contralateral SMA (Barbas et al., 1987; Dum et al., 1991; He et al., 1995; Keizer et al., 1989; Lu et al., 1994; Muakkassa et al., 1979; Rizzolatti et al., 1996). Pre-SMA has only corticobulbar projections to the superior colliculus and the reticular formation in the brainstem (Geyer et al., 2000a; He et al., 1993; Keizer et al., 1989; Lu et al., 1994). SMA receives thalamic inputs from VLo, putamen and pallidum and cortical inputs from PMdc and PMvc (~25%), PMdr, PMvr, pre-SMA (~20%), secondary somatosensory, posterior parietal (~20%), cingulate cortices (~20%) and M1 (~20%). Pre-SMA receives thalamic inputs from VApc, area X, dorsal medial thalamic nucleus, caudate and cerebellum and cortical inputs from PMdr, PMvr (~40%), prefrontal cortex (~20%), cingulate cortex (~20%), PMdc, PMvc, SMA (~15%), posterior parietal and superior temporal areas (~5%) (Alexander et al., 1986; Matelli et al., 1996; Rizzolatti et al., 1996; Rouiller et al., 1994).

Function. SMA is involved in temporal organization of movements and planning of the learned sequences (Jenkins et al., 2000). This is the region of preparation potential, which starts a second before the movement is initiated and the stimulation of SMA creates the necessity of movement (Geyer et al., 2000a). Additionally, a large proportion of SMA cells (41%) are specialized in perimovement activity only (the activity immediately before, during

or immediately after the movement (Churchland et al., 2010)). In SMA the perimovement is movement specific, independent of sequence in 61% of cases, while in pre-SMA, though it is less common, the perimovement activity reflects a particular movement in a particular sequence (Matsuzaka et al., 1992; Tanji, 1996). It has been shown that bilateral lesions of SMA block the learning of new motor sequences, yet pre-SMA has been shown to have a stronger involvement in cognitive processes as well as a role in preserving the learned motor sequences (Boussaoud, 2001; Grafton et al., 1998; Jenkins et al., 1994). In fact, the neurons preferring to learn new sequences are more common for pre-SMA (~25%) than in SMA (~10%), yet the pre-SMA activity depends on visual input, because inactivation of pre-SMA impairs the performance of motor sequences from memory when visual cues are absent (Shima et al., 1998). Pre-SMA is also involved in monitoring the task performance and switching between the tasks (Hikosaka et al., 2002; Matsuzaka et al., 1992). Unilateral lesions of SMA/pre-SMA cause transient akinesia and bimanual dyscoordination (mirror movements), while bilateral SMA/pre-SMA lesions cause a lasting deficit in selecting and initiating the movement in the absence of an indication what to do, "when" – is not important (Brinkman, 1981; Goldberg, 1985; Thaler et al., 1995).

1.2.4 Cingulate motor areas

Structure. The cingulate sulcus contains three separate motor areas which are parts of the motor system: the rostral anterior cingulate zone (RCZa), rostral posterior cingulate zone (RCZp) and caudal cingulate zone (CCZ) (Picard et al., 1996). RCZa and CCZ have been described to have a somatotopic face representation (Picard et al., 1996).

Connectivity. CMA has been shown to send projections to limbic structures such as retrosplenial, parahippocampal, entorhinal, temporal pole (Morecraft et al., 1998). CMA receives projections from the dorsolateral prefrontal cortex (8/9/10/46), orbitofrontal, insular, posterior cingulate, premotor cortices and M1 (Hatanaka et al., 2003; Morecraft et al., 1993; 1998; Morecraft et al., 2000; Morecraft et al., 2004; Picard et al., 1996). RCZ receives projections from anteromedial occipital, ventral prefrontal, posterior orbitofrontal cortices, rostral putamen, ventral anterior and ventrolateral thalamus, while CCZ receives only from ventrolateral thalamus (Hatanaka et al., 2003; Morecraft et al., 2004; Picard et al., 1996). Additionally, in humans CMA receives projections from M1, while no such connections have been described in monkeys (Habas, 2010). CMA is also part of the corticofacial, corticopontine and corticorubral tracts (Picard et al., 1996).

Function. CMA has a role in preparing and executing movement sequences which have been well practiced and memorized (Picard et al., 1996). CCZ specifically, is activated especially in relation to movement execution (Fink et al., 1997; Kwan et al., 2000; Petit et al., 1998; Picard et al., 1996). Also, CCZ and SMA have the tendency to be co-activated during manual tasks, but still CCZ activation is well separated from SMA activation (Koski et al., 2000; Picard et al., 2001). CCZ is also activated during painful stimuli (Kwan et al., 2000). RCZ is involved in "conflict monitoring" (an evaluative function) and „attention/selection of action" (a motor function) (Botvinick et al., 1999; Carter et al., 2000; Petersen et al., 2004). It was further suggested that conflict monitoring reflects the properties of RCZa while selection of action is specific for RCZp (Picard et al., 2001). Additionally RCZ activation was associated with a word generating task (Crosson et al., 1999).

1.3 Connectivity

1.3.1 General aspects of connectivity

Cortical and subcortical grey matter regions are connected and interact through the white matter fibre pathways, which form the brain's communication network. The physical condition of a given pathway will influence how effectively it can be used to transmit signals between brain regions and might thereby influence performance of behaviours that rely on that pathway (Fields, 2008). Individual differences in white matter structure may therefore be expected to correlate with variations in behavioural performance (Johansen-Berg, 2010; Scholz et al., 2009). In addition, changes in white matter structure over time might accompany behavioural decrements or gains in performance due to disease, recovery or learning.

Brain connectivity has three main categories: structural, functional and effective. **Structural connectivity** describes a physical network of connections, which may correspond to fibre pathways or individual synapses (i.e., a network of anatomical links). It includes the biophysical attributes of structural connections that are expressed in parameters such as connection strength or effectiveness (Bullmore et al., 2009). The physical pattern of these connections may be thought of as relatively static at shorter time scales (seconds to minutes), but may be plastic or dynamic at longer time scales (hours to days), for example during learning or development (Sporns, 2009).

Functional connectivity is defined as the pattern of activity between distributed and often spatially remote neuronal groups (Friston et al., 1993; Friston, 1994). There is a significant overlap between anatomical network modules and functional systems in the cortex,

yet the functional activity does not necessarily coincide with the actual causal effects of the structural model (Chen et al., 2008). Functional connectivity can be empirically measured as a correlation/covariance, spectral coherence or phase locking and it is highly time dependent, i.e. it changes on time scales that are significant relative to experimental perturbations and the temporal progression of cognitive states. In large-scale brain networks functional connectivity can change within hundreds of milliseconds.

Effective connectivity is defined as the network of causal effects of one neural system over another (Büchel et al., 2000; Friston, 1994). Inferring effective connectivity is possible in two ways – through assessing the effects of perturbations, or by performing sophisticated time series analysis. Model-free attempts to reconstruct patterns of causal influence usually quantify the gain in information about the future state of one time series from observing the past state of another. Effective connections usually change on fast time scales.

1.3.2 Connectivity in Parkinson's disease

Although the main site of neurodegeneration in Parkinson's disease (PD) is a small subcortical region in the basal ganglia, neuroimaging studies showed widespread changes in the neuronal activity within both subcortical and cortical structures (Jahanshahi et al., 1995; Playford et al., 1992; Rascol et al., 1997; Sabatini et al., 2000a; Samuel et al., 1997; Thobois et al., 2004; Turner et al., 2003). Basal ganglia controls the functioning of the frontal regions by five segregated basal ganglia thalamo-cortical circuits: the lateral orbitofrontal circuit, the “motor circuit” (which is primarily directed to the precentral motor fields), two prefrontal circuits and the oculomotor circuit (Alexander et al., 1986; Alexander et al., 1990; Mehler-Wex et al., 2006). Further, it has been suggested that in PD there is a switch from the use of striato-mesial frontal circuits to parietal-lateral premotor circuits (Samuel et al., 1997). Several studies confirmed this shift. For example a Wisconsin Card Sorting Task study in non-demented PD patients, determined a significant activation bilaterally in the RCZa (BA 32), PMv, PMd (BA 6) and other non-motor areas, while in healthy controls these regions showed a reduction of the signal (Monchi et al., 2001). Other studies showed changes in the functional and effective connectivity in PD during rest, motor tasks and cognitive tasks, suggesting that normal functional networks are disrupted by the basal ganglia degeneration in PD, and alternative networks may be activated as a compensatory strategy (Helmich et al., 2009a; Palmer et al., 2009; Rowe et al., 2002; Wu et al., 2009). Helmich and colleagues showed in a recent study the presence of alternative networks in PD when compared to healthy controls, e.g. the anterior putamen presented an increase of functional connectivity

with parietal operculum, supramarginal gyrus, insula and inferior temporal gyrus (Helmich et al., 2009b). On the other hand, previous MRI studies showed that in PD the posterior putamen is affected the most, and indeed the posterior putamen showed reduced functional connectivity with CMA, primary and secondary somatosensory cortices and supramarginal gyrus, suggesting the presence of a shift in cortico-striatal connections from posterior putamen to anterior putamen (Brück et al., 2006; Caspers et al., 2006; Helmich et al., 2009b).

Other studies reported a functional disconnection of SMA, with compensatory amplification of lateral premotor systems, probably determined by primary pre-SMA and SMA dysfunction, regions that are especially vulnerable in PD (Haslinger et al., 2001).

Palmer and colleagues also reported connectivity differences between control subjects and PD with respect to basal ganglia, thalamic and cortical connections (Figure 1.2), suggesting that not only the output from the basal ganglia is disrupted in PD, but the input connections to the basal ganglia are functionally impaired as well (Palmer et al., 2010; Rektorova et al., 2007). Additionally PD subjects had a unique pattern of connectivity from the cerebellum, putamen, globus pallidus, thalamus and right caudate (Figure 1.2). Nevertheless, novel connections reflected the functional connections, rather than anatomical ones (Palmer et al., 2010).

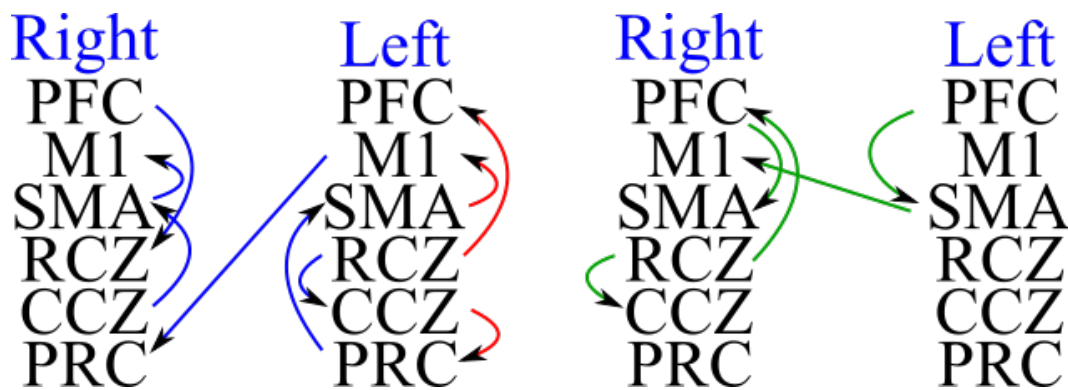


Fig. 1.2. Cortical connectivity patterns in healthy controls and PD patients. Right/Left = right/left hemisphere. Blue connections are present only in healthy controls. Red connections are present in healthy controls and PD patients. Green connections are present only in PD patients. PFC = prefrontal cortex, M1 = primary motor cortex, SMA = supplementary motor area, RCZ = rostral (anterior) cingulate cortex, CCZ = caudal (posterior) cingulate cortex, PRC = precuneus. Figure adapted (Palmer et al., 2010).

1.3.3 Connectivity research methods. Transcranial magnetic stimulation.

A widely used tool for measuring the connectivity is the transcranial magnetic stimulation (TMS). TMS is a non-invasive method for stimulating the human cortex through intact skull (Barker et al., 1985). Using the principle of electromagnetic induction, the rapidly

alternating magnetic pulses passing through a coil placed over subject's head, reach the brain with neglectable attenuation and inducing a secondary ionic current in the brain. The power of electric current in the coil is 2-10 kA, power of induced magnetic field is 1-2 T, magnetic field is present for approximately 200 μ s and the area that can be stimulated is almost 3 cm² and 2 cm in depth (Ebmeier et al., 2001; Maeda et al., 2003). The region to stimulate a nervous fibre is the place along its length in which sufficient current passes through its membrane and causes a depolarization (Abdeen et al., 2002; Barker, 2002; Maccabee et al., 1993).

In the field of motor control TMS is used to study the function in two main ways: by testing the connectivity between structures and by interfering with the function of specific brain areas. The simplest example of TMS connectivity is the motor evoked potential (MEP) in response to stimulation of motor cortex. This is the consequence of an impulse transmitted through at least two synaptic connections from corticospinal tract to spinal motoneuron at the spinal cord and from peripheral motor axon to muscle in the periphery. However, though the consequence of activity in corticospinal tract is easy to measure, many other outputs are activated by TMS applied on the level of motor cortex. A number of techniques are now available to detect motor control outputs after applying the TMS to a variety of sites in cortical, subcortical and brainstem regions.

One method for studying connectivity with TMS is the usage of multifocal TMS, using several coils to detect inputs from other areas of the cortex onto the motor cortex (Siebner et al., 2003). This method uses a standard single TMS pulse to motor cortex evoking an MEP in the target muscle, but prior to this pulse a conditioning TMS pulse can be given by a second stimulator on another region of the scalp. If the conditioning stimulus changes the MEP amplitude, then we can conclude that there is an influence of the conditioning site on the motor cortex. If the interval of this influence is short, then the effect is likely to be produced by a direct pathway linking the two regions (Rothwell, 2010).

1.4 Concepts of the study

1) It has been shown that PD patients have an impaired RT with an increase of more than 30% in RT when compared to age-matched healthy controls (Wilson, 1925). Yet, other studies revealed the presence of large variations with respect to RT in PD – some parkinsonians being quite slow, whereas others having a relatively normal RT (Evarts et al., 1979). This can be caused by the fact that the speed of movement and the speed of response initiation may be independently impaired in PD even in the same patient when comparing the

two limbs (Evarts et al., 1981). RT is a valuable parameter for understanding the functional activity in the cortical motor regions, the correlation between RT and cortical parameters might reveal the specific changes in the cortical motor regions.

2) It has been reported that neurons within the cerebral cortex are organized into ontogenetic columns that run perpendicular to the surface of the brain (Mountcastle, 1997). The radial unit hypothesis of cortical development argues that the cells within a column share a common origin and the size of the cortical area is driven by the number of columns while the cortical thickness is influenced by the number of cells within a column (Rakic, 1988; Rakic, 2007). Additionally, it has been suggested that this parameter reflects the state of the underlying white matter fibres, and more tension or shrinkage of the white matter fibres could lead to deeper sulci and extended cortical area indirectly imaging white matter tract damage (Van Essen, 1997). Thus, cortical thickness and cortical area are parameters that can be used to analyse the cortical morphology.

3) Five segregated basal ganglia thalamo-cortical circuits have been described, by which the control over the functioning of the frontal regions is performed (Alexander et al., 1986). The “motor circuit” (which is primarily directed to the precentral motor fields) together with the two prefrontal circuits (which project to the dorsolateral prefrontal and lateral orbitofrontal cortex), the oculomotor circuit (leading to the frontal and supplementary eye fields), and the limbic circuit (connected to the cingulate and medial orbitofrontal cortex) might be mainly involved in inducing the structural cortical changes in PD (Alexander et al., 1990; Mehler-Wex et al., 2006). Based on this concept, PD patients might present changes in the cortical thickness and cortical area parameters in the motor areas, dorsolateral prefrontal cortex, the orbitofrontal cortex and the cingulate region.

4) Previously it has been shown that caudate, putamen and thalamic nuclei volumes are significantly smaller in PD than in age-matched healthy controls, and the volume decline in PD did not correlated with age or sex (Lisanby et al., 1993). Nevertheless, the changes in the parameters of cortical morphology in the motor areas in PD might reveal a correlation with the volumes of subcortical nuclei.

Chapter 2 HYPOTHESIS AND AIMS

This study had the following aims:

- 1) to determine the reaction time in patients with Parkinson's disease in comparison to healthy controls.
- 2) to analyse the changes of the cortical integrity in patients with Parkinson's disease in comparison to healthy controls.
- 3) to analyse the correlation between reaction time and cortical thickness in patients with Parkinson's disease.
- 4) to analyse the correlation between the cortical (specifically the cortical area parameter) and the subcortical changes (specifically the volumes of segmented subcortical structures) in patients with Parkinson's disease.

The hypotheses for this study were:

- 1) Reaction times in patients with Parkinson's disease are significantly slower compared to healthy controls.
- 2) Reaction times in patients with Parkinson's disease correlate with cortical thickness. This correlation differs in healthy controls and in patients with Parkinson's disease.
- 3) Cortical thickness and cortical area show significant changes in Parkinson's disease when compared to healthy controls.
- 4) Cortical integrity correlates with the volumes changes of segmented subcortical gray matter structures.

Chapter 3 PARTICIPANTS AND METHODS

3.1 Inclusion/exclusion criteria

TMS criteria. For healthy controls the criteria were chosen according to safety aspects for TMS and MRI, in order to minimize the adverse effects. **Inclusion:** (a) healthy controls, men and women, with age corresponding to the PD group (mean 60 years) (b) no neurological pathologies, (c) written consent of the participant. The **exclusion** criteria are in accordance with those previously described in the safety guidelines (Rossini et al., 1994).

MRI criteria. The inclusion criteria for MRI images were: (1) only MRI images of 3 Tesla, (2) MRI examination should be performed the closest possible to the TMS testing day, (3) no visible neurological, structural deficits or specific anomalies on MRI images.

Criteria for patients with Parkinson's disease. For patients with PD the criteria for **Inclusion** were: (a) patients with diagnosis of Parkinson's disease and without confirmed dementia according with DSM-IV, (b) patient's written consent. Additional **exclusion** criterion was the absence of intracerebral implants (e.g. deep brain stimulation electrodes).

3.2 Study design

3.2.1 Reaction time in patients with Parkinson's disease

3.2.1.1. Healthy subjects collective description

In this study thirteen healthy controls (HC) were included (nine men, mean age \pm s.d.: 54.4 \pm 7.4 years) and fourteen patients with PD (five men, mean age \pm s.d.: 66.5 \pm 7.6 years). All subjects were right-handed, according with Edinburgh Handedness Inventory, and all presented written informed consent for the study (Oldfield, 1971). Procedures for the experiment have been approved by the Ethics Committee of Christian-Albrechts University in Kiel, and were processed according to Helsinki Declaration (Annas, 1998).

3.2.1.2. Transcranial Magnetic Stimulation

We applied TMS to examine the corticospinal motor projections' functional integrity. Specifically, this study was based on the property of TMS to produce a synchronized activation of cortical neurons, followed by a long-lasting inhibition – a transient effect that is usually mentioned as a "virtual lesion" and was widely used to examine the functional relevance of the stimulated area in behaviour (Jahanshahi et al., 1999; Pascual-Leone et al., 2000; Walsh et al., 2000).

For this study we used two "P Stim 160 stimulator" devices (MAG & MORE GmbH, München, Germany), connected with two minicoils of special modified configuration of figure-eight design with an external diameter of ~10 cm, that were applied over left M1 and PMd regions. The coils of figure-eight design are capable to stimulate the brain regions more focally (Daskalakis et al., 2002; Gershon et al., 2003). The changed geometry of the used coils, shifted the maximal stimulation in the x-axis away from the geometric centre of the coil towards one edge of the coil (Groppa et al., 2012). The magnetic stimulus that was used had a biphasic configuration of the pulse, which was shown to produce a quick alternative electric field with a lower energetic usage than the monophasic pulse (Daskalakis et al., 2002).

The electrical potential, which represents the response to motor cortex or motor pathways stimulation and is defined as the Motor Evoked Potential (MEP), was registered from the peripheral muscle using surface electrodes (Maeda et al., 2003). Based on the highest evoked MEP results in the contralateral FDI muscle, we found the spot on the skull of the hand motor area in the region of the left M1. The optimal position for activating the FDI muscle was found by moving the coil in steps of 0.5 cm around the hand motor area. The regions where the applied stimulus with a slight over threshold intensity, produced permanently the highest MEPs with the deepest waves in the contralateral first dorsal interosseus (FDI) muscle (the motor hot spot), were marked with a red marker by colouring the coil's borders. After that, the position of the coil for the left PMd was defined, based on the position of the motor hot spot. One positron emission tomography study showed that the localization of PMd is ~2 cm anterior from the hand area in the motor cortex (Fink et al., 1997). The coil was fixed under an angle of 45-55 degrees from the median line of the central sulcus, inducing a postero-anterior current in the stimulated cortex. In the coil applied over the PMd site, the direction of the pulse was changed, in order to make the stimulation in the same direction as in M1. The small diameter of these coils and the type of the handle, allowed the positioning of each coil over the target region at the optimal level.

MEPs were registered bilaterally from the FDI and adductor pollicis brevis muscles on the right hand, using electrodes with 9 mm diameter and AgCl surface. The active electrode was placed on the muscle pulp, and the reference electrode at the level of metacarpophalangeal joint of the index finger. FDI muscle was the target for MEP registrations. MEP responses were amplified using Digitimer D360 amplifier (Digitimer Ltd, Welwyn Garden City, Herts, UK), by filtering from 3 Hz up to 1 kHz. Signals were digitalized using laboratory interface CED 1401 and were saved at the frequency of 5 kHz. In order to register base EMG activity during the measurements, EMG signals were continuously monitored

acoustically. The peak-to-peak amplitude of MEPs were analysed using a personal computer and the software NuCursor (J. Rothwell, Neurology Institute, London University College, GB).

After positioning the coils, the rest motor threshold (RMT) was determined. RMT is defined as the minimum TMS intensity (expressed as a percentage of maximum stimulator output) that elicits reproducible MEPs in a fully relaxed target muscle in 50% of 10 to 20 successive trials (Rossini et al., 1994).

Test pulse (TP) over M1 was adjusted to evoke an MEP of 0.5 mV peak-to-peak amplitude. For stimulating the PMd, we used the intensity of 90% of the RMT (conditioning pulse) determined over M1. The conditioning pulse over PMd was applied after the TP on M1.

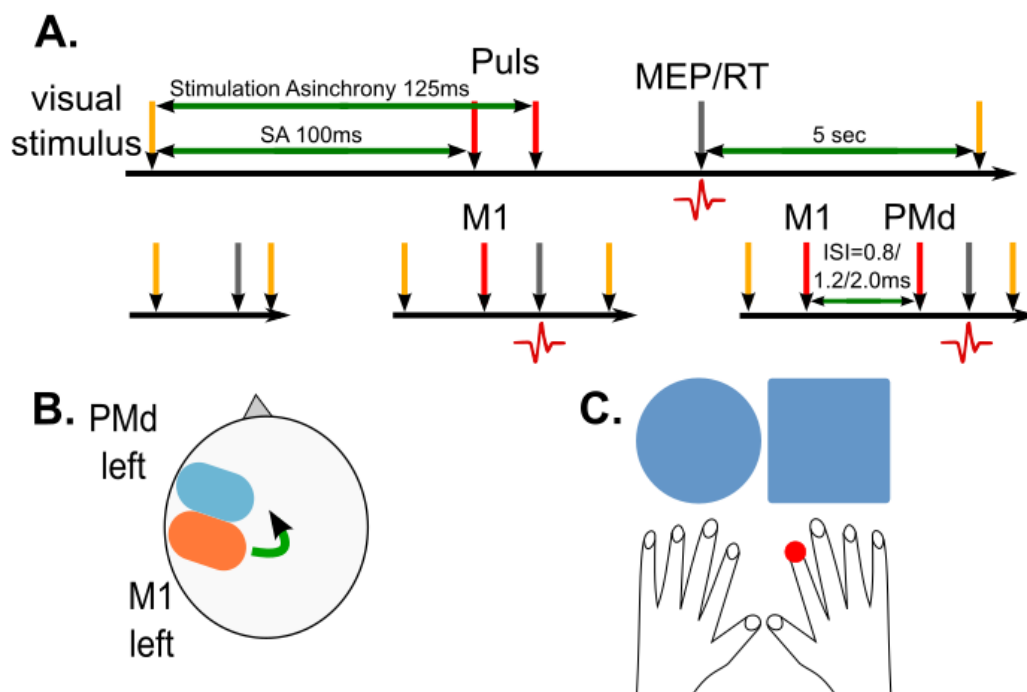


Fig. 3.1. Reaction time research paradigm

3.2.1.3. Description of the choice reaction time task

We used a choice reaction time task (CRTT) paradigm – a selection task, because in elderly people CRTT impairment is greater than simple RT (Simon, 1967). During the task, on a screen placed in front of subject's central visual field, at a distance of 30 cm, two shapes were presented – a circle and a square, and they remained on the screen until the subject initiated an answer by pressing a tab on the keyboard (using the CEDRUS type keyboard, RB series, Cedrus Corporation, San Pedro, USA) with the indicator finger of the right hand. The stimuli were modelled and presented using the E-PRIME software on a personal computer

(Psychology Software Tools, Pittsburgh, USA), and initiated by CED 1401. After applying a stimulation asynchrony (SA) of 100 ms or 125 ms after presenting the image, a sequence of TMS pulses was applied in the form of a singular TP over M1 on the left side or a double pulse over M1-PMd on the left side at ISI of 0.8 ms, 1.2 ms and 2.0 ms. For each ISI, 10 MEPs were registered. Additionally 20 unconditional TPs were applied. Until the appearance of the next image, an interval of 5 seconds was maintained. The sequence of SA trials was in a different order for each subject.

3.2.1.4. Statistical analysis

For statistically analysing the results we used SPSS 17.0 software (SPSS, Chicago, IL, USA). Differences were considered significant if $p \leq 0.05$. The analysis of ANOVA variates was performed based on the factors included in the study: *Group* (on 2 levels: Parkinson group and HC group), *Hand* (on 2 levels: right, left), *SA* (on 2 levels: 100, 125 ms) and *Pulse* (on 5 levels: without pulse, single pulse, double pulse and at ISI 0.8, 1.2, 2.0 ms). Additionally for the significant values, we performed a paired post-hoc comparison after Fisher ($p \leq 0.05$; without adjustment for multiple comparisons) and Scheffé ($p \leq 0.05$; with adjustment for multiple comparisons).

3.2.2 Changes of cortical thickness, cortical area and correlation with reaction time

3.2.2.1. Group collective description

To study the changes of cortical thickness and cortical area, we analysed the MRI-T1 images of 84 patients with Parkinson's disease (56 men, mean age \pm s.d.: 59.3 ± 9.9 years) and 43 HC (mean age \pm s.d.: 59.35 ± 9.91). Further, to perform the correlation between cortical thickness and RT, we included only the patients that participated in the first TMS study, i.e.: 13 HC (nine men, mean age \pm s.d.: 54.4 ± 7.4 years) and 14 patients with PD (five men, mean age \pm s.d.: 66.5 ± 7.6 years). All subjects were right-handed, according to Edinburgh Handedness Inventory, and all presented writing consent for the study (Oldfield, 1971). The procedures for experiment were approved by the Ethics Committee of Christian-Albrechts University in Kiel, and were processed according to Helsinki Declaration (Annas, 1998).

3.2.2.2. Description of MRI analysis

Acquisition of MRI images was performed using Achieva 3-Tesla scanner (Philips Medical System, Best, the Netherlands), using an 8 channel head coil. Structural data were acquired using an echo-planar imagery sequence T1-weighted (slice thickness of 1 mm, matrix 208 x 208, TE = 3,6 ms, TR = 7,8 ms, rotation angle = 8 degrees). For each image automated correction was applied for intensity non-uniformity and standardization (Sled et al., 1998).

The construction of cortical surface was based on 3D MPRAGE images using Freesurfer version 5.0 (Massachusetts General Hospital, Harvard Medical School; <http://surfer.nmr.mgh.harvard.edu>), an integrated software package for the surface-based cortical thickness analysis. The detailed procedure for the surface construction with Freesurfer has been described and validated in previous papers (Dale et al., 1999; Fischl et al., 1999; Fischl et al., 2000). In brief, each resampled T1-weighted MR image underwent a correction for intensity inhomogeneity and intensity standardization (Sled et al., 1998). MRI images were linearly registered afterwards in a stereotactic standardized space on the bases of Talairach atlas (Collins et al., 1994; Talairach et al., 1988). Then the skull strip and the tessellation of the grey/white matter junction with intensity gradient and connectivity among voxels was performed. Misclassification of tissue types was corrected by minimal manual adjustment. After that, images underwent inflation of the folded surface tessellation patterns and automatic correction of topological defects in the resulting manifold. This surface was then used as the starting point for a deformable surface algorithm designed to find the grey/white and pial (*Note: refers to pia mater*) surfaces with submillimetre precision. This method uses both intensity and continuity information from the surfaces in the deformation procedure in order to interpolate surface locations for regions in which the MRI image is ambiguous. For each subject, the thickness of the cortical ribbon was computed on a uniform grid with 1mm spacing across both cortical hemispheres, with the cortical thickness being defined as the shortest distance between the grey/white matter border and pial surface border, providing in essence the estimates of submillimetre differences (Fischl et al., 2000). Thickness measures were mapped to the inflated surface of each subject's brain reconstruction, allowing visualization of data across the entire cortical surface. All images were aligned to a common surface template using a high-resolution surface-based averaging technique that aligned cortical folding patterns. By inflating the cortical sulci, the inflated white matter surface model was created and used for statistical analysis.

Using a general linear model in the QDEC module (integrated in Freesurfer), we investigated the regional difference pattern of cortical thickness between subjects with Parkinson's disease and age-matched HC. Cortical thickness was smoothed with a 10-mm full width at half height Gaussian kernel to reduce local variations in the measurements for further analysis. Significance was set to a p -value of 0,001 without correction for logically accepted group errors. For each cluster significant at $p=0.001$ value we registered a region of interest (ROI), and the thickness value of each ROI was computed.

For analysing the changes of the cortical area, we excluded 4 patients who revealed extensive errors in the subcortical segmentations. This was done in order to have the same group as in the third study (Chapter 3.2.1). The procedure in the FreeSurfer underwent the same steps as described previously, but in the QDEC module we analysed the cortical area.

For analysing the correlation between RT and cortical thickness, the MRI images of the groups from the first study were chosen and the RT data was introduced in the QDEC module in order to perform the correlation with the cortical thickness. The analysis was performed for HC alone, for PD patients alone, and for PD group compared with HC.

3.2.3 Correlation between regional cortical area and the volumes of subcortical structures in PD

3.2.3.1. Group collective description

This study included initially the same group as for the second study, yet 4 PD patients revealed extensive subcortical grey matter errors and were excluded from the study. As a result, we included 80 patients with Parkinson's disease (mean age \pm s.d.: 63.86 \pm 9.08) and 43 HC (mean age \pm s.d.: 59.35 \pm 9.91).

3.2.3.2.Measurement of cortical area and volumes of subcortical structures

In order to analyse the cortical area, we registered the regions of interest for each expounded cluster of cortical thickness from the second study, at $p=0.001$ threshold, and computed the parameter of cortical area for each region of interest.

In order to determine the volumes of subcortical grey matter structures, we used the fully automated segmentation software FSL/FIRST (<http://www.fmrib.ox.ac.uk/fsl/first/index.html>) to measure the volume of four structures: caudate, putamen, pallidum and thalamus (Morey et al., 2009; Patenaude, 2007). The data from all subjects were nonlinearly aligned into a standard MNI 152 space at 1-mm resolution, by means of affine transformations based on 12 degrees of freedom (i.e. three translations, three rotations, three

scalings and three skews). After this, subcortical maps were applied to locate the different subcortical structures, the maps being generated from the probabilistic atlas without previous threshold, followed by segmentation based on shape models and voxel intensities (Mazziotta et al., 1995). After that all segmented subcortical regions were visually checked for errors in registration and segmentation. None were found. Finally a boundary correction is used to determine which boundary voxels belong to the structure or not. We used a Z-value of 3, corresponding to a 99.998% certainty that the voxel belonged to a specific subcortical structure. Brain tissue volume was estimated with SIENAX, part of FSL (Smith et al., 2002; Smith et al., 2004). After extracting brain and skull images from the single whole-head input data, the tissue-type segmentation with partial volume estimation is carried out in order to calculate total volume of brain tissue (including separate estimates of volumes of grey matter, white matter) (Smith et al., 2002; Zhang et al., 2001). For this study we used the absolute volumes generated by the algorithm. Next, automated segmentation proceeded via a Bayesian probabilistic approach using shape and appearance models. These models were constructed from a library of manually segmented images, parameterized as surface meshes and then modelled as point distributions. Using the learned models, FIRST searched through linear combinations of shape modes of variation (principal components) to find the most probable shape instance given the observed intensities from the input image. FIRST uses an empirically determined fixed number of modes (iterations) for each structure. Finally, the vertex information or models were transformed to the native space where the boundaries were corrected and the volumes (labels) were generated.

3.2.3.3. Statistical analysis

SPSS 17.0 software (SPSS, Chicago, IL, USA) was used to perform the correlations between volumes of subcortical grey matter structures and the cortical area of the ROIs for both PD patients and HC. The spreadsheet shows all correlation coefficients that were significant at $p < 0.05$ (two-tailed). The first result displayed the correlation coefficients, the p -value and the pairwise N.

Chapter 4 RESULTS

4.1 Reaction time in patients with Parkinson's disease

The procedures were well tolerated by all participants. Mean rest motor threshold (RMT) for the left M1 was $58.8 \pm 10.9\%$ (for HC) and $68.6 \pm 17.3\%$ (for patients with PD) of maximal stimulation output. Test pulses (TP) over M1 constituted $66.3 \pm 11.4\%$ (HC) and $74.5 \pm 17.4\%$ (PD), whereas conditioning pulses over PMd were $52.9 \pm 9.7\%$ (HC) and $61.7 \pm 15.6\%$ (PD).

The calculated ANOVA was significant for the interaction (*Group x Hand x SA x Pulse*) ($F(4,40) = 3.1623, p=0.023$) (Figure 4.1). The main factor *Pulse* was significant ($F(4, 40)=11.43; p\leq 0.0001$). The further main factors and interactions did not present any significant results or trends (Figure 4.2).

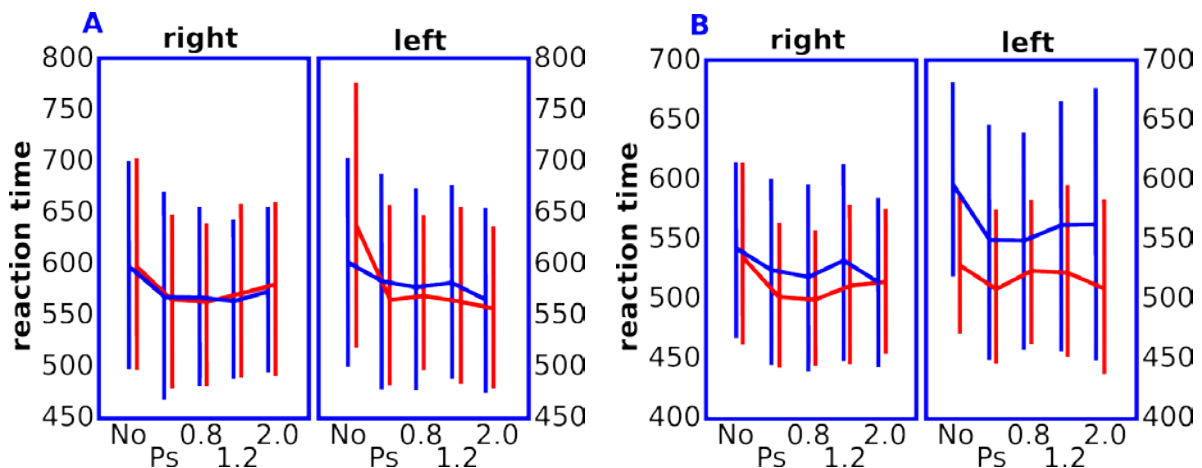


Fig. 4.1. ANOVA between factors *Group x Hand x SA x Pulse* ($F(4, 40)=3.1623; p=0.023$). A= patients with Parkinson's disease; B= healthy controls; right= right hand; left= left hand; red line = SA 125 ms; blue line = SA 100 ms; No= no TMS pulse was applied; Ps= one M1 pulse was applied; 0.8/ 1.2/ 2.0 = two pulses were applied at an interstimulus interval of 0.8/ 1.2/ 2.0 ms.

A Fisher post-hoc test revealed that RT in the absence of TMS was statistically significantly slower in patients with PD when compared to HC, and this significance was bilateral at SA 125 ms (right hand, RT (PD/HC)= 592.9/ 551.5, $p=0.00002$; left hand, RT= 639.7/ 548, $p<0.0001$) and in the right dominant hand at SA 100 ms (right hand, RT (PD/HC)= 602/ 542.2, $p=0.00006$; left hand, RT= 618.2/ 612.1, $p=0.9$). Additionally, in the absence of TMS, the left hand was statistically significantly slower than the right hand in the PD group at SA 125 ms (RT (right/left)= 592.9/ 639.7, $p=0.0009$) but not at SA 100 ms, while

in HC this difference was present at SA 100ms (RT (right/left)= 542.2/ 612.1, $p=0.00006$) but not at SA 125 ms. A further analysis showed that applying a single pulse over M1 facilitated the neuronal transmission and determined a significantly quicker RT in the PD group in both hands at SA 125 ms in comparison to the *No pulse* condition (right hand, RT [pulse/No pulse]= 562.6/ 592.9, $p=0.007$; left hand, RT= 574.4/ 639.7, $p<0.00001$) and in the right hand at SA 100 ms (RT= 574.2/ 602, $p=0.022$). In the HC group, this facilitation was also present in the right dominant hand at SA 125 ms (RT (1 pulse/No pulse)= 513.2/ 551.5, $p=0.009$) and in the left hand at SA 100 ms (RT= 556.1/ 612.1, $p=0.0002$).

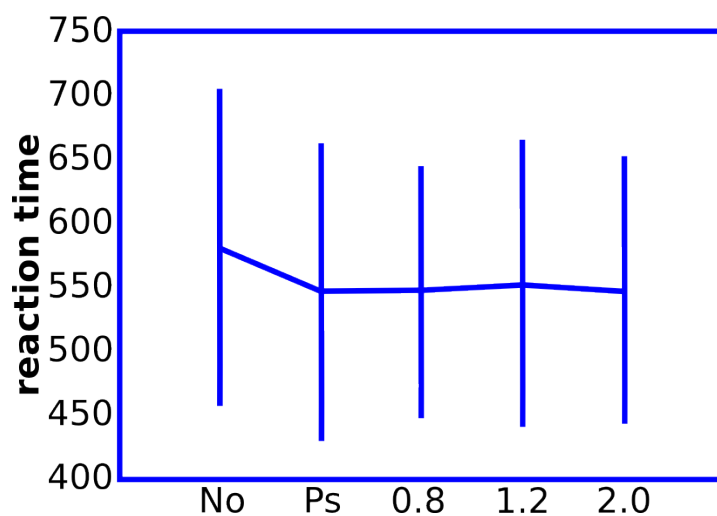


Fig. 4.2. ANOVA for the factor *Pulse* ($F(4, 40)=11.43$; $p\leq 0.0001$). No= no TMS pulse was applied; Ps= one M1 pulse was applied; 0.8/ 1.2/ 2.0 = two pulses were applied at an interstimulus interval of 0.8/ 1.2/ 2.0 ms.

When the double stimulation over M1 and PMd was applied, both groups preserved the same pattern of facilitating effect. The PD group had a significantly quicker RT at ISI 0.8 ms compared to the *No pulse* condition, at SA 125 ms in both hands (right hand, RT(ISI 0.8 ms/No pulse)= 567.9/ 592.2, $p=0.003$; left hand, RT= 516.3/ 551.5, $p<0.001$) and in the right hand at SA 100 ms (RT= 566.7/ 602, $p=0.01$) and the HC group had a quicker RT in the right hand at SA 125 ms (RT= 516.3/ 551.5, $p=0.007$), and in the left hand at SA 100 ms (RT= 553.8/ 612.1, $p=0.0003$). An opposite answer has been depicted during the double pulse stimulation at ISI 1.2 ms when compared to the No Pulse variable. The HC group showed an inhibition effect from PMd over M1 by blocking the facilitating pulse applied over M1 and presented an absence of significant differences between the two variables in both hands at SA 125 ms (right hand, RT(ISI 1.2 ms/ No pulse)= 527/551.5, $p=0.06$; left hand, RT= 534.6/548,

$p=0.7$) and in the right hand at SA 100 ms (RT= 534.4/542.2, $p=0.42$);), while in the PD group this effect was weaker and the significant differences between the two variables were preserved in the left hand at SA 125 ms (RT= 573.1/639.7, $p<0.001$ and) and in the right hand at SA 100 ms (RT= 564.3/602, $p=0.01$). A distinction between SA has also been determined between the two groups in the left hand. In the absence of any TMS pulses there was a statistically significant difference in RT between the two SA variables in both groups in the left hand (PD, RT(SA 100ms/ SA 125ms)= 618.2/639.7, $p=0.001$; HC, RT= 612.1/548, $p<0.001$), but after applying the TMS stimulation the HC group preserved the significant difference with respect to SA (1 Pulse, RT= 556.1/512.3, $p=0.006$; ISI 1.2ms, RT= 566.1/534.6, $p=0.006$; ISI 2.0ms, RT= 569.1/522.9, $p=0.002$), while in the PD group these differences were wiped out (1 Pulse, RT= 590.8/574.4, $p=0.32$, ISI 1,2ms, RT= 586.3/573.1, $p=0.3$, ISI 2.0ms, RT= 567.9/570.7, $p=0.5$).

4.2 Correlation between reaction time and cortical thickness

The analysis for HC (Figure 4.3) revealed a positive correlation bilaterally in the insula, the right superior and inferior temporal regions, right posterior cingulate, right lingual region and left orbito-frontal area.

Correlation of RT with cortical thickness in the PD group (Figure 4.4), showed mainly a negative correlation in the bilateral middle temporal, right inferior parietal, right lingual and left inferior temporal regions. Additionally, a positive correlation has been revealed in the right anterior rostral cingulate and the left insula.

The direct comparison between the PD and HC groups (Figure 4.5), presented only negative correlation bilateral in the temporal pole and insula, in the right middle temporal, right lingual and left orbito-frontal regions. It is interesting to note that several clusters - bilateral insula, right middle temporal, left medial orbitofrontal – which showed positive correlation in the analysis of HC alone (Figure 4.3) were also depicted in the analysis of the PD group and the between groups analysis (Figure 4.5), yet in the later cases these regions revealed a strong negative correlation, suggesting that the between groups results have been driven by the PD patients.

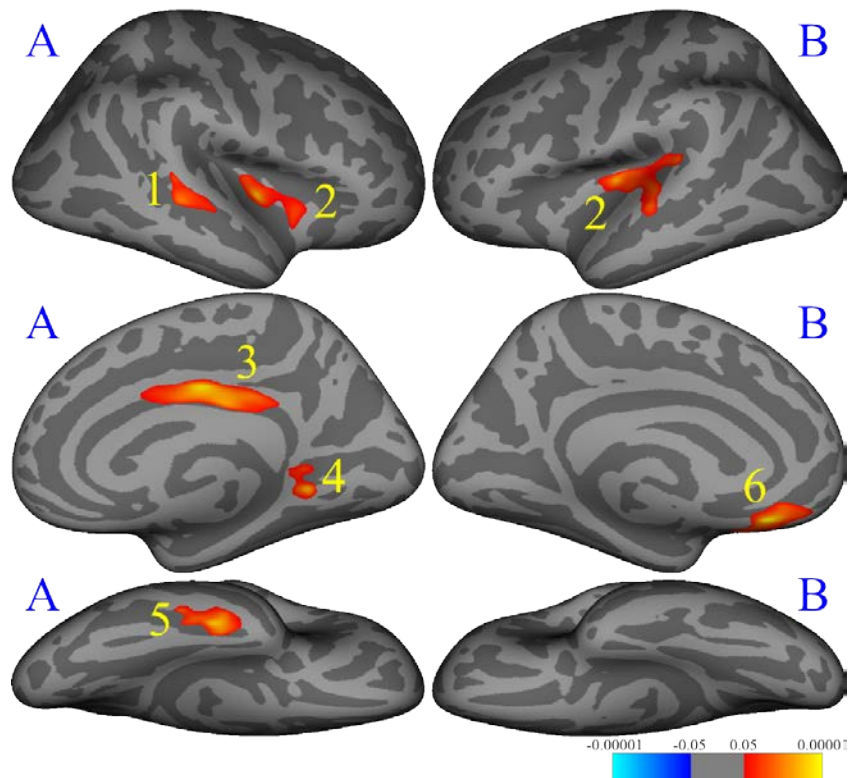


Fig. 4.3. Correlation between reaction time and cortical thickness in healthy controls. (significant regions at $p < 0.001$ uncorrected). A=right hemisphere, B=left hemisphere. 1=temporal superior, 2=insula, 3=cingulate posterior, 4=lingual, 5=temporal inferior, 6=medialorbitofrontal (results in figure are shown at $p = 0.05$).

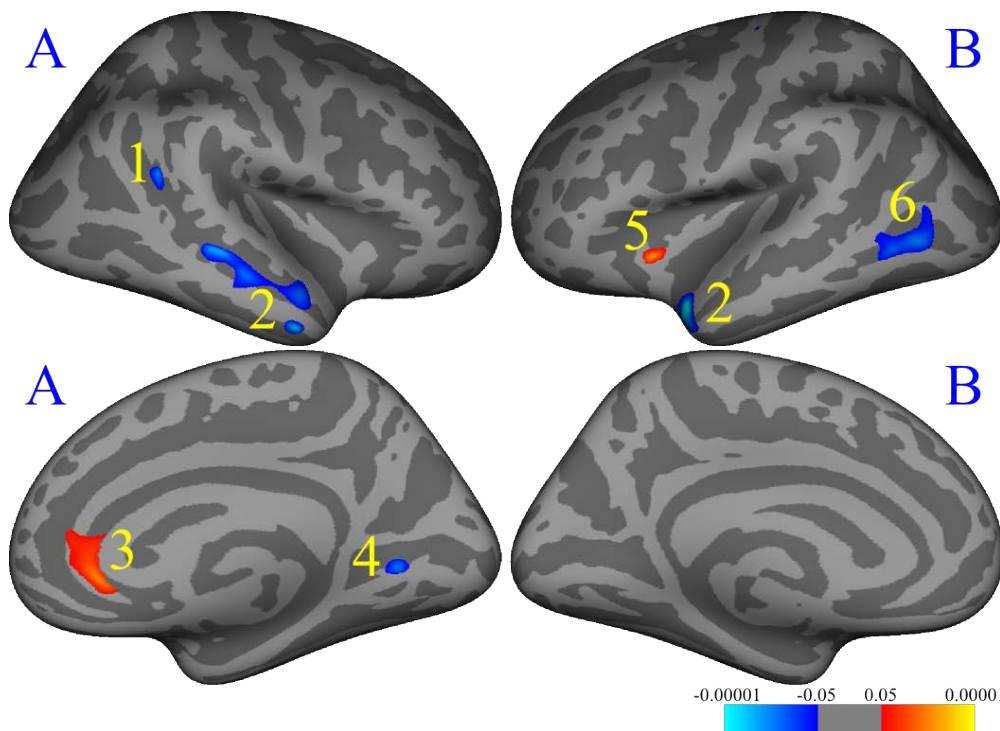


Fig. 4.4. Correlation of reaction time with cortical thickness in patients with Parkinson's disease (significant regions at $p < 0.001$ uncorrected). A=right hemisphere, B=left hemisphere. 1=parietal inferior, 2=middle temporal, 3=cingulate rostral anterior, 4=lingual, 5=insula, 6=temporal inferior (results in figure are shown at $p = 0.05$).

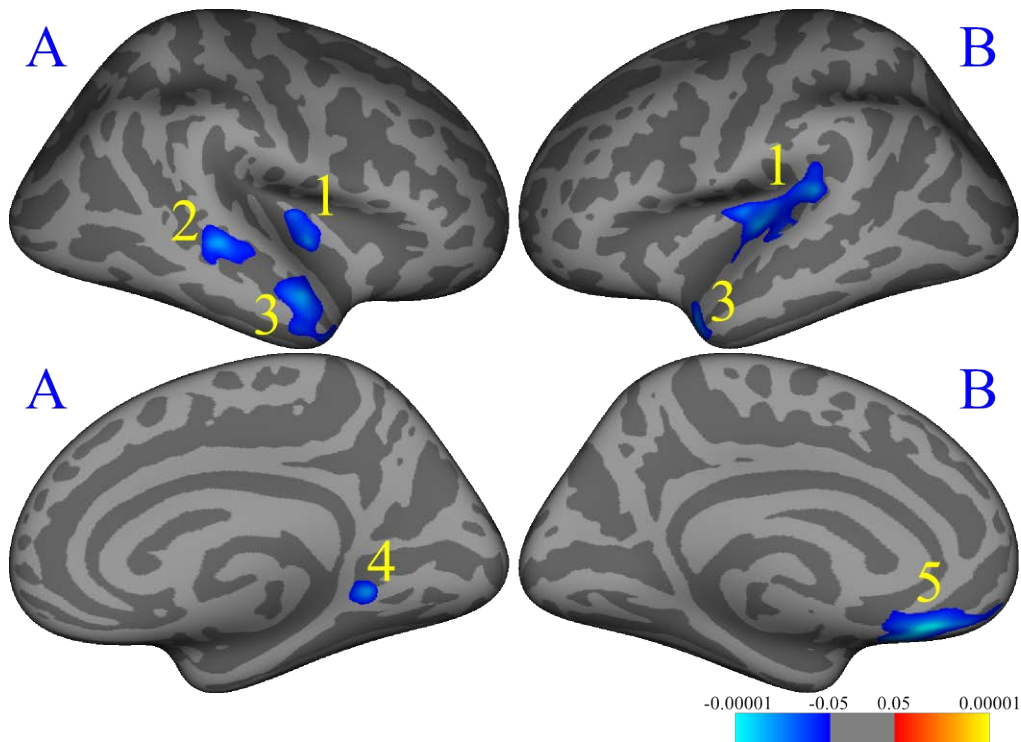


Fig. 4.5. Correlation of reaction time with cortical thickness in patients with Parkinson's disease compared to healthy controls (significant regions at $p < 0.001$ uncorrected). A=right hemisphere, B=left hemisphere. 1=insula, 2=middle temporal, 3=temporal pole, 4=lingual, 5=medial orbito-frontal (*results in figure are shown at $p = 0.05$*).

4.3 Changes of cortical thickness and cortical area in patients with Parkinson's disease

Direct comparison of the results between the PD and the healthy control groups presented regions with severe atrophy in patients (Figure 4.5), localised both bilaterally (superior frontal and inferior parietal regions) as well as unilaterally in the right superior temporal, fusiform, cingulate isthmus and right precuneus, as well as left superior parietal and pars orbitalis cortices. The correction using false discovery rate revealed no significant effects (Benjamini et al., 2001). Only the clusters at $p \leq 0.001$ are presented, yet the diminishment of this threshold revealed a tendency of bilateralization for the majority of regions (right hemisphere: superior parietal region $p = 0.012$; pars orbitalis $p = 0.0035$; left hemisphere: superior temporal $p = 0.0013$; fusiform $p = 0.0045$; cingulate isthmus $p = 0.0066$; precuneus $p = 0.012$).

The analysis of cortical area (Figure 4.6), depicted similar clusters as in the corresponding cortical thickness study. PD patients showed lower cortical area in the bilateral frontal superior areas (SMA/ pre-SMA), bilateral precentral gyrus, right temporal lobe (specifically the temporal pole bilaterally, right middle temporal, superior temporal and

parahippocampal regions), right isthmus cingulate and precuneus, left postcentral gyrus and left supramarginal area. Only regions significant at $p \leq 0.001$ were considered for this study.

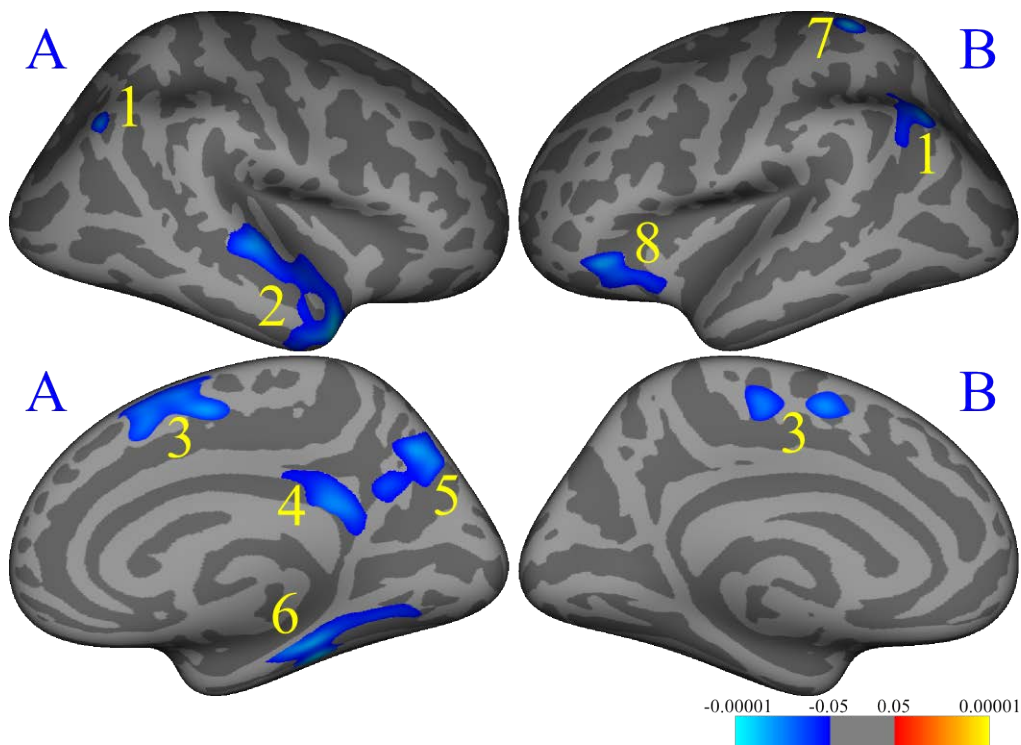


Fig. 4.6. Regions with changed cortical thickness in patients with Parkinson's disease, compared to healthy controls (significant regions at $p < 0.001$ uncorrected). A=right hemisphere, B=left hemisphere. 1=parietal inferior (right: $p=0.0008$; left: $p=0.0004$) 2=temporal superior ($p=0.00009$), 3=frontal superior (right: $p=0.0005$; left: $p=0.0004$), 4=isthmus cingulate ($p=0.0008$), 5=precuneus ($p=0.0003$), 6=fusiform ($p=0.0002$), 7=parietal superior ($p=0.00006$), 8=orbito-frontal ($p=0.0002$) (results in figure are shown at $p=0.05$).

Table 3.1. Changes of cortical thickness in patients with Parkinson's disease compared to healthy controls

	Talairach coordinates			PD patients (mm)		Healthy controls (mm)		Difference (%)
	x	y	Z	Media	SD	Media	SD	
R parietal inferior	39.77	-65.05	39.91	2.58	0.39	2.82	0.31	- 8.63
R temporal superior	41.63	11.24	-27.86	3.36	0.44	3.65	0.26	- 8.02
R frontal superior	10.28	-0.52	29.78	2.55	0.35	2.76	0.26	- 7.73
R isthmus cingulate	8.52	-41.19	25.25	2.17	0.42	2.43	0.34	- 10.6
R precuneus	7.57	-65.30	38.67	2.16	0.31	2.35	0.19	- 8.00
R fusiform	34.37	-34.71	-15.66	2.48	0.33	2.70	0.27	- 8.17
L parietal inferior	-38.47	-64.51	43.90	2.61	0.33	2.82	0.25	- 7.28
L frontal superior	-7.35	-0.24	50.11	2.72	0.38	2.95	0.25	- 7.88
L parietal superior	-20.50	-36.79	55.49	1.68	0.21	1.86	0.26	- 9.66
L orbito-frontal	-43.76	29.21	-11.63	2.69	0.36	2.93	0.24	- 7.95

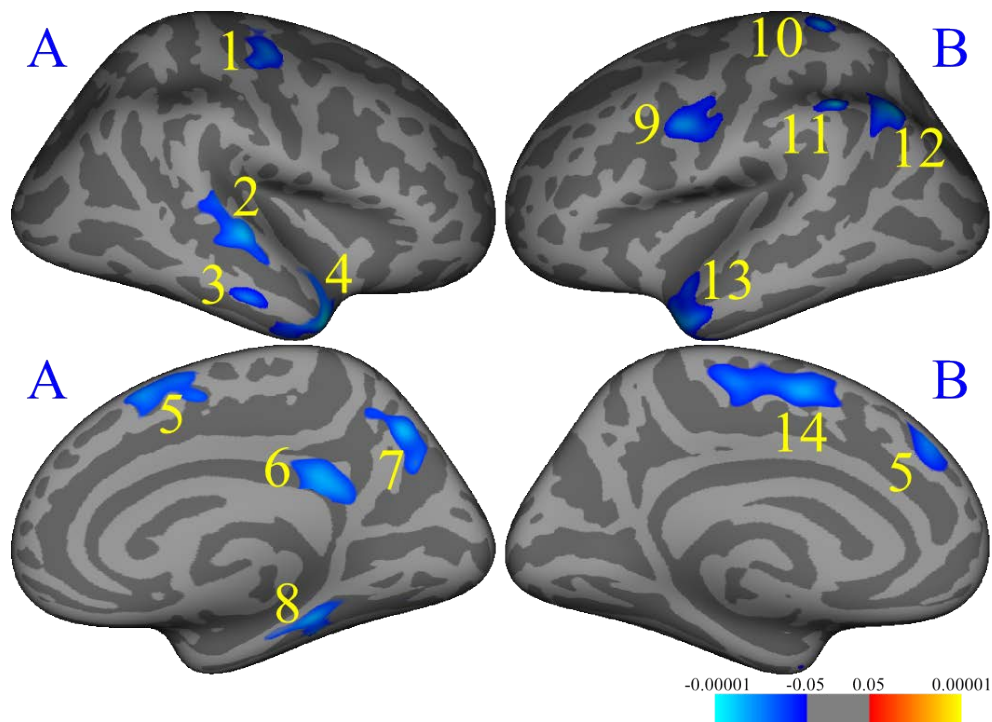


Fig. 4.7. Regions with changed cortical area in patients with Parkinson's disease compared to healthy controls. (significant regions at $p < 0.001$ uncorrected). A=right hemisphere, B=left hemisphere. 1=precentral, 2=temporal superior, 3=middle temporal, 4=temporal pole, 5=frontal superior, 6=isthmus cingulate, 7=precuneus, 8=parahippocampal, 9=precentral, 10=postcentral, 11=parietal inferior, 12=supramarginal, 13=temporal pole, 14=frontal superior, (*results in figure are shown at $p = 0.05$*).

4.4 Correlation between regional cortical area and the volumes of subcortical structures in patients with Parkinson's disease

The analysis displayed positive correlations between the segmented cortical areas and the subcortical grey matter structures and no negative correlations were revealed. Left M1 (precentral cluster) showed a positive correlation with bilateral caudate nucleus and the left pallidum. Left SMA/pre-SMA area (frontal superior clusters) showed positive correlation with the bilateral putamen, the left caudate nucleus and the left pallidum. The right cortical areas did not reveal any significant correlations with the volumes of the analysed subcortical structures.

Table 3.2. Correlation matrix between volumes of subcortical segmentations and regional cortical area.

Area Volume		Right (area)				Left (area)			
		Precentral	Postcentral	Frontal superior	Precuneus	Precentral	Postcentral	Frontal superior	Precuneus
Right (volume)	Thalamus	-.0712	.0172	-.0411	.0860	-.0223	.0527	.0322	-.0378
		<i>p</i> =.434	<i>p</i> =.850	<i>p</i> =.651	<i>p</i> =.344	<i>p</i> =.807	<i>p</i> =.562	<i>p</i> =.723	<i>p</i> =.678
	Caudate	.1446	.1161	.0413	.1353	.2222	.0836	.0847	.1044
		<i>p</i> =.110	<i>p</i> =.201	<i>p</i> =.650	<i>p</i> =.136	<i>p</i>=.014	<i>p</i> =.358	<i>p</i> =.352	<i>p</i> =.251
	Putamen	.0389	.1675	.0087	.1030	.0613	.0631	.2351	-.0400
		<i>p</i> =.670	<i>p</i> =.064	<i>p</i> =.924	<i>p</i> =.257	<i>p</i> =.501	<i>p</i> =.488	<i>p</i>=.009	<i>p</i> =.661
	Pallidum	-.0209	.0748	.0560	.0571	.0975	.0978	.1190	.1127
		<i>p</i> =.818	<i>p</i> =.411	<i>p</i> =.539	<i>p</i> =.530	<i>p</i> =.283	<i>p</i> =.282	<i>p</i> =.190	<i>p</i> =.214
Left (volume)	Thalamus	-.0801	.0429	-.0023	.0661	-.0065	.0354	.1156	.0021
		<i>p</i> =.378	<i>p</i> =.637	<i>p</i> =.980	<i>p</i> =.468	<i>p</i> =.943	<i>p</i> =.698	<i>p</i> =.203	<i>p</i> =.981
	Caudate	.1345	.1528	.0966	.1742	.2771	.0552	.2400	.1020
		<i>p</i> =.138	<i>p</i> =.092	<i>p</i> =.288	<i>p</i> =.054	<i>p</i>=.002	<i>p</i> =.544	<i>p</i>=.007	<i>p</i> =.262
	Putamen	.0201	.1683	-.0135	.0888	.0989	.0185	.2275	.0247
		<i>p</i> =.825	<i>p</i> =.063	<i>p</i> =.883	<i>p</i> =.329	<i>p</i> =.277	<i>p</i> =.839	<i>p</i>=.011	<i>p</i> =.786
	Pallidum	.0729	.1595	.1255	.1501	.2299	.1681	.2427	.1196
		<i>p</i> =.423	<i>p</i> =.078	<i>p</i> =.167	<i>p</i> =.098	<i>p</i>=.011	<i>p</i> =.063	<i>p</i>=.007	<i>p</i> =.188

The results display the correlation coefficients, the pairwise N and the *p*-values.

Chapter 5 DISCUSSION

5.1 General considerations

The main findings of our study are: (1) patients with PD have a slower RT than HC; (2) the functional connectivity in PD has a changed pattern with respect to the cortical motor regions, when compared to HC; (3) cortical motor regions in PD have decreased cortical thickness and decreased cortical area, when compared to HC; (4) cortical changes in the motor regions in patients with PD correlate with the volumes of the caudate, putamen and the pallidum.

During the first two stages of PD morphological development, the pathology is confined only to the olfactory sites, medulla oblongata and the pontine tegmentum and does not present the full clinical picture (Braak et al., 2004). Nevertheless, it is already a fact that PD is much more than just the loss of nigro-striatal neurons, this morphological feature being only one aspect in the whole picture of the disease (Tolosa et al., 2009). In future it will be important to diagnose PD in presymptomatic stages to initiate a causal or progression modifying therapy and the subsequent loss in the substantia nigra could be entirely prevented (Cronin-Golomb, 2013).

New clinical approaches for diagnosing the PD have developed and the features of “premotor phase” in PD became better defined, allowing to consider the disease by years and perhaps even decades before the development of the classical motor features of PD (Tolosa et al., 2009). Apart from the clinical assessment, the consideration of imaging and neuropsychological data, by analysing the structural and functional brain changes, can also be used to characterise the PD evolution and maybe control the long term trajectory of treatment interventions. The results of this work could bring further insights into this possibility.

5.2 Reaction time. Correlation between reaction time and cortical thickness.

Functional connectivity

Our results showed that PD patients had a slower RT compared with HC in both hands in the absence of TMS stimulation. These results are in good agreement with previous data, which revealed that PD patients show impairments of RT (Kojovic et al., 2014; Wilson, 1925). Furthermore, the results of our study showed a difference between the left and the right hands with respect to the SA variable, which is in accordance with another study which showed an independently impaired speed of movement and speed of response initiation in PD patients and this impairment was even in the same patient between the two limbs (Evarts et

al., 1979). In our study, the HC group showed a significant difference between the two SA variables in the left hand during the TMS stimulation while the PD group did not reveal this change of perception dependant connectivity for the visual stimuli. Thus, the normal distinction between the hands, which is present in age-matched HC, was wiped out in patients with PD. These divergences confirm both the change of functional connectivity in PD with respect to motric responses (a slower RT), as well as changes with respect to visual perception. By reports, there are no direct connections between visual areas and the primary motor cortex, yet the animal studies showed that visual pathways, have their main stations in the posterior parietal cortex and subsequently secondary motor areas (Merchant et al., 2001; Mushiaké et al., 1991; Schwartz, 1994). Another pathway is through the thalamus, which links the visual and somatosensory perception to the motor output (Guillery et al., 2002; Guillery, 2003). The data of our study might imply the loss of functional connectivity in PD patients in the motor and visual cortical areas or in the described visual-motor pathways. Considering the studies of functional connectivity remodelling in PD patients, our data might reveal that some of the cortico-cortical connections in PD patients are less efficient (Palmer et al., 2010).

The correlation between RT and cortical thickness in the PD group, presented a distinct pattern in comparison to HC. Temporal areas, bilateral insula, left orbitofrontal area and the right lingual region presented a positive correlation in HC (Figure 4.3), while in PD patients these regions had a negative correlation, meaning that the higher are the RT values in patients with PD (respectively the slower is the RT response), the lower is the cortical thickness in those specific regions (Figure 4.5). On the other hand, RT correlation for PD alone (Figure 4.4) showed that in the insula region, in the left hemisphere the same positive correlation was attested, but at a lower significance. These results could reveal a progressive loss of functional connectivity in these areas, but could also be in line with the functional connectivity-remodelling pattern in PD.

An important result of our work is the involvement of the orbito-frontal area, which showed a negative correlation with RT in patients with PD. It has been shown that the orbito-frontal region is involved in the coordination of decision-making, being an intermediate connection between the limbic emotional structures and the frontal decision applying structures (Bechara et al., 2000). The orbitofrontal region (part of the ventromedial prefrontal cortex) represents aspects of reinforcing value that govern instrumental choice behaviour (Cardinal et al., 2002). This area is implicated in affective and motivated behaviours and damages to this region causes profound changes in emotional and social behaviours, including

impairments in certain aspects of decision making (Bechara et al., 1997; Drevets et al., 1995). One reinforcement mechanism that may well contribute to these behaviours is conditioned reinforcement, whereby this mechanism is disrupted in primates with lesions of the orbitofrontal but not medial prefrontal cortex (Pears et al., 2003). Similar results with the involvement of the orbitofrontal area were described in other studies. An fMRI study in non-demented PD patients presented an extensive brain network under-recruitment including bilateral orbito-frontal and striatal regions (Ekman et al., 2012). Interestingly, the orbito-frontal region has been revealed to have structural changes in PD, specifically one study showed cortical atrophy and another one revealed increased cortical area (Burton et al., 2004; Lyoo et al., 2010; Nagano-Saito et al., 2005). As such, cortical changes in the orbito-frontal region seem to have specific correlations with the development of PD. The negative correlation revealed in our study in patients with PD, which show that a thinner cortex in the orbito-frontal region correlates with a slower RT, might be considered as a marker that reveals the impairment in decision-making and executive functions in the PD group, and this, might be one of the causes for a slower RT in PD patients.

Our results present a shift of functional connectivity from the posterior cingulate area, present only in HC (Figure 4.3) to the anterior rostral cingulate area that is present in PD patients alone (Figure 4.4). This change is in accordance with a previous study, which reported a connectivity shift in PD patients, with the loss of connections from posterior cingulate to SMA (which was present in HC) and the creation of new connections from anterior cingulate to prefrontal cortex and caudate (which were absent in HC) (Palmer et al., 2010). Our results clearly correspond with the previous study and support the hypothesis of functional connectivity remodelling of the posterior cingulate region and the CMA. These changes can be considered as cerebral plastic adaptation measures due to loss of activity in the posterior cingulate area. Anatomical particularities in the CMA region in PD have been reported by other studies. Anterior cingulate region has been shown to be especially vulnerable for Lewy body inclusions in PD (Hurtig et al., 2000; Rüb et al., 2002), and the structural reducing of the anterior cingulate region in PD patients has been associated with the attention deficits that were previously described in this pathology (Salmon et al., 1996; Summerfield et al., 2005). Of interest is as well why the connections from the posterior cingulate region to SMA could change to CMA and prefrontal cortex (Palmer et al., 2010). It has been shown that in healthy people the cingulate and SMA regions present separate activations, even if they have proximity and have a tendency to be co-activated during manual activities (Kwan et al., 2000; Petit et al., 1998). According to Helmich and colleagues in

patients with PD, changes in CMA are predominantly with respect to functional connectivity, which was revealed in our results by the correlation analysis between RT and cortical thickness (Helmich et al., 2009b). Indeed our results show that the regions specific for the HC group (insula bilaterally, temporal regions, left orbitofrontal and right lingual area) present a strong negative correlation in PD patients, confirming the new functional connectivity pattern.

Our results presented significant changes in the occipital lobe, the left lingual area that showed a positive correlation with RT in HC (Figure 4.3) and a negative correlation in the PD group (Figure 4.4; 4.5). A previous VBM study in PD patients with dementia revealed that the lingual region (BA 19) had bilateral cerebral atrophy (Burton et al., 2004). Other studies outlined the changes in the occipital cortex. In patients with milder PD (Hoehn and Yahr I and II) the greatest hypoperfusion was observed in the occipital cortex (Nagamachi et al., 2008). A PET study showed that the greatest cerebral glucose metabolic rate reduction in PD vs. healthy controls occurred in the occipital lobe and that there was an inverse correlation between this rate and the tapping performance in the contralateral hand in PD patients (Bohnen et al., 1999). Our results are in accordance with the previous study, and showed the same pattern – the higher the RT values in patients with PD (meaning the slower the RT response), the lower was the cortical thickness in the lingual region.

5.3 Cortical thickness and cortical area in PD. Correlation between cortical area and volumes of subcortical structures. Structural connectivity.

The results of cortical thickness and cortical area analysis in our study showed cortical thinning and decreased cortical area in the parietal lobe, temporal lobe, posterior cingulate region and SMA. According to Braak and colleagues cortical changes in PD pathology in the premotor and primary sensory areas appear in the final 6th stage of disease development (Braak et al., 2003). Nevertheless, previous VBM studies reported changes in non-demented PD patients with regional atrophy of grey matter in the frontal, temporal and parietal cortices (Burton et al., 2004; Nagano-Saito et al., 2005; Summerfield et al., 2005). The corticometry data showed areas of surface expansion in the bilateral superior parietal cortex, left cingulate region, left insula and right superior frontal gyrus and a cortical thinning associated with PD in the left medial SMA and the right dorsal pre-SMA (Jubault et al., 2011).

The changes depicted in the somatosensory cortex and the inferior parietal area (corresponding to the supramarginal and angular gyri) are in accordance with previously reported cortical thinning in the inferior parietal region as well as superior parietal cortex (Jubault et al., 2011; Lyoo et al., 2010). Other studies revealed that in non-demented PD

patients the topographic distribution of the hypometabolism and hypoperfusion is more located in the posterior parieto-temporal and occipital regions (Abe et al., 2003; Bohnen et al., 1999; Eberling et al., 1994; Hu et al., 2000). One fMRI study about the involvement of brain areas in speech production and initiation showed that the left primary orofacial sensorimotor cortex was more engaged in PD patients than in HC (Rektorova et al., 2007). A pattern of connectivity remodelling in PD in the somatosensory cortex, has been revealed by another study, which showed that responses to fearful facial expression in patients with PD are generated within the parietal somatosensory cortex, whereas in normal subjects the responses are located in the amygdala and visual temporal cortex (Yoshimura et al., 2005). The cortical thinning distribution pattern in the parietal cortex, overlaps with the area in which cortical Lewy bodies and Lewy neuritis were found in patients with advanced Parkinson's disease, corresponding with Braak stage 4 and stage 5 (Braak et al., 2003). From this point of view, our results of cortical changes in the parietal lobe are in line with previous reports.

An important degree of cortical thinning (about -8%) and bilateral decrease of cortical area has been revealed in PD in the superior frontal region (SMA and pre-SMA areas) when compared to HC. The SMA/ pre-SMA region was shown previously to have structural changes, specifically cortical thinning in PD compared to HC in a study which used the SurfStat toolbox in Matlab and cortical atrophy using VBM (Brück et al., 2004; Jubault et al., 2011). White matter abnormalities with decreased fractional anisotropy have been reported in the SMA, pre-SMA and the cingulate regions (Karagulle Kendi et al., 2008). Pre-SMA region in PD patients was shown to have a significant loss of cortico-cortical projecting pyramidal neurons, but with no loss of other pyramidal neurons or interneurons in this region or in the dorsolateral premotor region, indicating a highly selective loss of pyramidal cells in the SMA (MacDonald et al., 2002). Functional changes in the SMA have also been described. One fMRI study showed a relatively decreased signal in the rostral part of the SMA (Sabatini et al., 2000b). An fMRI investigation of the causal connectivity of basal ganglia networks in PD, from the substantia nigra pars compacta during movement and during resting state, revealed that in healthy people the activity in the substantia nigra predicted increased activity in the SMA while in patients with PD the activity in the substantia nigra predicted decreased activity in the SMA (Wu et al., 2001). Excessive metabolic activity in SMA have been associated with motor deficits while the hypometabolism in pre-SMA has been identified in relation to cognition deficits (Huang et al., 2007). Connectivity studies have revealed important patterns in SMA. One study reported connectivity losses in SMA and M1 in patients with PD, but instead new connections have been described between the motor regions, cerebellum and

subcortical nuclei that were specific only for PD (Palmer et al., 2010). In PD patients substantia nigra pars compacta showed decreased connectivity with cortical regions like SMA, insula, the temporal lobe when compared to controls and the levodopa administration partially normalized the pattern of connectivity (Wu et al., 2001). As such, our results are in accordance with previous studies and present additional changes in SMA/ pre-SMA region with respect to cortical thickness and cortical area parameters.

Two clusters with significantly decreased cortical area have been revealed in the right and left precentral regions, corresponding to M1 on the right side and to PMv and posterior prefrontal cortex to the left side. The PMv/ posterior prefrontal cortex was shown to have lower activation in PD patients compared with HC subjects when matching after both negative and positive feedback (Monchi et al., 2004). This same study presented greater activation in the PD group compared to HC in the right lateral premotor areas and the right motor cortex, corresponding to the M1 cluster in our results. One study revealed that lesions confined to this prefrontal region cause impairment in the selection of alternative responses on the bases of conditional rules and it has been shown that PD patients are impaired at making choices that require learning from trial and error (Cools, 2006; Petrides, 1990; Shohamy et al., 2004). Thus, our results show that M1 and PMv/ posterior prefrontal cortex reveal decreased cortical area in PD patients compared to HC (Figure 4.6, 4.7). This would imply that PD has extensive white matter tract damage (Van Essen, 1997).

The correlations between cortical areas and the volumes of subcortical grey matter structures revealed that cortical changes in the motor regions, M1 and SMA correlated with the volumes of the caudate nucleus and pallidum. Cortical area of SMA correlated with the volume of the putamen. In healthy people M1 both sends projections to the striatum and receives inputs from striatum and pallidum via VA (Jones et al., 1977; Matelli et al., 1989; Strick et al., 1974). SMA also receives inputs from the putamen, pallidum and caudate nucleus (Alexander et al., 1986; Matelli et al., 1996; Rizzolatti et al., 1996). From this point of view, the correlations between cortical morphology and the volumes of these subcortical structures are in line with their connectivity patterns. Thus, we could argue that the cortical changes are in direct relation with the changes in subcortical structures due to PD.

Hypothesis discussion

To evaluate the specific changes of connectivity in the motor regions, we designed a multimodal approach, by directly measuring functional motor responses, correlating these results with cortical thickness and cortical area measurements, and revealing the correlation between cortical area and the volumes of subcortical grey matter structures. As expected our group of PD non-demented patients exhibited significantly lower RT compared with HC subjects, and all PD patients had slower RT results, compared with previous study where some PD patients had normal RT (Evarts et al., 1979; Evarts et al., 1981; Wilson, 1925). In contrast to above mentioned studies we applied a CRTT, and it has been shown previously that CRTT impairments are greater than simple RT in elderly subjects (Simon, 1967). Further, correlation of RT with cortical thickness revealed strong changes of connectivity pattern in PD compared to HC: (1) disappearance of positive correlation in the orbito-frontal region (Figure 4.4), (2) strong diminishment of the positive correlation in the insular region in PD patients alone (Figure 4.4) and appearance of clusters with negative correlation in this region when compared with HC (Figure 4.5) (3) a shift of connectivity in the cingulate region, from posterior to rostral anterior (Figure 4.4), corresponding with previous results on morphological changes and functional connectivity changes in the cingulate area in PD patients (Hurtig et al., 2000; Palmer et al., 2010; Rüb et al., 2002).

We presented evidence that changes in the motor cortex in PD patients show specific patterns both for functional and structural connectivity. We revealed extensive regions of cortical thinning and changes of cortical area in the motor regions (specifically M1, PMv, SMA, CMA). We aimed to see specific changes in the five basal ganglia – thalamo-cortical circuits (motor circuit, two prefrontal circuits, oculomotor circuit, limbic circuit) (Alexander et al., 1986; Alexander et al., 1990; Mehler-Wex et al., 2006). Indeed we revealed correlation between M1 (Figure 4.7, precentral region, nr. 1) and the volumes of the caudate nucleus, and pallidum, between the left PMv area (Figure 4.7, precentral region, nr. 9) and bilateral caudate, between bilateral SMA (Figure 4.7, superior frontal region, nr. 5, 14) and bilateral striatum and left pallidum. These results suggest that the changes in the subcortical grey matter structures correlate with the degenerative changes in the motor regions in PD patients due to the development of the disease.

As hypothesized, we did find significant changes of cortical thickness and cortical area in PD patients, which are in line with previous studies (Palmer et al., 2010). These results of decreasing cortical structural connectivity account from 7% in the SMA area, to up to 10% in the isthmus cingulate. Furthermore we considered that in a post-mortem pathology study on

PD patients with slight or moderate dementia, quantitative neuronal counting did not show any global or regional neocortical neuronal loss and in healthy adults, cortical thinning could appear in cerebral areas where no neuronal loss was determined (Freeman et al., 2008; Pedersen et al., 2005). This way, as suggested by other studies, variations in the cortical thickness could be due to differences in myelination or the underlying white matter, reduction of dendritic arborizations or presynaptic terminals loss, rather than the number of cells within the column (Freeman et al., 2008; Panizzon et al., 2009). Furthermore, given that MRI measures do not have the resolution to examine brain structure at the cellular level, we cannot tell whether lower cortical thickness is due to different numbers of cells (respectively cell degradation) or the size of the cells (i.e., cell atrophy), but our results clearly present the re-distribution pattern of connections in PD patients.

Our results reveal cortical degradation and might further characterise PD before the clinical condition starts to manifest. Tracing the motor and non-motor cortical areas analysed in this study, can help improve and characterise specific rehabilitation treatments. At last, the present results allow to determine the main directions of changes that occur in the brain in the motor regions due to this disease, and to draw brain's tendencies of creating new connections. Future usage of connectivity shifting technics might be applied in order to increase brain's adaptability to such degradation processes, by stimulating the creation of new connections, primarily in the direction in which the brain already has its own natural tendency.

5.4 Summarizing remarks

- 1) PD patients had a significantly slower RT compared with HC, and these results were determined in all our patients. Such decrease of RT was associated with significant changes of functional connectivity in the cortical areas involved in this motor and visual act.
- 2) Single pulse TMS improves the RT both in PD patients and in HC.
- 3) M1 in PD showed decreased cortical area and this parameter revealed a positive correlation with the volumes of the caudate nucleus and pallidum, meaning that the smaller the volumes of the caudate nucleus and the pallidum, the less is the cortical area in M1.
- 4) SMA region seems to have a much more specific involvement in the development of PD motor degradation. It presented bilateral changes with both cortical thinning as well as decreased cortical area and it showed a positive correlation with the volumes of the striatum and pallidum.
- 5) CMA revealed a strong change of functional connectivity in patients with PD, being line with previous studies (Helmich et al., 2009b). CMA showed a diminishment/reprofilation or inactivation of posterior cingulate region and, possibly as a compensatory response – the activation or connectivity amplification of anterior cingulate region.
- 6) Cortical changes in the motor regions correlate with changes in the volumes of subcortical grey matter structures

5.5 Conclusions

This thesis provided evidence that the motor regions in patients with Parkinson's disease are involved structurally and functionally. Primary motor area showed mainly structural changes that correlated with the volume of the caudate nucleus and pallidum. Cingulate motor area showed only functional connectivity changes that correlated positively with the slower reaction time. The ventral premotor area and supplementary motor area presented both structural and functional connectivity changes and correlated with the volumes of subcortical structures. Our study did not reveal any changes in the dorsal premotor area. As such, primary motor cortex and supplementary motor area are the motor regions the most involved in the PD pathology and can be used as markers for identifying the disease in the early stages.

Chapter 6 SUMMARY

Parkinson's disease is the second after Alzheimer's disease, most frequent chronic neurodegenerative disorder affecting up to 2% of individuals aged 65 years and older and nearly 10% of people older than 80 years. The process that ultimately leads to the full clinical picture of PD does not merely involve substantia nigra. The loss of nigro-striatal neurons is only a stage in cortical and subcortical neurodegeneration.

In this thesis we applied transcranial magnetic stimulation and structural MRI imaging (by the aid of FreeSurfer and FSL software) in order to study the reaction time, the morphometric brain parameters of cortical thickness, cortical area, volumes of subcortical grey matter structures and correlated between the reaction time and the cortical thickness in non-demented patients with Parkinson's disease. In the first study, fourteen patients (mean age \pm s.d.: 66.5 \pm 7.6 years) and thirteen healthy controls (mean age \pm s.d.: 54.4 \pm 7.4 years) were included in the choice reaction time task. Each participant performed a choice reaction time task during primary motor cortex and dorsal premotor area transcranial magnetic stimulation. In the second study we analysed the brain morphometric properties of eighty-four patients (mean age \pm s.d.: 59.3 \pm 9.9 years) and forty-three healthy controls (mean age \pm s.d.: 59.35 \pm 9.91). They underwent an MRI investigation and the T1 images were used to measure the cortical thickness, cortical area and the volumes of thalamus, caudate nucleus, putamen and pallidum. Further, we performed correlation analysis between choice reaction time task and cortical thickness on one side. Further, we calculated the correlation of cortical area of the significant regions of interest and the volumes of the above-mentioned subcortical structures.

In the first study we could show that patients with Parkinson's disease had a slower reaction time when compared to healthy controls. During the application of magnetic stimulation pulses in both groups the reaction time decreased. Nevertheless, patients with Parkinson's disease still had a slower reaction time when compared to healthy controls. The slower reaction time correlated with a higher cortical thickness in the cingulate motor region and with a lower cortical thickness in the temporal and parietal regions. The second study revealed that Parkinson's disease is associated with a decreased cortical thickness and area in the motor regions, especially in the primary motor area, the ventral premotor area and the supplementary motor cortex. The decreased cortical area in the motor regions positively correlated with the volumes of the caudate nucleus, putamen and pallidum.

The present study showed that patients with Parkinson's disease presented a different pattern of functional and structural interactions in the motor regions when compared to

healthy controls. Structural parameters' changes were revealed in the motor cortex and these are mirrored in the subcortical volumes of the caudate nucleus and pallidum. The cingulate motor area revealed only functional changes, which showed a positive correlation with the slower reaction times in patients with Parkinson's disease. The ventral premotor and the supplementary motor area underwent both functional as well as structural remodelling due to PD and these changes correlated with the volumes of the caudate nucleus, putamen and pallidum.

The present study showed that PD is associated with distinct connectivity patterns in motor regions. Both degeneration processes as well as compensatory mechanisms of the brain can explain these changes. These parameters might develop to primary or additional biomarkers for identifying the pathology in the early stages of the disease or track its progression.

Chapter 7 ANNEX

7.1 Bibliography

- Aarsland, D., Brønneck, K., Fladby, T. (2011). Mild Cognitive Impairment in Parkinson's Disease. *Curr Neurol Neurosci Rep* 4, 371-378.
- Abdeen, M.A., Stuchly, M.A. (2002). Modeling of magnetic field stimulation of bent neurons. *IEEE Trans Biomed Eng* 11, 1092-1095.
- Abe, Y., Kachi, T., Kato, T., Arahata, Y., Yamada, T., Washimi, Y., Iwai, K., Ito, K., Yanagisawa, N., Sobue, G. (2003). Occipital hypoperfusion in Parkinson's disease without dementia: correlation to impaired cortical visual processing. *J Neurol Neurosurg Psychiatry* 4, 419-22.
- Alexander, G.E., DeLong, M.R., Strick, P.L. (1986). Parallel organization of functionally segregated circuits linking basal ganglia and cortex. *Annu Rev Neurosci* 1, 357-81.
- Alexander, G.E., Crutcher, M.D. (1990). Functional architecture of basal ganglia circuits: neural substrates of parallel processing. *Trends Neurosci* 7, 266-71.
- Annas, G.J. (1998). Human rights and health - the universal declaration of human rights. *N Engl J Med* 24, 1778-81.
- Barbas, H., Pandya, D.N. (1987). Architecture and frontal cortical connections of the premotor cortex (area 6) in the rhesus monkey. *J Comp Neurol* 2, 211-228.
- Barker, A., Jalinos, J., Freeston, I. (1985). Non-invasive magnetic stimulation of human motor cortex. *Lancet* 11, 1106-7.
- Barker, A.T. (2002). The history and basic principle of magnetic nerve stimulation. In: Pascual-Leone, A., Davey, N., Wassermann, E.M., Rothwell, J., Puri, B.K., eds. *Handbook of transcranial magnetic stimulation*. London: Arnold. 3-17.
- Bear, M.F., Connors, B.W., Paradiso, M.A. (2007). *Neuroscience: Exploring the brain*: Lippincott Williams & Wilkins.
- Bechara, A., Damasio, H., Tranel, D., Damasio, A.R. (1997). Deciding Advantageously Before Knowing the Advantageous Strategy. *Science* 5304, 1293-1295.
- Bechara, A., Damasio, H., Damasio, A.R. (2000). Emotion, Decision Making and the Orbitofrontal Cortex. *Cereb Cortex* 3, 295-307.
- Benjamini, Y., Drai, D., Elmer, G., Kafkafi, N., Golani, I. (2001). Controlling the false discovery rate in behavior genetics research. *Behav Brain Res* 1-2, 279-284.
- Bohnen, N.I., Minoshima, S., Giordani, B., Frey, K.A., Kuhl, D.E. (1999). Motor correlates of occipital glucose hypometabolism in Parkinson's disease without dementia. *Neurology* 3, 541.
- Botvinick, M., Nystrom, L.E., Fissell, K., Carter, C.S., Cohen, J.D. (1999). Conflict monitoring versus selection-for-action in anterior cingulate cortex. *Nature* 6758, 179-180.
- Boussaoud, D., Wise, S.P. (1993). Primate frontal cortex: effects of stimulus and movement. *Exp Brain Res* 1, 28-40.
- Boussaoud, D. (1995). Primate premotor cortex: modulation of preparatory neuronal activity by gaze angle. *J Neurophysiol* 2, 886.
- Boussaoud, D. (2001). Attention versus Intention in the Primate Premotor Cortex. *Neuroimage* 1, S40-S45.
- Braak, H., Del Tredici, K., Rüb, U., de Vos, R.A.I., Jansen Steur, E.N.H., Braak, E. (2003). Staging of brain pathology related to sporadic Parkinson's disease. *Neurobiol Aging* 2, 197-211.
- Braak, H., Ghebremedhin, E., Rüb, U., Bratzke, H., Del Tredici, K. (2004). Stages in the development of Parkinson's disease-related pathology. *Cell Tissue Res* 1, 121-134.

- Braak, H., Bohl, J.R., Müller, C.M., Rüb, U., de Vos, R.A.I., Del Tredici, K. (2006). Stanley Fahn Lecture 2005: The staging procedure for the inclusion body pathology associated with sporadic Parkinson's disease reconsidered. *Mov Disord* 12, 2042-2051.
- Brinkman, C. (1981). Lesions in supplementary motor area interfere with a monkey's performance of a bimanual coordination task. *Neurosci Lett.* 3, 267-270.
- Brück, A., Kurki, T., Kaasinen, V., Vahlberg, T., Rinne, J.O. (2004). Hippocampal and prefrontal atrophy in patients with early non-demented Parkinson's disease is related to cognitive impairment. *J Neurol Neurosurg Psychiatry* 10, 1467-1469.
- Brück, A., Aalto, S., Nurmi, E., Vahlberg, T., Bergman, J., Rinne, J.O. (2006). Striatal subregional 6-[18F] fluoro-L-dopa uptake in early Parkinson's disease: a two-year follow-up study. *Mov Disord* 7, 958-963.
- Büchel, C., Friston, K. (2000). Assessing interactions among neuronal systems using functional neuroimaging. *Neural Netw* 8-9, 871-882.
- Bullmore, E., Sporns, O. (2009). Complex brain networks: graph theoretical analysis of structural and functional systems. *Nat Rev Neurosci* 3, 186-198.
- Burton, E.J., McKeith, I.G., Burn, D.J., Williams, E.D., O'Brien, J.T. (2004). Cerebral atrophy in Parkinson's disease with and without dementia: a comparison with Alzheimer's disease, dementia with Lewy bodies and controls. *Brain* 4, 791-800.
- Buter, T.C., van den Hout, A., Matthews, F.E., Larsen, J.P., Brayne, C., Aarsland, D. (2008). Dementia and survival in Parkinson disease. *Neurology* 13, 1017-1022.
- Caminiti, R., Ferraina, S., Johnson, P.B. (1996). The sources of visual information to the primate frontal lobe: a novel role for the superior parietal lobule. *Cereb Cortex* 3, 319.
- Cardinal, R.N., Parkinson, J.A., Hall, J., Everitt, B.J. (2002). Emotion and motivation: the role of the amygdala, ventral striatum, and prefrontal cortex. *Neurosci Biobehav Rev* 3, 321-52.
- Carter, C.S., Macdonald, A.M., Botvinick, M., Ross, L.L., Stenger, V.A., Noll, D., Cohen, J.D. (2000). Parsing executive processes: strategic vs. evaluative functions of the anterior cingulate cortex. *Proc Natl Acad Sci* 4, 1944.
- Caspers, S., Geyer, S., Schleicher, A., Mohlberg, H., Amunts, K., Zilles, K. (2006). The human inferior parietal cortex: cytoarchitectonic parcellation and interindividual variability. *Neuroimage* 2, 430-448.
- Chen, Z.J., He, Y., Rosa-Neto, P., Germann, J., Evans, A.C. (2008). Revealing modular architecture of human brain structural networks by using cortical thickness from MRI. *Cereb Cortex* 10, 2374.
- Churchland, M.M., Cunningham, J.P., Kaufman, M.T., Ryu, S.I., Shenoy, K.V. (2010). Cortical Preparatory Activity: Representation of Movement or First Cog in a Dynamical Machine? *Neuron* 3, 387-400.
- Collins, D.L., Neelin, P., Peters, T.M., Evans, A.C. (1994). Automatic 3D intersubject registration of MR volumetric data in standardized Talairach space. *J Comput Assist Tomogr* 2, 192-205.
- Cools, R. (2006). Dopaminergic modulation of cognitive function-implications for l-DOPA treatment in Parkinson's disease. *Neurosci Biobehav Rev* 1, 1-23.
- Cronin-Golomb, A. (2013). Emergence of nonmotor symptoms as the focus of research and treatment of Parkinson's disease: Introduction to the special section on nonmotor dysfunctions in Parkinson's disease. *Behav Neurosci* 2, 135.
- Crosson, B., Sadek, J.R., Bobholz, J.A., Gökçay, D., Mohr, C.M., Leonard, C.M., Maron, L., Auerbach, E.J., Browd, S.R., Freeman, A.J. (1999). Activity in the paracingulate and cingulate sulci during word generation: an fMRI study of functional anatomy. *Cereb Cortex* 4, 307.

- Dale, A.M., Fischl, B., Sereno, M.I. (1999). Cortical surface-based analysis: I. Segmentation and surface reconstruction. *Neuroimage* 2, 179-194.
- Daskalakis, Z.J., Christensen, B.K., Fitzgerald, P.B., Chen, R. (2002). Transcranial magnetic stimulation: a new investigational and treatment tool in psychiatry. *J Neuropsychiatry Clin Neurosci* 4, 406-15.
- Del Tredici, K., Rüb, U., De Vos, R.A.I., Bohl, J.R.E., Braak, H. (2002). Where does Parkinson disease pathology begin in the brain? *J Neuropathol Exp Neurol* 5, 413-426.
- di Pellegrino, G., Wise, S.P. (1993). Visuospatial versus visuomotor activity in the premotor and prefrontal cortex of a primate. *J Neurosci* 3, 1227-1243.
- Drevets, W.C., Raichle, M.E. (1995). Positron emission tomographic imaging studies of human emotional disorders. In: Gazzaniga, M.S., Editor. *The cognitive neurosciences*. Cambridge, MA, US: The MIT Press. 1153-1164.
- Dum, R.P., Strick, P.L. (1991). The origin of corticospinal projections from the premotor areas in the frontal lobe. *J Neurosci* 3, 667-689.
- Eberling, J.L., Richardson, B.C., Reed, B.R., Wolfe, N., Jagust, W.J. (1994). Cortical glucose metabolism in Parkinson's disease without dementia. *Neurobiol Aging* 3, 329-335.
- Ebmeier, K.P., Lappin, J.M. (2001). Electromagnetic stimulation in psychiatry. *Adv Psychiatr Treat* 3, 181.
- Ekman, U., Eriksson, J., Forsgren, L., Mo, S.J., Riklund, K., Nyberg, L. (2012). Functional brain activity and presynaptic dopamine uptake in patients with Parkinson's disease and mild cognitive impairment: a cross-sectional study. *Lancet Neurol* 8, 679-687.
- Evarts, E.V., Teravainen, H.T., Beuchert, D.E., Calne, D.B. (1979). Pathophysiology of motor performance in Parkinson's disease. In: Fuxe, K., Calne, D.B., eds. *Dopaminergic Ergot Derivatives and Motor function*. Oxford: Pergamon Press. 45-59.
- Evarts, E.V., Teräväinen, H., Calne, D.B. (1981). Reaction time in Parkinson's disease. *Brain* 1, 167-186.
- Fields, R.D. (2008). White matter in learning, cognition and psychiatric disorders. *Trends Neurosci* 7, 361-370.
- Fink, G.R., Frackowiak, R.S.J., Pietrzyk, U., Passingham, R.E. (1997). Multiple Nonprimary Motor Areas in the Human Cortex. *J Neurophysiol* 4, 2164-2174.
- Fischl, B., Sereno, M.I., Dale, A.M. (1999). Cortical surface-based analysis: II: Inflation, flattening, and a surface-based coordinate system. *Neuroimage* 2, 195-207.
- Fischl, B., Dale, A.M. (2000). Measuring the thickness of the human cerebral cortex from magnetic resonance images. *Proc Natl Acad Sci* 20, 11050-5.
- Freeman, S.H., Kandel, R., Cruz, L., Rozkalne, A., Newell, K., Frosch, M.P., Hedley-Whyte, E.T., Locascio, J.J., Lipsitz, L., Hyman, B.T. (2008). Preservation of neuronal number despite age-related cortical brain atrophy in elderly subjects without Alzheimer disease. *J Neuropathol Exp Neurol* 12, 1205.
- Friston, K.J., Frith, C.D., Fiddle, P.F., Frackowiak, R.S.J. (1993). Functional connectivity: the principal-component analysis of large (PET) data sets. *J Cereb Blood Flow Metab*, 5-14.
- Friston, K.J. (1994). Functional and effective connectivity in neuroimaging: a synthesis. *Hum Brain Mapp* 1-2, 56-78.
- Gabernet, L., Meskenaite, V., Hepp-Reymond, M.-C. (1999). Parcellation of the lateral premotor cortex of the macaque monkey based on staining with the neurofilament antibody SMI-32. *Exp Brain Res* 1, 188-193.
- Gallese, V., Murata, A., Kaseda, M., Niki, N., Sakata, H. (1994). Deficit of hand preshaping after muscimol injection in monkey parietal cortex. *Neuroreport* 12, 1525-9.

- Gentilucci, M., Fogassi, L., Luppino, G., Matelli, M., Camarda, R., Rizzolatti, G. (1988). Functional organization of inferior area 6 in the macaque monkey. *Exp Brain Res* 3, 475-490.
- Georgopoulos, A.P., Kettner, R.E., Schwartz, A.B. (1988). Primate motor cortex and free arm movements to visual targets in three-dimensional space. II. Coding of the direction of movement by a neuronal population. *J Neurosci* 8, 2928-2937.
- Gershon, A.A., Dannon, P.N., Grunhaus, L. (2003). Transcranial magnetic stimulation in the treatment of depression. *Am J Psychiatry* 5, 835.
- Geyer, S., Ledberg, A., Schleicher, A., Kinomura, S., Schormann, T., Burgel, U., Klingberg, T., Larsson, J., Zilles, K., Roland, P.E. (1996). Two different areas within the primary motor cortex of man. *Nature* 6594, 805-807.
- Geyer, S., Matelli, M., Luppino, G., Zilles, K. (2000a). Functional neuroanatomy of the primate isocortical motor system. *Anat Embryol* 6, 443-474.
- Geyer, S., Zilles, K., Luppino, G., Matelli, M. (2000b). Neurofilament protein distribution in the macaque monkey dorsolateral premotor cortex. *Eur J Neurosci* 5, 1554-1566.
- Ghosh, S., Brinkman, C., Porter, R. (1987). A quantitative study of the distribution of neurons projecting to the precentral motor cortex in the monkey (*M. fascicularis*). *J Comp Neurol* 3, 424-444.
- Goldberg, G. (1985). Supplementary motor area structure and function: review and hypotheses. *Behav Brain Sci* 04, 567-588.
- Grafton, S.T., Hazeltine, E., Ivry, R.B. (1998). Abstract and effector-specific representations of motor sequences identified with PET. *J Neurosci* 22, 9420.
- Graziano, M.S.A., Yap, G.S., Gross, C.G. (1994). Coding of visual space by premotor neurons. *Science* 5187, 1054-1057.
- Grèzes, J., Decety, J. (2001). Functional anatomy of execution, mental simulation, observation, and verb generation of actions: A meta-analysis. *Hum Brain Mapp* 1, 1-19.
- Groppa, S., Schlaak, B.H., Münchau, A., Werner-Petroll, N., Dünneberger, J., Bäumer, T., van Nuenen, B.F.L., Siebner, H.R. (2012). The human dorsal premotor cortex facilitates the excitability of ipsilateral primary motor cortex via a short latency cortico-cortical route. *Hum Brain Mapp* 2, 419-430.
- Guillery, R.W., Sherman, S.M. (2002). The thalamus as a monitor of motor outputs. *Philos Trans R Soc Lond B Biol Sci* 1428, 1809-1821.
- Guillery, R.W. (2003). Branching thalamic afferents link action and perception. *J Neurophysiol* 2, 539-548.
- Habas, C. (2010). Functional connectivity of the human rostral and caudal cingulate motor areas in the brain resting state at 3T. *Neuroradiology* 1, 47-59.
- Halsband, U., Passingham, R. (1982). The role of premotor and parietal cortex in the direction of action. *Brain Res* 2, 368-372.
- Haslinger, B., Erhard, P., Kampfe, N., Boecker, H., Rummeny, E., Schwaiger, M., Conrad, B., Ceballos-Baumann, A.O. (2001). Event-related functional magnetic resonance imaging in Parkinson's disease before and after levodopa. *Brain* 3, 558.
- Hatanaka, N., Tokuno, H., Hamada, I., Inase, M., Ito, Y., Imanishi, M., Hasegawa, N., Akazawa, T., Nambu, A., Takada, M. (2003). Thalamocortical and intracortical connections of monkey cingulate motor areas. *J Comp Neurol* 1, 121-138.
- He, S.Q., Dum, R.P., Strick, P.L. (1993). Topographic organization of corticospinal projections from the frontal lobe: motor areas on the lateral surface of the hemisphere. *J Neurosci* 3, 952.

- He, S.Q., Dum, R.P., Strick, P.L. (1995). Topographic organization of corticospinal projections from the frontal lobe: motor areas on the medial surface of the hemisphere. *J Neurosci* 5, 3284-3306.
- Helmich, R.C., Aarts, E., de Lange, F.P., Bloem, B.R., Toni, I. (2009a). Increased dependence of action selection on recent motor history in Parkinson's disease. *J Neurosci* 19, 6105.
- Helmich, R.C., Derikx, L.C., Bakker, M., Scheeringa, R., Bloem, B.R., Toni, I. (2009b). Spatial Remapping of Cortico-striatal Connectivity in Parkinson's Disease. *Cereb Cortex* 5, 1175-1186.
- Hikosaka, O., Nakamura, K., Sakai, K., Nakahara, H. (2002). Central mechanisms of motor skill learning. *Curr Opin Neurobiol* 2, 217-222.
- Horwitz, B., Deiber, M.P., Ibáñez, V., Sadato, N., Hallett, M. (2000). Correlations between Reaction Time and Cerebral Blood Flow during Motor Preparation. *Neuroimage* 4, 434-441.
- Hu, M.T.M., Taylor-Robinson, S.D., Chaudhuri, K.R., Bell, J.D., Labbé, C., Cunningham, V.J., Koeppe, M.J., Hammers, A., Morris, R.G., Turjanski, N., Brooks, D.J. (2000). Cortical dysfunction in non-demented Parkinson's disease patients. *Brain* 2, 340-352.
- Huang, C., Mattis, P., Tang, C., Perrine, K., Carbon, M., Eidelberg, D. (2007). Metabolic brain networks associated with cognitive function in Parkinson's disease. *Neuroimage* 2, 714-723.
- Hurtig, H.I., Trojanowski, J.Q., Galvin, J., Ewbank, D., Schmidt, M.L., Lee, V.M.-Y., Clark, C.M., Glosser, G., Stern, M.B., Gollomp, S.M., Arnold, S.E. (2000). Alpha-synuclein cortical Lewy bodies correlate with dementia in Parkinson's disease. *Neurology* 10, 1916-1921.
- Jahanshahi, M., Jenkins, I.H., Brown, R.G., Marsden, C.D., Passingham, R.E., Brooks, D.J. (1995). Self-initiated versus externally triggered movements. An investigation using measurement of regional cerebral blood flow with PET and movement-related potentials in normal and Parkinson's disease subjects. *Brain* 4, 913-933.
- Jahanshahi, M., Dirnberger, G. (1999). The left dorsolateral prefrontal cortex and random generation of responses: studies with transcranial magnetic stimulation. *Neuropsychologia* 2, 181-90.
- Jenkins, I.H., Brooks, D.J., Nixon, P.D., Frackowiak, R.S., Passingham, R.E. (1994). Motor sequence learning: a study with positron emission tomography. *J Neurosci* 6, 3775.
- Jenkins, I.H., Jahanshahi, M., Jueptner, M., Passingham, R.E., Brooks, D.J. (2000). Self-initiated versus externally triggered movements: II. The effect of movement predictability on regional cerebral blood flow. *Brain* 6, 1216.
- Johansen-Berg, H. (2010). Behavioural relevance of variation in white matter microstructure. *Curr Opin Neurol* 4, 351-358.
- Jones, E.G., Wise, S.P. (1977). Size, laminar and columnar distribution of efferent cells in the sensory-motor cortex of monkeys. *J Comp Neurol* 4, 391-437.
- Jubault, T., Gagnon, J.-F., Karama, S., Ptito, A., Lafontaine, A.-L., Evans, A.C., Monchi, O. (2011). Patterns of cortical thickness and surface area in early Parkinson's disease. *Neuroimage* 2, 462-467.
- Kaas, J.H. (1995). The evolution of isocortex. *Brain Behav Evol* 4-5, 187-196.
- Karagulle Kendi, A.T., Lehericy, S., Luciana, M., Ugurbil, K., Tuite, P. (2008). Altered diffusion in the frontal lobe in Parkinson disease. *AJNR Am J Neuroradiol* 3, 501-5.
- Keizer, K., Kuypers, H. (1989). Distribution of corticospinal neurons with collaterals to the lower brain stem reticular formation in monkey (*Macaca fascicularis*). *Neurosci Res* 2, 311-318.

- Kojovic, M., Mir, P., Trender-Gerhard, I., Schneider, S., Pareés, I., Edwards, M., Bhatia, K., Jahanshahi, M. (2014). Motivational modulation of bradykinesia in Parkinson's disease off and on dopaminergic medication. *J Neurol*, 1-10.
- Koski, L., Paus, T. (2000). Functional connectivity of the anterior cingulate cortex within the human frontal lobe: a brain-mapping meta-analysis. *Exp Brain Res* 1, 55-65.
- Kurata, K. (1991). Corticocortical inputs to the dorsal and ventral aspects of the premotor cortex of macaque monkeys. *Neurosci Res* 1, 263-280.
- Kurata, K., Hoffman, D.S. (1994). Differential effects of muscimol microinjection into dorsal and ventral aspects of the premotor cortex of monkeys. *J Neurophysiol* 3, 1151.
- Kwan, C.L., Crawley, A.P., Mikulis, D.J., Davis, K.D. (2000). An fMRI study of the anterior cingulate cortex and surrounding medial wall activations evoked by noxious cutaneous heat and cold stimuli. *Pain* 3, 359-374.
- Lisanby, S., McDonald, W., Massey, E., Doraiswamy, P., Rozear, M., Boyko, O., Krishnan, K., Nemeroff, C. (1993). Diminished subcortical nuclei volumes in Parkinson's disease by MR imaging. *J Neural Transm Suppl*, 13-21.
- Lu, M.-T., Preston, J.B., Strick, P.L. (1994). Interconnections between the prefrontal cortex and the premotor areas in the frontal lobe. *J Comp Neurol* 3, 375-392.
- Luppino, G., Matelli, M., Rizzolatti, G. (1990). Cortico-cortical connections of two electrophysiologically identified arm representations in the mesial agranular frontal cortex. *Exp Brain Res* 1, 214-218.
- Luppino, G., Matelli, M., Camarda, R.M., Gallese, V., Rizzolatti, G. (1991). Multiple representations of body movements in mesial area 6 and the adjacent cingulate cortex: An intracortical microstimulation study in the macaque monkey. *J Comp Neurol* 4, 463-482.
- Luppino, G., Matelli, M., Camarda, R., Rizzolatti, G. (1993). Corticocortical connections of area F3 (SMA-proper) and area F6 (pre-SMA) in the macaque monkey. *J Comp Neurol* 1, 114-140.
- Lyoo, C.H., Ryu, Y.H., Lee, M.S. (2010). Topographical distribution of cerebral cortical thinning in patients with mild Parkinson's disease without dementia. *Mov Disord* 4, 496-499.
- Maccabee, P.J., Amassian, V.E., Eberle, L.P., Cracco, R.Q. (1993). Magnetic coil stimulation of straight and bent amphibian and mammalian peripheral nerve in vitro: locus of excitation. *J Physiol* 1, 201.
- MacDonald, V., Halliday, G.M. (2002). Selective loss of pyramidal neurons in the pre-supplementary motor cortex in Parkinson's disease. *Mov Disord* 6, 1166-1173.
- Maeda, F., Pascual-Leone, A. (2003). Transcranial magnetic stimulation: studying motor neurophysiology of psychiatric disorders. *Psychopharmacology (Berl)* 4, 359-76.
- Matelli, M., Luppino, G., Rizzolatti, G. (1985). Patterns of cytochrome oxidase activity in the frontal agranular cortex of the macaque monkey. *Behav Brain Res* 2, 125-136.
- Matelli, M., Luppino, G., Fogassi, L., Rizzolatti, G. (1989). Thalamic input to inferior area 6 and area 4 in the macaque monkey. *J Comp Neurol* 3, 468-488.
- Matelli, M., Luppino, G., Rizzolatti, G. (1991). Architecture of superior and mesial area 6 and the adjacent cingulate cortex in the macaque monkey. *J Comp Neurol* 4, 445-462.
- Matelli, M., Luppino, G. (1996). Thalamic input to mesial and superior area 6 in the macaque monkey. *J Comp Neurol* 1, 59-87.
- Matelli, M., Govoni, P., Galletti, C., Kutz, D.F., Luppino, G. (1998). Superior area 6 afferents from the superior parietal lobule in the macaque monkey. *J Comp Neurol* 3, 327-352.
- Matsuzaka, Y., Aizawa, H., Tanji, J. (1992). A motor area rostral to the supplementary motor area (presupplementary motor area) in the monkey: neuronal activity during a learned motor task. *J Neurophysiol* 3, 653-662.

- Mazziotta, J.C., Toga, A.W., Evans, A., Fox, P., Lancaster, J. (1995). A probabilistic atlas of the human brain: theory and rationale for its development: The International Consortium for Brain Mapping (ICBM). *Neuroimage* 2, Part A, 89-101.
- McGeer, P.L., McGeer, E.G. (2004). Inflammation and neurodegeneration in Parkinson's disease. *Parkinsonism Relat Disord*, S3-S7.
- Mehler-Wex, C., Riederer, P., Gerlach, M. (2006). Dopaminergic dysbalance in distinct basal ganglia neurocircuits: Implications for the pathophysiology of parkinson's disease, schizophrenia and attention deficit hyperactivity disorder. *Neurotox Res* 3-4, 167-79.
- Merchant, H., Battaglia-Mayer, A., Georgopoulos, A.P. (2001). Effects of optic flow in motor cortex and area 7a. *J Neurophysiol* 4, 1937-1954.
- Mitz, A.R., Godschalk, M., Wise, S.P. (1991). Learning-dependent neuronal activity in the premotor cortex: activity during the acquisition of conditional motor associations. *J Neurosci* 6, 1855-1872.
- Monchi, O., Petrides, M., Petre, V., Worsley, K., Dagher, A. (2001). Wisconsin Card Sorting revisited: distinct neural circuits participating in different stages of the task identified by event-related functional magnetic resonance imaging. *J Neurosci* 19, 7733-41.
- Monchi, O., Petrides, M., Doyon, J., Postuma, R.B., Worsley, K., Dagher, A. (2004). Neural bases of set-shifting deficits in Parkinson's disease. *J Neurosci* 3, 702-10.
- Morecraft, R.J., van Hoesen, G.W. (1993). Frontal granular cortex input to the cingulate (M3), supplementary (M2) and primary (M1) motor cortices in the rhesus monkey. *J Comp Neurol* 4, 669-689.
- Morecraft, R.J., Van Hoesen, G.W. (1998). Convergence of Limbic Input to the Cingulate Motor Cortex in the Rhesus Monkey. *Brain Res Bull* 2, 209-232.
- Morecraft, R.J., Rockland, K.S., Van Hoesen, G.W. (2000). Localization of Area Prostriata and its Projection to the Cingulate Motor Cortex in the Rhesus Monkey. *Cereb Cortex* 2, 192-203.
- Morecraft, R.J., Cipolloni, P.B., Stilwell-Morecraft, K.S., Gedney, M.T., Pandya, D.N. (2004). Cytoarchitecture and cortical connections of the posterior cingulate and adjacent somatosensory fields in the rhesus monkey. *J Comp Neurol* 1, 37-69.
- Morey, R.A., Petty, C.M., Xu, Y., Pannu Hayes, J., Wagner II, H.R., Lewis, D.V., LaBar, K.S., Styner, M., McCarthy, G. (2009). A comparison of automated segmentation and manual tracing for quantifying hippocampal and amygdala volumes. *Neuroimage* 3, 855-866.
- Mountcastle, V.B. (1997). The columnar organization of the neocortex. *Brain* 4, 701-722.
- Muakkassa, K.F., Strick, P.L. (1979). Frontal lobe inputs to primate motor cortex: evidence for four somatotopically organized 'premotor' areas. *Brain Res* 1, 176-182.
- Murata, A., Fadiga, L., Fogassi, L., Gallese, V., Raos, V., Rizzolatti, G. (1997). Object Representation in the Ventral Premotor Cortex (Area F5) of the Monkey. *J Neurophysiol* 4, 2226-2230.
- Mushiake, H., Inase, M., Tanji, J. (1991). Neuronal activity in the primate premotor, supplementary, and precentral motor cortex during visually guided and internally determined sequential movements. *J Neurophysiol* 3, 705-718.
- Nagamachi, S., Wakamatsu, H., Kiyohara, S., Fujita, S., Futami, S., Tamura, S., Nakazato, M., Yamashita, S., Arita, H., Nishii, R., Kawai, K. (2008). Usefulness of rCBF analysis in diagnosing Parkinson's disease: supplemental role with MIBG myocardial scintigraphy. *Ann Nucl Med* 7, 557-64.
- Nagano-Saito, A., Washimi, Y., Arahata, Y., Kachi, T., Lerch, J.P., Evans, A.C., Dagher, A., Ito, K. (2005). Cerebral atrophy and its relation to cognitive impairment in Parkinson disease. *Neurology* 2, 224-229.

- Oldfield, R.C. (1971). The assessment and analysis of handedness: The Edinburgh inventory. *Neuropsychologia* 1, 97-113.
- Palmer, S.J., Eigenraam, L., Hoque, T., McCaig, R.G., Troiano, A., McKeown, M.J. (2009). Levodopa-sensitive, dynamic changes in effective connectivity during simultaneous movements in Parkinson's disease. *Neuroscience* 2, 693-704.
- Palmer, S.J., Li, J., Wang, Z.J., McKeown, M.J. (2010). Joint amplitude and connectivity compensatory mechanisms in Parkinson's disease. *Neuroscience* 4, 1110-1118.
- Panizzon, M.S., Fennema-Notestine, C., Eyler, L.T., Jernigan, T.L., Prom-Wormley, E., Neale, M., Jacobson, K., Lyons, M.J., Grant, M.D., Franz, C.E., Xian, H., Tsuang, M., Fischl, B., Seidman, L., Dale, A., Kremen, W.S. (2009). Distinct genetic influences on cortical surface area and cortical thickness. *Cereb Cortex* 11, 2728-2735.
- Pascual-Leone, A., Walsh, V., Rothwell, J. (2000). Transcranial magnetic stimulation in cognitive neuroscience-virtual lesion, chronometry, and functional connectivity. *Curr Opin Neurobiol.* 2, 232-237.
- Passingham, R.E. (1995). *The frontal lobes and voluntary action*: Oxford University Press, USA.
- Patenaude, B. (2007). *Bayesian Statistical Models of Shape and Appearance for Subcortical Brain Segmentation*. University of Oxford.
- Pears, A., Parkinson, J.A., Hopewell, L., Everitt, B.J., Roberts, A.C. (2003). Lesions of the Orbitofrontal but not Medial Prefrontal Cortex Disrupt Conditioned Reinforcement in Primates. *J Neurosci* 35, 11189-11201.
- Pedersen, K.M., Marner, L., Pakkenberg, H., Pakkenberg, B. (2005). No global loss of neocortical neurons in parkinson's disease: A quantitative stereological study. *Mov Disord* 2, 164-171.
- Penfield, W., Rasmussen, T. (1950). *The Cerebral Cortex of Man*: The Macmillan Company. 248.
- Petersen, S.E., Fox, P.T., Posner, M.I., Mintum, M., Raichle, M.E. (2004). Positron emission tomographic studies of the cortical anatomy of single-word processing. *Nature*, 109.
- Petit, L., Courtney, S.M., Ungerleider, L.G., Haxby, J.V. (1998). Sustained activity in the medial wall during working memory delays. *J Neurosci* 22, 9429.
- Petrides, M. (1982). Motor conditional associative-learning after selective prefrontal lesions in the monkey. *Behav Brain Res* 4, 407-413.
- Petrides, M. (1990). Nonspatial conditional learning impaired in patients with unilateral frontal but not unilateral temporal lobe excisions. *Neuropsychologia* 2, 137-49.
- Petrides, M., Paxinos, G., Huang, X.F., Morris, R., Pandya, D.N. (2000). Delineation of the monkey cortex on the basis of the distribution of a neurofilament protein. In: Paxinos, G., Huang, X.F., Toga, A., eds. *The rhesus monkey brain in stereotaxic coordinates*. San Diego: Academic Press. 155-229.
- Picard, N., Strick, P.L. (1996). Motor areas of the medial wall: A review of their location and functional activation. *Cereb Cortex* 3, 342-353.
- Picard, N., Strick, P.L. (2001). Imaging the premotor areas. *Curr Opin Neurobiol* 6, 663-672.
- Playford, E.D., Jenkins, I.H., Passingham, R.E., Nutt, J., Frackowiak, R.S.J., Brooks, D.J. (1992). Impaired mesial frontal and putamen activation in Parkinson's disease: a positron emission tomography study. *Ann Neurol* 2, 151-161.
- Rakic, P. (1988). Specification of cerebral cortical areas. *Science* 4862, 170-176.
- Rakic, P. (2007). The radial edifice of cortical architecture: From neuronal silhouettes to genetic engineering. *Brain Res Rev* 2, 204-219.
- Rascol, O., Sabatini, U., Fabre, N., Brefel, C., Loubinoux, I., Celsis, P., Senard, J.M., Montastruc, J.L., Chollet, F. (1997). The ipsilateral cerebellar hemisphere is overactive during hand movements in akinetic parkinsonian patients. *Brain* 1, 103.

- Rektorova, I., Barrett, J., Mikl, M., Rektor, I., Paus, T. (2007). Functional abnormalities in the primary orofacial sensorimotor cortex during speech in Parkinson's disease. *Mov Disord* 14, 2043-51.
- Rijk, M.C., Tzourio, C., Breteler, M.M., Dartigues, J.F., Amaducci, L., Lopez-Pousa, S., Manubens-Bertran, J.M., Alperovitch, A., Rocca, W.A. (1997). Prevalence of parkinsonism and Parkinson's disease in Europe: the EUROPARKINSON Collaborative Study. European Community Concerted Action on the Epidemiology of Parkinson's disease. *J Neurol Neurosurg Psychiatry* 1, 10-15.
- Rizzolatti, G., Camarda, R., Fogassi, L., Gentilucci, M., Luppino, G., Matelli, M. (1988). Functional organization of inferior area 6 in the macaque monkey. *Exp Brain Res* 3, 491-507.
- Rizzolatti, G., Luppino, G., Matelli, M. (1996). The classic supplementary motor area is formed by two independent areas. In: Lüders, H., Editor. *Supplementary sensorimotor area*. Philadelphia: Lippincott-Raven. 45-56.
- Rizzolatti, G., Arbib, M.A. (1998a). Language within our grasp. *Trends Neurosci* 5, 188-94.
- Rizzolatti, G., Luppino, G., Matelli, M. (1998b). The organization of the cortical motor system: new concepts. *Electroencephalogr Clin Neurophysiol* 4, 283-296.
- Rossini, P.M., Barker, A.T., Berardelli, A., Caramia, M.D., Caruso, G., Cracco, R.Q., Dimitrijevi, M.R., Hallett, M., Katayama, Y., Lücking, C.H. (1994). Non-invasive electrical and magnetic stimulation of the brain, spinal cord and roots: basic principles and procedures for routine clinical application. Report of an IFCN committee. *Electroencephalography and Clinical Neurophysiology*. 2, 79.
- Rothwell, J.C. (2010). Using transcranial magnetic stimulation methods to probe connectivity between motor areas of the brain. *Human Movement Science*.
- Rouiller, E.M., Liang, F., Babalian, A., Moret, V., Wiesendanger, M. (1994). Cerebellothalamocortical and pallidothalamocortical projections to the primary and supplementary motor cortical areas: A multiple tracing study in macaque monkeys. *J Comp Neurol* 2, 185-213.
- Rowe, J., Stephan, K.E., Friston, K., Frackowiak, R., Lees, A., Passingham, R. (2002). Attention to action in Parkinson's disease: impaired effective connectivity among frontal cortical regions. *Brain* 2, 276.
- Rüb, U., Del Tredici, K., Schultz, C., Ghebremedhin, E., de Vos, R.A.I., Jansen Steur, E., Braak, H. (2002). Parkinson's disease: the thalamic components of the limbic loop are severely impaired by α -synuclein immunopositive inclusion body pathology. *Neurobiol Aging* 2, 245-254.
- Sabatini, U., Boulanouar, K., Fabre, N., Martin, F., Carel, C., Colonnese, C., Bozzao, L., Berry, I., Montastruc, J.L., Chollet, F., Rascol, O. (2000a). Cortical motor reorganization in akinetic patients with Parkinson's disease: a functional MRI study. *Brain* 2, 394.
- Sabatini, U., Boulanouar, K., Fabre, N., Martin, F., Carel, C., Colonnese, C., Bozzao, L., Berry, I., Montastruc, J.L., Chollet, F., Rascol, O. (2000b). Cortical motor reorganization in akinetic patients with Parkinson's disease. *Brain* 2, 394-403.
- Sabbagh, M.N., Adler, C.H., Lahti, T.J., Connor, D.J., Vedders, L., Peterson, L.K., Caviness, J.N., Shill, H.A., Sue, L.I., Ziabreva, I. (2009). Parkinson's disease with dementia: comparing patients with and without Alzheimer pathology. *Alzheimer Dis Assoc Disord* 3, 295-7.
- Salmon, D.P., Galasko, D., Hansen, L.A., Masliah, E., Butters, N., Thal, L.J., Katzman, R. (1996). Neuropsychological Deficits Associated with Diffuse Lewy Body Disease. *Brain Cogn* 2, 148-165.

- Samuel, M., Ceballos-Baumann, A.O., Blin, J., Uema, T., Boecker, H., Passingham, R.E., Brooks, D.J. (1997). Evidence for lateral premotor and parietal overactivity in Parkinson's disease during sequential and bimanual movements. A PET study. *Brain* 6, 963-976.
- Scholz, J., Tomassini, V., Johansen-Berg, H. (2009). Individual differences in white matter microstructure in the healthy human brain. In: Johansen-Berg, H., Behrens, T.E.J., Editor. *Diffusion MRI: From quantitative measurement to in-vivo neuroanatomy*. London: Oxford: Elsevier. 237-250.
- Schubotz, R.I., Von Cramon, D.Y. (2003). Functional-anatomical concepts of human premotor cortex: evidence from fMRI and PET studies. *Neuroimage* 1, 120.
- Schwartz, A.B. (1994). Distributed motor processing in cerebral cortex. *Curr Opin Neurobiol* 6, 840-846.
- Shen, L., Alexander, G.E. (1997). Preferential Representation of Instructed Target Location Versus Limb Trajectory in Dorsal Premotor Area. *J Neurophysiol* 3, 1195-1212.
- Shima, K., Tanji, J. (1998). Both supplementary and presupplementary motor areas are crucial for the temporal organization of multiple movements. *J Neurophysiol.* 6, 3247.
- Shohamy, D., Myers, C.E., Grossman, S., Sage, J., Gluck, M.A., Poldrack, R.A. (2004). Cortico-striatal contributions to feedback-based learning: converging data from neuroimaging and neuropsychology. *Brain* 4, 851-859.
- Siebner, H.R., Rothwell, J. (2003). Transcranial magnetic stimulation: new insights into representational cortical plasticity. *Exp Brain Res* 1, 1-16.
- Simon, J.R. (1967). Choice reaction time as a function of auditory S-R correspondence, age and sex. *Ergonomics* 6, 559-564.
- Sled, J.G., Zijdenbos, A.P., Evans, A.C. (1998). A nonparametric method for automatic correction of intensity nonuniformity in MRI data. *IEEE Trans Med Imaging* 1, 87-97.
- Smith, S.M., Zhang, Y., Jenkinson, M., Chen, J., Matthews, P.M., Federico, A., De Stefano, N. (2002). Accurate, Robust, and Automated Longitudinal and Cross-Sectional Brain Change Analysis. *Neuroimage* 1, 479-489.
- Smith, S.M., Jenkinson, M., Woolrich, M.W., Beckmann, C.F., Behrens, T.E.J., Johansen-Berg, H., Bannister, P.R., De Luca, M., Drobnjak, I., Flitney, D.E., Niazy, R.K., Saunders, J., Vickers, J., Zhang, Y., De Stefano, N., Brady, J.M., Matthews, P.M. (2004). Advances in functional and structural MR image analysis and implementation as FSL. *Neuroimage* 0, S208-S219.
- Sporns, O. (2009). The human connectome: linking structure and function in the human brain. In: Johansen-Berg, H., Behrens, T.E.J., Editor. *Diffusion MRI: From quantitative measurement to in-vivo neuroanatomy*. London: Oxford: Elsevier.
- Stepniewska, I., Preuss, T.M., Kaas, J.H. (1993). Architectonics, somatotopic organization, and ipsilateral cortical connections of the primary motor area (M1) of owl monkeys. *J Comp Neurol* 2, 238-271.
- Strick, P.L., Sterling, P. (1974). Synaptic termination of P afferents from the ventrolateral nucleus of the thalamus in the cat motor cortex: A light and electron microscope study. *J Comp Neurol*, 77-106.
- Strick, P.L., Preston, J.B. (1982). Two representations of the hand in area 4 of a primate. I. Motor output organization. *J Neurophysiol* 1, 139.
- Summerfield, C., Junque, C., Tolosa, E., Salgado-Pineda, P., Gomez-Anson, B., Marti, M.J., Pastor, P., Ramirez-Ruiz, B., Mercader, J. (2005). Structural brain changes in Parkinson disease with dementia: a voxel-based morphometry study. *Arch Neurol* 2, 281-285.
- Talairach, J., Tournoux, P. (1988). *Co-planar stereotaxic atlas of the human brain*. ed. Talairach, J., Tournoux, P. New York: Thieme Medical.

- Tanji, J. (1996). New concepts of the supplementary motor area. *Curr Opin Neurobiol* 6, 782-787.
- Thaler, D., Chen, Y.C., Nixon, P.D., Stern, C.E., Passingham, R.E. (1995). The functions of the medial premotor cortex. I. Simple learned movements. *Exp Brain Res* 3, 445.
- Thobois, S., Jahanshahi, M., Pinto, S., Frackowiak, R., Limousin-Dowsey, P. (2004). PET and SPECT functional imaging studies in Parkinsonian syndromes: from the lesion to its consequences. *Neuroimage* 1, 1-16.
- Tolosa, E., Gaig, C., Santamaría, J., Compta, Y. (2009). Diagnosis and the premotor phase of Parkinson disease. *Neurology* 7 Supplement 2, S12-S20.
- Turner, R.S., Desmurget, M., Grethe, J., Crutcher, M.D., Grafton, S.T. (2003). Motor subcircuits mediating the control of movement extent and speed. *J Neurophysiol* 6, 3958-3966.
- Van Essen, D.C. (1997). A tension-based theory of morphogenesis and compact wiring in the central nervous system. *Nature* 23, 313-318.
- van Mier, H., Tempel, L.W., Perlmutter, J.S., Raichle, M.E., Petersen, S.E. (1998). Changes in Brain Activity During Motor Learning Measured With PET: Effects of Hand of Performance and Practice. *J Neurophysiol* 4, 2177-2199.
- von Campenhausen, S., Bornschein, B., Wick, R., Bötzel, K., Sampaio, C., Poewe, W., Oertel, W., Siebert, U., Berger, K., Dodel, R. (2005). Prevalence and incidence of Parkinson's disease in Europe. *Eur Neuropsychopharmacol* 4, 473-490.
- Vorobiev, V., Govoni, P., Rizzolatti, G., Matelli, M., Luppino, G. (1998). Parcellation of human mesial area 6: cytoarchitectonic evidence for three separate areas. *Eur J Neurosci* 6, 2199-2203.
- Walsh, V., Cowey, A. (2000). Transcranial magnetic stimulation and cognitive neuroscience. *Nat Rev Neurosci* 1, 73-80.
- Wang, Y., Shima, K., Sawamura, H., Tanji, J. (2001). Spatial distribution of cingulate cells projecting to the primary, supplementary, and pre-supplementary motor areas: a retrograde multiple labeling study in the macaque monkey. *Neurosci Res* 1, 39-49.
- Williams-Gray, C.H., Foltynie, T., Brayne, C.E.G., Robbins, T.W., Barker, R.A. (2007). Evolution of cognitive dysfunction in an incident Parkinson's disease cohort. *Brain* 7, 1787-1798.
- Wilson, S.A.K. (1925). The Croonian Lectures on some disorders of motility and of muscle tone, with special reference to the corpus striatum. *Lancet* 5315/7/8/9, 53-62, 169-178, 215-219, 268-276.
- Wu, T., Wang, L., Chen, Y., Zhao, C., Li, K., Chan, P. (2009). Changes of functional connectivity of the motor network in the resting state in Parkinson's disease. *Neurosci Lett* 1, 6-10.
- Wu, Y.R., Ashby, P., Lang, A.E. (2001). Orthostatic tremor arises from an oscillator in the posterior fossa. *Mov Disord* 2, 272-9.
- Yoshimura, N., Kawamura, M., Masaoka, Y., Homma, I. (2005). The amygdala of patients with Parkinson's disease is silent in response to fearful facial expressions. *Neuroscience* 2, 523-534.
- Zhang, Y., Brady, M., Smith, S. (2001). Segmentation of brain MR images through a hidden Markov random field model and the expectation-maximization algorithm. *IEEE Trans Med Imaging* 1, 45-57.

7.2 Informed consent, Information letter

Universitätsklinikum Schleswig – Holstein, Campus Kiel

KLINIK FÜR NEUROLOGIE

Direktor: Prof. Dr. G. Deuschl

Niemannsweg 147

24105 Kiel

Einverständniserklärung für gesunde Probanden

Titel der Studie: Einsatz der multifokalen transkraniellen Magnet-stimulation zur Charakterisierung „degenerierter“ motorischer und semantischer Repräsentationen im menschlichen Gehirn

Hiermit bestätige ich, dass ich die oben aufgeführten Fragen vollständig beantwortet habe und dass ich keinen Herzschrittmacher oder sonstige elektronischen Implantate trage. Ich bin heute von Dr. _____ über die Durchführung folgender Untersuchungen

- Transkranielle Magnetstimulation (TMS) der motorischen Gehirnrinde**
- Magnetresonanztomografie des Gehirns (MRT)**

aufgeklärt worden. Dabei konnte ich alle mir wichtig erscheinenden Fragen, insbesondere zu Risiken und Nebenwirkungen der Untersuchung, stellen. Ich habe keine weiteren Fragen, fühle mich ausreichend informiert. Ich nehme an der Studie „**Einsatz der multifokalen transkraniellen Magnet-stimulation zur Charakterisierung „degenerierter“ motorischer und semantischer Repräsentationen im menschlichen Gehirn**“ teil und bin mit den geplanten Untersuchungen und Interventionen einverstanden. Es ist mir bewußt, dass ich jederzeit mein Einverständnis zur Teilnahme an der Studie ohne Angabe von Gründen zurückziehen kann. Dies wird keine negativen Auswirkungen auf meine medizinische Betreuung haben.

Mit meiner Unterschrift erkläre ich mich damit einverstanden, dass die im Rahmen der Untersuchung erhobenen, im Aufklärungsprotokoll beschriebenen Daten aufgezeichnet und anonymisiert für die biomedizinische Forschung verwendet werden dürfen. Einer wissenschaftlichen Auswertung der anonymisierten Daten und einer möglichen Veröffentlichung stimme ich zu.

Unterschrift des Probanden

Unterschrift des untersuchenden Arztes

7.3 Acknowledgements

My most sincere thanks to Prof. em. Dr. Dr. h.c. Günther Deuschl, Director of the Neurology Clinic at the Universitätsklinikum Schleswig-Holstein, Campus Kiel, for giving me the opportunity to perform this study in his clinic. Thank you also to Prof. Dr. Sergiu Groppa for all the support, attention and guidance. Additionally, my most sincere thanks and gratitude to Prof. Dr. Hartwig Siebner for all his help during this research period.

Sincere thanks to my family (Teodor, Lilia and Ludmila Hanganu) and all my relatives for supporting me during my studies abroad and for all the good thoughts and wishes they sent.

My deepest appreciation and gratitude to the European Federation of Neurological Societies, the Deutsche Akademische Austausch Dienste and the Neurology Clinic Uni-Kiel for giving me the financial support during the studies.

Additional thanks to everyone who participated in our studies and who gave the opportunity for this research to happen.

7.4 Curriculum vitae

Alexandru Hanganu. Kishinau, Republic of Moldova.

Degrees:

- (1) Ph.D. in Neurology, Nicolae Testemitanu University, Kishinau, September 2012
- (2) Licence in Neurology, Nicolae Testemitanu University, Kishinau, September 2008
- (3) Medical Doctor (M.D.), Nicolae Testemitanu University, Kishinau, June 2005

Education

- 2012/07 – present Post-doctoral research at the Research Centre of the Montreal Geriatrics Institute, Montreal, Quebec, Canada.
- 2011/01 – /08 Research internship at the Functional Imaging laboratory of the Department of Neurology, Christian-Albrechts-University, Kiel, Germany.
- 2008/06 – 2009/06
- 2005/11 – 2008/05 Neurologist Physician Intern at the Neurology Ward of Nicolae Testemitanu University, Kishinau, Moldova.
- 1999/09 – 2005/06 Student, General Medicine, State Medical and Pharmaceutical University Nicolae Testemitanu, Kishinau, Moldova.

Professional experience

- 2011/10 – 2012/06 Scientific researcher at the Neurobiology and Medical Genetics Laboratory, Nicolae Testemitanu University, Kishinau, Moldova.
- 2011/01 – 2011/08 Doctorand at the Functional Imaging laboratory of the Department of Neurology, Christian-Albrechts-University, Kiel, Germany.
- 2010/02- 2010/12 Neurologist in the Emergency Department, Emergency Hospital, Kishinau, Moldova.
- 2008/11 – 2011/11 Doctorand (staff researcher) at the Neurobiology and Medical Genetics Laboratory, Nicolae Testemitanu University, Kishinau, Moldova.
- 2008/06 – 2009/06 Fellow at the Functional Imaging laboratory of the Department of Neurology, Christian-Albrechts-University, Kiel, Germany.
- 2005/11 – 2008/09 Neurologist Resident at the Neurology, Neurosurgery and Medical Genetics Department, Emergency Hospital and the Traumatology Hospital Toma Ciorba, Kishinau, Moldova.

Doctoral studies

- 2008/06 – present Functional Imaging laboratory, Department of Neurology, Christian-Albrechts-University, Kiel, Germany.
- Theme Functional and structural connectivity in the motor system in healthy people and in patients with Parkinson's disease
- Doktorvater/ Betreuer PD Dr. med Sergiu Groppa

Publications

Journals

3. Hanganu A., Bedetti C., Degroot C., Mejia-Constain B., Lafontaine A.L., Chouinard S., Monchi O. (2013) Mild cognitive impairment is linked with faster rate of cortical thinning in Parkinson's disease. *Brain*. doi: 10.1093/brain/awu036. PMID: 24613932
2. Hanganu A., Groppa S.A., Deuschl G., Siebner H., Möller F., Siniatchkin M., Stephani U., Groppa S. (2013) Cortical thickness changes associated with photoparoxysmal response. *Brain Topography*. doi: 10.1007/s10548-014-0353-y. PMID: 24487625.
1. Hanganu A., Bedetti C., Jubault T., Gagnon J.F., Mejia-Constain B., Degroot C., Lafontaine A.L., Chouinard S., Monchi O. (2013) Mild cognitive impairment in Parkinson's disease is associated with increased cortical degradation. *Movement Disorders*. doi: 10.1002/mds.25541. PMID: 23801590

Abstracts

5. Groppa S., Hanganu A., Bustorf T., Deuschl G., Siebner H. (2014) Connectivity between dorsal premotor and primary motor cortex in patients with Parkinson's disease. In: 20th Meeting of the Organization for Human Brain Mapping, Hamburg, Germany.
4. Hanganu A., Zeuner K., Paktas B., Deuschl G., Groppa S. (2014) Structural brain changes in patients with blepharospasm and hemifacial spasm. In: 20th Meeting of the Organization for Human Brain Mapping, Hamburg, Germany.
3. Groppa S., Ghobadi Z., Hanganu A., Siebner HR., Deuschl G. (2014) Ipsilateral connectivity between posterior parietal and primary motor cortex at high temporal resolution with dual-site TMS. In: 30th International Congress of Clinical Neurophysiology. Berlin. Germany.
2. Groppa S., Ghobadi Z., Hanganu A., Siebner H.R., Deuschl G. (2011) Probing ipsilateral connectivity between posterior parietal and primary motor cortex at high temporal resolution with dual-site TMS. In: 84. Kongress der Deutschen Gesellschaft für Neurologie mit Fortbildungsakademie. Hamburg, Germany.
1. Hanganu A, Siems C, Groppa SA, Groppa S, Siebner HR (2009) Combining transcranial direct current stimulation with „bursty” repetitive transcranial magnetic stimulation of the primary motor cortex: an electrophysiological study. In: European Journal of Neurology, Special Issue: Abstracts of the 13th Congress of the European Federation of Neurological Societies, Florence, Italy. Vol. 16, Suppl. 3, p. 422.