



Imaging in Suspected Renal Colic: Systematic Review of the Literature and Multispecialty Consensus

Christopher L. Moore, MD^a, Christopher R. Carpenter, MD, MSc^b, Marta E. Heilbrun, MD^c, Kevin Klauer, DO, EJD^{d,e,f}, Amy C. Krambeck, MD^g, Courtney Moreno, MD^c, Erick M. Remer, MD^b, Charles Scales, MD, MSHSⁱ, Melissa M. Shaw, BS^a, Kevan M. Sternberg, MD^j

Abstract

Background: Renal colic is common, and CT is frequently utilized when the diagnosis of kidney stones is suspected. CT is accurate but exposes patients to ionizing radiation and has not been shown to alter either interventional approaches or hospital admission rates. This multi-organizational transdisciplinary collaboration sought evidence-based, multispecialty consensus on optimal imaging across different clinical scenarios in patients with suspected renal colic in the acute setting.

Methods: In conjunction with the American College of Emergency Physicians (ACEP) eQual network, we formed a nine-member panel with three physician representatives each from ACEP, the ACR, and the American Urology Association. A systematic literature review was used as the basis for a three-step modified Delphi process to seek consensus on optimal imaging in 29 specific clinical scenarios.

Results: From an initial search yielding 6,337 records, there were 232 relevant articles of acceptable evidence quality to guide the literature summary. At the completion of the Delphi process consensus, agreement was rated as perfect in 15 (52%), excellent in 8 (28%), good in 3 (10%), and moderate in 3 (10%) of the 29 scenarios. There were no scenarios where at least moderate consensus was not reached. CT was recommended in 7 scenarios (24%), with ultrasound in 9 (31%) and no further imaging needed in 12 (45%).

Summary: Evidence and multispecialty consensus support ultrasound or no further imaging in specific clinical scenarios, with reduced-radiation dose CT to be employed when CT is needed in patients with suspected renal colic.

Key Words: CT, imaging, reduced radiation CT, renal colic, ultrasound

J Am Coll Radiol 2019;16:1132-1143.

This article is published in print and electronic format in the Journal of American College of Radiology, ©2019 by American College of Radiology; Annals of Emergency Medicine, American College of Emergency Physicians; and The Journal of Urology®, American Urological Association Education and Research, Inc.

This is an open access article under the CC BY-NC-ND license (<http://creativecommons.org/licenses/by-nc-nd/4.0/>).

^aDepartment of Emergency Medicine, Yale University School of Medicine, New Haven, Connecticut.

^bDepartment of Emergency Medicine, Washington University in Saint Louis, Saint Louis, Missouri.

^cDepartment of Radiology & Imaging Sciences, Emory University School of Medicine, Atlanta, Georgia.

^dEmergency Medicine, University of Tennessee, Chattanooga, Tennessee.

^eDepartment of Family Medicine, University of Tennessee, Knoxville, Tennessee.

^fDepartment of Osteopathic Specialties, Michigan State University, East Lansing, Michigan.

^gDepartment of Urology, Indiana University School of Medicine, Indianapolis, Indiana.

^hImaging Institute and Glickman Urological and Kidney Institute, Cleveland Clinic, Cleveland, Ohio.

ⁱDuke Clinical Research Institute and Department of Surgery (Urology), Duke University School of Medicine, Durham, North Carolina.

^jDepartment of Urology, University of Vermont Medical Center, Burlington, Vermont.

Corresponding author and reprints: Christopher L. Moore, MD, Yale University, School of Medicine, Emergency Medicine, 464 Congress Avenue, New Haven, CT 06519; e-mail: Chris.moore@yale.edu.

Christopher L. Moore, MD, declares grant funds from AHRQ and Philips Healthcare; nonfinancial support from BK Medical and GE Healthcare; ACEP consultant. Amy C. Krambeck, MD, declares consultant for Lumenis and Boston Scientific. Charles Scales, MD, MSHS, declares grant funds from NIDDK and Allena Pharmaceuticals. Melissa M. Shaw, BS, declares grant funds from AHRQ. Kevan M. Sternberg, MD, declares consultant for Bard Endourology. The other authors state that they have no conflict of interest related to the material discussed in this article.

BACKGROUND

There are over 2 million annual emergency department visits for suspected renal colic in the United States, and CT scanning is now performed in more than 90% of patients diagnosed with kidney stones [1,2]. Despite a dramatic increase in CT use for diagnosis over the last 2 decades, patient-centered outcomes such as admission and intervention do not seem to have been impacted [3,4]. In 2014, a multicenter prospective trial randomized patients with suspected renal colic to CT, radiology-performed ultrasound (RPUS), or point-of-care ultrasound (POCUS) and concluded that initial ultrasonography (either RPUS or POCUS) could lower radiation exposure without adversely affecting patient-centered outcomes [5]. Despite this evidence, recent data suggest that ultrasound is used in fewer than 7% of patients diagnosed with kidney stones, and CT use has continued to increase [1]. Similarly, although reduced-radiation dose CT (RDCT) is recommended for the evaluation of renal colic, RDCT use has increased only modestly in recent years and is used in fewer than 10% of patients diagnosed with kidney stones [6].

Renal colic is a self-limited condition in the majority of patients. However, CT can effectively guide therapy in the subset of patients requiring urologic intervention and can detect conditions with signs and symptoms that can mimic renal colic but require intervention (such as appendicitis). The perspective of the urologist considering surgical intervention may differ from that of the clinician initially evaluating and treating the patient (often an emergency physician). Deciding whether patients with suspected renal colic need imaging during the initial evaluation and, if so, what type is an area with wide practice variation [7]. Although guidelines on “appropriate use” have been developed, they tend to emphasize CT without providing guidance on optimal imaging or scenarios in which CT may not be needed [8-10].

We convened a multispecialty group with representation from national organizations including emergency medicine, urology, and radiology to perform a systematic literature review and seek consensus on imaging approaches in specific clinical scenarios in which renal colic was suspected, with an emphasis on situations in which CT may not be required.

METHODS

Formation of the Panel, Overview, Definitions, and Population, Intervention, Comparison, Outcome Question

This initiative was formed under the umbrella of the Emergency Quality Network (eQual; <https://www.acep.org/equal/>), a CMS-funded Support and Alignment

Network that is part of a Transforming Clinical Practice Initiative and administered through the American College of Emergency Physicians (ACEP). The eQual network nominated three emergency physician members (C.L.M., C.C., K.K.). The ACR and the American Urological Association (AUA) were contacted and provided three representative members from each society, thus forming a nine-member group that conducted this process (ACR: C.C.M., E.M.R., M.E.H.; AUA: A.K., K.M.S., C.S.). The panel initially defined terms and agreed upon a population, intervention, comparison, outcome (PICO) question. A systematic literature review was conducted followed by a consensus process for specific clinical scenarios.

Consensus definitions are included in [Appendix C](#). The “optimal diagnostic imaging strategy” was defined as the imaging approach that would maximize patient-centered outcomes: guiding appropriate management while minimizing harms. “Uncomplicated renal colic” was considered to be renal colic without suspicion of infection (based on urinalysis or systemic symptoms such as fever). Cost of imaging was specifically excluded. Improving certainty of diagnosis without an impact on patient care was not considered patient centered. RDCT was not specified as having a specific dose cutoff but defined as a CT protocol that was specifically tailored to imaging renal colic with lower radiation dose parameters. POCUS was differentiated from RPUS in that it was expected to provide information about the presence or absence of hydronephrosis but would not be uniformly expected to identify stone size or location, and RPUS might (but would not always) be able to determine stone size or location. It is noted that the availability, skill set, and use patterns of POCUS may differ between institutions and even between individuals at an institution. Although we attempted to suggest when POCUS might be most appropriate, RPUS may be substituted if more appropriate.

The overall PICO question arrived at by the group was: “In patients presenting to the emergency department with pain suspected to be uncomplicated renal colic (P) what imaging (I) should be pursued compared to standard non-contrast computed tomography (CT) scanning (C) to optimize patient-centered outcomes (O)?” From the specific questions submitted by members of the group, three subthemes emerged: imaging in first-time renal colic, imaging in recurrent renal colic, and special populations (pregnancy, pediatric, obese patients).

Literature Review

A systematic literature review was performed following the Preferred Reporting Items for Systematic reviews and

Table 1. Clinical vignettes with level of agreement and imaging modality (after third round of voting)

Vignettes	Agreement	Answers
1. A 35-year-old man with two prior kidney stones that passed spontaneously presents with an acute onset flank pain over the last 3 hours. He reports nausea with vomiting and has hematuria on urine dip. He has no abdominal tenderness. His pain is relieved after intravenous analgesics.	Moderate	5 POCUS, 4 No Imaging
2. A 55-year-old man with two prior kidney stones that passed spontaneously presents with an acute onset of flank pain over the last 3 hours. He reports nausea with vomiting and has hematuria on urine dip. He has no abdominal tenderness. His pain is relieved after intravenous analgesics.	Moderate	5 No Imaging, 4 POCUS
3. A 75-year-old man with two prior kidney stones that passed spontaneously presents with an acute onset of flank pain over the last 3 hours. He reports nausea with vomiting and has hematuria on urine dip. He has no abdominal tenderness. His pain is relieved after intravenous analgesics.	Good	7 RDCT, 2 US (1 POCUS, 1 RPUS)
4. A 35-year-old man with no prior history of kidney stones presents with an acute onset of flank pain over the last 3 hours. He reports nausea with vomiting and has hematuria on urine dip. He has no abdominal tenderness. His pain is relieved after intravenous analgesics.	Perfect	9 POCUS
5. A 55-year-old man with no prior history of kidney stones presents with an acute onset of flank pain over the last 3 hours. He reports nausea with vomiting and has hematuria on urine dip. He has no abdominal tenderness. His pain is relieved after intravenous analgesics.	Excellent	8 RDCT, 1 POCUS
6. A 75-year-old man with no prior history of kidney stones presents with an acute onset of flank pain over the last 3 hours. He reports nausea with vomiting and has hematuria on urine dip. He has no abdominal tenderness. His pain is relieved after intravenous analgesics.	Perfect	9 RDCT
7. A 35-year-old man with two prior kidney stones that passed spontaneously presents with an acute onset of flank pain over the last 3 hours. He reports nausea with vomiting and has hematuria on urine dip. He has no abdominal tenderness. His pain is relieved after intravenous analgesics. An ultrasound is performed; there is hydronephrosis on the side of the pain, and a stone is not visualized.	Perfect	9 No Imaging
8. A 35-year-old man with two prior kidney stones that passed spontaneously presents with an acute onset of flank pain over the last 3 hours. He reports nausea with vomiting and has hematuria on urine dip. He has no abdominal tenderness. His pain is relieved after intravenous analgesics. An ultrasound is performed; there is no hydronephrosis, and a stone is not visualized.	Perfect	9 No Imaging
9. A 35-year-old man with no prior history of kidney stones presents with an acute onset of flank pain over the last 3 hours. He reports nausea with vomiting and has hematuria on urine dip. He has no abdominal tenderness. His pain is not relieved after intravenous analgesics.	Perfect	9 RDCT
10. A 35-year-old man with no prior history of kidney stones presents with an acute onset of flank pain over the last 3 hours. He reports nausea with vomiting and has hematuria on urine dip. He has no abdominal tenderness. His pain is relieved after intravenous analgesics. An ultrasound is performed; there is hydronephrosis on the side of the pain, and a stone is not visualized.	Excellent	8 No Imaging, 1 RDCT
11. A 35-year-old man with no prior history of kidney stones presents with an acute onset of flank pain over the last 3 hours. He reports nausea with vomiting and has hematuria on urine dip. He has no abdominal tenderness. His pain is relieved after intravenous analgesics. An ultrasound is performed; there is no hydronephrosis, and a stone is not visualized.	Excellent	8 No Imaging, 1 RDCT
12. A 35-year-old woman with no prior history of kidney stones presents with an acute onset of flank pain over the last 3 hours. She reports nausea with vomiting and has hematuria on urine dip. She has no abdominal tenderness. Her pain is relieved after intravenous analgesics.	Excellent	8 US (6 POCUS, 2 RPUS), 1 RDCT

(continued)

Table 1. Continued

Vignettes	Agreement	Answers
13. A 35-year-old man with two prior kidney stones that passed spontaneously presents with left flank pain over the last 2 days. He reports nausea but no vomiting and has hematuria on urine dip. He has some left lower quadrant abdominal tenderness. His pain is relieved after intravenous analgesics.	Good	7 POCUS, 2 RDCT
14. A 35-year-old man with two prior kidney stones that passed spontaneously presents with left flank pain over the last 2 days. He reports nausea but no vomiting and has hematuria on urine dip. He has some left lower quadrant abdominal tenderness. His pain is relieved after intravenous analgesics. An ultrasound is performed; there is hydronephrosis on the side of the pain, and a stone is not visualized.	Excellent	8 No Imaging, 1 RDCT
15. A 35-year-old man with two prior kidney stones that passed spontaneously presents with left flank pain over the last 2 days. He reports nausea but no vomiting and has hematuria on urine dip. He has some left lower quadrant abdominal tenderness. His pain is relieved after intravenous analgesics. An ultrasound is performed; there is no hydronephrosis, and a stone is not visualized.	Moderate	5 No Imaging, 4 RDCT
16. A 35-year-old man with no prior history of kidney stones presents with left flank pain over the last 2 days. He reports nausea but no vomiting and has hematuria on urine dip. He has some left lower quadrant abdominal tenderness. His pain is relieved after intravenous analgesics.	Excellent	8 RDCT, 1 POCUS
17. A 55-year-old man with no prior history of kidney stones presents with left flank pain over the last 2 days. He reports nausea but no vomiting and has hematuria on urine dip. He has some left lower quadrant abdominal tenderness. His pain is relieved after intravenous analgesics.	Perfect	9 CT (7 RDCT, 1 NCCT, 1 CT IV CON)
18. A 75-year-old man with no prior history of kidney stones presents with left flank pain over the last 2 days. He reports nausea but no vomiting and has hematuria on urine dip. He has some left lower quadrant abdominal tenderness. His pain is relieved after intravenous analgesics.	Perfect	9 CT (5 NCCT, 4 CT IVCON)
19. A 35-year-old woman who is 10 weeks pregnant with no prior history of kidney stones presents with an acute onset of right flank pain over the last 3 hours. She reports nausea with vomiting and has hematuria on urine dip. She has no abdominal tenderness. Her pain is relieved after intravenous analgesics.	Perfect	9 US (8 RPUS, 1 POCUS)
20. A 35-year-old woman who is 10 weeks pregnant with no prior history of kidney stones presents with acute onset right flank pain over the last 3 hours. She reports nausea with vomiting and has hematuria on urine dip. She has no abdominal tenderness. Her pain is relieved after intravenous analgesics. An ultrasound is performed; there is hydronephrosis on the side of the pain, and a stone is not visualized.	Perfect	9 No Imaging
21. A 35-year-old woman who is 10 weeks pregnant with no prior history of kidney stones presents with an acute onset of right flank pain over the last 3 hours. She reports nausea with vomiting and has hematuria on urine dip. She has no abdominal tenderness. Her pain is relieved after intravenous analgesics. An ultrasound is performed; there is no hydronephrosis, and a stone is not visualized.	Excellent	8 No Imaging, 1 RPUS
22. A 35-year-old woman who is 30 weeks pregnant with no prior history of kidney stones presents with an acute onset of right flank pain over the last 3 hours. She reports nausea with vomiting and has hematuria on urine dip. She has no abdominal tenderness. Her pain is relieved after intravenous analgesics.	Perfect	9 US (8 RPUS, 1 POCUS)
23. A 35-year-old woman who is 30 weeks pregnant with no prior history of kidney stones presents with an acute onset of right flank pain over the last 3 hours. She reports nausea with vomiting and has hematuria on urine dip. She has no abdominal tenderness. Her pain is relieved after intravenous analgesics. An ultrasound is performed; there is hydronephrosis on the side of the pain, and a stone is not visualized.	Perfect	9 No Imaging

(continued)

Table 1. Continued

Vignettes	Agreement	Answers
24. A 35-year-old man was seen in the ED the previous day with an acute onset of right flank pain, and a CT was performed that showed a 4-mm stone in the proximal right ureter with some hydronephrosis. He presents today with recurrent, severe right flank pain.	Perfect	9 No Imaging
25. A 12-year-old boy with no prior history of kidney stones presents with an acute onset of flank pain over the last 3 hours. He reports nausea with vomiting and has hematuria on urine dip. He has no abdominal tenderness. His pain is relieved after intravenous analgesics.	Perfect	9 US (7 RPUS, 2 POCUS)
26. A 12-year-old boy with no prior history of kidney stones presents with an acute onset of flank pain over the last 3 hours. He reports nausea with vomiting and has hematuria on urine dip. He has no abdominal tenderness. His pain is relieved after intravenous analgesics. An ultrasound is performed; there is hydronephrosis on the side of the pain, and a stone is not visualized.	Perfect	9 No Imaging
27. A 12-year-old boy with no prior history of kidney stones presents with an acute onset of flank pain over the last 3 hours. He reports nausea with vomiting and has hematuria on urine dip. He has no abdominal tenderness. His pain is relieved after intravenous analgesics. An ultrasound is performed; there is no hydronephrosis, and a stone is not visualized.	Excellent	8 No Imaging, 1 RDCT
28. A 35-year-old man with kidney stones who underwent shock wave lithotripsy without stent placement 2 days ago presents with an acute onset of flank pain over the last 3 hours. He reports nausea with vomiting and has hematuria on urine dip. He has no abdominal tenderness. His pain is relieved after intravenous analgesics.	Good	7 US (6 RPUS, 1 POCUS) 2 RDCT
29. A 35-year-old man with a 6-mm left ureteral stone diagnosed by CT underwent stent placement yesterday. He presents with left flank and suprapubic pain worsening for the past 24 hours. He has some nausea without vomiting. He has microscopic hematuria, but no abdominal tenderness. His pain is relieved after intravenous analgesics.	Perfect	9 POCUS

Authors were given the following instructions, based on consensus definitions (Appendix C): “For each of the brief clinical vignettes below, please select the imaging test that you believe would represent the best next imaging test (if any) in an *optimal diagnostic imaging strategy*, as defined below. In each case you can assume the patient is otherwise healthy without significant past medical history (in particular no renal insufficiency, solitary kidney, or transplant) and that there are no signs of infection (history or documented fever; leukocytes/bacteria in urine).” Authors could indicate “No (further) imaging.” CT IVCON = IV contrast-enhanced CT; ED = emergency department; NCCT = standard noncontrast CT; POCUS = point-of-care ultrasound; RDCT = Reduced-radiation dose CT; RPUS = radiology-performed ultrasound.

Meta-Analyses (PRISMA) guidelines. National Library of Medicine, PubMed, and Embase databases were queried for English language articles published between January 1995 and May 2018 using a search strategy that included medical subject headings as well as keywords (Appendix A). To ensure key articles were not missed, each group member provided six articles from their personal libraries (blinded to the search), which were then crossmatched against search results. Articles were reviewed for relevance to the PICO question as level I (definitely relevant), II (probably relevant), or X (not relevant). Interobserver reliability for relevance between nonphysician reviewers and each of the nine physician authors was measured using a random selection of 45 included and 45 excluded articles that were blindly reviewed (10 articles per author).

Relevant articles were rated for quality of evidence using a hybrid of two evidence based tools: Quality

Assessment Tool for Diagnostic Accuracy Studies-2 (QUADAS-2) with the ACEP Clinical Policy Committee criteria for diagnostic questions. This hybrid tool rated evidence as I, II, III, or X (Appendix B) [11,12]. Some articles were not felt to be amenable to rating by this tool for diagnostic accuracy studies (epidemiologic and systematic meta-analyses) but were included after review by the group (evidence level not applicable). Thirty-two randomly selected articles were reviewed by each physician member of the group using this instrument. Discrepancies were discussed on weekly conference calls until the group reached consensus. This was used to help guide the two nonphysician reviewers who then assessed the remaining articles independently for evidence level. This evidence was synthesized by the group into a review of principal imaging modalities, which formed the basis for the consensus discussion.

Consensus on Clinical Scenarios

After the systematic literature review, discussion, and a written summary of the literature for imaging modalities, we attempted to define specific clinical scenarios in which consensus could be reached regarding the optimal initial imaging, including scenarios in which CT may not be the optimal initial approach. A set of 29 brief clinical vignettes were agreed upon that were felt to represent the best balance between overall number of scenarios and possible permutations (age, gender, pregnancy status, likelihood of stone disease, likelihood of acute alternative diagnosis; Table 1). Consensus was sought using a modified Delphi process that included three rounds of anonymous voting with two group discussions between rounds of voting. All nine members of the group answered the vignettes in a blinded fashion individually for the first round.

For each clinical scenario, the physician was asked to select the “optimal diagnostic imaging strategy” using a priori definitions. Imaging options included no (further) imaging, POCUS, RPUS, RDCT, standard CT (non-contrast), and CT with IV contrast. For purposes of defining consensus, imaging modalities were separated into three groups: no further imaging, ultrasound, and CT, although subtypes within imaging modalities are reported. A priori, consensus was defined as “perfect” (nine of nine), “excellent” (eight of nine), “good” (six to seven of nine), “moderate” (five of nine), and “not reached” (less than five of nine).

After the first round of voting, a focused group discussion occurred in which voting results from round 1 were anonymously shared with all members. Questions in which perfect consensus was reached were not revoted on in the next round. After the second round of voting, this process was repeated to reach a final level of consensus, with group discussion and opportunity to revise imaging choice between the second and third round.

RESULTS

Literature Review

For the literature review, of 6,337 publications screened, 232 were deemed relevant with acceptable methodology (PRISMA flow diagram, Fig 1; full citation list Appendix D). Of key articles provided by authors blinded to the search results, 100% (95% confidence interval [CI] 93%-100%) were identified, indicating excellent capture of relevant articles. Interobserver agreement for inclusion and exclusion yielded a κ of 0.45 (95% CI 0.26-0.63)

indicating moderate (range of fair to good) agreement. Notably only 10% (nine articles) considered relevant by the nonphysician reviewers were rated as not relevant by the blinded reviewers, favoring inclusion when there was disagreement. Abbreviated review of the literature for the main imaging modalities (RPUS, POCUS, standard CT, and RDCT) that were used as the basis for the discussion and the consensus process follows.

Ultrasound: RPUS and POCUS. For RPUS, there were 43 relevant articles with grades of evidence I ($n = 3$), II ($n = 17$), III ($n = 20$), and not applicable ($n = 3$). Reported sensitivity of RPUS for kidney stones varied widely, ranging from 3% to 98% depending on whether direct stone visualization was required or if indirect evidence of stone presence such as hydronephrosis was sufficient [13,14]. The preponderance of studies reported sensitivities from 57% to 91%, with improved sensitivity when twinkling artifact is used to help identify stones [15-18]. RPUS may be particularly helpful in younger patients with lower body mass index, with sensitivities as high as 96% in patients under age 35 [19]. Although RPUS is imperfectly sensitive for detection of stones when compared with CT, this difference may not be clinically significant. Several studies show that RPUS is unlikely to miss stones requiring intervention [20-22].

There were 15 articles relevant to the use of POCUS for renal colic with evidence grades of evidence I ($n = 4$), II ($n = 8$), III ($n = 2$), and not applicable ($n = 1$). A systematic review and meta-analysis of POCUS completed in 2018 identified five high-quality articles on diagnostic accuracy and six on prognostic value, all of which were identified in our literature review [23]. Diagnostic accuracy was based on presence of hydronephrosis rather than direct visualization of stones, and pooled results yielded sensitivity of 70.2% and specificity of 75.4%, although specificity increased to 94.4% when moderate or greater hydronephrosis was used as a criterion [24,25]. Four studies did show a positive association between stone size, and larger stones had a higher likelihood of intervention when hydronephrosis was present [24,26-28].

A multicenter, pragmatic, comparative effectiveness trial published in 2014 randomized over 2,500 patients with suspected kidney stones to POCUS, RPUS, or CT and concluded that ultrasound (RPUS or POCUS) is a safe approach for the evaluation of ureterolithiasis, noting that “return emergency department visits, hospitalizations, and diagnostic accuracy did not differ significantly

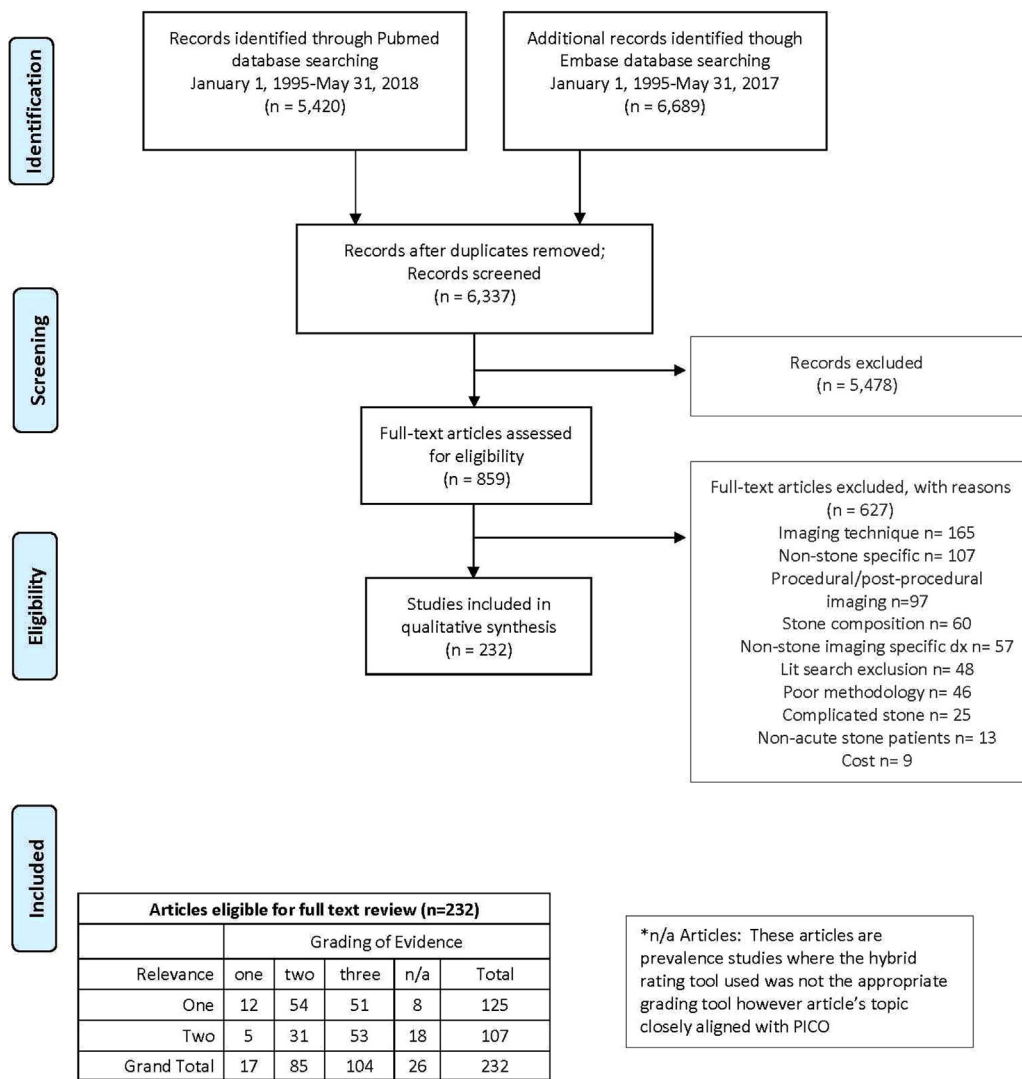


Fig 1. Preferred Reporting Items for Systematic reviews and Meta-Analyses (PRISMA) 2009 flow diagram and evidence grading. PICO = population, intervention, comparison, outcome. From Moher D, Liberati A, Tetzlaff J, Altman DG, The PRISMA Group 2009. Preferred reporting items for systematic reviews and meta-analyses: The PRISMA statement PLoS Med 6(7): e1000097, doi:10.1371/journal.pmed1000097.

among the groups” [5]. RPUS when compared with POCUS was less likely to result in subsequent CT (27% with RPUS versus 41% with POCUS) [5,29]. The study showed a small but significant longer length of emergency department stay for RPUS than either the POCUS or CT groups (7.0 hours versus 6.3 and 6.4 hours, respectively) [5].

Standard CT. CT is accepted as the reference modality for diagnosis of kidney stones, and our group did not seek to review the literature on overall accuracy of CT for kidney stones; rather, we sought to understand how often CT identified other pathologies and how CT affected management. There were 36 relevant articles

addressing alternative findings on CT with grades of I (n = 3), II (n = 9), III (n = 20), and not applicable (n = 4) (Table 2). The prevalence of alternate findings ranged from 0% to 33%; however, definitions of acute alternate diagnoses varied widely. Before completing the literature review, our group established definitions (Appendix C) including “acute alternative diagnosis” (requiring a therapeutic intervention, such as appendicitis), “nonacute alternative diagnosis” (causing symptoms but not requiring intervention, such as mesenteric adenitis), and true “incidental findings” (identified as needing follow-up but not related to presenting symptoms). Incorporating these definitions, the prevalence of alternate findings in suspected renal

Table 2. Relevant studies reporting an alternate diagnosis on CT for renal colic, listed alphabetically by last name of first author, with year, study type, ratings of relevance and evidence, overall number of patients, prevalence (%) of renal stone by imaging, and reported prevalence of alternate findings

Year	Author	Study Type	Relevance	Evidence	n	Prevalence of Stone (%)	Alternate Findings (%)
2000	Abramson et al	P	2	3	93	60	18.0
2003	Ahmad et al	R	1	3	233	64	12.0
2006	Akay et al	R	1	2	87	54	16.1
2013	Arif et al	P	1	2	124	69	8.1
2009	Ather et al	R	2	3	4,000	78	9.9
2010	Ben Nakhi et al	P	2	3	36	31	11.1
2016	Blecher et al	R	1	n/a	626	58	9.2
2007	Broder et al	R	1	2	356	58	2.0
2002	Catalano et al	P	1	2	181	51	14.0
2008	Cullen et al	R	2	3	500	56	13.0
1999	Dorio et al	R	1	3	163	66	7.0
2013	Dyer et al	R	1	3	228	34	27.0
2002	Eshed et al	P	1	3	425	59	10.0
2010	Goldstone et al	R	2	3	231	64	3.5
2004	Ha et al	P	1	3	132	58	33.0
2015	Hall et al	R	2	3	513	45	14.0
2001	Hamm et al	P	1	3	125	73	3.2
2001	Homer et al	P	1	3	228	70	5.7
2006	Hoppe et al	R	2	n/a	1,500	69	14.0
2000	Katz et al	R	2	3	1,000	56	10.1
2012	Khan et al	R	2	3	899	NR	14.0
2003	Kobayashi et al	P	2	2	560	60	2.5
2001	Messersmith et al	R	2	n/a	21	NR	19.0
2014	Moore et al	R	2	1	1,040	50	2.9
2013	Moore et al	R	1	2	5,383	48	2.8
2015	Pernet et al	P	1	3	155	76	6.0
2006	Rafique et al	P	1	3	130	47	23.0
2016	Sarofim et al	R	1	2	215	38	7.0
2015	Schoenfeld et al	R	1	2	291	59	0.0
1999	Sheley et al	R	2	2	180	46	3.0
1996	Smith et al	P	1	3	210	50	14.8
2014	Smith-Bindman et al	P	1	1	926	33	0.2
2002	Strouse et al	R	2	n/a	94	40	29.0
1998	Vieweg et al	P	1	2	105	47	27.6
2008	Xafis et al	R	2	3	638	79	5.0

Please see [Appendix D](#) for full references. Note that the definition of “alternate findings” was typically different than the consensus definition of “acute alternative diagnoses,” often including incidental findings and nonacute alternative diagnoses. n/a = not available; NR = not reported; P = prospective; R = retrospective.

colic that could be considered acute or clinically important is substantially lower than often reported, typically less than 5%. In the largest prospective study of patients with suspected renal colic (including 2,759 patients randomized to CT or ultrasound as an initial diagnostic test), 4.9% had an “important alternative diagnosis” [30]. The largest prospective study to randomize patients to CT or ultrasound found no significant difference in high-risk diagnoses or adverse events based on initial imaging modality. Notably,

this study had a very low rate (0.4%) of high-risk diagnoses [5].

Few studies have separated incidental findings from alternate causes of symptoms. A study of over 5,000 patients that used a strict definition of incidental findings (requiring follow-up but not causative of symptoms) identified incidental findings in 12.7% of CTs performed for renal colic [31]. Although incidental findings may occasionally lead to earlier diagnosis and treatment of pathology (typically malignancy), in many cases, these

findings may lead to unnecessary workup and even potential morbidity [32].

CT may be performed after initial ultrasound imaging if nondefinitive. In the previously cited large randomized pragmatic trial, between 27% of patients with RPUS and 41% with POCUS had a subsequent CT [5]. A single-center experience found that although about one-half of patients evaluated for stone disease underwent CT on initial evaluation, only 10% of those not undergoing CT had it done later in the episode of evaluation and treatment, with 20% of those undergoing initial ultrasound having a CT performed later. They found overall imaging costs and radiation exposure to be higher in patients undergoing initial CT [33]. Delayed versus immediate CT does not seem to impact morbidity [34].

Despite the potential for CT to predict need for intervention, population-based studies have shown little change in rates of admission or intervention with increasing CT use [3,4]. A 2002 study that prospectively compared CT to the combination of an abdominopelvic radiograph plus ultrasound found a higher sensitivity for CT but that the increased sensitivity “did not result in a change in treatment.” The study concluded that “primary CT causes an overevaluation of these patients with minor colic . . . both diagnostic accuracy and patient treatment will be unchanged” [35]. A secondary analysis of the large prospective multicenter randomized trial comparing ultrasound to CT as an initial imaging modality found that there was no significant difference between timing of urologic intervention based on the initial imaging modality [29].

RDCT. Although there is controversy around risk of radiation from CT, most practitioners, radiologists, and organizations continue to adhere to the “as low as reasonably achievable” principle for radiation levels in diagnostic imaging. Statements from ACEP, ACR, and AUA recommend using RDCT [8,22,36]. Despite these recommendations, in 2011 to 2012 only 2% of studies for suspected renal colic were performed with an RDCT technique, and as of 2015 to 2016, this percentage had risen to only 8% [37]. There were 50 relevant articles on RDCT with evidence level I (n = 9), II (n = 27), III (n = 10), and not applicable (n = 4). The definition of RDCT in the literature is variable. The consensus definition of RDCT by this group did not involve a specific numeric cutoff; rather, it is defined as a protocol that is specific for detection of renal colic and utilizes lower radiation settings than an undifferentiated CT of the abdomen and pelvis at

the same institution. It is important to understand that because of their high attenuation, kidney stones can be detected using lower radiation levels. Many institutions simply perform the same CT that they would on an undifferentiated abdominal pain but just without contrast. This misses an opportunity to lower dose further, particularly when kidney stones are likely and alternative diagnoses unlikely [38]. This group specifically defines RDCT as “a CT protocol specific to renal colic that has radiation dose parameters that are lower than an undifferentiated CT abdomen/pelvis at the institution.”

The literature supports the diagnostic accuracy of RDCT compared with standard CT. For ureteral stone identification, sensitivities of RDCT range from 90% to 95% and specificities from 97% to 99% [39]. RDCT is particularly sensitive for larger stones that are more likely to require intervention [40,41]. RDCT is sufficiently sensitive and specific for alternate diagnoses [38,40,42]. Although some guidelines include a body mass index cutoff for use of RDCT, the literature suggests that although CT settings may need to be adjusted, diagnostic accuracy can be maintained in obese patients using RDCT techniques [10,42-43]. Using a definition of RDCT that does not involve a specific cutoff but rather a dedicated protocol and using lower radiation (as suggested by our group) should be considered in patients with high body mass index.

Consensus Results. The level of consensus by round of voting as well as proportions of imaging modalities recommended are shown in Table 3. By the final round of voting, the group was able to reach perfect consensus in 15 of 29 vignettes (45%), with at least moderate consensus in all scenarios. CT continued to be recommended in 7 of 29 (24%) scenarios. All vignettes

Table 3. Consensus level and imaging modality by round in the modified Delphi process. The number and percent of vignettes (out of 29 total) are shown

Consensus Level	Round 1	Round 2	Round 3
Perfect	6 (21%)	12 (29%)	15 (52%)
Excellent	3 (10%)	6 (21%)	8 (28%)
Good	11 (38%)	6 (21%)	3 (10%)
Moderate	7 (24%)	4 (14%)	3 (10%)
Not reached	2 (7%)	1 (3%)	0 (0%)
No imaging	13 (45%)	13 (45%)	13 (45%)
Ultrasound	7 (24%)	7 (24%)	9 (31%)
CT	7 (24%)	8 (28%)	7 (24%)
No consensus	2 (7%)	1 (3%)	0 (0%)

along with final level of consensus and voting by modality are shown in [Table 1](#).

DISCUSSION

To our knowledge, this article presents the first systematic, multispecialty, evidence-based consensus regarding imaging in renal colic. The evidence suggests that in many cases, ultrasound, either radiology performed or point-of-care, may provide adequate diagnostic information to guide initial treatment. When CT is needed, a reduced radiation approach should be used. Our recommendations are in line with ACR Appropriateness Criteria, which suggest that CT is “usually appropriate” and ultrasound “may be appropriate” for acute onset of flank pain but provide further clarification on when approaches such as ultrasound may be more optimal [8].

We were able to reach at least moderate consensus in all scenarios. Question (Q) 1 is the “base-case” scenario: a 35-year-old man with a prior history of kidney stones who presents with typical symptoms and adequate pain relief. No respondents favored initial CT in this patient. Although five recommended POCUS, there was perfect consensus that no additional imaging was needed regardless of the presence or absence of hydronephrosis after POCUS was performed (Q7, Q8).

In the same scenario but without prior history of stones (Q4), there was perfect consensus for POCUS as the initial imaging modality, with excellent agreement for no additional imaging regardless of POCUS result (Q10, Q11). It could be argued that if the next step regardless of the result of the POCUS (hydronephrosis or no hydronephrosis) is no further imaging, then POCUS is not needed. In group discussion, respondents felt that even if the POCUS result did not influence the decision to obtain a subsequent CT, it could provide a baseline for the patient in case he returned, as well as providing some information regarding prognosis and likelihood of spontaneous stone passage.

One respondent recommended RDCT regardless of POCUS result in the scenario when the patient had no prior history of stones (Q4). This respondent was an emergency physician, and this response is highlighted because it is in line with a common teaching in emergency medicine that “every first-time stone requires a CT.” However, eight of the nine members of the group (including all three urologists) did not feel a CT was required in this young patient with typical symptoms and relief of pain even if it was a first-time stone.

When the clinical presentation of the case was less typical in a patient with a prior history of stones (Q13), there was still good consensus that ultrasound would be the best initial modality, though more respondents (two of nine) favored CT. This suggests that as the presentation becomes less typical, CT is favored. Performance of POCUS in a patient with less typical symptoms (Q14, Q15) did alter the recommendation for subsequent CT. Although there was still moderate consensus for no further imaging in a young patient with atypical symptoms and no hydronephrosis (five of nine, Q15), the absence of hydronephrosis on POCUS led four of nine respondents to recommend RDCT. This is in line with literature to suggest that POCUS may be most helpful in patients who have a moderate likelihood of stones, with presence of hydronephrosis suggesting stones and no need for further imaging, and absence of hydronephrosis suggests that an alternate diagnosis should be considered [24].

Q2 and Q3, Q5 and Q6, and Q17 and Q18 included identical scenarios to Q1, Q4, and Q16 with ages altered to 55 and 75 years old. For age 75, regardless of prior history of stones or presentation, there was good to perfect consensus that CT should be obtained, with RDCT favored (Q3, Q6, Q18). For age 55, when there was a history of a prior kidney stone and a typical presentation (Q2), there was moderate consensus (five of nine) for no imaging with the remainder (four of nine) recommending POCUS. For a 55-year-old with no prior history of kidney stones, there was perfect consensus that RDCT should be obtained (Q4), with perfect consensus that CT be obtained with a less typical presentation (Q17).

When the base case was varied to the female gender in a young patient with no prior history of stones (Q12), there was excellent consensus for ultrasound (eight of nine), with six respondents recommending POCUS. Notably, two respondents chose RPUS (versus none with the male), which would be reasonable, particularly if radiology ultrasound was definitive for stone size and location, allowing for avoidance of CT. RPUS may also be diagnostic of pelvic or adnexal pathology that could be present acutely in a female patient.

It should be noted that even in a young patient with a prior history of stones, if symptoms cannot be appropriately relieved, RDCT was recommended with perfect consensus (Q9). What might constitute adequate relief of symptoms is a somewhat subjective determination. It is also acknowledged that attempting to achieve analgesia requires at least a short period of observation before deciding on imaging, but in many cases, a single dose of an intravenous nonsteroidal (such as ketorolac) with or

without an opioid may achieve adequate analgesia. It is recommended that analgesia be attempted before decision to obtain a CT examination. It is also acknowledged that if adequate analgesia cannot be obtained, RDCT may identify a stone requiring intervention.

There was excellent consensus that in a pregnant patient with typical symptoms RPUS was the preferred test (Q19 and Q22). Regardless of presence of hydronephrosis on ultrasound (Q21 and Q23), no respondents recommended CT as long as symptoms were relieved. Similarly, in pediatric patients (Q25-Q27), there was perfect consensus that ultrasound was the favored initial modality, with RPUS favored (seven of nine, Q25). In pediatric patients with a typical presentation in whom pain was relieved, there was excellent to perfect consensus that CT was not needed regardless of the presence or absence of hydronephrosis if symptoms were relieved.

There was perfect consensus that in a patient with stent placement for kidney stones POCUS was the preferred test (Q29). The presence of hydronephrosis suggests a nonfunctioning stent, and in the absence of hydronephrosis with adequate pain control, the patient could be discharged without further imaging. For a patient with pain after lithotripsy, there was good consensus that ultrasound should be performed, with five respondents favoring RPUS. It was noted by the urologists that RPUS would be more likely to identify a post-procedural hematoma, favoring RPUS over POCUS.

If CT is not initially performed, it is expected that some patients will require subsequent CT if they are in the minority of patients with a stone that does not pass spontaneously. This should be explained to patients before discharge (suggested follow-up instructions are presented in [Appendix E](#)).

Limitations

There could be nearly unlimited permutations of the clinical presentation described in the vignettes. Twenty-nine questions were included because it was felt to be the best balance of major factors with the number of questions the group felt was within a reasonable scope to address. However, not all clinical scenarios were included. For example, gender was only varied in one question (Q12 versus Q4), and there was not a lot of variation in the answers by gender, although it may be more reasonable to forego CT in a female than a male patient (slightly more risk of radiation and somewhat higher likelihood of finding an alternative diagnosis in the pelvis or adnexa) with ultrasound.

SUMMARY

Based on systematic literature review with a strength of evidence rating and consensus determination by a modified Delphi method, our recommendations are that CT may be avoided in many common clinical scenarios when uncomplicated renal colic is suspected, as summarized in the Take-Home Points.

TAKE-HOME POINTS

- For suspected uncomplicated kidney stones and adequate pain relief, even without prior history of kidney stones, CT can be avoided in younger patients (~35 years old) with a presentation typical for kidney stones.
- In middle-aged patients (~55 years old), CT may be avoided if there is a prior history of kidney stones.
- In older patients (~75 years old), CT should generally be obtained.
- POCUS may help guide clinical suspicion and need for further imaging in patients with less typical signs and symptoms.
- Pregnant and pediatric patients should have RPUS as the initial imaging modality.

ACKNOWLEDGMENTS

This work was supported by the Agency for Healthcare Research and Quality (AHRQ) grant R18HS023778. The authors would like to acknowledge the support of the American College of Emergency Physicians, specifically Drs Jeremiah Schuur and Arjun Venkatesh, PIs for the ACEP eQual initiative.

ADDITIONAL RESOURCES

Additional resources can be found online at: <https://doi.org/10.1016/j.jacr.2019.04.004>.

REFERENCES

1. Chang H, Dai J, Holt S, Sorensen M, Sternberg K, Harper J. National imaging trends for acute kidney stone disease: do renal ultrasounds for nephrolithiasis in the emergency department pave the way to computerized tomography? *J Urol* 2018;199:e683-4.
2. Fwu C-W, Eggers PW, Kimmel PL, Kusek JW, Kirkali Z. Emergency department visits, use of imaging, and drugs for urolithiasis have increased in the United States. *Kidney Int* 2013;83:479-86.
3. Gottlieb RH, Erturk EN, Sotack JL, et al. CT in detecting urinary tract calculi: influence on patient imaging and clinical outcomes. *Radiology* 2002;225:441-9.
4. Westphalen AC, Hsia RY, Maselli JH, Wang R, Gonzales R. Radiological imaging of patients with suspected urinary tract stones: national trends, diagnoses, and predictors. *Acad Emerg Med* 2011;18:699-707.

5. Smith-Bindman R, Aubin C, Bailitz J, et al. Ultrasonography versus computed tomography for suspected nephrolithiasis. *N Engl J Med* 2014;371:1100-10.
6. Weisenthal K, Karthik P, Shaw M, et al. Evaluation of kidney stones with reduced-radiation dose CT: progress from 2011–2012 to 2015–2016—not there yet. *Radiology* 2017;286:581-9.
7. Schoenfeld EM, Pekow PS, Shieh MS, Scales CD, Lagu T, Lindenauer PK. The diagnosis and management of patients with renal colic across a sample of US hospitals: high CT utilization despite low rates of admission and inpatient urologic intervention. *PLoS One* 2017;12:e0169160.
8. Coursey CA, Casalino DD, Remer EM, et al. ACR Appropriateness Criteria acute onset flank pain—suspicion of stone disease. *Ultrasound Q* 2012;28:227-33.
9. American College of Radiology ACR Appropriateness Criteria acute onset flank pain—suspicion of stone disease (urolithiasis). American College of Radiology. Available at: <https://acsearch.acr.org/docs/69362/Narrative/>. Published 2015. Accessed May 7, 2019.
10. Fulgham PF, Assimos DG, Pearle MS, Preminger GM. Clinical effectiveness protocols for imaging in the management of ureteral calculous disease: AUA technology assessment. *J Urol* 2013;189:1203-13.
11. Whiting, PF, Rutjes AW, Westwood ME et al. QUADAS-2: A Revised Tool for the Quality Assessment of Diagnostic Accuracy Studies. *Ann. Intern. Med.* 155, 529–536 (2011) <https://doi.org/10.7326/0003-4819-155-8-201110180-00009>.
12. ACEP Clinical Policy Rating Tool. Available at: <https://www.acep.org/globalassets/uploads/uploaded-files/acep/clinical-and-practice-management/clinical-policies/grading-form—diagnostic-questions.pdf>. Accessed May 3, 2019.
13. Hamm M, Wawroschek F, Weckerman D, et al. Unenhanced helical computed tomography in the evaluation of acute flank pain. *Eur Urol* 2001;39:460-5.
14. Abdel-Gawad M, Kadasne R, Anjekar C, Elsobky E. Value of color Doppler ultrasound, KUB and urinalysis in diagnosis of renal colic due to ureteral stones. *Int Braz J Urol* 2014;40:513-9.
15. Ripollés T, Martínez-Pérez MJ, Vizuite J, Miralles S, Delgado F, Pastor-Navarro T. Sonographic diagnosis of symptomatic ureteral calculi: usefulness of the twinkling artifact. *Abdom Imaging* 2013;38:863-9.
16. Sen V, Imamoglu C, Kucukturkmen I, et al. Can Doppler ultrasonography twinkling artifact be used as an alternative imaging modality to non-contrast-enhanced computed tomography in patients with ureteral stones? A prospective clinical study. *Urolithiasis* 2017;45:215-9.
17. Vallone G, Napolitano G, Fonio P, et al. US detection of renal and ureteral calculi in patients with suspected renal colic. *Crit Ultrasound J* 2013;5(Suppl 3):1-5.
18. Yavuz A, Ceken K, Alimoglu E, Kabaalioglu A. The reliability of color Doppler “twinkling” artifact for diagnosing millimetric nephrolithiasis: comparison with B-mode US and CT scanning results. *J Med Ultrason* 2015;42:215-22.
19. Pichler R, Skradski V, Aigner F, Leonhartsberger N, Steiner H. In young adults with a low body mass index ultrasonography is sufficient as a diagnostic tool for ureteric stones. *BJU Int* 2012;109:770-4.
20. Ekici S, Sinanoglu O. Comparison of conventional radiography combined with ultrasonography versus nonenhanced helical computed tomography in evaluation of patients with renal colic. *Urol Res* 2012;40:543-7.
21. Kobayashi T, Nishizawa K, Watanbe J, Ogura K. Clinical characteristics of ureteral calculi detected by nonenhanced computerized tomography after unclear results of plain radiography and ultrasonography. *J Urol* 2003;170:799-802.
22. Ripollés T, Agramunt M, Errando J, Martínez MJ, Coronel B, Morales M. Suspected ureteral colic: plain film and sonography vs unenhanced helical CT. A prospective study in 66 patients. *Eur Radiol* 2004;14:129-36.
23. Wong C, Teitge B, Ross M, Young P, Robertson HL, Lang E. The accuracy and prognostic value of point-of-care ultrasound for nephrolithiasis in the emergency department: a systematic review and meta-analysis. *Acad Emerg Med* 2018;25:684-98.
24. Daniels B, Gross CP, Molinaro A, et al. STONE PLUS: evaluation of emergency department patients with suspected renal colic, using a clinical prediction tool combined with point-of-care limited ultrasonography. *Ann Emerg Med* 2016;67:439-48.
25. Herbst MK, Rosenberg G, Daniels B, et al. Effect of provider experience on clinician-performed ultrasonography for hydronephrosis in patients with suspected renal colic. *Ann Emerg Med* 2014;64:269-76.
26. Riddell J, Case A, Wopat R, et al. Sensitivity of emergency bedside ultrasound to detect hydronephrosis in patients with computed tomography-proven stones. *West J Emerg Med* 2014;15:96-100.
27. Goertz JK, Lotterman S. Can the degree of hydronephrosis on ultrasound predict kidney stone size? *Am J Emerg Med* 2010;28:813-6.
28. Moak JH, Lyons MS, Lindsell CJ. Bedside renal ultrasound in the evaluation of suspected ureterolithiasis. *Am J Emerg Med* 2012;30:218-21.
29. Metzler IS, Smith-Bindman R, Moghadasi M, Wang RC, Stoller ML, Chi T. Emergency department imaging modality effect on surgical management of nephrolithiasis: a multicenter, randomized clinical trial. *J Urol* 2017;197:710-4.
30. Wang RC, Rodriguez RM, Fahimi J, et al. Derivation of decision rules to predict clinically important outcomes in acute flank pain patients. *Am J Emerg Med* 2017;35:554-63.
31. Samim M, Goss S, Luty S, Weinreb J, Moore C. Incidental findings on CT for suspected renal colic in emergency department patients: prevalence and types in 5,383 consecutive examinations. *J Am Coll Radiol* 2015;12:63-9.
32. Hayward R. VOMIT (victims of modern imaging technology)—an acronym for our times. *BMJ* 2003;326:1273.
33. Sternberg KM, Pais VM, Larson T, Han J, Hernandez N, Eisner B. Is hydronephrosis on ultrasound predictive of ureterolithiasis in patients with renal colic? *J Urol* 2016;196:1149-52.
34. Lindqvist K, Hellström M, Holmberg G, Peeker R, Grenabo L. Immediate versus deferred radiological investigation after acute renal colic: a prospective randomized study. *Scand J Urol Nephrol* 2006;40:119-24.
35. Catalano O, Nunziata A, Sandomenico F, Siani A. Acute flank pain: comparison of unenhanced helical CT and ultrasonography in detecting causes other than ureterolithiasis. *Emerg Radiol* 2002;9:146-54.
36. Sierzynski PR, Linton OW, Stephen Amis E, et al. Applications of justification and optimization in medical imaging: examples of clinical guidance for computed tomography use in emergency medicine. *Ann Emerg Med* 2014;63:25-32.
37. Weisenthal K, Karthik P, Shaw M, et al. Evaluation of kidney stones with reduced-radiation dose CT. *Radiology* 2017;000:1-9.
38. Moore CL, Daniels B, Singh D, et al. Ureteral stones: implementation of a reduced-dose CT protocol in patients in the emergency department with moderate to high likelihood of calculi on the basis of STONE score. *Radiology* 2016;280:743-51.
39. Niemann T, Kollmann T, Bongartz G. Diagnostic performance of low-dose CT for the detection of urolithiasis: a meta-analysis. *AJR Am J Roentgenol* 2008;191:396-401.
40. Poletti P-A, Platon A, Rutschmann OT, Schmidlin FR, Iselin CE, Becker CD. Low-dose versus standard-dose CT protocol in patients with clinically suspected renal colic. *AJR Am J Roentgenol* 2007;188:927-33.
41. Glazer DI, Maturen KE, Cohan RH, et al. Assessment of 1 mSv urinary tract stone CT with model-based iterative reconstruction. *AJR Am J Roentgenol* 2014;203:1230-5.
42. Tack D, Sourtzis S, Delpierre I, Gevenois PA. Low-dose unenhanced multidetector CT of patients with suspected renal colic. *AJR Am J Roentgenol* 2003;180:305-11.
43. Gervaise A, Naullet P, Beuret F, et al. Low-dose CT with automatic tube current modulation, adaptive statistical iterative reconstruction, and low tube voltage for the diagnosis of renal colic: impact of body mass index. *AJR Am J Roentgenol* 2014;202:553-60.