

Tissue eosinophils as a histopathological marker in oral premalignant and malignant lesions: a histochemical study

Shirin Saravani¹, Hamideh Kadeh^{1✉}, Asma Abil najafzade²

1. Assistant Professor, Oral & Dental Diseases Research Center, Department of Oral & Maxillofacial Pathology, Faculty of Dentistry, Zahedan University of Medical Sciences, Zahedan, IR Iran.
2. General Dentist, Faculty of Dentistry, Zahedan University of Medical Sciences, Zahedan, IR Iran.

✉ **Corresponding Author:** Hamideh Kadeh, Faculty of Dentistry, Zahedan University of Medical Sciences, Zahedan, IR Iran.

Email: kadeh@zaums.ac.ir

Tel: +985433414001

Received: 1 Oct 2016

Accepted: 9 Aug 2017

Abstract

Introduction: Although recent studies show the association of eosinophils with different tumors including oral malignancies, the role of eosinophils in premalignant conditions of the oral cavity is not known precisely. Therefore, this study aimed to determine the number of eosinophils in premalignant and malignant conditions of the oral cavity and its role in progression to malignancy.

Materials & Methods: This cross-sectional study was done on 50 samples with oral squamous cell carcinoma (OSCC), 18 with verrucous carcinoma, 13 with erosive lichen planus, and 10 with leukoplakia with mild dysplasia after confirmation of histopathological diagnosis. The samples were stained with Sirius Red. The total numbers of eosinophils in 10 areas were counted at a magnification of 400x (eosinophil/10HPF). Data are analyzed with Kruskal-Wallis test, Mann-Whitney test, and Spearman's correlation test.

Results: The mean number of eosinophils in OSCC, verrucous carcinoma, erosive lichen planus, and leukoplakia with mild dysplasia was 90.26, 59.72, 11.08 and 0.0 eosinophil/10HPF respectively. The mean number of eosinophils was significantly higher in malignant (OSCC and verrucous carcinoma) than premalignant (erosive lichen planus and leukoplakia with mild dysplasia) lesions of the oral cavity ($P=0.0001$). No significant correlation was found between the number of eosinophils with histopathologic grade, gender, and age in OSCC samples.

Conclusion: The greater number of eosinophils is seen in malignant than premalignant lesions of the oral cavity. It is recommended to consider the high number of eosinophils in premalignant lesions as an indicator for a more potential of preliminary oral lesions to undergo malignant transformation.

Keywords: Eosinophil, Oral cancer, Squamous cell carcinoma, Precancerous conditions

Citation for article: Saravani S, Kadeh H, Abil najafzade S. Tissue eosinophils as a histopathological marker in oral premalignant and malignant lesions: a histochemical study. Caspian J Dent Res 2017;6: 8-14.

اُتوزینوفیل‌های بافتی بعنوان یک مارکر هیستوپاتولوژیک در ضایعات پیش بدخیم و بدخیم دهانی: یک مطالعه هیستوشیمی

شیرین سراوانی، حمیده کده*، اسما آیل نجف زاده

چکیده

مقدمه: هرچند مطالعات اخیر همراهی اُتوزینوفیل‌ها با تومورهای مختلف من جمله بدخیم‌های دهان نشان داده شده است ولی نقش اُتوزینوفیل‌ها در شرایط پیش بدخیم حفره دهان بطور دقیق مشخص نشده است. بدین ترتیب هدف از مطالعه حاضر تعیین تعداد اُتوزینوفیل‌ها در شرایط پیش بدخیم و بدخیم حفره دهان و نقش آن در پیشرفت به سمت بدخیمی می باشد.

مواد و روش‌ها: این مطالعه مقطعی بر روی ۵۰ نمونه OSCC، ۱۸ نمونه verrucous carcinoma، ۱۳ نمونه لیکن پلان اروزیو و ۱۰ نمونه لکوپلاکیا با دیسپلازی خفیف بعد از تایید هیستوپاتولوژیک آنها صورت پذیرفت. نمونه‌ها با Sirius red رنگ آمیزی شدند. مجموع تعداد اُتوزینوفیل‌ها در ۱۰ ناحیه با بزرگنمایی ۴۰۰ (eosinophil/10HPF) محاسبه شد. اطلاعات بدست آمده توسط آزمون‌های کروسکال والیس، من ویتنی و آزمون همبستگی اسپیرمن تجزیه و تحلیل شدند.

یافته‌ها: میانگین تعداد اُتوزینوفیل‌ها در OSCC، verrucous carcinoma، لیکن پلان اروزیو و لکوپلاکیا با دیسپلازی خفیف به ترتیب ۹۰/۲۶، ۵۹/۷۲، ۱۱/۰۸ و صفر eosinophil/10HPF بود. میانگین تعداد اُتوزینوفیل‌ها در ضایعات بدخیم دهان (OSCC و verrucous carcinoma) بطور معنی دار بیشتر از ضایعات پیش بدخیم (لیکن پلان اروزیو و لکوپلاکیا با دیسپلازی خفیف) بود (P=0.0001). بین تعداد اُتوزینوفیل‌ها با درجه هیستوپاتولوژیک، جنس و سن در نمونه‌های OSCC ارتباط معنی داری بدست نیامد.

نتیجه‌گیری: حضور بیشتر اُتوزینوفیل‌ها در ضایعات بدخیم نسبت به پیش بدخیم حفره دهان مشاهده شد. پیشنهاد می‌گردد تا تعداد زیاد اُتوزینوفیل‌ها در ضایعات پیش بدخیم بعنوان شاخصی برای پتانسیل بیشتر ضایعات پیش بدخیم دهانی جهت تبدیل به بدخیمی در نظر گرفته شود.

واژگان کلیدی: اُتوزینوفیل، سرطان دهان، کارسینوما سلول سنگفرشی، شرایط پیش بدخیم

Introduction

Oral squamous cell carcinoma (OSCC) is the most prevalent malignancy of the oral cavity with different reasons,^[1] including tobacco and alcohol use, malnutrition, systemic diseases and genetic factors.^[1, 2] OSCC development can also be affected by immune response in the host.^[3] Verrucous carcinoma is a variant of squamous cell carcinoma that most commonly appears in oral cavity.^[4] Although this tumor is very similar to OSCC, it shows different biological behavior and rarely produces metastasis.^[5] Lichen planus is a common inflammatory mucocutaneous disease with uncertain etiology that occurs in 1-2% of the general population.^[6, 7] The frequency of malignancy changes in oral lichen planus (OLP) is 0.4-5.3%. The World Health Organization (WHO) has classified OLP as a potentially malignant disorder.^[7] Infiltration of inflammatory cells such as mast cells, lymphocytes and eosinophils is seen in lichen planus.^[6] As defined by WHO, leukoplakia is "a white patch or plaque that

cannot be characterized clinically or pathologically as any other disease." The risk of a malignancy is very high in a leukoplakia (1000 times or fold).^[8] Some studies have reported the presence of eosinophil as an inflammatory cell in leukoplakia.^[9] Eosinophils are multi-functional leukocytes, produced in the bone marrow and transmitted by blood to the site of inflammation.^[10] They are cells with abundant cytoplasm and rough granules.^[9] Different histochemical techniques such as Sirius Red, Congo red, and Luna, as well as conventional and modified hematoxylin and eosin have been used for staining eosinophils. For multiple parameters such as eosinophil detection, specificity, and contrast with background tissues, Sirius Red technique and after that Congo red are more useful.^[11] Eosinophils normally present in mucosal tissues and are effective in tissue morphogenesis and homeostasis.^[10] Large quantities of these cells are observed in different diseases like allergies, asthma and parasitic infections.^[12]

Eosinophils are released proinflammatory mediators in these diseases.^[10] The presence of eosinophils has been observed in tumors in different areas of the body including the oral cavity.^[12] Eosinophils also play a role in biological behavior of carcinomas and produce substances that induce tumor progression or regulation.^[13] It is also believed that eosinophils kill tumor cells directly by releasing cytotoxic proteins and indirectly by increasing the permeability of tumor cells to tumor-killing cytokines.^[9]

Since many attempts are made today to discover the suitable conditions from premalignant to malignant transformation, this study compared the number of tissue eosinophils in premalignant and malignant conditions of the oral cavity.

Materials and Methods

Patient selection: This study, approved in the Ethics Committee of Zahedan University of Medical Sciences (Project Number. 7037), was conducted on all biopsied specimens of 50 patients with OSCC (well differentiated), oral verrucous carcinoma (18 cases), erosive lichen planus (13 cases), and leukoplakia with mild dysplasia (10 cases) existing in the pathology laboratory of Zahedan Dental School. Lesions were diagnosed according to clinical and histopathological criteria.^[14] Data containing age, gender, and lesion site were collected from the patients' records.

Histochemical staining: The microscopic slides of hematoxylin-eosin staining (H and E staining) were examined and diagnosed again. Samples with necrosis or muscle destruction were excluded. A 4- μ m section was prepared from paraffin block of each sample, and stained with histochemical staining of Sirius Red.^[11] The prepared sections were first deparaffinized and immersed in an alcohol solution. They were, then, placed in Harris Hematoxylin for two minutes and rinsed with running water. After that, they were placed in 1% acid alcohol for 5 seconds and rinsed again with running water and 100% ethanol. In the next stage, sections were immersed in an alkaline Sirius red solution (pH 8-9) for two hours and rinsed with running water for three minutes. They were, then, rehydrated in an alcohol solution and cleared in a xylene, and finally mounted. The prepared slide was examined with an optical microscope (Nikon, Japan). Finally, the total number of eosinophils in 10 areas was recorded for each sample at a magnification of 400X (eosinophil/10HPF).

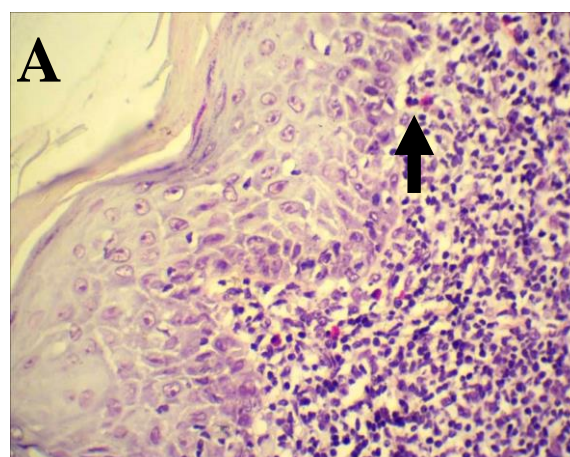
^[9] It is worth noting that only nucleated cells with intensely red cytoplasmic granules were accepted as eosinophils, and those confined to lymphovascular spaces were excluded.

Statistical analysis: All obtained data were analyzed using 21.0 (SPSS Inc, Chicago, IL). First, the normality of data was examined with Kolmogorov–Smirnov test. Second, the number of eosinophils in different groups was compared and its correlation with age was inspected using Kruskal-Wallis Test, Mann-Whitney Test, and Spearman's correlation test. Then, $p < 0.05$ was statistically considered significant.

Results

In general, there were 91 oral samples (39 males (42.9%) and 52 females (57.1%)) with the mean age of 52.58 ± 16.08 . The samples included 13 erosive lichen planus, 10 leukoplakia with mild dysplasia, 18 verrucous carcinoma and 50 OSCC with mean ages of 43.61 ± 10.19 , 39.6 ± 18.37 , 51.83 ± 19.4 , and 57.78 ± 13.17 , respectively. The incidence of erosive lichen planus, leukoplakia with mild dysplasia, verrucous carcinoma, and OSCC was 76.9%, 20%, 55.6%, and 60%, respectively in females. Lesions existed on the buccal mucosa (26.4%), lips (13.2%), mandibular gingiva (11%), mandibular bone (9.9%), tongue (11%), floor of the mouth (2.2%), maxillary gingiva (1.1%), and other areas (25.3%).

The mean number of eosinophils in the lesions was 62.99 ± 86.53 eosinophil/10HPF in overall (Figure 1).



Downloaded from cjdr.ir at 14:20 +0330 on Tuesday December 11th 2018 [DOI: 10.22088/cjdr.6.2.8]

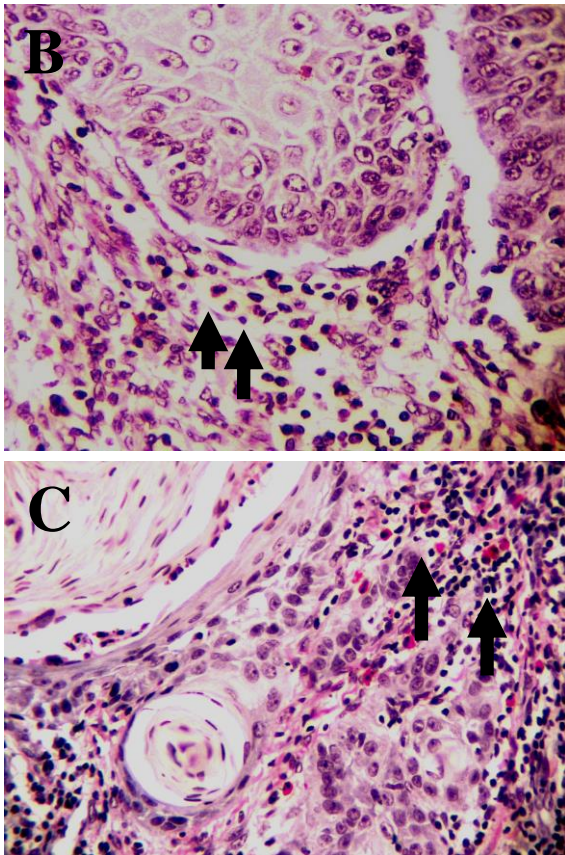


Figure 1. A: eosinophil cells (red arrow) beneath the epithelium in oral lichen planus (×400, Sirius Red staining). **B:** eosinophil cells (red arrow) near the rete ridge in verrucous carcinoma (×400, Sirius Red staining). **C:** eosinophil (red arrows) cells around the epithelial nests of oral squamous cell carcinoma (×400, Sirius Red staining).

The mean numbers of eosinophils were 6.26±9.15 and 82.18±92.48 eosinophil/10HPF in premalignant (erosive lichen planus and leukoplakia with mild dysplasia) and malignant (OSCC and verrucous carcinoma) lesions, respectively implying a significant difference between the two groups in this regard (Mann-Whitney Test, P=0.001). Table 1 shows the mean number of eosinophils in erosive lichen planus, leukoplakia with mild dysplasia, verrucous carcinoma, and OSCC separately. According to this table, the difference in the number of eosinophils was statistically significant between the four lesion groups (P=0.001). According to Tukey test, there was only a significant difference between OSCC and erosive lichen planus (P=0.011) and between OSCC and leukoplakia with mild dysplasia (P=0.009).

Table 1. Comparison of eosinophil counts in erosive lichen planus, leukoplakia with mild dysplasia, verrucous carcinoma, and OSCC

| Diagnosis | N | Minimum | Maximum | Mean |
|---------------------------------|----|---------|---------|--------------|
| Erosive Lichen planus | 13 | 1 | 27 | 11.08±9.78 |
| Leukoplakia with mild dysplasia | 5 | 0 | 0 | 0 |
| Verrucous carcinoma | 18 | 0 | 157 | 59.72±60.38 |
| OSCC | 50 | 0 | 387 | 90.26±100.88 |

*p=0.001 Kruskal-Wallis Test

Although the mean number of eosinophils was higher in women with OSCC (101.07±112.06) than men with OSCC (74.05±81.35), this difference was not significant (Mann-Whitney Test, P value=0.55). In addition, no significant correlation was observed between the age and mean number of eosinophils in patients with OSCC (Spearman’s rho, P=0.26, r=-0.16). Table 2 represents the mean number of eosinophils in different histopathologic grades of OSCC. As it is observed, there is no statistically significant difference between them (P=0.21).

Table 2. Comparison of eosinophil counts between different histopathologic grades of OSCC

| Grade | N | Minimum | Maximum | Mean |
|-----------|----|---------|---------|---------------|
| Grade I | 33 | 0 | 387 | 104.64±113.26 |
| Grade II | 11 | 6 | 262 | 79.91±75.02 |
| Grade III | 6 | 0 | 64 | 30.17±20.98 |

* P=0.21 Kruskal-Wallis Test

Discussion

Eosinophils contain several cytotoxic granule proteins including major basic protein (MBP), MBP2, eosinophil-derived neurotoxin (EDN), eosinophil peroxidase (EPX), and eosinophil cationic protein (ECP).^[10] They can kill tumor cells through binding molecules such as CD11a and CD18.^[15] Moreover, eosinophils secrete MMP-1 in head and neck tumors. Therefore, they can contribute to remodeling process through this enzyme against tumor envision.^[16] In this study, the mean number of eosinophils was significantly higher in OSCC than erosive lichen planus and leukoplakia with mild dysplasia. Moreover, malignant lesions contained higher amounts of eosinophils than

pre-malignant lesions, which are consistent with the findings of Jain et al. and Kargahi et al.^[9, 17] They correlated the greater infiltration of eosinophils with more invasions of OSCC to connective tissue.^[17]

Different numbers of eosinophils have been reported by various studies, which may be due to the difference in staining techniques, and classifying and counting methods.^[18] Although eosinophils are commonly seen in H and E staining, sometimes they haven't normal morphology especially in fibrous tissue and inflammatory infiltrate and their recognition in stained slides with H and E is very difficult.^[13] Some studies have revealed that Congo red staining as compared to H and E staining has a significantly higher capability in the detection of eosinophils^[13, 17] whereas other studies have indicated that Sirius red has better detection of eosinophils than other histochemical methods including Congo red.^[11] There is a discrepancy among studies on the superiority of immunohistochemistry staining over histochemical staining.^[17, 19] With respect to eosinophils counting, some studies have presented some quantitative and qualitative reports.^[9, 13, 20] In this study, the mean number of eosinophils was obtained 90.26 eosinophil/10HPF, using Sirius red. Other studies have reported the mean number of eosinophils is 75.7 eosinophil/10HPF (using Congo red),^[13] 57.1 eosinophil/mm² (using H and E),^[21] 12.8 eosinophil/10HPF (using H and E),^[13] and 6.56 eosinophil/10HPF (using Congo red).^[9]

Rahrotaban et al. showed the correlation between histopathologic grade and the number of eosinophils in head and neck SCC, so that the amount of eosinophils was decreased as tumor grade was increased.^[18] Although the current study suggested lower number of eosinophils in higher OSCC grades, this correlation was not significant, which is quite contradictory to those of Kargahi et al.^[17] Some other studies also have not shown a certain correlation between the number of eosinophils and histopathologic grade.^[13, 22] In the present study, there was found no certain relationship between the number of eosinophils with gender and age of OSCC samples, which agrees with other studies.^[23, 24] The number of eosinophils in verrucous carcinoma was obtained as 0-157 eosinophil/10HPF in this study. Oliveira et al. studied on 20 areas with HPF in H and E staining. They concluded that eight of nine samples were without infiltration or with mild eosinophilic infiltration (0-175 eosinophils).^[23] In another study on

three HPF, using Luna staining, at least 30 eosinophils were reported in one case with verrucous carcinoma.^[16]

Jain et al. used the Congo red method and reported the amount of dysplastic leukoplakia with mild, moderate, and severe dysplasia as 2.1, 2.8, and 2.3 eosinophil/10HPF, respectively, indicating no significant difference.^[9] In this study, the number of eosinophils was reported zero. In addition, the mean number of eosinophils in lichen planus was 11.08 eosinophil/10HPF (ranging from 1 to 27) while Reddy et al. reported this amount as 0.183 eosinophil/4HPF, using H and E staining.^[6] Mravak-Stipetic et al. observed eosinophils in 4.1% of OLP cases.^[25]

Conclusion

In conclusion, the number of eosinophils was higher in malignant than pre-malignant lesions of the oral cavity. Therefore, the number of eosinophils can be used as a marker when there is a suspicious transformation of small pre-malignant lesions to malignant lesions of the oral cavity. The use of eosinophils number, as a prognostic factor, along with longer follow-up periods is recommended in further investigations on oral pre-malignant and malignant lesions.

Acknowledgments

The authors would like to thank the Research Deputy of Zahedan University of Medical Sciences for approving and supporting this study.

Funding: This study was a thesis and research project (Grant No: 94-7037) supported and funded by Zahedan University of Medical Sciences.

Conflict of Interests: The authors had no conflict of interest to declare.

Authors' Contribution

Study concept and design: Shirin Saravani; collecting data: Shirin Saravani, Hamideh Kadeh and Asma Abil Najaf Zade; analysis and interpretation of data: Shirin Saravani and Asma Abil Najaf Zade; drafting of the manuscript: Shirin Saravani, Hamideh Kadeh and Asma Abil Najaf Zade; critical revision of the manuscript for important intellectual content: Shirin Saravani, Hamideh Kadeh and Asma Abil Najaf Zade; statistical analysis: Shirin Saravani and Asma Abil Najaf Zadeh. Study supervision: Shirin Saravani.

References

- Miri-Moghaddam E, Saravani S, Garne Y, Khosravi A, Bazi A, Motazedian J. Methylenetetrahydrofolate reductase C677T and A1298C gene polymorphisms in oral squamous cell carcinoma in south-east Iran. *J Oral Pathol Med* 2016;45:96-100.
- Saravani S, Miri-Moghaddam E, Sanadgol N, Kadeh H, Nazeri MR, Nazeri M R. Human herpesvirus-6 and epstein-barr virus infections at different histopathological grades of oral squamous cell carcinomas. *Int J Prev Med* 2014;5:1231-8.
- Martinelli-Klay CP, Mendis BRRN, Lombardi T. Eosinophils and oral squamous cell carcinoma: a short review. *J Oncol* 2009;2009:310132.
- Santoro A, Pannone G, Contaldo M, Sanguedolce F, Esposito V, Serpico R, et al. A troubling diagnosis of verrucous squamous cell carcinoma ("the bad kind" of keratosis) and the need of clinical and pathological correlations: a review of the literature with a case report. *J Skin Cancer* 2011;2011:370605.
- Kadeh H, Saravani S, Heydari F, Keikha M, Rigi V. Expression of matrix metalloproteinase-10 at invasive front of squamous cell carcinoma and verrucous carcinoma in the oral cavity. *Asian Pac J Cancer Prev* 2015;16:6609-13.
- Reddy DS, Sivapathasundharam B, Saraswathi TR, SriRam G. Evaluation of mast cells, eosinophils, blood capillaries in oral lichen planus and oral lichenoid mucositis. *Indian J Dent Res* 2012;23:695-6.
- Shen ZY, Liu W, Zhu LK, Feng JQ, Tang GY, Zhou ZT. A retrospective clinicopathological study on oral lichen planus and malignant transformation: analysis of 518 cases. *Med Oral Patol Oral Cir Bucal* 2012;17:e943-7.
- van der Waal I. Oral leukoplakia, the ongoing discussion on definition and terminology. *Med Oral Patol Oral Cir Bucal* 2015;20:e685-92.
- Jain M, Kasetty S, Sudheendra US, Tijare M, Khan S, Desai A. Assessment of tissue eosinophilia as a prognosticator in oral epithelial dysplasia and oral squamous cell carcinoma-an image analysis study. *Patholog Res Int* 2014;2014:507512.
- Kita H. Eosinophils: multifaceted biological properties and roles in health and disease. *Immunol Rev* 2011;242:161-77.
- Meyerholz DK, Griffin MA, Castilow EM, Varga SM. Comparison of histochemical methods for murine eosinophil detection in an RSV vaccine-enhanced inflammation model. *Toxicol Pathol* 2009;37:249-55.
- Davoine F, Sim A, Tang C, Fisher S, Ethier C, Puttagunta L, et al. Eosinophils in human oral squamous carcinoma; role of prostaglandin D2. *J Inflamm (Lond)* 2013;10:4.
- Joshi PS, Kaijkar MS. A histochemical study of tissue eosinophilia in oral squamous cell carcinoma using congo red staining. *Dent Res J (Isfahan)* 2013;10:784-9.
- Neville BW, Damm DD, Allen CM, Chi AC. *Oral and maxillofacial pathology*. 4th ed. St. Louis, Missouri: Elsevier;2016.p.355-63, 374-91, 729-34.
- Amini-Vaughan ZJ, Martinez-Moczygemba M, Huston DP. Therapeutic strategies for harnessing human eosinophils in allergic inflammation, hypereosinophilic disorders, and cancer. *Curr Allergy Asthma Rep* 2012;12:402-12.
- Ono Y, Fujii M, Kameyama K, Otani Y, Sakurai Y, Kanzaki J. Expression of matrix metalloproteinase-1 mRNA related to eosinophilia and interleukin-5 gene expression in head and neck tumour tissue. *Virchows Arch* 1997;431:305-10.
- Kargahi N, Razavi SM, Deyhimi P, Homayouni S. Comparative evaluation of eosinophils in normal mucosa, dysplastic mucosa and oral squamous cell carcinoma with hematoxylin-eosin, congo red, and EMR1 immunohistochemical staining techniques. *Electron Physician* 2015;7:1019-26.
- Rahrotaban S, Jolehar M, Khatibi AH. Tissue Eosinophilia in Head and Neck Squamous Cell Carcinoma. *J Res Dent Sci* 2014;11:96-102.[In Persian]
- Lorena SC, Dorta RG, Landman G, Nonogaki S, Oliveira DT. Morphometric analysis of the tumor associated tissue eosinophilia in the oral squamous cell carcinoma using different staining techniques. *Histol Histopathol* 2003;18:709-13.
- Rakesh N, Devi Y, Majumdar K, Reddy SS, Agarwal K. Tumour associated tissue eosinophilia as a predictor of locoregional recurrence in oral squamous cell carcinoma. *J Clin Exp Dent* 2015;7:e1-6.
- Pereira MC, Oliveira DT, Olivieri EH, Rogatto SR, Carvalho AL, Landman G, et al. The 434(G>C) polymorphism in the eosinophil cationic protein gene and its association with tissue eosinophilia in oral squamous cell carcinomas. *J Oral Pathol Med* 2010;39:56-62.

22. Tadbir AA, Ashraf MJ, Sardari Y. Prognostic significance of stromal eosinophilic infiltration in oral squamous cell carcinoma. *J Craniofac Surg* 2009;20:287-9.
23. Tostes Oliveira D, Tjioe KC, Assao A, Sita Faustino SE, Lopes Carvalho A, Landman G, et al. Tissue eosinophilia and its association with tumoral invasion of oral cancer. *Int J Surg Pathol* 2009;17:244-9.
24. Oliveira DT, Biassi TP, Faustino SE, Carvalho AL, Landman G, Kowalski LP. Eosinophils may predict occult lymph node metastasis in early oral cancer. *Clin Oral Investig* 2012;16:1523-8.
25. Mravak-Stipetić M, Lončar-Brzak B, Bakale-Hodak I, Sabol I, Seiwerth S, Majstorović M, et al. Clinicopathologic correlation of oral lichen planus and oral lichenoid lesions: a preliminary study. *ScientificWorld Journal* 2014;2014:746874.