

Dimensional changes of dental arch following non-extraction orthodontic treatment

Mahsa Sobhi Afshar¹, Asghar Ebadifar^{2✉}

1. Dentist.

2. Associate Professor, Dentofacial Deformities Research Center, Department of Orthodontics, Dental School, Shahid Beheshti University of Medical Sciences, Tehran, Iran.

✉ **Corresponding Author:** Asghar Ebadifar, Dental School, Shahid Beheshti University of Medical Sciences, Tehran, Iran.

Email: a.ebadifar@sbm.ac.ir

Tel: +98021-81455181

Received: 12 Oct 2015

Accepted: 2 Apr 2016

Abstract

Introduction: Since the emergence of normal occlusion concept, selecting an appropriate treatment plan with or without tooth extraction has been a controversial subject. Nowadays, both methods can be successfully used for treatment of patients. However, some clinicians still believe that non-extraction orthodontic treatments have fewer complications. The purpose of this study was to evaluate dental arch dimensional changes following non-extraction orthodontic treatment.

Materials & Methods: A total of 200 pre- and post-treatment diagnostic dental casts belonging to 100 patients (non-ext treated by 0.18 roth system) who met the inclusion criteria for this study were collected from the archives of Shahid Beheshti Dental School. Sampling was nonrandomized. A digital caliper with the accuracy of 0.1 mm was used for the measurement of variables such as inter-canine width, inter-premolar width and inter-molar width.

Results: Non-extraction orthodontic treatment increased all the variables, except for the mandibular inter-canine width and incisor-canine distance.

Conclusion: Non-extraction orthodontic treatment causes a significant increase in almost all dental arch parameters. This increase manifests as teeth flaring.

Keywords: Dental arch, Orthodontics, Mandible, Maxilla

Citation for article: Sobhi Afshar M, Ebadifar A. Dimensional changes of dental arch following non-extraction orthodontic treatment. Caspian J Dent Res 2016; 5: 29-35.

بررسی تغییرات طول و عرض قوس فکی متعاقب درمانهای ارتودنسی بدون کشیدن دندان

مهسا صبحی افشار، اصغر عبادی فر*

چکیده

مقدمه: از زمان ظهور نظریه اکلوتن نرمال، طرح درمان صحیح با و یا بدون کشیدن دندان بحث برانگیز بوده است. امروزه بیماران را میتوان با هر دو روش درمان کرد، اما همچنان این پیش فرض در بین تعدادی از دندانپزشکان وجود دارد که درمانهای ارتودنسی بدون کشیدن دندان عوارض کمتری دارد. هدف از این مطالعه بررسی تغییرات طول و عرض قوس فکی متعاقب درمانهای ارتودنسی بدون کشیدن دندان است.

مواد و روش ها: در این مطالعه تعداد ۲۰۰ جفت کست تشخیصی قبل و بعد از درمان متعلق به ۱۰۰ بیمار با میانگین سن ۲۱ سال و ± 6 ماه که حائز شرایط این مطالعه بودند و با استفاده از سیستم Roth 0.18 بصورت Non ext درمان شده بودند از آرشیو دانشکده دندانپزشکی شهید بهشتی مورد بررسی قرار گرفتند. انتخاب بیماران به صورت سرشماری (غیر تصادفی) بوده است. برای اندازه گیری متغیرهای این مطالعه از کولیس دیجیتالی با دقت ± 0.1 میلیمتر استفاده گردید.

یافته ها: براساس یافته های این تحقیق تمامی متغیرهای مورد مطالعه طی درمان ارتودنسی بدون کشیدن دندان با افزایش تمامی پارامترهای قوس دندانی مواجه شدند و این افزایش در مورد تمامی متغیرها به جز عرض مابین کاین های مندیبل و طول انسیزال-کاین کاملاً معنی دار بوده است.

نتیجه گیری: درمان ارتودنسی بدون کشیدن دندان باعث افزایش معنی دار اکثر ابعاد قوس فکی میشود که این افزایش به صورت flaring دندانی نمود می یابد.

واژگان کلیدی: قوس دندانی، ارتودنسی، فک پایین، فک بالا

Introduction

Many orthodontic researchers believe that a successful orthodontic treatment should comply with patients' needs and patients must be satisfied with the outcome. Since the emergence of the normal occlusion concept, selecting an appropriate treatment plan with or without tooth extraction has been a controversial subject.^[1-6] angle and his followers strongly opposed extraction for orthodontics purposes^[7] and they did not recognize any need for the extraction of teeth, the angle system dose not take into account any possibility of arch perimeter problems.^[8] However, Charles H Tweed, one of Angle's apostate students, was dissatisfied with facial proportions in non-extraction patients and challenged Angle's non-extraction theory. Due to his efforts, extraction orthodontic treatment gained the spotlight and became a popular technique.^[9-11] Since 1960, with the advancements in orthodontic techniques and appliances, this equilibrium lies towards the non-extraction treatments again.^[12] At present, due to the advancements in orthodontic science, patients can be treated with both techniques. However, choosing the

most appropriate treatment plan for patients is still a difficult task in some cases. Some clinicians still believe that tooth extractions further narrow the dental arch and compromise smile esthetics because of the wide buccal corridors.^[13-15] Non-extraction orthodontic treatments do not have such complications and therefore, are favored by most clinicians. Another advantage of non-extraction orthodontic treatments is their shorter duration compared to the extraction treatments. However, instability of treatment outcome and relapse is one major drawback of this technique that significantly affects the treatment planning. Theoretically, the greater the buccalmovement of teeth, the greater the load applied to teeth by the lips and chicks and therefore, the greater their relapse will be.^[16] Extraction orthodontic therapy has better outcome stability but it has its own disadvantages as well. Many studies have also demonstrated that teeth tend to relapse even after extraction orthodontic treatments.^[17] Considering the mentioned controversies, selection of an appropriate treatment plan should not be only based on one of the mentioned factors but dental and skeletal impacts of extraction and non-extraction orthodontic treatments

should be taken into account as well. It is important to find out which treatment plan best complies with patient's conditions.^[18] This study sought to assess dental arch length and width changes following non-extraction orthodontic treatment.

Materials & Methods

This retrospective descriptive analytical study was conducted on 100 dental records of patients (age 21 ± 0.5 years) with Class I malocclusion (non-ext treated by 0.18 roth system) and a total of 200 pairs of dental casts that met the inclusion criteria were selected from the archives of the Orthodontic Department of Shahid Beheshti Dental School. Sampling was census and non-randomized. The inclusion criteria were as follows:

1. Class I malocclusion
2. Presence of complete permanent dentition
3. Acceptable treatment outcome at the end of the treatment course
4. Availability of pre- and post-orthodontic treatment casts
5. Crowding range (5-9mm)

The exclusion criteria were as follows:

1. Congenital missing
2. Facial asymmetry
3. Orthodontic treatment along with tooth stripping
4. Orthodontic treatment along with the use of adjunctive appliances such as Quad helix, functional appliances and rapid palatal expander.

The variables of this study were:

1. Inter-canine width: defined as the linear distance between the cusp tips of the right and left canines in each arch
2. Inter-first premolar width: defined as the linear distance between the buccal cusp tips of the right and left first premolars in each arch
3. Inter-second premolar width: defined as the linear distance between the buccal cusp tips of the right and left second premolars in each arch
4. Inter-first molar width at MBCT: defined as the linear distance between the mesio-buccal cusp tips of first molars in each arch
5. Inter-first molar width at DBCT: defined as the linear distance between the disto-buccal cusp tips of first molars in each arch
6. Incisor-canine distance: defined as the linear distance between the midpoint of the incisal edge of

central incisor and cusp tip of canine tooth in the right and left quadrants

7. Canine-molar distance: defined as the linear distance between the canine cusp tip and disto-buccal cusp tip of the first molar in the right and left quadrants
8. Incisor-molar distance: defined as the linear distance between the midpoint of the incisal edge of the central incisor and the disto-buccal cusp tip of the first molar in the right and left quadrants
9. Total arch length: defined as the sum of incisor-canine and canine-molar distances of both quadrants of each jaw

The variables were measured using a digital caliper with the accuracy of 0.1 mm. Each measurement was repeated twice with a 2-day interval time. If the difference between the two measurements was greater than 0.1 mm, a third measurement was made and the mean of the three values was calculated and recorded.

Data were statistically analyzed using SPSS version 18 software. The mean and standard deviation of each variable were calculated. Kolmogorov-Smirnov test was applied to determine the distribution of data. Two-tailed t-test was used for evaluation of changes before and after treatment. Type I error (α) was considered as 0.05 and if type II error was smaller than 0.05 mm, the difference was statistically significant.

Results

According to results non-extraction orthodontic treatments significantly increased the inter-canine width in the maxilla (Mean=0.88, SD=1.64). Mandibular inter-canine width also increased (Mean=0.05, SD=1.72) but this increase was not statistically significant. The inter-premolar width (both first (Maxilla Mean: 2.07, SD: 2.07) (Mandible Mean: 0.48, SD: 2.09) and second (Maxilla Mean: 2.03, SD: 2.13 (Mandible Mean: 1.18, SD: 2.45)) premolars) also increased significantly in both maxilla and mandible as the result of non-extraction treatment. The inter-molar width at MBCT (Maxilla Mean: 1.12, SD: 1.69) (Mandible Mean: 1.05, SD: 1.70) and DBCT (Maxilla Mean: 0.67, SD: 1.48) (Mandible Mean: 0.91, SD: 1.83) in both jaws experienced a significant increase as well. The incisor-canine distance at both quadrants of the maxilla and mandible increased but this increase only in the maxillary left quadrant (Mean: 0.53, SD: 1.11) was statistically significant. The increase in canine-molar distance was statistically significant in all areas except for the right maxilla (Mean: 0.19, SD: 1.49). A significant increase was also noted in incisor-molar

distance in both quadrants of the maxilla (Mean 0.94, SD: 1.88) and mandible (Mean: 0.92, SD: 2.12) as the result of non-extraction orthodontic therapy. The total arch length in both jaws significantly increased, too (Maxilla Mean: 1.67, SD: 3.15 and Mandible Mean: 1.14, SD: 3.55). In the next step, the following schematic views were drawn using the obtained mean values for inter-canine width, inter-molar width, incisor-canine length, canine-molar length and incisor-molar length. Figures 1 and 2 are shown the overall arch shape before and after non-extraction orthodontic treatment.

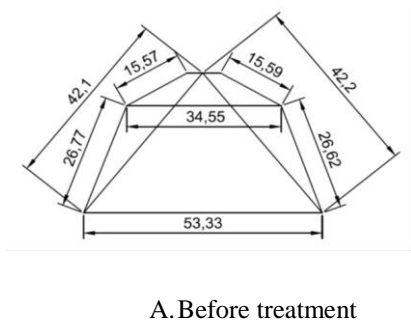


Figure 1. Schematic view of the maxillary arch

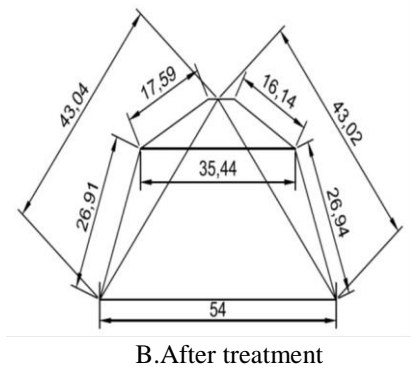


Figure 2. Schematic view of the mandibular arch

The pre- and post-treatment images were superimposed and evaluated as demonstrated in figure 3. As observed in figure 3 and 4, both jaws experienced an expansion as the result of non-extraction orthodontic treatment

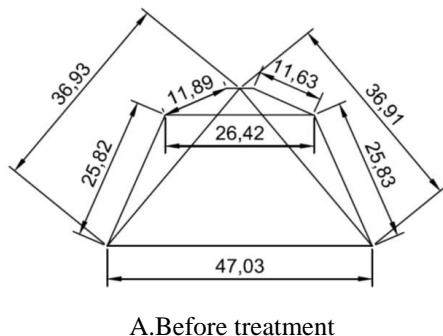


Figure 3. Schematic view of dimensional changes of the jaws before and after treatment

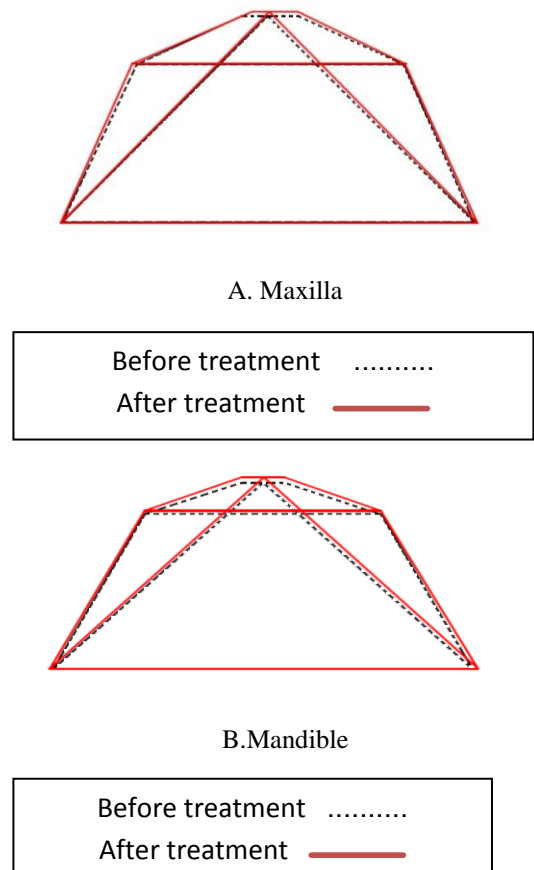


Figure 4. Schematic view of dimensional changes of maxilla & mandible before and after treatment

Discussion

The importance of dimensional changes of the arch due to orthodontic therapy and their role in choosing an appropriate treatment plan has been well documented and discussed in several studies. Based on our obtained results, non-extraction orthodontic treatment expanded the inter-canine width in both jaws. However, this increase was only statistically significant in the maxilla.

Inter-first premolar width and inter-second premolar width increased in both the maxilla and mandible (compared to baseline values) after non-extraction orthodontic treatment. This increase in both jaws was statistically significant. Furthermore, the inter-first molar width at MBCT and DBCT significantly increased in both jaws compared to the baseline values. In general, this study demonstrated that non-extraction orthodontic treatment caused a significant increase in all arch width dimensions except for the mandibular inter-canine width. Also, comparison of the drawn schematic views in terms of the pre- and post-treatment mean values indicates flaring of the teeth in both jaws. Similar results were obtained by Bishara et al.^[2], Isik et al.^[19], Taner et al.^[20], Kim et al.^[21], Aksuet al.^[22]

The results of Bishara et al.^[2] are in accord with our findings. The only difference is that the understudy subjects in our study had Class I malocclusion; whereas Bishara evaluated Class II div 2 patients in two groups of males and females. Furthermore, Bishara concluded that post-treatment alterations had a similar trend in males and females.

Taner et al.^[20] evaluated dimensional changes of the dental arch (width and form) in 21 Class II div 2 patients after non-extraction orthodontic treatment. They applied a new, accurate computerized method and obtained results completely similar to the present study. They demonstrated that non-extraction orthodontic treatment increased the maxillary and mandibular inter-canine widths but this increase only in the maxilla was statistically significant; which is in concord with our finding. Also, the arch width at the first and second premolars and first permanent molar region experienced a significant increase due to non-extraction orthodontic treatment.

Our obtained results also confirmed those of Isik et al.^[19] They evaluated a total of 84 patients; out of whom, 42 were treated with the non-extraction way, 15 were treated through non-extraction along with rapid maxillary expansion (RME) and 27 underwent extraction of first premolars. They noticed that the maxillary inter-canine width and the arch width at the first and second premolars and first molar region of both jaws increased significantly in the non-extraction group. As expected, the magnitude of this increase was significantly greater in subjects who underwent RME.

Gianelly et al.^[23] evaluated 50 CLI, CLII and CLIII patients (25 patients treated without extractions and 25 treated by extraction of four first premolars) and

concluded that the mandibular inter-canine dimension experienced a significant increase after the extraction treatment. They also showed an insignificant reduction in inter-molar width, whereas in our study the inter-molar width significantly increased as the result of non-extraction treatment. Differences between the two studies may be attributed to Gianelly's small sample size (25 patients in each group) and measurement of inter-second molar dimension instead of inter-first molar width. We tried to obtain more accurate results in our study by selecting a larger sample size and determining strict inclusion and exclusion criteria.

Concerning the changes in length caused by non-extraction orthodontic treatment, our study showed that although the incisor-canine distance at both right and left quadrants of the maxilla and mandible increased post-treatment, this increase only at the left maxillary quadrant was statistically significant. Canine-molar distance increased in both quadrants of the maxilla and mandible as the result of treatment as well and this increase was statistically significant at all areas except for the maxillary right quadrant. The incisor-molar distance experienced a significant increase, as expected, in both quadrants of the maxilla and mandible. Furthermore, total arch length significantly increased post-treatment in both jaws.

In a study by Heiser et al.,^[12] 25 patients who underwent non-extraction orthodontic treatment were compared with 24 patients who underwent first premolar extractions. The total maxillary arch length significantly increased in the non-extraction group compared to the baseline value. Total mandibular arch length experienced an insignificant increase post-treatment. However, measurements made post-retention and at the follow up session, indicated a significant increase in mandibular arch length.

In the study by Al Sayagh et al's^[24] the incisor-canine distance increased in both males and females in the non-extraction treatment group but this increase only in the right maxillary quadrant was statistically significant. The canine-molar and incisor-molar distances increased in females but the obtained values only for the left maxilla were statistically significant. The reduction in canine-molar distance in men was not significant but the incisor-molar distance experienced a significant increase at both sides. The total arch length increased in both males and females but this increase only in the women's group was statistically significant. As mentioned earlier, the differences between the

results of the mentioned study and ours may be attributed to the Al Sayah's small sample size in both groups of men and women that reduced the internal consistency of the results.

Conclusion

Within the limitations of this study, it is concluded that Non-extraction orthodontic treatment increased all the variables, except for the mandibular inter-canine width and incisor-canine distance.

Acknowledgments

This study is the result of the thesis performed by Dr Mahsa sobhi Afshar under Dr. Ebadifar supervision and granted by Dentofacial Deformities Research Center, Research Institute of Dental Sciences, Shahid Beheshti University of Medical Sciences, Tehran, Iran.

Authors' Contribution

The study was designed by Mahsa sobhi Afshar. The study data were collected by Mahsa sobhi Afshar. Analysis and interpretation of data, drafting of the manuscript and critical revision of the manuscript for important intellectual content were pre-formed by Asghar Ebadifar. Study supervision was performed by Asghar Ebadifar.

References

1. Brodie AG. Does scientific investigation support the extraction of teeth in orthodontic therapy? *Am J Orthod Oral Surg* 1944-45; 42:61-77.
2. Bishara SE, Bayati P, Zaher AR, Jakobsen JR. Comparisons of the dental arch changes in patients with Class II, Division 1 malocclusions: extraction vs nonextraction treatments. *Angle Orthod* 1994; 64:351-8.
3. Case CS. The question of extraction in orthodontia (1911 debate). *Am J Orthod* 1964; 50:658-91.
4. Proffit WR, Fields HW. Contemporary orthodontics. 6th ed. St Louis: The C.V. Mosby Company; 1986. p. 455-70.
5. Riedel R, Joondeph DR. Retention. In: Graber TM, Swain F, editor. Current orthodontics: concepts and techniques. 2th ed. Philadelphia: W.B. Saunders; 1975. p. 1095-137.

6. Baumrind S, Korn EL, Boyd RL, Maxwell R. The decision to extract: part 1—interclinician agreement. *Am J Orthod Dentofacial Orthop* 1996; 109:297-309.
7. Proffit WR., Fields HW, Sarver DM. Contemporary orthodontics. 4th ed. St Louis: C.V. Mosby; 2007. p.4,5.
8. Garber LW, Vanarsdall RL Jr, Vig KW. Orthodontics: Current principles and techniques. 5th ed. Philadelphia: Elsevier Mosby; 2012. p.21.
9. Tweed CH. The application of the principles of the edgewise arch in the treatment of malocclusions I, II. *Angle Orthod* 1941; 11:5-11,5-67.
10. Tweed CH. Indications for the extraction of teeth in orthodontic procedures. *Am J Orthod Oral Surg* 1944-45; 42:22-45.
11. Tweed CH. Clinical orthodontics. St. Louis: C.V. Mosby pub ; 1966, Vol 1. p. 6-82.
12. Heiser W, Niederwanger A, Bancher B, Bittermann G, Neunteufel N, Kulmer S. Three-dimensional dental arch and palatal form changes after extraction and nonextraction treatment. Part 1. Arch length and area. *Am J Orthod Dentofacial Orthop* 2004; 126:71-81.
13. Dierkes JM. The beauty of the face: an orthodontic perspective. *J Am Dent Assoc* 1987; 89E-95E.
14. Spanl TJ, Witzig J W. The clinical management of basic maxillofacial orthopedic appliances. Littleton, Massachusetts: PSG Publishing Company Inc; 1987. Vol. 1. p. 161-216.
15. Witzig JW, Spahl RJ. The clinical management of basic maxillofacial orthopedic appliances. Littleton, Massachusetts: PSG Publishing Company Inc; 1987. Vol. 1. p. 1-13.
16. Germane N, Lindauer SJ, Rubenstein LK, Revere JH Jr, Isaacson RJ. Increase in arch perimeter due to orthodontic expansion. *Am J Orthod Dentofacial Orthop* 1991; 100:421-7.
17. Shields TE, Little RM, Chapko MK. Stability and relapse of mandibular anterior alignment: a cephalometric appraisal of first-premolar-extraction cases treated by traditional edgewise orthodontics. *Am J Orthod* 1985; 87:28-38.
18. Basciftci FA, Usumez S. Effects of extraction and nonextraction treatment on class I and class II subjects. *Angle Orthod* 2003; 73:36-42.
19. İşik F, Sayinsu K, Nalbantgil D, Arun T. A comparative study of dental arch widths: extraction and non-extraction treatment. *Eur J Orthod* 2005; 27:585-9.

20. Taner TU, Ciger S, El H, Germeç D, Es A. Evaluation of dental arch width and form changes after orthodontic treatment and retention with a new computerized method. *Am J Orthod Dentofacial Orthop* 2004; 126:464-76.
21. Kim E, Gianelly AA. Extraction vsnonextraction: arch widths and smile esthetics. *Angle Orthod* 2003;73:354-8.
22. Aksu M, Kocadereli I. Arch width changes in extraction and nonextraction treatment in class I patients. *Angle Orthod*2005;75:948-52.
23. Gianelly AA. Arch width after extraction and nonextraction treatment. *Am J Orthod Dentofacial Orthop* 2003; 123:25-8.
24. Al-Sayagh NM. Maxillary Arch Dimensional Changes in the Extraction and Non Extraction Orthodontic Treatment. *Al-Rafidain Dent J* 2008; 8: 26-37.