

See discussions, stats, and author profiles for this publication at: <https://www.researchgate.net/publication/42369521>

# Double plate osteosynthesis provides better biomechanical stabilization than double tension band technique in distal humerus fractures

Article · April 2010

Source: PubMed

CITATIONS

6

READS

221

6 authors, including:



Yunus Dogramaci

Mustafa Kemal University

47 PUBLICATIONS 397 CITATIONS

SEE PROFILE



Erdinç Esen

Gazi University

37 PUBLICATIONS 270 CITATIONS

SEE PROFILE

Some of the authors of this publication are also working on these related projects:



Detection of adhesin genes and slime production among Staphylococci in orthopaedic surgical wounds [View project](#)



Ulnar artery stenosis [View project](#)



## Double plate osteosynthesis provides better biomechanical stabilization than double tension band technique in distal humerus fractures

Humerus distal kırıklarında çift plak osteosentezi, çift gergi bandı tekniğinden daha iyi biyomekanik stabilizasyon sağlar

Yunus Dođramacı, M.D.,<sup>1</sup> Erdinç Esen, M.D.,<sup>2</sup> Mustafa Kürklü, M.D.,<sup>3</sup> Yalçın Kırıcı, M.D.,<sup>4</sup>  
Ali O. Atahan, PhD.,<sup>5</sup> Mahmut Kömürcü, M.D.,<sup>3</sup>

<sup>1</sup>Department of Orthopedics and Traumatology, Medical Faculty of Mustafa Kemal University, Antakya, Hatay, Turkey

<sup>2</sup>Department of Orthopedics and Traumatology, Medical Faculty of Gazi University, Ankara, Turkey

Departments of <sup>3</sup>Orthopedics and Traumatology, <sup>4</sup>Anatomy, Gülhane Military Medical School, Ankara, Turkey

<sup>5</sup>Departments of Engineering, Mustafa Kemal University, Antakya, Hatay, Turkey

**Objectives:** In this study we evaluated the stability and effectiveness of the double tension band osteosynthesis technique compared to the double plate osteosynthesis technique used for fixation of distal humerus fractures.

**Materials and methods:** The study was performed on two groups, and in each group eight cadaveric, elderly (mean age 70-80) human humeri was used. An osteotomy was performed in the supracondylar region using a manual saw. The first group (group 1) was fixed with double 3.5 mm reconstruction plates, while the second group (group 2) was fixed with the double tension band technique, using crossing Kirschner wires. The osteotomy was designed so that the distal fragment would allow only a single screw per plate. The constructs were evaluated using a material testing machine. A linear non-cyclic load was applied until the failure of the constructs. The force which produced a 3 mm gap (3 mm gap strength), as detected visually with the aid of operating loupes, and the maximum load prior to failure of the fixation (maximum force) were measured from all tests.

**Results:** The mean value for the 3 mm gap strength was 1356.29±226.97 N for group 1 and 882.63±305.21 N for group 2. The mean value of the maximum load strength was 1487.13±298 N for group 1 and 1232±107.62 N for group 2. There were significant differences in 3 mm gap strengths of the two groups (p=0.005). There was also a significant difference in the maximum load between the two groups (p=0.016).

**Conclusion:** Double plate osteosynthesis technique is superior to double tension band osteosynthesis for the fixation of distal humerus fractures.

**Key words:** Biomechanics; distal humerus; fractures; osteosynthesis.

**Amaç:** Bu çalışmada humerus distal kırıklarının fiksasyonunda uygulanan çift gergi bandı osteosentez tekniği ile çift plak osteosentez tekniği stabilite ve etkinlik açısından değerlendirildi.

**Gereç ve yöntemler:** Çalışma, iki grup üzerine yapıldı ve her bir grupta sekiz adet, insan (ortalama yaş 70-80) kadavra humerus kemiği kullanıldı. El testeresi kullanılarak suprakondiler bölgeden osteotomi uygulandı. Birinci grup (grup 1) çift 3.5 mm'lik rekonstrüksiyon plakları ile tespit edildi. İkinci grup (grup 2), çapraz Kirschner telleri kullanılarak çift gergi bandı tekniği ile tespit edildi. Osteotomi tasarımı, distal parçaya sadece bir adet vida konulmasına izin verdi. Örnekler, materyal test makinesi kullanılarak değerlendirildi. Yetmezlik noktasına kadar, doğrusal yük uygulandı. Üç milimetre aralık oluşturan (3 mm ayrışma gücü) güç ve yetmezlik öncesi maksimum yükleme gücü, büyütücü kullanılarak tüm testlerde ölçüldü.

**Bulgular:** Üç milimetre ayrışma gücünün ortalama değeri, grup 1 için 1356.29±226.97 N ve grup 2 için 882.63±305.21 N bulundu. Maksimum yükleme gücünün ortalama değeri grup 1 için 1487.13±298 N ve grup 2 için 1232±107.62 N bulundu. İki grup arasında, 3 mm ayrışma gücünde anlamlı fark (p=0.005) vardı. İki grup arasında, maksimum güçte de anlamlı fark (p=0.016) vardı.

**Sonuç:** Humerus distal kırık fiksasyonunda çift plak osteosentez tekniği, çift gergi bandı osteosentez tekniğinden daha üstündür.

**Anahtar sözcükler:** Biyomekanik değerlendirme; distal humerus; kırık; osteosentez.

Surgical treatment of distal humerus fractures in the elderly remains one of the demanding challenges in trauma surgery.<sup>[1-3]</sup> For most displaced unstable fractures in patients with functional arms, open reduction and internal fixation (ORIF) with early mobilization is indicated to restore optimal elbow function.<sup>[3-7]</sup> It is difficult to achieve a secure fixation in an elderly patient with low supracondylar fractures because of inadequate space for screw fixation and bad screw purchase in osteoporotic bone.<sup>[3,8]</sup> Comminution and poor bone quality can even make these cases more difficult.<sup>[9]</sup> Loss of fixation, non-union, and stiffness may occur in up to 35% of cases.<sup>[10,11]</sup> Early rehabilitation and mobilization is difficult because of the lack of rigid fixation. Furthermore, the long period of immobilization required can result in unsatisfactory elbow function.<sup>[3,12]</sup>

Double plating is the standard approach for complex supracondylar distal humerus fractures, and provides sufficient stability for early rehabilitation.<sup>[13]</sup> Nonsurgical treatment is appropriate for stable, nondisplaced fractures and in patients with neurologic impairment or otherwise non-functional extremities.<sup>[14]</sup> External fixation can be used for either temporary or definitive treatment in patients with severely contaminated open wounds or extensive soft-tissue defects.<sup>[15]</sup> In older patients with osteopenia and/or comminution of the joint surface in which stable reconstruction cannot be achieved, total elbow arthroplasty using a semi-constrained linked prosthesis may be preferable to other options.<sup>[16]</sup>

Some authors reported the use of double tension band osteosynthesis for fixation of the distal humeral and intra-articular bicondylar fractures.<sup>[17,18]</sup> So far, there is no biomechanical study comparing the effectiveness of this method to double plate osteosynthesis. We assume that the double plate fixation will stabilize distal humerus fractures better than double tension band osteosynthesis.

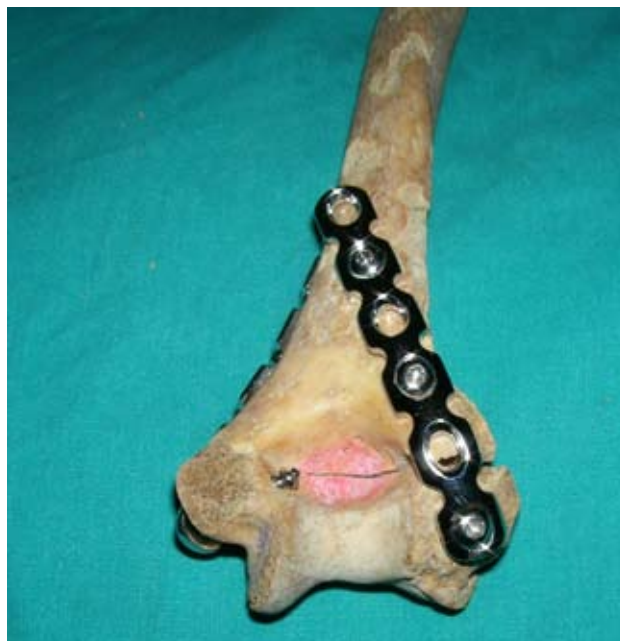The aim of this study was to test and compare the biomechanical stability of double tension band osteosynthesis technique to that of the double plate fixation technique in cadaveric supracondylar humerus fractures.

## MATERIALS AND METHODS

Sixteen elderly cadaveric humeri, with an average age of 72.6 (ranged from 70 to 80), were used in

the laboratory experiments. X-rays of all humeri were taken to exclude any pathology or previously treated fractures. Specimens were randomly divided into two groups. The first group (group 1) contained eight humeri treated with double plate fixation. The second group (group 2), also consisting of eight humeri, was treated with double tension band osteosynthesis. Using a manual saw, a transverse humeral osteotomy was performed in each specimen in the most distal extra-articular part of the bone. The fracture model was standardized to allow only a single screw per plate at the distal fragment. In group 1, the humeri were fixed using two (3.5 mm) reconstruction plates (Tipmed, Ltd. Co., İzmir, Turkey), one on the medial aspect and the other on the posterior lateral aspect of the bone (Figure 1). In group 2, the osteotomy site was fixed using 2 mm crossing Kirschner wires (K-wire) on each side, from the nonarticular medial side to the opposite lateral column and from the lateral side to the opposite medial column. Then tension wires were used to tauten both medial and lateral columns and to achieve compression (Figure 2).

Materials Testing Machine (model TIRA test 24500; Demgen, Werkzeugbau, GmbH, Nordrhein-Westfalen, Germany) was used for mechanical testing (Figure 3). All specimens were loaded to their



**Figure 1.** Fixation of the osteotomy site using double plate osteosynthesis. Single screw in the distal fragments was used.



**Figure 2.** Fixation of the osteotomy site using double tension band osteosynthesis technique.

failure point at a static rate of 40 mm/minute and force versus displacement data was recorded. The force which produced a 3 mm gap (gap load) as detected visually with the aid of operating loupes and the maximum force prior to failure of the con-

struct (maximum load) were determined from all tests.


Statistical analysis of the data was performed using the SPSS 13.0 version (SPSS Inc., Chicago, IL, USA) statistical package. We compared double plate osteosynthesis and double tension band osteosynthesis group parameter values with Mann Whitney U-test. Spearman rank coefficients of correlation were calculated to investigate the relations among the parameters. P value was set at  $p \leq 0.05$ . Data were presented as mean  $\pm$  standard deviation (Table I).

## RESULTS

There were no statistically significant differences in the length of the humeri. The mean value for the gap load was  $1356.29 \pm 226.97$  N for group 1 and  $882.63 \pm 305.21$  N for group 2. The mean value of the maximum load was  $1487.13 \pm 298$  N for group 1 and  $1232 \pm 107.62$  N for group 2.

Double plate fixation stabilized distal humerus fractures significantly ( $p < 0.05$ ) better than double tension band osteosynthesis (Table I). The double plate group had significantly higher maximum load ( $p = 0.016$ ) and gap load ( $p = 0.005$ ) values, respectively.

We found that there was a statistically significant correlation between maximum load and gap load ( $p = 0.001$ ).



**Figure 3.** Axial tension test using material testing machine. Lateral view of the distal humerus fixed with double tension osteosynthesis during test shows displacement at the osteotomy site.

**TABLE I**  
Descriptive statistics and comparisons of the results

Parameters	Group 1	Group 2	<i>p</i>
	Mean±SD	Mean±SD	
3 mm gap load (N)	1356.29±226.97	882.63±305.21	0.005
Maximum load (N)	1487.13±298.59	1232.00±107.62	0.016
Length of humeri (cm)	23.57±1.72	23.67±1.63	0.941

Group 1: Double plate osteosynthesis; Group 2: double tension band osteosynthesis technique; SD: Standard deviation.

## DISCUSSION

Double plating is the standard approach for complex supracondylar distal humerus fractures, and provides sufficient stability for early rehabilitation.<sup>[13]</sup> Tension band wiring on the other hand is thought to be an unstable fixation technique requiring early immobilization of the joint. We thought that a biomechanical analysis of distal humerus fracture fixation comparing these techniques would be beneficial for the treatment decision.

In literature dealing with biomechanical testing, the displacement at the fracture site and maximum load were utilized as the main parameters to show the main outcome.<sup>[19-21]</sup> The fixation methods that allow the least displacement at the fracture site are often regarded as superior.<sup>[20,21]</sup> Our results showed that the load required to produce gap at the osteotomy site were significantly higher in the double plate osteosynthesis than the double tension band osteosynthesis. It is well recognized that fracture movement leads to callus elongation and distraction. If the amount of strain caused by fragment movement during physical exercise is higher, the initial microstructure of the bridging tissues is repeatedly disrupted. As a result, the contribution of the callus formation to stabilizing the fracture is delayed.<sup>[22]</sup>

Higher tolerance to axial load diminishes the risk of fixation failure. In this study, the maximum load tolerated by the double plate osteosynthesis group was significantly higher compared to the double tension band osteosynthesis group. In addition, a significantly higher load was required to produce a failure of the bone-implant interface in double plate osteosynthesis than in double tension band osteosynthesis.

However, an important advantage of double tension band osteosynthesis is that it may prevent

forces which usually occur between the plate and the underlying cortex. Consequently, implant-related impairment of the periosteal blood supply is decreased.<sup>[22]</sup>

Previous clinical and biomechanical studies have demonstrated that double plate osteosynthesis provides a stable method of fixation in these fractures, especially when the plates are perpendicular to each other.<sup>[1,2]</sup> A study by Gabel et al.<sup>[5]</sup> has shown the superiority of the dual plate fixation over single plate fixation in adult intraarticular fractures of the distal humerus. In a biomechanical study, Molloy et al.<sup>[19]</sup> has shown that interference K-wire augmentation may make this method more stable in elderly. In another biomechanical study, Korner et al.<sup>[20]</sup> reported that configuration of plate is important and that better fixation achieved by using locking compression plates in elderly patients with diminished bone density. A study by Eralp et al.<sup>[4]</sup> has reported satisfactory results in 15 of 17 patients treated surgically using double plate osteosynthesis. However, the complex morphology of the distal humerus may not allow the perpendicular placement of the hardware and the often small distal fragments may allow only limited space for a single screw to be placed: as a result, sufficient fixation of low columnar fractures may be difficult, occasionally requiring addition of a third plate.<sup>[7,10]</sup>

In a study performed by Ali et al, the authors found that 75% of nonunions at the distal humerus were caused by inadequate primary fracture fixation. These results provide clear evidence that stable initial osteosynthesis is one of the main keys to avoid secondary interventions, prolonged immobilization and ultimately, to achieving a good functional outcome.<sup>[8]</sup>

Ring and Jupiter<sup>[23]</sup> reported that plating around the medial epicondyle may contribute to the

development of ulnar nerve dysfunction, as a result of ulnar nerve fibrosis secondary to scar formation and the fracture healing response, both of which can be minimized with anterior ulnar nerve transposition.

Russell et al.<sup>[24]</sup> recommend minifragment fixation construct, using 2.7 mm plates, for distal fracture fixation that is potentially compromised by very distal fractures, comminuted fractures, and in small stature patients in whom small fragment implants may be too large. Minifragment implants may provide enhanced fracture fixation because a greater number of screws can be placed into the distal fragments. In addition, minifragment plates are easier to contour and are less prominent. They reported late ulnar nerve neuritis and heterotopic ossification as complications of this method.

Zhao et al.<sup>[18]</sup> have shown good and excellent results in 83% of their patients using the double tension band osteosynthesis. Union obtained in all 24 patients and the complications were comparable to other techniques. They found that this technique is easier to perform, offers good stability, is more cost effective and allows earlier functioning of the elbow with complication rates that are comparable to other fixation methods. Houben et al.<sup>[17]</sup> used double tension band osteosynthesis instead of double plating for fixation of the condylar block to the shaft. They reported the advantages of double tension band wiring as a faster and easier procedure, with less periosteal and muscle damage, and symmetrical compression.

In this study, the intent was to prove the biomechanical stability of double tension band osteosynthesis and compare the results with the more invasive double plate osteosynthesis using cadaveric bones.

One of the limitations of this study is that the mineral density of the tested specimens was not measured using the dual energy X-ray absorptiometry (DEXA) method. Another limitation is in the measurement of the gap strength, as we measured the gap visually, using a magnifying loop instead of a displacement gauge or more accurate camera systems. This is an in-vitro study which tests the stability without taking the soft tissue components into account. The muscles, ligaments and other surrounding soft tissues in the elbow region have a great impact on the biomechanical behavior of

this fracture and on the long-term stability of the construct.

Understanding the exact contribution of the supporting ligaments to the functional integrity is crucial for the diagnosis and treatment.<sup>[25,26]</sup> A two-dimensional finite element study may be of great help in overcoming certain limitations of cadaver studies.<sup>[25,26]</sup>

The mechanical test setup simulated a tensile force across the fracture gap while the humerus is physiologically loaded in bending and in compression. The number of the cadaveric specimens in this study may not be sufficient so we recommend higher specimen numbers to evaluate this two different technique. This study may provide a clue in the treatment of such a difficult fracture by comparing the commonly used and recommended double plate osteosynthesis technique to the double tension band osteosynthesis.

In conclusion, double plate osteosynthesis provides better fixation for supracondylar humeral fracture compared to double tension band osteosynthesis. Double plate osteosynthesis should be the first choice for fixation of supracondylar humeral fractures.

## REFERENCES

1. Gupta R. Intercondylar fractures of the distal humerus in adults. *Injury* 1996;27:569-72.
2. Jupiter JB, Neff U, Holzach P, Allgöwer M. Intercondylar fractures of the humerus. An operative approach. *J Bone Joint Surg [Am]* 1985;67:226-39.
3. Korner J, Lill H, Müller LP, Hessmann M, Kopf K, Goldhahn J, et al. Distal humerus fractures in elderly patients: results after open reduction and internal fixation. *Osteoporos Int* 2005;16 Suppl 2:S73-9.
4. Eralp L, Kocaoglu M, Sar C, Atalar AC. Surgical treatment of distal intraarticular humeral fractures in adults. *Int Orthop* 2001;25:46-50.
5. Gabel GT, Hanson G, Bennett JB, Noble PC, Tullos HS. Intraarticular fractures of the distal humerus in the adult. *Clin Orthop Relat Res* 1987;216:99-108.
6. Jupiter JB, Mehne DK. Fractures of the distal humerus. *Orthopedics* 1992;15:825-33.
7. Jupiter JB, Barnes KA, Goodman LJ, Saldaña AE. Multiplane fracture of the distal humerus. *J Orthop Trauma* 1993;7:216-20.
8. Ali A, Douglas H, Stanley D. Revision surgery for non-union after early failure of fixation of fractures of the distal humerus. *J Bone Joint Surg [Br]* 2005;87:1107-10.
9. Waddell JP, Hatch J, Richards R. Supracondylar fractures of the humerus-results of surgical treatment. *J Trauma* 1988;28:1615-21.

10. Holdsworth BJ, Mossad MM. Fractures of the adult distal humerus. Elbow function after internal fixation. *J Bone Joint Surg [Br]* 1990;72:362-5.
11. John H, Rosso R, Neff U, Bodoky A, Regazzoni P, Harder F. Operative treatment of distal humeral fractures in the elderly. *J Bone Joint Surg [Br]* 1994;76:793-6.
12. McKee MD, Wilson TL, Winston L, Schemitsch EH, Richards RR. Functional outcome following surgical treatment of intra-articular distal humeral fractures through a posterior approach. *J Bone Joint Surg [Am]* 2000;82-A:1701-7.
13. Helfet DL, Schmeling GJ. Bicondylar intraarticular fractures of the distal humerus in adults. *Clin Orthop Relat Res* 1993;292:26-36.
14. Anglen J. Distal humerus fractures. *J Am Acad Orthop Surg* 2005;13:291-7.
15. Kömürçü M, Yanmış I, Ateşalp AS, Gür E. Treatment results for open comminuted distal humerus intra-articular fractures with Ilizarov circular external fixator. *Mil Med* 2003;168:694-7.
16. Cobb TK, Morrey BF. Total elbow arthroplasty as primary treatment for distal humeral fractures in elderly patients. *J Bone Joint Surg [Am]* 1997;79:826-32.
17. Houben PF, Bongers KJ, vd Wildenberg FA. Double tension band osteosynthesis in supra- and transcondylar humeral fractures. *Injury* 1994;25:305-9.
18. Zhao J, Wang X, Zhang Q. Surgical treatment of comminuted intra-articular fractures of the distal humerus with double tension band osteosynthesis. *Orthopedics* 2000;23:449-52.
19. Molloy S, Jasper LE, Burkhart BG, Brumback RJ, Belkoff SM. Interference Kirschner wires augment distal humeral fracture fixation in the elderly. *J Orthop Trauma* 2005;19:377-9.
20. Korner J, Diederichs G, Arzdorf M, Lill H, Josten C, Schneider E, et al. A biomechanical evaluation of methods of distal humerus fracture fixation using locking compression plates versus conventional reconstruction plates. *J Orthop Trauma* 2004;18:286-93.
21. Helfet DL, Hotchkiss RN. Internal fixation of the distal humerus: a biomechanical comparison of methods. *J Orthop Trauma* 1990;4:260-4.
22. Perren SM. Evolution of the internal fixation of long bone fractures. The scientific basis of biological internal fixation: choosing a new balance between stability and biology. *J Bone Joint Surg [Br]* 2002;84:1093-110.
23. Ring D, Jupiter JB. Complex fractures of the distal humerus and their complications. *J Shoulder Elbow Surg* 1999;8:85-97.
24. Russell GV Jr, Jarrett CA, Jones CB, Cole PA, Gates J. Management of distal humerus fractures with mini-fragment fixation. *J Orthop Trauma* 2005;19:474-9.
25. Seber S, Gökdemir H, Özçelik A, Günel İ, Aydın R, Köse N. A two-dimensional wrist model for carpal instability and force transmission. *Eklemler Hastalıkları Cerrahisi* 2008;19:127-32.
26. Bodzay T, Burján T, Bagdi C, Flóris I, Vendégh Z, Váradi K. Evaluation of stabilization methods of pelvic ring injuries by finite element modeling. *Eklemler Hastalıkları Cerrahisi* 2007;18:108-15.