

See discussions, stats, and author profiles for this publication at: <https://www.researchgate.net/publication/323820995>

# A significant danger to children: foreign body ingestion

Article · January 2018

DOI: 10.5455/jtomc.2018.02.029

CITATIONS

0

READS

49

3 authors, including:



**Ahmet Atici**

Mustafa Kemal University

24 PUBLICATIONS 4 CITATIONS

[SEE PROFILE](#)



**Çiğdem El**

Mustafa Kemal University

18 PUBLICATIONS 1 CITATION

[SEE PROFILE](#)

Some of the authors of this publication are also working on these related projects:



A significant danger to children: foreign body ingestion [View project](#)



Pyloric perforation due to stress disorders in an adolescent girl [View project](#)

# A significant danger to children: foreign body ingestion

Mehmet Emin Celikkaya<sup>1</sup>, Ahmet Atici<sup>1</sup>, Cigdem El<sup>2</sup>

<sup>1</sup>Mustafa Kemal University, Faculty of Medicine, Department of Pediatric Surgery, Hatay, Turkey

<sup>2</sup>Mustafa Kemal University, Faculty of Medicine, Department of Pediatrics, Hatay, Turkey

## Abstract

**Aim:** The most important way for children to communicate with their surroundings is to take every substance that they keep in hand to their mouths. Foreign bodies that are ingested can be found anywhere in the gastrointestinal tract. Especially foreign bodies in esophagus may be the cause of morbidity and mortality. For this reason, the ingestion of foreign bodies in children is one of the most important health problems.

**Material and Methods:** Between January 2014 and June 2017, 119 patients, admitted to Mustafa Kemal University [MKÜ] Faculty of Medicine, Department of Pediatric Surgery with foreign body ingestion diagnosis, were retrospectively studied. Patients were evaluated in terms of age, gender, complaints of arrival, ingested foreign body quality, location in the gastrointestinal tract and treatment approaches.

**Results:** Of the patients, 74 were males [62%] and 45 were females [38%]. The mean age of the patients was 4.3 years [6 months-15 years]. Foreign bodies most commonly seen in the esophagus first stenosis in 73 patients [61%]. Most commonly complaint at presentation was parental recognition of the ingested object and hypersalivation. The most commonly ingested foreign bodies included coins.

**Conclusion:** Esophagoscopy must be performed foreign bodies in the esophagus should be treated conservatively, in case of clinical suspicion, the possibility of foreign body ingestion must be kept in mind. Education of the parents and taking some precautions where the children play are the most important protective factors.

**Keywords:** Esophagus; Foreign Body; Children.

## INTRODUCTION

Every year, thousands of children in the world are brought to emergency services because they have ingested foreign bodies and at the same time thousands of children lose their lives for this reason (1). The most important way for children to communicate with their surroundings is to take every substance that they keep in hand to their mouths. For this reason, the ingestion of foreign bodies in children is usually observed between 6 months and 5 years (2, 3).

Anatomic obstruction sites in the gastrointestinal tract; upper, middle and lower strictures of the esophagus, pylorus, ileocecal valve and rectosigmoid colon (4). Ingested foreign bodies are usually attached to the esophagus first stenosis, which is the narrowest site of the gastrointestinal tract, and a foreign body, falling into the stomach, is usually considered to be spontaneously excreted through the anus (5, 6, 7). Foreign bodies seen in the gastrointestinal tract in children are listed as coins, small toys, magnets and batteries (8, 9). Immediate intervention may be required if corrosive substances such as

batteries are ingested. In this study, we studied 119 patients retrospectively.

## MATERIAL and METHODS

Between January 2014 and June 2017, 119 patients, admitted to Mustafa Kemal University (MKÜ) Faculty of Medicine, Department of Pediatric Surgery with foreign body ingestion diagnosis, were retrospectively studied. Patients were evaluated in terms of age, gender, complaints of arrival, ingested foreign body quality, location in the gastrointestinal tract and treatment approaches.

In children brought to our clinic with the complaint of foreign body ingestion, direct radiographs containing the entire gastrointestinal tract were taken. The cases, in which foreign bodies were detected in esophagus, were taken to esophagoscopy procedures under elective conditions. Patients were taken to emergency endoscopy if the ingested foreign body had perforating, cutting or burning characteristics. If the foreign body had passed to the distal of esophagus and did not show any clinical findings, the patient

**Received:** 15.02.2018 **Accepted:** 11.03.2018

**Corresponding Author:** Mehmet Emin Celikkaya, Mustafa Kemal University, Faculty of Medicine, Department of Pediatric Surgery, Hatay, Turkey, E-mail: eminctf@hotmail.com

was called out to the outpatient clinic for radiography every 3 days. Surgical procedures were not considered in patients who had no clinical complaints and observed to have foreign body replacement in their radiographs.

The interventions to all patients were performed in the operating room. Foreign bodies attached to the upper end of the esophagus or to the hypopharynx were removed with the help of a Magill clamp using the Storz 8402 zx brand videolaryngoscope. In cases which the foreign body cannot be reached by this way, foreign bodies were removed by performing rigid esophagoscopy with the Olympus Exera 2 CV180 camera. No procedures were performed on foreign bodies which went to stomach or more distal.

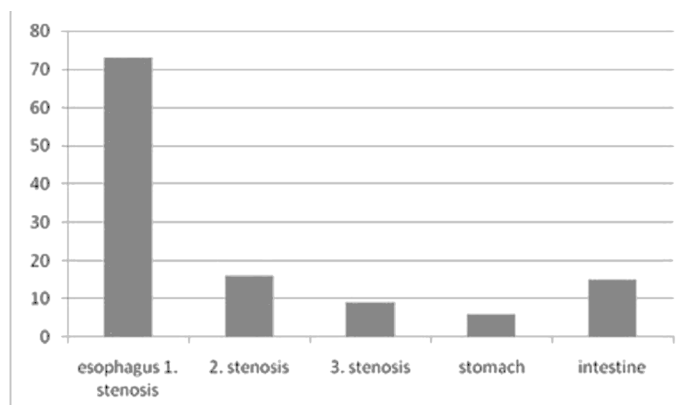
Rectoscopy was performed on two patients due to foreign bodies attached in the rectum (bone in one patient, brad in the other). All children who underwent endoscopy were observed for 4 hours postoperatively in terms of complication risk.

### RESULTS

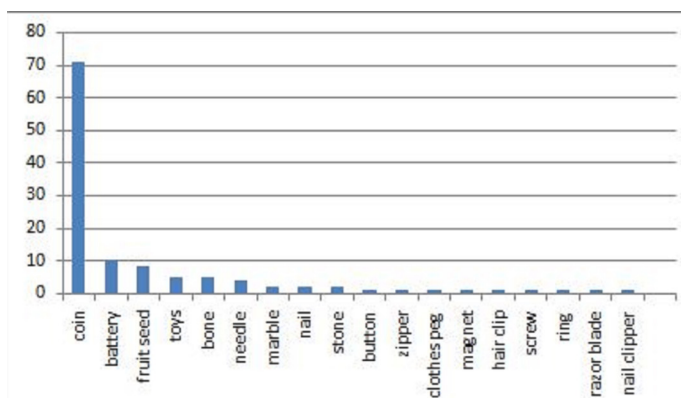
It was determined that between January 2014 and June 2017, a total of 119 patients were applied to the Department of Pediatric Surgery of the MKU Faculty of Medicine. Of the patients, 74 were males (62%) and 45 were females (38%). The mean age of the patients was 4.3 years (6 months-15 years). There were hypersalivation complaint in 22 patients (19%), ingestion difficulty in 16 patients (13%), pharyngeal hyperemia in 6 patients (5%), cough and dyspnea in 6 patients (5%). In one patient, a battery in esophagus was observed during esophagus dilatation, incidentally on endoscopy.

Foreign bodies were in the esophagus first stenosis in 73 patients (61%). Foreign bodies were observed in 16 patients (13%) in the esophagus second stenosis, in 9 patients (7%) in esophagus third stenosis, in 6 patients (5%) in the stomach and in 15 patients (13%) in the intestines (Table 1).

The most common of the ingested foreign bodies was found to be coin observed in 71 patients (60%). Battery in 10 patients (8%), fruit seed in 9 patients (7%), chicken bone in 5 patients (4%), plastic toys in 5 patients (4%), needles in 4 patients (3%), marble in 2 patients (1%), nail in 2 patients (1%), stone in 2 patients (1%), button in 1 patient (0.8%), zipper in 1 patient (0.8%), clothes peg in 1 patient (0.8%), magnet in 1 patient (0.8%), hair clip in 1 patient (0.8%), screw in 1 patient (0.8%), ring in 1 patient (0.8%), razor blade in 1 patient (0.8%), and nail clipper in 1 patient (0.8%) were observed (Table 2).



**Table 1.** Places where foreign bodies are found in the gastrointestinal tract



**Table 2.** The types of ingestion foreign body

While foreign bodies were removed with the help of videolaryngoscope under anesthesia from 70 patients (59%), rigid esophagoscopy was performed in 28 patients (23.5%). In one patient, laparotomy was performed in case it was observed that the nails showing persistence in the same place for two months. The nail was palpated in the colon and was removed from the anus by milking method. In one patient, sigmoidoscopy was performed after the bone fragment was found to be attached to the sigmoid bone for more than 72 hours. In a patient who was admitted to esophageal dilatation program for corrosive esophagitis, a battery was found incidentally in the esophagus second stenosis. A second-degree burn was observed in the esophagus. The oral intake was discontinued for 3 days and followed up. None of the patients observed to have permanent morbidity and mortality due to foreign body.

### CONCLUSION

Foreign bodies are usually being excreted by defecation without causing serious distress (10). In foreign bodies that are ingested, the first order is coin (11). In our study, the first order was also a coin. In a study conducted, it was said that the needle took the first order (12). In our study, the needle was in 6th place with 4 patients (3%).

When the anatomical regions that foreign bodies attached were examined, it was seen that the esophagus first stenosis was in the first place with 73 patients (61%). In the literature, it is seen that the most frequent location of being attached of foreign bodies is the first stenosis of the esophagus (13). The being attached of foreign bodies especially in the esophagus is important, because the absence of serosa of the esophagus and being located in the deepness of the thorax is the most important cause of serious complications (14). It has also been reported that foreign bodies can cause necrosis 6 hours after with the compression effect (15). Emergency removal is necessary, as the batteries can cause erosion and perforation, in particular.5 Depending on the content of the batteries, it may also lead to the findings of systemic toxicity (16). The complication rate of esophagoscopy is reported below 1% in the literature (17). In our clinic, all of the foreign bodies attached to the esophagus were removed with no complications, with a rigid esophagoscope or with a Magill forceps with video-laryngoscope assist.

It has been reported that endoscopic or surgical procedures are not required, since the batteries that has passed to stomach can be defecated (14, 18). In our clinic, intervention to foreign bodies falling in the stomach was not considered.

Foreign bodies passed to the small intestine are usually removed with spontaneous defecation. 2 In our study, all foreign bodies in the small intestines were followed. Only two cases that were attached to the colon were intervened.

All procedures performed on the patients were under anesthesia in the operating room. The removal of the foreign body by video-laryngoscope assisted Magill forceps was performed under slight sedation because of the very short duration; but endotracheal intubation was performed on patients in order to secure the airway, to those with a foreign body in the esophagus second and third stenosis, that cannot be reached with Magill forceps.

Since there is a procedure that takes less than 5 minutes even under mild sedation, if there is enough vision area for the foreign bodies in the esophageal first stenosis and upper part, removal should be attempted with Magill forceps. However, the patient should always be prepared to undergo esophagoscopy and it should be performed if it fails with a Magill forceps. For all foreign bodies located in the cervical esophagus, Magill forceps was used and succeeded.

Esophagoscopy should not be delayed because foreign bodies in the esophagus can cause vomiting and aspiration, as well as dyspnea with pressure on the trachea, especially in young children. There are publications that say that balloon extraction with Foley catheter is safely applied without giving the child anesthesia to remove foreign bodies; however, rigid esophagoscopy appears to be the safest and most successful method for removing esophageal foreign bodies so we preferred esophagoscopy rather than balloon extraction (5, 9, 18).

In our study, the number of cases that did not come out endoscopically or spontaneously and therefore required intervention was (1.6%) (2). In different studies this ratio has been reported between 0.5% and 5% (14, 19). As a result, esophageal foreign bodies must be removed endoscopically. Foreign bodies in the first stenosis and its proximal are easily, safely and quickly removed with Magill forceps. Rigid esophagoscopy is still the most reliable and successful treatment option for the removal of esophageal foreign bodies.

All foreign bodies passing the esophagus should be treated conservatively, in the presence of peritoneal irritation findings or in situations where foreign bodies remain in the same location for more than 48-72 hours, intervention is necessary (20). In non-radiopaque foreign bodies such as plastic beads or toys present a much more difficult radiographic challenge, the history that the family will give is important. In case of clinical suspicion, the possibility of foreign body ingestion must be kept in mind. In these cases, suspicion must be high enough to use diluted

contrast studies for the diagnosis. An esophagogram may demonstrate a foreign body as a filling defect (1).

As a result; education of the parents and taking some precautions where the children play are the most important protective factors.

## REFERENCES

1. Lelli Jr JL, Foreign Bodies. Holcomb GW MJ Ashcraft's Pediatric Surgery. Philadelphia. Fifth edition 2010. p. 135-43.
2. Arana A, Hauser B, Hachimi-Idrissi S, Vandenplas Y. Management of ingested foreign bodies in childhood and review of the literature. *Eur J Pediatr* 2001;160(8):468-72.
3. Lindahl H, Esophagoscopy and diagnostic techniques, Grosfeld JL, O'neill JA, Fonkalsfrud WE, Coran AG. *Pediatric Surgery*. Philadelphia. Sixth edition 2006. p. 1038-46.
4. Schwartz G, Polsky HS. Ingested foreign bodies of the gastrointestinal tract. *Am surg* 1976;42(4):236-8.
5. Morrow SE, Bickler SW, Kennedy AP, Snyder CL, Sharp RJ, Ashcraft KW. Balloon extraction of esophageal foreign bodies in children. *J Pediatr Surg* 1998;33(2):266-70.
6. Shepherd RL, Raffensperger JG, Goldstein R. Pediatric esophageal perforation. *J Thorac Cardiovasc Surg* 1977;74(2):261-7.
7. Köseoğlu B, Bakan V, Bilici S, Önem Ö, Katı İ, Demirtaş İ, et al. Çocukluk çağı gastrointestinal yabancı cisimlerinin tedavisi. *Van Tıp Dergisi*. 2001;8(2):47-53.
8. Kay M, Wyllie R. Pediatric foreign bodies and their management. *Curr Gastroenterol Rep* 2005;7(3):212-8.
9. Hawkins DB. Removal of blunt foreign bodies from the esophagus. *Ann Otol Rhinol Laryngol* 1990;99(12):935-40.
10. Sugawa C, Ono H, Taleb M, Lucas CE. Endoscopic management of foreign bodies in the upper gastrointestinal tract: A review. *World JGastrointest Endosc* 2014;6(10):475-81.
11. Waltzman ML, Baskin M, Wypij D, Mooney D, Jones D, Fleisher G. A randomized clinical trial of the management of esophageal coins in children. *Pediatrics* 2005;116(3):614-9.
12. Aydogdu S, Arikan C, Cakir M, Baran M, Yuksekkaya HA, Saz UE, et al. Foreign body ingestion in Turkish children. *Turk J Pediatr* 2009;51(2):127-32.
13. Brady PG. Esophageal foreign bodies. *Gastroenterol Clin North Am* 1991;20(4):691-701.
14. Macpherson RI, Hill JG, Othersen HB, Tagge EP, Smith CD. Esophageal foreign bodies in children: diagnosis, treatment, and complications. *AJR Am J Roentgenol* 1996;166(4):919-24.
15. Gershman G, Ament ME. Pediatric upper gastrointestinal endoscopy: state of the art. *Acta Paediatr Taiwan* 1999;40(6):369-92.
16. Kruk-Zagajewska A, Szmaja Z, Wojtowicz J, Wierzbicka M, Piatkowski K. [Foreign bodies in the esophagus]. *Otolaryngol Pol* 1999;53(3):283-8.
17. Olsen H, Lawrence W, Bernstein R. Fiberendoscopic removal of foreign bodies from the upper gastrointestinal tract. A simple and consistent method using a snare. *Gastrointest Endosc* 1974;21(2):58-60.
18. Sigalet D, Lees G. Tracheoesophageal injury secondary to disc battery ingestion. *J Pediatr Surg* 1988;23(11):996-8.
19. Cheng W, Tam PK. Foreign-body ingestion in children: experience with 1,265 cases. *J Pediatr Surg* 1999;34(10):1472-6.
20. A Al Qudah, S Daradkeh S, M Abu-Khalaf . Esophageal foreign bodies. *European journal of cardio-thoracic surgery*: 1998;13(5):494-9.