

## Morphologic Features of the Interdigital Sinus of the Tuj Sheep

Kadir ASLAN \*✍ İbrahim KÜRTÜL \*\* Mümtaz NAZLI \*\*\* Sevinç ATEŞ \*\*

- \* Faculty of Veterinary Medicine, Kafkas University, Department of Anatomy, TR-36100 Kars - TÜRKİYE  
\*\* Faculty of Veterinary Medicine, Mustafa Kemal University, Department of Anatomy, TR-31100 Hatay - TÜRKİYE  
\*\*\* Faculty of Veterinary Medicine, Kafkas University, Department of Histology-Embriology, TR-36100 Kars - TÜRKİYE

Makale Kodu (Article Code): KVFD-2009-1307

### Summary

This research, for the first time, documented the interdigital sinuses and their glandular structures of the fore- and hindfeet of the 10 Tuj sheep (5 male and 5 female) at gross and subgross and light microscopic levels. They were noted in all feet as peculiar tubular invaginations in-between the proximal and middle interdigital joints. The shape of the interdigital sinus resembles that of the pipe, composing of a narrow and long neck and a blind sac. The vascularization was through the 3rd and 4th palmar and dorsal digital arteries at the forefeet, and the 3<sup>rd</sup> and 4<sup>th</sup> plantar digital arteries at the hindfeet. The sinus was encircled with a thick capsule connected to the skin and the neighbor tissues through the connective tissue. On transversal section, there were numerous tenuous hairs clearly seen grossly on the section surface. Parenchyma and stroma units were observed in the interdigital gland. There were also hair follicles, sebaceous and sweat glands, muscle tissue and lymph follicles in the layer of the connective tissue. In this study, the morphological features of the interdigital sinuses and the glands that they contain was the first reported in the Tuj sheep. They were active in all feet, were supplied by different digital arteries and thus, it was supposed that the glands were very active on secretion.

**Keywords:** *Interdigital sinus, Tuj sheep, Morphology*

## Tuj Koyununda Sinus Interdigitalis'in Morfolojik Özellikleri

### Özet

Bu araştırma, 10 adet Tuj koyununa (5 adet erkek ve 5 adet dişi) ait ön ve arka ayaklarda sinus interdigitalis ve barındırdığı bezsel yapıları ilk kez gross, subgross ve ışık mikroskobu düzeyinde ortaya koymuştur. Araştırma sonucunda, bu yapıların tubular invaginasyonlar şeklinde üst ve orta ayak eklemleri arasında aktif bir şekilde lokalize oldukları belirlendi. Şekilleri ise dar ve uzun bir boyun ve bir kör kese ihtiva eden bir pipoya benzemektedir. Beslenmeleri ön ayakta 3. ve 4. a. digitalis palmaris ve a. digitalis dorsalis, arka ayakta ise 3. ve 4. a. digitalis plantaris'ler tarafından sağlanmaktadır. Yapılar, histolojik olarak, bağ doku komşu dokulara ve deriye tutturulan kalın bir kapsül ile çevrilmiştir. Transversal kesitte, gross olarak açıkça görülebilen çok sayıda ince kıllar görülmüştür. Interdigital bezde parenşim ve stroma üniteleri görüldü. Bağ dokuda kıl folikülleri, yağ ve ter bezleri, kas doku ve lenf foliküllerinin de varlığı tespit edildi. Bu çalışmada sinus interdigitalis ve bezin morfolojik özellikleri Tuj koyununda ilk kez ortaya çıkarıldı. Farklı digital arterler tarafından beslenen, bütün ayaklarda aktif olan interdigital sinuslerin bol miktarda sekresyon yapma özelliğinin olduğu kanaatine varıldı.

**Anahtar sözcükler:** *Interdigital sinus, Tuj koyunu, Morfoloji*

### INTRODUCTION

Tuj sheep is mainly raised in northeast Anatolia. Its body is covered with white wool, and while male has horn female does not. It is also called Tuchin in south of Russia, and Caucasia. It has a shorter and fatty tail <sup>1</sup>.

The interdigital sinus, also called interdigital pouch, in sheep is a peculiar tubular invagination of the skin which comprises mainly sebaceous and apocrine type glandular structures (GII. interdigitales). It is present



İletişim (Correspondence)



+90 474 2426807/1324



kadiraslan25@hotmail.com

both in the fore- and hind feet, discharging an oily substance at various viscosity and composition through a prominent orifice at the anterior aspect of the interdigital cleft <sup>2-6</sup>. The odorous nature of discharge is used as a trial marker or as sure-footedness by animals <sup>6-8</sup>. The odorous signals and pheromones produced by these scent glands have essential biological roles in the conspecific chemical messages including active territorial delimitation and in the manifestation of social behavior.

Development, location, shape, and function of the interdigital sinus and the glandular structures it contain, have been documented in various sheep and goat breeds <sup>2,4,9,10</sup>, and in some wild animals <sup>9,11-13</sup>.

This study has been performed to observe the interdigital sinus and the glandular structures it contains of fore- and hindfeet of the Tuj sheep at gross and light microscopic levels. Yet, there has been no literature report so far on revealing the morphological features of the interdigital glands.

## MATERIAL and METHODS

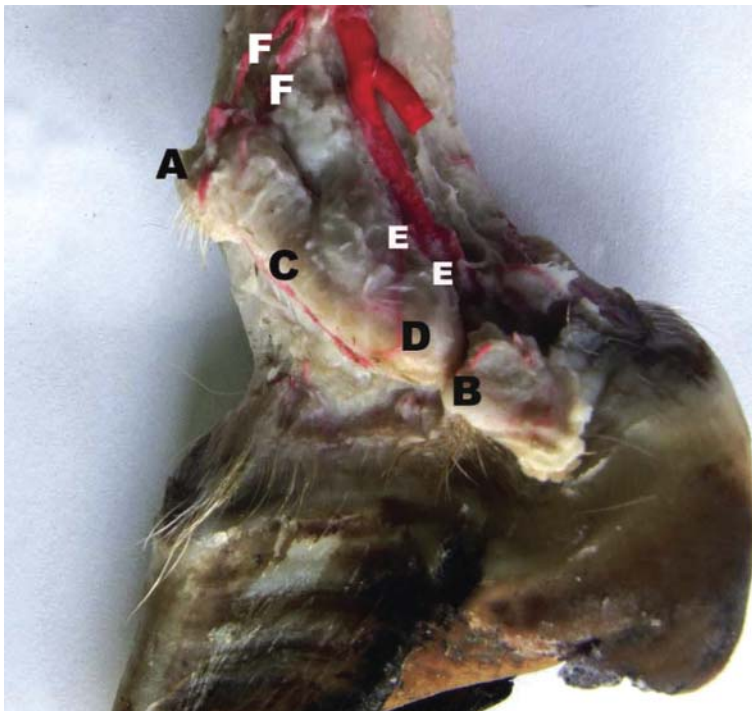
This study examined the interdigital sinuses and the glandular structures they contain of fore- and hindfeet of the 10 Tuj sheep (5 male and 5 female) at gross and subgross and light microscopic levels. The feet were provided from the Animal Breeding Exercise Research Centre of Kafkas University after slaughter for selling of meat and expenses of feeding. They were dissected and observed grossly and subgrossly, and were put in 10%

formaldehyde fixative solution at room temperature for further assessment. Nomina Anatomica Veterinaria <sup>14</sup> was employed for the anatomical nomenclature.

For histological examination, the tissue samples were fixed in 10% formaldehyde solution and routine tissue processing procedures were applied. The Triple Mallory staining modified by Crossman was applied to the 5 µm thick sections using the indicated method by Bancroft and Cook <sup>15</sup>. The sections were examined under light microscope.

## RESULTS

The interdigital sinus in all feet was potently present as a peculiar tubular invagination, located in-between the proximal and middle interdigital joints (*Fig 1 and 2*). At gross and subgross observations in all feet of sheep, there were neither side nor fore- hind-feet differences. There was also no sex variation determined at these levels. Its opening was observable grossly from dorsal aspect at the level of the proximal interdigital joint and at the level of the anterior part of the interdigital cleft (*Fig 1A and 2A*) while distal edge rested against the interdigital ligament (*Fig 1B and 2B*). On sagittal section, it resembled the shape of the pipe, composing of a narrow and long neck (*Fig 1C and 2C*) and a blind sac (*Fig 1D and 2D*). The sac and the neck were clearly distinguishable with a noticeable flexure. The sinus was encircled with a thick capsule connected to the skin and the neighbor tissues through the connective tissue. On transversal section, there were numerous tenuous hairs clearly seen grossly on the section surface.



**Fig 1.** Gross view of the interdigital sinus in the forefoot of the Tuj sheep **A:** Opening of the interdigital sinus; **B:** its attachment to the interdigital ligament; **C:** the neck; **D:** the sac; **E:** subbranches from the 3<sup>rd</sup> and 4<sup>th</sup> palmar digital arteries at the palmar aspect; **F:** subbranches from the 3<sup>rd</sup> and 4<sup>th</sup> dorsal digital arteries at the dorsal aspect

**Şekil 1.** Tuj koyunlarında ön bacak sinus interdigitalis'inin makroskobik görünümü **A:** Sinus interdigitalis'inin ağız açıklığı; **B:** Ligamentum interdigitalis'in yapıldığı yer; **C:** Boyun; **D:** Kese; **E:** 3. ve 4. A. digitalis palmaris'lerden ayrılan dalların ventral görünümü; **F:** 3. ve 4. A. digitalis dorsalis'lerden ayrılan dalların dorsal görünümü

### Arterial Vascularization

The interdigital sinuses of the forefeet were seen to nourish by the subbranches originating from the 3<sup>rd</sup> and 4<sup>th</sup> palmar digital arteries at the palmar aspect (Fig 1E) and from the 3<sup>rd</sup> and 4<sup>th</sup> dorsal digital arteries at the dorsal aspect (Fig 1F). There were 3-4 subbranches originated from the palmar digital arteries while 1-2 smaller subbranches from the dorsal digital ones. Likewise, the interdigital sinuses of the hindfeet received blood through subbranches from the 3<sup>rd</sup> and 4<sup>th</sup> plantar digital

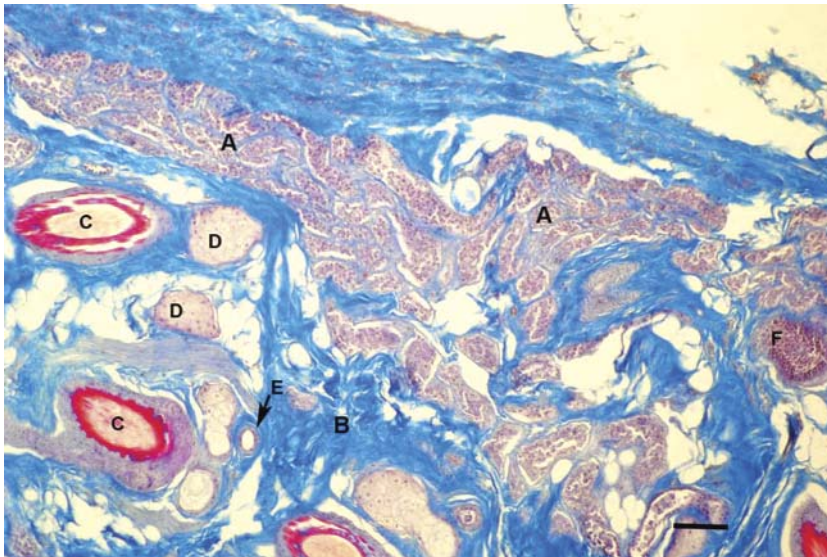
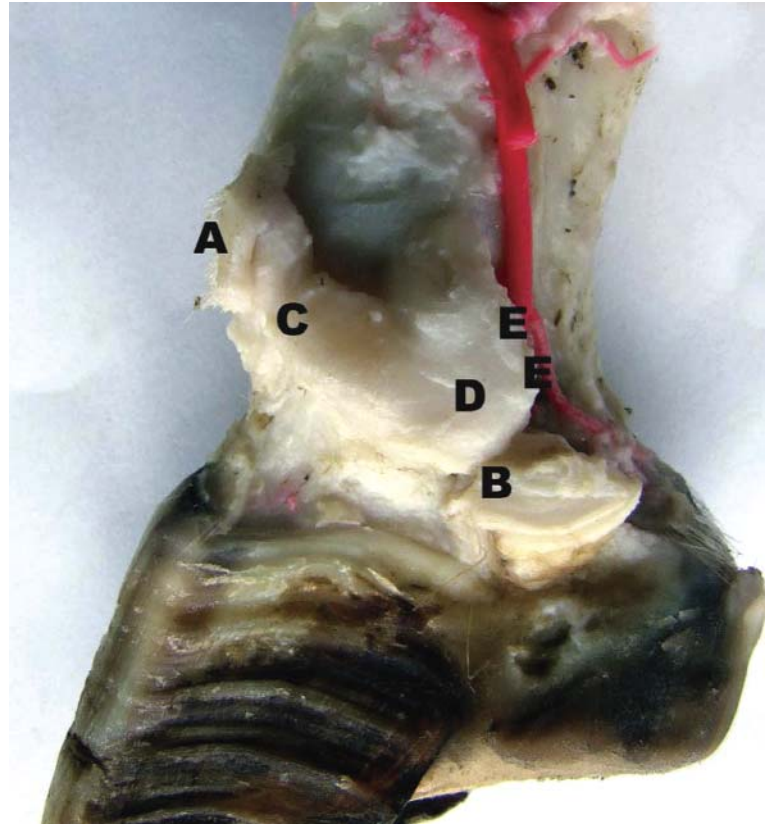
arteries at the plantar aspect (Fig 2E). The 3<sup>rd</sup> plantar digital artery gave 1-2 subbranches while the 4<sup>th</sup> one sent 2-3 subbranches for the vascularization of the gland.

### Histology

At light microscopic level, a thick connective tissue was observed externally. The glands producing secretion and their tubules were observed as the parenchyma (Fig 3A), and the stroma units surrounding the parenchyma being as the connective tissue (Fig 3B). Glandular epithelial cells

**Fig 2.** Gross view of the interdigital sinus in the hindfoot of the Tuj sheep **A:** Opening of the interdigital sinus; **B:** its attachment to the interdigital ligament; **C:** the neck; **D:** the sac; **E:** subbranches from the 3<sup>rd</sup> and 4<sup>th</sup> plantar digital arteries at the plantar aspect

**Şekil 2.** Tuj koyunlarında arka bacak sinus interdigitalis'inin makroskobik görünümü **A:** Sinus interdigitalis'inin ağız açıklığı; **B:** Ligamentum interdigitalis'in yapıştığı yer; **C:** Boyun; **D:** Kese; **E:** 3. ve 4. A. digitalis plantaris'lerden ayrılan dalların plantar görünümü



**Fig 3.** Light microscopic view of the interdigital glands of the Tuj sheep **A:** Parenchyma; **B:** Stroma as the connective tissue; **C:** Hair follicles; **D:** Sebaceous glands; **E:** Sweat glands; **F:** Lymph follicles. Scale bar: 200 µm

**Şekil 3.** Tuj koyunlarında interdigital bezlerin ışık mikroskopik görünümü **A:** Parenşim; **B:** Bağ doku stroması; **C:** Kıl folikülleri; **D:** Yağ bezleri; **E:** Ter bezleri; **F:** Lenf folikülleri. Bar: 200 µm



of the glands were oval in shape, possessing a nucleus located in the center. Moreover, in the layer of the epithelium, as seen in the dermis, there were hair follicles (Fig 3C), sebaceous glands (Fig 3D), sweat glands (Fig 3E), muscle tissue, and lymph follicles (Fig 3F).

## DISCUSSION

This research is the first to document the morphology of the interdigital sinus that comprises the interdigital glands in the Tuj sheep at gross and light microscopic levels, which is mainly raised in northeast Anatolia. Our findings have found that the interdigital sinuses in all feet are present, potent, and yet either of which is not a rudimentary organ even though they have been reported to be rudimentary in goats<sup>9,16</sup>. The glandular structures at gross and light microscopic levels are very similar to those reported by the literature<sup>6,17</sup>. The interdigital sinuses and their shapes were like a pipe possessing a narrow and long neck and a blind sac, as documented by the literature<sup>1-5</sup>.

As to our knowledge, there is no such literature report other than textbooks which mostly explain the arterial vascularization of the legs of the ovine superficially. This report is also the first that gathers detailed information on the vascularization of the interdigital sinuses in ovine. The branches arising from the 3<sup>rd</sup> and 4<sup>th</sup> palmar digital arteries and from the 3<sup>rd</sup> and 4<sup>th</sup> dorsal digital arteries, at the palmar and dorsal aspects, respectively, were the responsible for the nourishment at the forefeet while the interdigital sinuses of the hindfeet received their arterial vascularization from the 3<sup>rd</sup> and 4<sup>th</sup> plantar digital arteries at the plantar aspect. There seemed to be no subbranch supplying the sinuses from the dorsal side of the hindfeet.

Our histological observations, i.e, hair follicles, sebaceous glands, sweat glands, and muscle tissue, have indicated that the interdigital sinuses containing the glands were indeed peculiar tubular invaginations of the integument, which has also been yielded in the literature<sup>18</sup>. Likewise, the glandular structures observed in the Tuj sheep were mostly sebaceous and apocrine in nature. The presence of the potent interdigital sinus in all the feet and the glands comprising very active sebaceous ones suggest that this organ has a high activity of secretion in the Tuj sheep. Parillo and Diverio<sup>8</sup> have demonstrated that the interdigital tubular glands secreted neutral glycoproteins, containing hexoses with vicinal hydroxyls visualized with the PAS procedure, suggesting that the interdigital glands of the fallow deer may probably play only an accessory role in the production of odoriferous signals in fallow deer.

Consequently, this study is the first which reports the morphological features of the interdigital sinuses and the glands that they contain in the Tuj sheep. They were active in all feet, were supplied by the 3<sup>rd</sup> and 4<sup>th</sup> palmar and dorsal digital arteries at the forefeet, and by the 3<sup>rd</sup> and 4<sup>th</sup> plantar digital arteries at the hindfeet. Thus, the glands were very active on secretion.

## REFERENCES

- Akçapınar H:** Koyun yetiştiriciliği. 2. baskı. ISBN: 975-96978-1-5. İsmat Matbaacılık, Ankara, 2000.
- Çalışlar T:** Sinus interdigitalis'in morfolojik özellikleri. *Ankara Univ Vet Fak Derg*, 18 (1): 38-40, 1971.
- Sisson S, Grossman JD:** The Anatomy of the Domestic Animals. pp. 920-922. WB Saunders Company, Philadelphia and London, 1964.
- Taşbaş M:** Komparatif Veteriner Anatomi, Duyu Bilimi. s. 90. Ankara Univ Vet Fak Yay, No: 399, Ankara, 1985.
- Dursun N:** Veteriner Anatomi III. p. 198. Medisan Yayınevi, Ankara, 2000.
- Nickel R, Schummer A, Seiferle E:** The Anatomy of the Domestic Animals, Vol. 3: The circulatory system, the skin, and the cutaneous organs of domestic mammals. pp. 441-557. Verlag Paul Parey, Berlin, 1981.
- Karahan S, Yıldız D, Bolat D:** Scanning electron microscopic features of the ovine interdigital sinus. *Acta Vet Hung*, 55, 424-427, 2007.
- Epple G, Belcher AM, Küderling İ, Zeller U, Scolnick L, Greenfield KL, Smith AB:** Marking sense out of scents: species differences in scent glands, scent-marking behaviour, and scent-marking composition in the Callitrichidae. In, Rylands AB (Ed): Marmosets and Tamarins. pp. 124-151. Oxford University Press, Oxford, 1993.
- Parillo F, Diverio S:** Glycocomposition of the apocrine interdigital gland secretions in the fallow deer. *Res Vet Sci*, 86, 194-199, 2009.
- Bahadır A, Yakışık M:** Yerli kıl keçisinde sinus interdigitalis'in morfolojisi. *Uludağ Univ Vet Fak Derg*, 7, 87-92, 1988.
- Atoji Y, Yamamoto Y, Suzuki Y:** Morphology of the interdigital glands of a Formosan serow. *J Vet Med Sci*, 57, 963-964, 1995.
- Lamps LW, Smoller BR, Rasmussen REL, Slade BE, Fritsch G, Goodwin TH:** Characterisation of interdigital glands in the Asian elephant. *Res Vet Sci*, 71, 197-200, 2001.
- Wood WF:** Volatile components in metatarsal glands of sika deer. *J Chem Ecol*, 29, 2729-2733, 2003.
- International Committee on Veterinary Gross Anatomical Nomenclature:** General Assembly of the World Association of Veterinary Anatomists. Nomina Anatomica Veterinaria. 5<sup>th</sup> ed. Hannover, Columbia, Gent, Sappora, 2005.
- Bancroft JD, Cook HC:** Manual of Histological Techniques, Churchill Livingstone, London, 1984.
- Temizer M:** Ayak Hastalıkları, Veteriner Fakültesi Yayınları No: 204, Ankara Univ Basımevi, Ankara, 1967.
- Kozłowski GP, Calhoun ML:** Microscopic anatomy of the integument of sheep. *Am J Vet Res*, 30, 1267-1279, 1969.
- Eurell JA, Frappier BL, Dellmann HD:** Textbook of Veterinary Histology. Sixth ed., Blackwell Publishing Ltd, Ames, Iowa, USA, 2006.