

CASE REPORT

Unilateral Uterine Torsion in A Pregnant Bitch

Gökhan Doğruer¹, Ayşe Merve Köse^{1*}, Ece Koldaş Ürer¹, Azime Doğruer²

¹Mustafa Kemal Üniversitesi Veteriner Fakültesi, Klinik Bilimler Bölümü Doğum ve Jinekoloji Anabilim Dalı, Hatay, Türkiye

²Minik Dost Veteriner Kliniği, Hatay, Türkiye

Geliş:13.07.2017, Kabul: 25.12.2017

* aysemervekose@gmail.com

Gebe Bir Köpekte Unilateral Uterus Torsiyonu

Eurasian J Vet Sci, 2018, 34, 1, 60-64

DOI:10.15312/EurasianJVetSci.2018.181

Öz

Bu olgu sunumu gebe bir köpekte operasyon sezaryende belirlenen unilateral uterus torsiyonunun tanı ve tedavisini tanımlamaktadır. Olgunun materyalini iki gündür devam eden halsizlik, iştahta azalma ve kusma şikayeti olan; 34 kg ağırlığında 1 yaşlı kangal melezi bir köpek oluşturdu. Köpekte hafif bir halsizlik saptandı. Mukoz membranların rengi ve kapillar dolum zamanı, nabız ve solunum sayıları fizyolojik değerlerdeydi. Vücut ısısı 37.5°C idi. Vaginal muayenede kahverengi-yeşilimsi mukoid bir akıntı belirlendi. Ölçülen biyokimyasal değerleri fizyolojik sınırlar içerisindeydi. Ultrasonografik muayenede hem canlı hem ölü fütusların olduğu tespit edildi, yarım saat sonra tekrarlanan ikinci USG muayenede ölü fütüs sayısında artış belirlendi bu yüzden sezaryen operasyonuna karar verildi. Sağ kornu uteriden canlı iki erkek bir dişi yavru, sol kornu uteriden iki ölü dişi yavru çıkarıldı. Sol kornu uteride hiperemi, hemoraji ve fragilite ile birlikte bifirkasyon bölgesinin yakınında uzun eksenli boyunca 1800 derece torsiyon belirlendi. Sol kornu uterideki amnion sıvıları normalden chorioallantoik sıvılar hemarajikti. Total ovariohisterektomi operasyonu yapıldı. Sonuç olarak; uterus torsiyonu olguları halsizlik ve kusma gibi nonspesifik klinik bulgularla ortaya çıkabilir. Tekrarlayan ultrasonografik muayenede ölü yavru sayısının artması durumunda uterus torsiyonu düşünülmelidir. Sunulan olgudaki gibi cerrahi müdahale ile gebe hayvanın hayatı kurtarılabilmektedir.

Anahtar kelimeler: Dişi köpek, tek taraflı, uterus torsiyonu

Abstract

This report describes the diagnosis and treatment of a case of unilateral uterine torsion, which was detected at the caesarean section of a pregnant bitch. A one-year-old, 34 kg half-breed Kangal dog, with signs of apathy, anorexia and emesis for the past two days was the material of this case report. The dog only displayed a mild apathy. Mucous membranes colour, capillary refilling time, heart and respiratory rates were within the physiological ranges. The body temperature was 37.5°C. A mucoid brown-greenish coloured vaginal discharge was determined. The measured biochemical values fell within the physiological ranges. Both live and dead fetuses were determined ultrasonographically then the number of dead fetuses increased half an hour later on second ultrasonographic examination so it was decided to perform a caesarean section. One female and two male live fetuses from the right uterine horn and two dead female fetuses from the left uterine horn were removed. The left uterine horn displayed hyperaemia, haemorrhage and fragility with a 1800° torsion along its long axis, near the uterine bifurcation. The amniotic fluids appeared normal, the chorioallantoic fluid was haemorrhagic in the left horn. Total ovariohysterectomy was performed. The uterine torsion cases may be manifested with nonspecific clinical signs such as anorexia and emesis. In the event of increased number of dead fetuses in repeated ultrasonographic examination, the presence of uterine torsion should be considered. In such cases, the pregnant animal can be saved by surgical intervention, as was in this case study.

Keywords: Bitch, unilateral, uterine torsion



Uterine torsion is described as the twisting of the uterus in various forms and degrees, and is observed more frequently in cows and rarely in sheep, goats, dogs, cats and horses (Apaydın 2005). Feline and canine cases of uterine torsion are reported to be uncommon, to be observed during either gestation or labour, and to display a life-threatening acute clinical condition (Biddle and Macintire 2000, Thilagar et al 2005, Nak et al 2008, Murugavel et al 2013). While the main predisposing factor of uterine torsion is indicated as late gestation, it is reported that excessive foetal activity in the late gestation, premature uterine contractions, lack of uterine tone, lack of foetal fluids, partial abortion, ligament deformation at previous parturition, hereditary weakness of the ovarian and uterine ligaments, variances in the length and mobility of the uterus, hyperactivity of the pregnant animal involving jumping, running and rolling, and oxytocin administration also cause predisposition to uterine torsion (Kumru et al 2011, Kacprzak et al 2014).

Literature reports indicate that the severity of the clinical condition in cats and dogs suffering from uterine horn torsion depends on the degree of the torsion (Johnston et al 2001, Bekyurek and Macun 2013). It is indicated that patients may present with clinical signs of varying severity, ranging from nonspecific signs such as apathy, ataxia, anorexia and emesis to shock and even death (Kacprzak et al 2014). In cases of uterine torsion, early diagnosis is of vital importance (Forsberg 2015). The differential diagnosis of the disorder is based on both the clinical signs observed and the findings of the radiological and ultrasonographic examination of the abdomen (Johnston et al 2001). Radiological examination may reveal a fluid-filled distended uterus, foetal skeletons, and intrauterine or intrafoetal gas. On the other hand, ultrasonographic examination aids in detecting the presence of dead and/or alive fetuses (Kacprzak et al 2014). Treatment is performed by total or partial ovariohysterectomy (Kustritz 2006, Bekyurek and Macun 2013).

A one-year-old, 34 kg half-bred female Kangal dog, which was referred to the clinic of the Obstetrics and Gynaecology Department of Mustafa Kemal University, Faculty of Veterinary Medicine from a private veterinary clinic and was reported to have mated 63 days before its referral to the clinic, constituted the

Table 1. Results of serum biochemical parameters

Parametres	Results	Reference Range
ALT (IU/L)	28	10.0-88.0
AST (IU/L)	34	10.0-88.0
Calcium (mg/dL)	8.5	8.6-11.2
Creatinine (mg/dL)	0.64	0.5-1.5
Phosphorus (mg/dL)	4	2.2-5.5
Magnesium (mEq/L)	2.18	1.2-2.0
BUN (mg/dL)	11.2	12.0-25.0

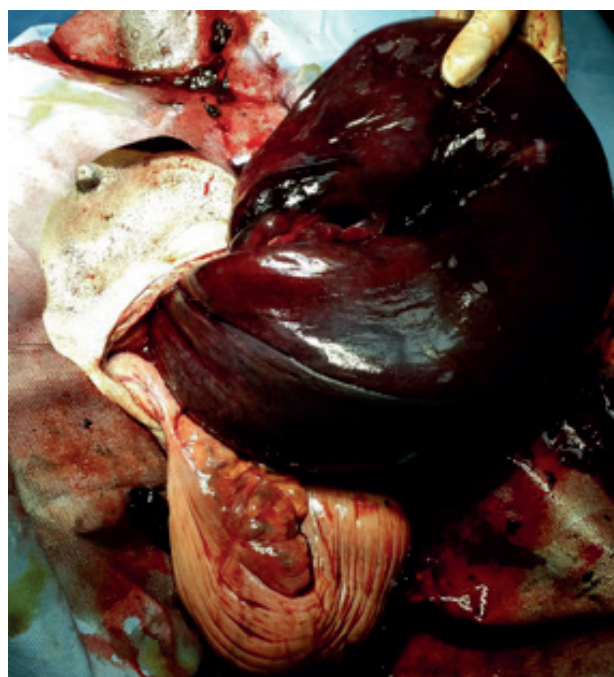


Figure 1. Congestion of left uterine horn

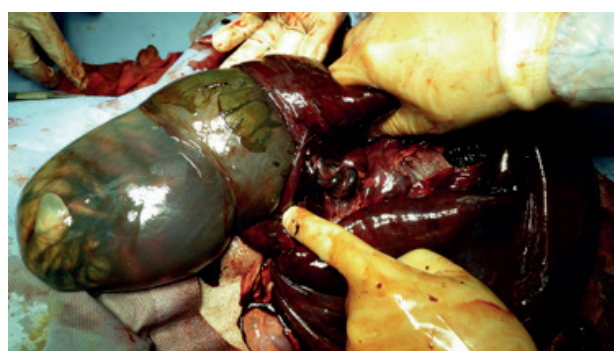

Figure 2. Removal of dead foetus from left uterine horn and hematometra

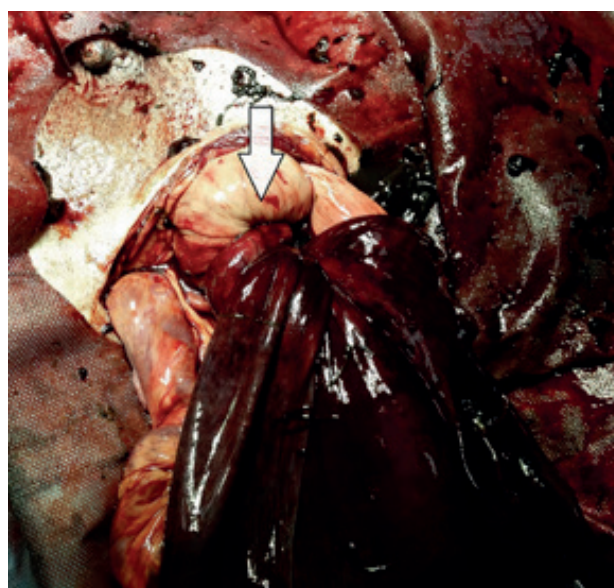


Figure 3. 180° torsion of left uterine horn (arrow)



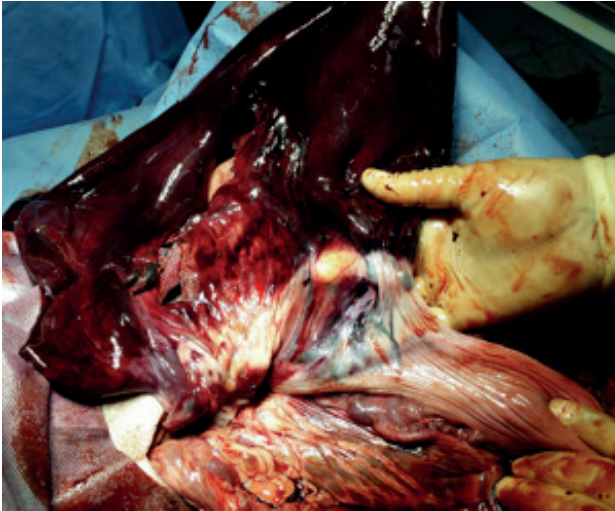


Figure 4. Uterus after torsion fixed

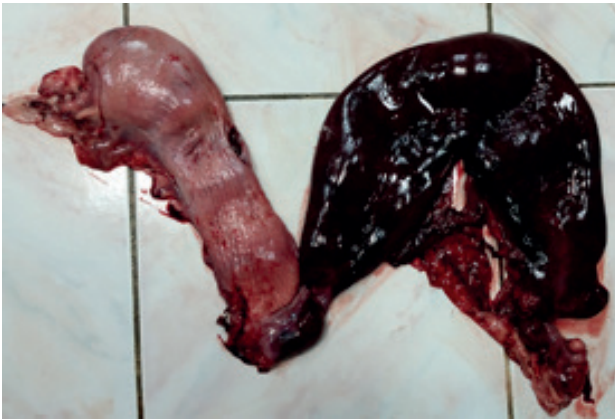

Figure 5. The view of uterus after ovariectomy and completion of surgery-1 yerine "The view of uterus after ovariectomy"

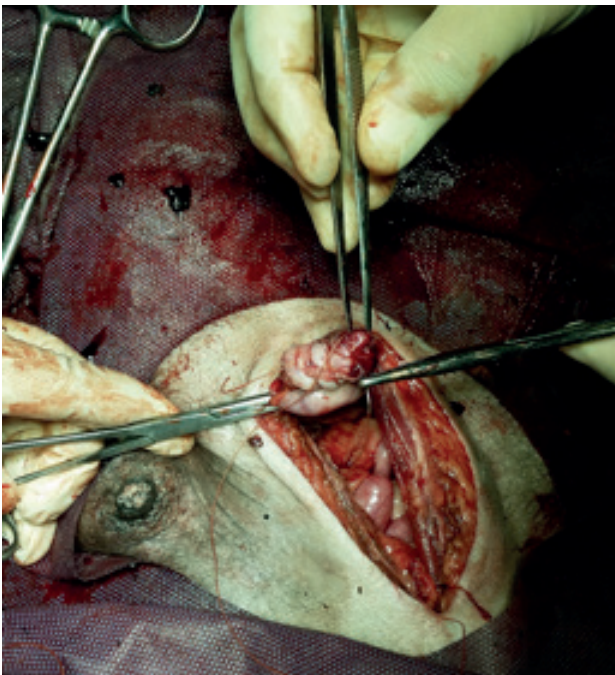


Figure 6. The view of uterus after ovariectomy and completion of surgery-2 yerine "Completion of ovariectomy operation"

material of this case study.

The anamnesis of the patient revealed that it had conceived in its first oestrus cycle and had presented with clinical signs of apathy, anorexia and emesis for the past two days. The physical examination of the animal demonstrated the presence of mild depression. The mucous membranes were observed to be of a dusty rose colour and the capillary filling time was measured as 1-2 seconds. The heart rate was 75/min, and the respiratory rate was 15/min. A tension was detected upon abdominal palpation. Vaginal examination revealed the presence of a brown mucoïd discharge. The body temperature of the animal was measured as 37.5°C. The serum biochemistry test results of the animal are shown in Table 1 (Table 1).

Abdominal ultrasonographic examination (5.0/7.5 MHz Falko, ESAOTE Pie Medical, Holland) showed that while some of the foetuses had no heart beat some other were alive. No abnormal uterine finding was detected at ultrasonography, thus, the site of uterine torsion was not able to be determined. The second ultrasonographic examination performed half an hour later revealed an increase in the number of dead foetuses. Thus, it was decided to perform a caesarean section. A median incision was applied along the linea alba. After a small amount of peritoneal fluid was removed from the abdominal cavity, firstly the right uterine horn and then the left uterine horn were accessed. The left uterine horn displayed congestion and fragility (Figure 1).

Three live foetuses, 2 of which were male and 1 was female, were retrieved from the right uterine horn, whilst the left uterine horn contained two dead female foetuses and displayed haematometra (Figure 2).

The female foetus, which was retrieved from the right uterine horn, died 30 minutes after its retrieval. While the amniotic fluids in the left uterine horn presented with no pathological finding, the chorioallantoic fluids were observed to be haemorrhagic. While the foetuses were retrieved, it was observed that the placenta in the left uterine horn detached much more easily than those in the right uterine horn. On the basis of the calculation of a torsion of 360 degrees (one complete twist) at the uterine bifurcation (Apaydin 2005), it was detected that the left uterine horn had rotated 1800 degrees (five complete twists) along its long axis (Figure 3).

The torsion of the left uterine horn was fixed and the horn was replaced in its normal position (Figure 4).

The animal underwent total ovariectomy (Figure 5 and 6) and was administered intravenous fluid therapy before, during and after the operation. Fluid treatment was initiated with the administration of colloid fluid (300 ml of 10% rheomacrodex, Mediflex, Eczacıbaşı) and continued with crystalloid fluids (500 ml of 5% dextrose – 0.45% NaCl Poliflex, Polifarma; 500 ml of 0.9% isotonic sodium chloride,

Mediflex, Eczacıbaşı). After the ovariohysterectomy procedure was completed, the abdominal cavity was lavaged with isotonic saline and the abdomen was administered with rifamycin (Rif 125 mg ampoule, Koçak Farma, İstanbul). The peritoneum, muscles and skin were closed in layers.

Postoperative treatment involved the intramuscular administration of cefuroxime sodium (Zinnat™ IV/IM 750 mg, GSK, İstanbul, Turkey) at a dose of 22 mg/kg for 7 days, a single subcutaneous injection of meloxicam (Zeloxim IM ampoule, 10 mg/ml, Bilim İlaç, İstanbul, Turkey) at a dose of 0.2 mg/kg and the intramuscular injection of vitamin B12 (Dodeks 1ml/ 2mg, Vetaş, İstanbul, Turkey) at a dose of 40 mcg/kg for a period of 5 days. The owner of the animal was contacted on days 1 and 7 post-operation to acquire information on the health status of the puppies, and it was confirmed that the new-born pups were healthy.

Reports indicate that the prevalence of dystocia in dogs is below 5%, and that out of 182 dystocia cases reported, 1.1% are due to uterine torsion (Forsberg, 2015). In dogs, either one of the uterine horns or both may twist about their own long axis or around each other, and in some cases the uterus itself twists about its own axis (Johnston et al 2001, Thomas 2010). It is indicated that the likelihood of unilateral uterine horn torsion is greater than that of bilateral uterine horn torsion (Kustritz 2006, Kacprzak et al 2014). In this case study, it was ascertained that the left uterine horn had twisted about its long axis, close to the uterine bifurcation (Figure 3).

In previous research, unilateral uterine horn torsions of 180° (Kumru et al 2011), 360° (John and Mathew 2014) and 1800° (Raut et al 2008) were reported in pregnant dogs, whilst a unilateral uterine horn torsion of 720° (Chambers et al 2011) was reported in a non-pregnant dog. In this case study, a unilateral uterine horn torsion of 1800 degrees was described in a 63-day-pregnant bitch. It was found to display similarity to that reported by Raut et al (2008) and was ascertained to be of a degree significantly higher than other previously reported cases.

The exact aetiology of uterine torsion is unknown. As cases of uterine torsion are observed particularly in pregnant animals and especially during the second half of pregnancy, gestation is considered to be the main factor involved in the aetiology of this disorder (Kacprzak et al 2014). The occurrence of uterine horn torsion in bitches is attributed to the uterine horns being very long in this species (Apaydin 2005, Kustritz 2006, Kacprzak et al 2014). Pregnancy-related factors that cause predisposition to uterine torsion include excessive foetal movements, lack of tonus in the gravid uterus, stretching of the uterine ligaments in previous pregnancies or the hereditary weakness of ligaments, rough intervention during pregnancy, trauma and hyperactivity of the pregnant animal involving jumping, running and rolling, as well as oxytocin

administration (Kumru et al 2011, Kacprzak et al 2014). In this case study, both the increased uterine weight caused by the growing foetuses in the uterus during the late stage of gestation (Day 63) and the continued hyperactivity of the bitch during gestation in particular during the last week, were considered to have resulted in uterine horn torsion by causing the uterus to rotate around its own axis. Kumru et al (2011) described a unilateral uterine horn torsion of 180 degrees in a 5-year-old primiparous pregnant bitch due to hyperactivity during gestation. The case described in this study displays similarity to that reported by Kumru et al (2011) in that both are considered to have been caused by hyperactivity. On the other hand, this case differs from the previously reported case in that the degree of the torsion is ten-fold higher. The bitch examined in this case study being of a large breed, and thus, having a large and deep abdominal cavity, is also considered to have increased the severity of uterine torsion.

Canine uterine torsion is characterized by the sudden occurrence of mucoid, serosanguinous or haemorrhagic vaginal discharge, abdominal distension associated by severe abdominal pain, hypothermia or hyperthermia, tachycardia, paleness of the mucosae, decreased heart rate, cooling of the extremities, shock (acute abdominal) and dystocia (Biddle and Macintire 2000, Johnston et al 2001, Bekyurek and Macun 2013, Kacprzak et al 2014). Nevertheless, uterine torsion may also present with very few or no clinical findings (Johnston et al 2001, Thomas 2010). In this case study, the history of the patient involving only anorexia, emesis and apathy, the physical examination of the animal demonstrating abdominal distension, mucoid vaginal discharge and a slight decrease of body temperature as 0.5°C. Serum biochemical analysis results being normal except for a slight decrease in the blood urea nitrogen (BUN) level were noteworthy. The decrease in the BUN level was attributed to increased glomerular infiltration during gestation. Furthermore, the presence of mucoid vaginal discharge and the slight decrease observed in the body temperature were attributed to the onset of labour.

The severity of canine uterine torsion varies with the degree of the torsion (Biddle and Macintire 2000, Johnston et al 2001, Thomas, 2010). In this case study, in which the degree of unilateral uterine horn torsion was determined to be very high (1800°), the animal did not show any sign of shock. This was attributed to the attentiveness of the animal owner and the referral of the animal to a veterinary clinic at the early stage of uterine torsion. Although shock was not encountered in this case, with an aim to prevent hypovolemic shock during operation, the animal was administered perioperative colloid and crystalloid fluids therapy. Severe cases of uterine torsion may result in the thrombosis or rupture of the uterine blood vessels, causing the obstruction of the blood supply to the uterus, and leading to congestion,

shock or even the death of the foetus and/or the mother. It is known that the twisted uterus may rupture during labour (Johnston et al 2001). In the case investigated in this study, at operation, it was observed that the left uterine horn displayed congestion, fragility and haematometra. In the left uterine horn, while the amniotic fluid appeared normal, the chorioallantoic fluids were haemorrhagic and two foetuses were observed to be dead. In addition to the clinical findings indicated in literature reports, in this case, it was observed that the placentae in the left uterine horn detached more easily than those in the right uterine horn. Similar to the other findings observed, this was also attributed to the uterine blood supply having been disrupted due to uterine horn torsion. Furthermore, it was considered that, as the uterine torsion had led to the constriction of the uterine veins while the arterial blood supply to the uterus continued with no disruption, eventually, the torsion resulted in congestion, oedema and venous infarction in the left uterine horn.

In cases of uterine torsion, early diagnosis has a vital importance (Forsberg 2015). Diagnosis is based on the clinical findings observed and the radiological and ultrasonographic examination of the abdomen (Johnston et al 2001). Ultrasonographic examination enables the detection of both dead and alive foetuses (Kacprzak et al 2014). In this case study, the second ultrasonographic examination, which was performed half an hour after the first, having revealed an increase in the number of dead foetuses is considered a significant finding. The first ultrasonographic examination had demonstrated the presence of both dead and live foetuses. Nevertheless, the differential diagnosis of the unilateral uterine horn torsion was not based on these findings. The differential diagnosis of uterine torsion is made by colour-flow Doppler ultrasonography or experimental laparotomy (Biddle and Macintire 2000, Kacprzak et al 2014). The differential diagnosis of this case was made at the caesarean section.

The routine treatment of canine uterine torsion is performed by unilateral en bloc ovariohysterectomy (Kustritz 2006, Bekyurek and Macun 2013). In the event of thrombosis and gangrene, an emergency surgical intervention is required, which involves the removal of the foetuses and hysterectomy (Johnston et al 2001, Thomas 2010). In the present case, in view of the twisted uterine horn being necrotic and fragile, and the animal owner not intending any future whelping for the dog, it was decided to perform a total ovariohysterectomy. In conclusion, although known as a life-threatening condition associated with systemic disorders that require emergency medical and surgical intervention, as was observed in the present case, canine uterine torsion may be manifested with nonspecific clinical findings such as apathy and emesis. The detection of both dead and live foetuses by ultrasonography and the observation of an increase in the number of dead foetuses at subsequent ultrasonographic examinations should be evaluated for uterine torsion. As in the present

case, early diagnosis and a successful surgical intervention can save the life of the animal.

Acknowledgements

This study was presented in VI. National Congress of Turkish Society of Veterinary Gynaecology 15-18 October 2015, Fethiye, TURKEY, as a poster presentation.

References

- Apaydin AM, 2005. Güç doğumlar, In: Evcil Hayvanlarda Doğum ve İnfertilite, Ed; Alacam, E, 5th Edn, Medisan, Ankara, pp; 195-212.
- Bekyürek T, Macun HC, 2013. Güç doğum, In: Köpek ve Kedi-lerde Doğum ve Jinekoloji, Eds; Kaymaz M, Fındık M, Rışvanlı A, Köker A, Medipres, Malatya, pp; 293-408.
- Biddle D, Macintire DK, 2000. Obstetrical emergencies. Clin Tech Small Anim Pract, 15, 88-93.
- Chambers BA, Laksito MA, Long F, Yates GD, 2011. Unilateral uterine torsion secondary to an inflammatory endometrial polyp in the bitch. Australian Vet J, 89, 380-384.
- Forsberg CL, 2015. Dystocia in the bitch, In: Mechanisms of Disease in Small Animal Surgery, Eds; Bojrab MJ, Monnet E, Teton New Media, Jackson, WY, USA, pp;1-10.
- John J, Mathew DP, 2014. Surgical management of unicornual torsion in a dog. Intas Polivet, 15, 261-262.
- Johnston SD, Kustritz MVD, OLSAN PSD, 2001. Canine parturition- eutocia and dystocia, In: Canine and Feline Theriogenology, Eds; Kersey R, Lemelledo D, WB Saunders Company, Philadelphia, pp; 105-128.
- Kacprzak KJ, Jurka P, Max A, Czerniawska-Piatkowska E, Bartyzel BJ, 2014. Etiology, symptoms and treatment of uterine torsion in domestic animals. Folia Pomer Univ Technol Stetin Agric Aliment Pisc Zootech, 315, 21-30.
- Kumru IH, Seyrek-Intas K, Seyrek-Intas D, Tek HB, Wehrend A, 2011. Clinical case: unilateral en bloc ovariocornuectomy as a treatment for uterine torsion in a bitch. Revue Med Vet, 162, 76-78.
- Kustritz MVR, 2006. Clinical management of pregnancy in cats. Theriogenology, 66, 45-150.
- Murugavel K, Antoine D, Kantharaj S, Raju MS, 2013. Unilateral uterine torsion secondary to pyometra in a bitch. Indian J Anim Sci, 34, 58-59.
- Nak D, Cangul IT, Nak Y, 2008. Torsion of the left uterine horn in a pregnant cat. Aust Vet Practit, 38, 29-30.
- Raut BM, Raghuvanshi DS, Upadhye SV, Gahlod BM, Gawande AP, Sirsat PR, Wankhade PR, 2008. Uterine torsion in a Bitch. Vet World, 1, 212.
- Thilagar S, Yew YC, Dhaliwal GK, Toh I, Tong LL, 2005. Uterine horn torsion in a pregnant cat. Vet Rec, 157, 558-560.
- Thomas P, 2010. Canine pregnancy and dystocia: clinical management. Proceedings of the 3rd AVA/NZVA, Pan Pacific Veterinary Conference, Brisbane, 43, 1-9.