

See discussions, stats, and author profiles for this publication at: <https://www.researchgate.net/publication/49801943>

# The effects of zoledronic acid on neointimal hyperplasia: A rabbit carotid anastomosis model

Article in *Anadolu kardiyoloji dergisi: AKD = the Anatolian journal of cardiology* · February 2011

DOI: 10.5152/akd.2011.026 · Source: PubMed

CITATIONS

9

READS

34

6 authors, including:



**Mehmet Guzeloglu**

Izmir University

31 PUBLICATIONS 175 CITATIONS

[SEE PROFILE](#)



**Buket Reel**

Ege University

36 PUBLICATIONS 184 CITATIONS

[SEE PROFILE](#)



**Ismail Yurekli**

Izmir Katip Celebi Universitesi

199 PUBLICATIONS 251 CITATIONS

[SEE PROFILE](#)

Some of the authors of this publication are also working on these related projects:



Is the ankle-brachial index directly associated with current glycemic control in diabetic patients? [View project](#)



Hospital pharmacy education and training [View project](#)

# The effects of zoledronic acid on neointimal hyperplasia: a rabbit carotid anastomosis model

## *Neointimal hiperplazi üzerine zoledronik asidin etkileri: Tavşan karotis anastomoz modeli*

Mehmet Güzeloğlu<sup>1</sup>, Mehmet Gül<sup>1</sup>, Buket Reeş<sup>2</sup>, İsmail Yürekli<sup>3</sup>, Koray Aykut<sup>4</sup>, Eyüp Hazan<sup>5</sup>

Department of Cardiovascular Surgery, Faculty of Medicine, Mustafa Kemal University, Hatay

<sup>1</sup>Department of Histology and Embryology, Faculty of Medicine, İnönü University, Malatya

<sup>2</sup>Department of Pharmacology, Faculty of Pharmacy, Ege University, İzmir

<sup>3</sup>Department of Cardiovascular Surgery, Atatürk Training and Research Hospital, İzmir

<sup>4</sup>Cardiovascular Surgery Clinics, Ege Hospital, Denizli

<sup>5</sup>Department of Cardiovascular Surgery, Faculty of Medicine, Dokuz Eylül University, İzmir, Turkey

### ABSTRACT

**Objective:** The aim of the present study was to investigate the effect of zoledronic acid (ZA), as a matrix metalloproteinase inhibitor, on neointimal hyperplasia in rabbit carotid anastomosis model.

**Methods:** New Zealand male rabbits were divided into two groups as placebo and treatment groups in this experimental study. After anesthesia, the right carotid artery of each rabbit was end-to-end anastomosed with an 8/0 polypropylene suture. Left carotid artery was kept as control without any operation. Placebo group (n=6) received phosphate buffered saline (PBS) (0.5mL/kg/day/s.c.) for 28 days postoperatively, whereas ZA group (n=6) received ZA (100 µg/kg/day/s.c.) for the same period. After sacrifice, the anastomosed and control arteries were isolated. Morphometric and immunohistochemical examinations were performed. Statistical analyses of morphometric and immunohistochemical data were performed using two-way ANOVA and Chi-square test respectively.

**Results:** In PBS group, vascular injury in the anastomosed artery significantly increased the intimal area (anastomosed: 112.51±61.18 µm<sup>2</sup>\*1000 vs. control: 22.62±4.26µm<sup>2</sup>\*1000, p<0.01) and intima/media index (anastomosed: 0.347±0.29 vs. control: 0.075±0.01, p<0.05) compared to control artery. ZA significantly reduced the intimal area (39.29±18.21 µm<sup>2</sup>\*1000, p<0.01) and intima/media index (0.112±0.07, p<0.05) compared to PBS group. Additionally, α-smooth muscle actin immunopositivity was found significantly decreased in anastomosed arteries from ZA group (ZA: 2.33±0.52 vs. PBS: 3.50±0.5, p<0.05). Moreover, intensive gelatinase (MMP-2 and MMP-9) immunoreactivities were clearly seen in anastomosed arteries compared to control arteries from PBS group. ZA apparently decreased immunopositivities for gelatinases in anastomosed arteries.

**Conclusion:** ZA might be a promising agent for prevention of neointimal hyperplasia, which is the most significant cause of graft failures in late postoperative period. (*Anadolu Kardiyol Derg 2011; 2: 93-100*)

**Key words:** Neointimal, matrix metalloproteinases (MMPs), zoledronic acid, rabbit

### ÖZET

**Amaç:** Çalışmamızın amacı tavşan karotis arter anastomoz modelinde gelişen neointimal hiperplazi üzerine bir matris metalloproteinaz inhibitörü olarak zoledronik asidin (ZA) etkilerini araştırmaktır.

**Yöntemler:** Bu deneysel çalışmada Yeni Zelanda tipi erkek tavşanlar plasebo ve ilaç-tedavi olmak üzere iki gruba ayrılmıştır. Anestezi sonrası, her bir tavşanın sağ karotis arteri 8/0 polipropilen sütür ile uç uca anastomoz edilmiştir. Sol karotis arter ise uygulama olmaksızın kontrol olarak bırakılmıştır. Plasebo grubundaki tavşanlara (n=6) operasyon sonrası 28 gün boyunca PBS (0.5mL/kg/gün/s.k.) uygulanırken ilaç grubundaki tavşanlara (n=6) aynı süre boyunca zoledronik asit (100 µg/kg/gün/s.k.) uygulanmıştır. Sakrifikasyondan sonra anastomozlu ve kontrol arterler izole edilmiştir. Morfometrik ve immünohistokimyasal incelemeler gerçekleştirilmiştir. Morfometrik ve immünohistokimyasal verilerin istatistiksel analizleri sırasıyla çift yönlü ANOVA ve Ki-kare testi ile yapılmıştır.

**Bulgular:** PBS grubunda anastomozlu arterlerde oluşan damar hasarının, kontrol artere kıyasla intimal alanı (kontrol: 22.62±4.26, µm<sup>2</sup>\*1000 anastomozlu: 112.51±61.18 µm<sup>2</sup>\*1000, p<0.01) ve intima/media indeksini (kontrol: 0.075±0.01, anastomozlu: 0.347±0.29, p<0.05) istatistiksel olarak anlamlı şekilde artırdığı saptanmıştır. Zoledronik asidin, PBS grubuna kıyasla intimal alanı (39.29±18.21 µm<sup>2</sup>\*1000, p<0.01) ve intima/media indeksini (0.112±0.07, p<0.05) anlamlı şekilde azaltmıştır. Buna ek olarak, ZA grubundan anastomozlu arterlerde α-düz kas aktin immunpozitivitesi

**Address for Correspondence/Yazışma Adresi:** Dr. Mehmet Güzeloğlu, Medical School of Mustafa Kemal University, Department of Cardiovascular Surgery, Hatay, Turkey Phone: +90 326 214 86 71 E-mail: mehmetguzeloglu@hotmail.com

**This study was partly presented as an oral presentation at XIV<sup>th</sup> National Vascular Surgery Congress, 15-19 Mayıs 2009, Bodrum, Muğla, Turkey**

**Accepted Date/Kabul Tarihi:** 20.09.2010 **Available Online Date/Çevrimiçi Yayın Tarihi:** 02.02.2011

©Telif Hakkı 2011 AVES Yayıncılık Ltd. Şti. - Makale metnine www.anakarder.com web sayfasından ulaşılabilir.

©Copyright 2011 by AVES Yayıncılık Ltd. - Available on-line at www.anakarder.com

doi:10.5152/akd.2011.026

anamlı şekilde düşük bulunmuştur (PBS:  $3.50 \pm 0.55$ , ZA:  $2.33 \pm 0.52$ ,  $p < 0.05$ ). Ayrıca, PBS grubundan anastomozlu arterlerde kontrol arterlere kıyasla yoğun jelatinaz (MMP-2 ve MMP-9) immunoreaktivitesi açıkça görülmüştür. Zoledronik asit anastomozlu arterlerde jelatinazların immunopozitifliğini belirgin şekilde azaltmıştır.

**Sonuç:** Zoledronik asit, vasküler cerrahide geç dönem greft yetmezliğinin en önemli sebebi olan neointimal hiperplazinin önlenmesi için kullanılabilir umut verici bir ajan olabilir. (*Anadolu Kardiyol Derg 2011; 2: 93-100*)

**Anahtar kelimeler:** Neointimal, matriks metalloproteinazlar (MMPler), zoledronik asit, tavşan

## Introduction

The main reason for early failure of small diameter grafts used in vascular surgery is thrombotic occlusion, whereas the main reason for late failure is neointimal hyperplasia (1-3). Therapeutic interventions such as balloon angioplasty, stenting and surgical vascular anastomosis results in arterial injury. Intimal thickening that develops in response to vascular injury is defined as neointimal hyperplasia. Neointimal hyperplasia is the main stage in the pathogenesis of vascular proliferative disorders such as atherosclerosis and restenosis (4). This process includes extracellular matrix (ECM) degradation, smooth muscle cell (SMC) proliferation and migration (5). Matrix metalloproteinases (MMPs) are known as the components of a Zn<sup>++</sup>- and Ca<sup>++</sup>-dependent neutral endopeptidase family that degrades ECM components and plays an essential role in SMC proliferation and migration (5, 6). Studies performed in rat balloon injury model (7), hypercholesterolemic rabbits (8) and mouse carotid artery ligation model (9) showed that in particular, gelatinases (MMP-2 and MMP-9) play essential role in intimal hyperplasia. Moreover, positive effects of different synthetic MMP inhibitors on SMC proliferation, migration and vascular remodeling have been demonstrated (10-13).

On the other hand, bisphosphonates are commonly used for treatment of osteoporosis by inhibiting the osteoclastic activity and bone resorption. They have recently been reported to have an inhibitory effect on the synthesis and activity of MMPs (14, 15). In most of the studies related to bisphosphonates have been shown to have inhibitory effects on MMP production and activities during tumor growth and invasion. Besides, it was reported that bisphosphonates inhibit SMC proliferation and migration in atherosclerotic animal models and cell culture (16-20).

However, antiproliferative effects related to MMP inhibition of bisphosphonates in atherosclerosis, which is also a proliferative process remains unclear.

The aim of this study was to investigate the possible inhibitory effects of zoledronic acid (ZA) as an MMP inhibitor on neointimal hyperplasia in a rabbit-model of carotid anastomosis.

## Methods

### Material and study design

This experimental study was approved by the Local Ethics Committee of the Faculty of Medicine, Dokuz Eylül University. All animals received care in compliance with the principles of labo-

ratory animal care formulated by the National Society for Medical Research and the Guide for the Care and Use of Laboratory Animals.

New Zealand male rabbits (n=12, weight range 2.3-2.9 kg) were randomly divided into two groups. Rabbits in the ZA group (n=6) received ZA (100 µg/kg/day, s.c.) for 28 days postoperatively (18), whereas rabbits in the phosphate buffered saline (PBS) group (n=6) received only sterile PBS (0.5mL/kg/day, s.c.) for the same period. Throughout the 28-days treatment period each rabbit was kept in a separate cage and allowed to access to regular diet (standard rabbit chow and tap water *ad libitum*). All animals were well tolerated drug treatment. The treatment protocol did not affect survival rate and body weight of animals from both groups (data not shown).

### Implementation of carotid artery anastomosis model

Rabbits were anesthetized with intramuscular xylazine (3 mg/kg) and ketamine (50 mg/kg). The same surgeon (MG) performed all procedures using a 3.5X surgical telescope (US PAT NO: 3273456, Designs for Vision, Ronkonkoma, NY, USA). An oblique cervical incision was made and the right carotid artery was explored. The distal and proximal parts were clamped and the right carotid artery was transected. Both ends were anastomosed in an end-to-end fashion using an 8/0 polypropylene suture (21). Then, a similar incision was made on the left contralateral carotid artery and a segment from the left carotid artery, which constituted control groups (ZA control and PBS control), was resected. Afterwards, the anatomic layers were closed properly.

### Tissue harvesting procedures

On the 28<sup>th</sup> postoperative day, the rabbits (n=12) were sacrificed using over dose of xylazine and ketamine. First, the anastomosed right carotid artery segment and then a segment from the contralateral intact carotid artery were isolated. Each segment was put into a tube containing 810% neutral buffered formalin for histological examination.

### Morphometry

After formalin fixation of the arteries, paraffin blocks were prepared following routine histological procedures. Five-micrometre sections were obtained from the prepared paraffin blocks. Sections were stained with hematoxylin and eosin (H&E). All slides were examined by Leica DFC280 light microscope. Leica QWin and Image Analysis System (Leica Micros Imaging Solutions Ltd., Cambridge, UK) were used for image processing. The luminal,

intimal and medial cross-sectional areas of the arteries were measured and the index defined as intimal/medial area ratio was calculated from these measurements.

### Immunohistochemistry

The sections were deparaffinized in xylene, rehydrated in graded ethanol and washed with distilled water. The slides were enhanced by boiling the tissue sections in 10 mM citrate buffer at pH 6.0 for 10 minutes followed by cooling at room temperature (RT) for 30 minutes. All tissue sections were rinsed with PBS at pH 7.4; in order to block endogenous peroxidase activity the sections were incubated in 0.3% H<sub>2</sub>O<sub>2</sub> for 30 min, and then washed with PBS. They were then incubated in 10% normal horse serum (NHS) for 20 minutes at 37°C. The NHS and all subsequent reagents were diluted in PBS containing 0.1% bovine serum albumin, 200 µL of the diluted solution was added to each slide and incubated in a moisture chamber (22). The NHS was removed, and the slides were incubated at 37°C with monoclonal anti  $\alpha$ -actin smooth muscle specific antibody (Cat. # A20002, ScyTek Laboratories, Utah, USA) and with antibodies against anti MMP-2 and MMP-9 (Cat. # MAB3308, Cat. # MAB3309 respectively Milipore, CA, USA). After incubation, in order to remove the primary antibody the slides were washed with PBS. Anti-mouse secondary antibodies were used at 1:200 dilution. After incubation for 30 minutes and washing in PBS, the avidin-biotin complex was added and the slides were incubated at RT for 30 min. Then, the slides were washed in PBS and the peroxidase reaction was initiated using 0.06% diaminobenzidine (DAB) and 0.01% H<sub>2</sub>O<sub>2</sub>. After the last rinsing, the sections were counterstained with hematoxylin, and mounted under a cover slip. Negative controls, slides of ZA and PBS group were directly colored with anti-mouse secondary antibodies.

In order to evaluate  $\alpha$ -smooth muscle actin immunoreactivity, the preparations were stained with  $\alpha$ -smooth muscle actin antibody and examined under different magnifications. Then, positive-stained cells were counted for immunoscore of  $\alpha$ -smooth muscle actin expressed cells. If none of the cells were stained, the score was indicated as (-). Likewise, if the number of stained cells was between 1–10, 11-50, 51-100 and  $\geq$ 100, the score was indicated as (+), (++) , (+++) and (++++), respectively (23).

### Statistical analysis

The statistical analysis was performed using SPSS 12.0 (SPSS Inc, Chicago, IL, USA) for windows. Statistical analysis of data performed for drug treatments (two levels; placebo or ZA) as between rabbit factor; and anastomosis (two levels; present or not) as within rabbit factor with analysis of variance (ANOVA). If there were interactions between the factors in ANOVA, the Wilcoxon signed ranks test and the Mann-Whitney U test were used for paired and unpaired comparisons respectively. Chi-square test was used to evaluate the statistical difference of immunostaining between ZA-treated and placebo group. Data are shown as mean $\pm$ SD (standard deviation); n indicates the number of animals. A  $p < 0.05$  was considered statistically significant.

## Results

### Morphometry

Morphometric examination of the anastomosed arteries from the PBS group showed different degrees of neointimal hyperplasia. The intimal cross-sectional area (112.509 $\pm$ 61.179  $\mu$ m<sup>2</sup>\*1000 PBS anastomosed group vs. 22.618 $\pm$ 4.263  $\mu$ m<sup>2</sup>\*1000 PBS control,  $p < 0.01$ ) and the ratio of intimal area to medial area (index) (0.347 $\pm$ 0.292 PBS anastomosed group vs. 0.075 $\pm$ 0.01 PBS control group,  $p < 0.05$ ) significantly increased in anastomosed arteries as compared to those in control arteries in placebo group (Fig. 1A, 1B, 1C, 1F, 2, 4).

ZA treatment significantly decreased the neointimal hyperplasia (39.286 $\pm$ 18.211  $\mu$ m<sup>2</sup>\*1000 ZA group vs. 112.509 $\pm$ 61.179  $\mu$ m<sup>2</sup>\*1000 PBS group,  $p < 0.01$ ) and carotid artery intima/media index (0.112 $\pm$ 0.072 ZA group vs. 0.347 $\pm$ 0.292 PBS group,  $p < 0.05$ ) in anastomosed arteries (Fig. 1D, 1E, 2, 4).

Medial cross-sectional area was not altered in anastomosed arteries in the placebo group (Fig. 3). ZA treatment did not affect the medial cross-sectional area (Fig. 3).

Luminal cross-sectional area was not affected by either intimal hyperplasia or ZA treatment (Fig. 5).

### Immunohistochemistry

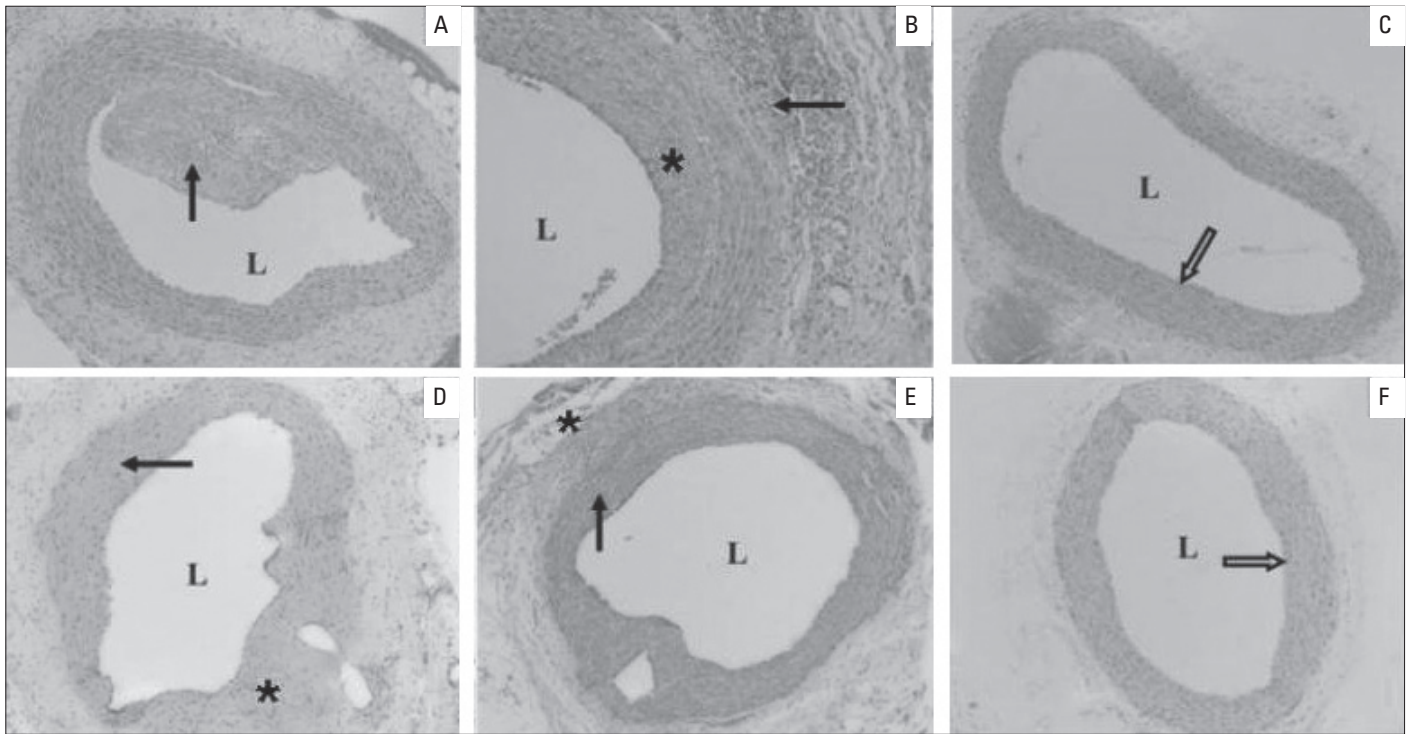
Immunoscore for  $\alpha$ -smooth muscle actin antibody revealed that  $\alpha$ -smooth muscle actin immunopositivity was significantly higher in the PBS group compared to ZA group (3.500 $\pm$ 0.548 PBS group vs 2.333 $\pm$ 0.516 ZA group,  $p < 0.05$ ) (Fig. 6, 7).

Immunostaining with MMP-2 and MMP-9 antibodies showed that intensive positive immunostaining for MMP-2 and MMP-9 were observed in anastomosed carotid arteries compared to control arteries from placebo group (Fig. 8, 9). However, ZA treatment apparently decreased positive immunoreactivities of MMP-2 and MMP-9 in anastomosed carotid arteries (Fig. 8, 9).

## Discussion

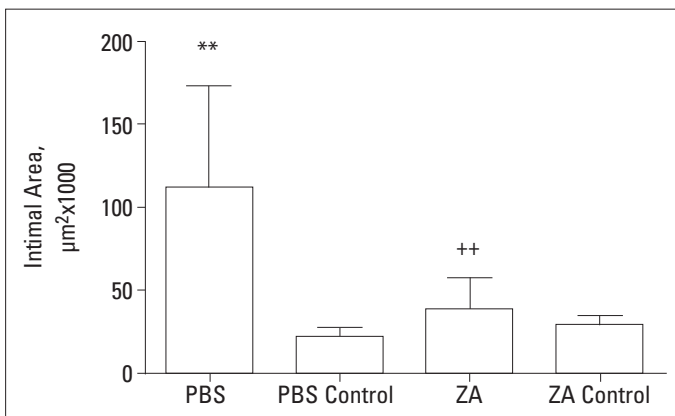
In the present study, we demonstrated that the injury by carotid artery anastomosis induces intensive neointimal hyperplasia, and increased intima/media index and  $\alpha$ -smooth muscle actin immunopositivity in rabbits from placebo (PBS) group.

It was known that neointimal hyperplasia is the main stage in the pathogenesis of restenosis development after vascular injury (1-3). It is also the main cause of late graft occlusions after vascular surgery (1-3). Many of the studies showed that throughout the neointimal hyperplasia process, the MMP enzyme family plays an essential role in SMC proliferation and migration by degrading the ECM components, and contributes to neointimal hyperplasia process (5, 7, 24). Development of intimal hyperplasia and early events of atherosclerosis are usually associated with the expression and activities of gelatinases (MMP-2 and MMP-9) (7, 9, 25). Similarly, in this study we investigated that the role of gelatinases in the development of neointimal hyperplasia



**Figure 1. Representative photomicrographs of paraffin transverse sections of carotid arteries stained with hematoxylin-eosin. A-B- placebo (PBS) group; C- placebo (PBS) control group; D-E- zoledronic acid (ZA) group; F- ZA control group. L- lumen. (Original magnification x10 for Figure A, C, D, E, F and original magnification x20 for Figure B).**

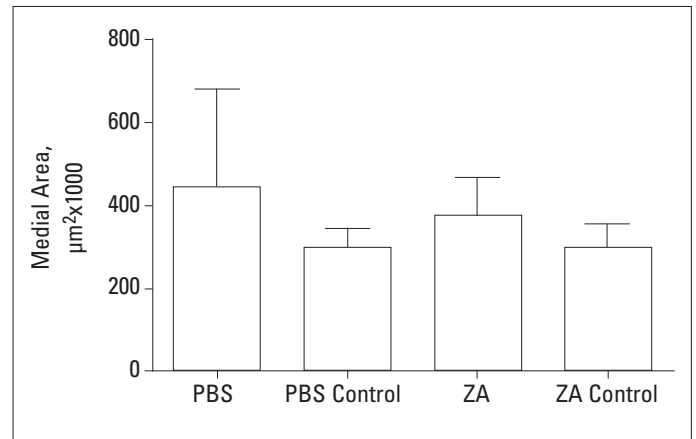
In the slices with intensive neointimal hyperplasia, several recanalized areas were identified within the hyperplastic tissue occluding the lumen (Figure 1A (→), 1B(\*)). In anastomosed arteries from PBS group, it was observed that alignment of the circular SMCs within media layer was disrupted, and in some of these areas, SMCs were aligned heading toward the lumen (Figure 1A, 1B). Some infiltrated areas and an increase in the density of fibrous connective tissue were also observed (Figure 1B (→)). ZA treatment significantly decreased the neointimal hyperplasia in anastomosed arteries (Figure 1D (→), 1E (→)). Disruption of the alignment of circular SMCs in the media layer was observed in ZA group, as were necrotic changes and mononuclear cellular infiltration around the sutured regions (Figure 1D (\*)), Mildly infiltrated areas were identified in the adventitia (Figure 1D (\*), 1E (\*)). Vascular layers of normal histological structure were observed while examining the samples obtained from the carotid arteries of the control groups (Figure 1C, 1F (→))



**Figure 2. Effects of anastomosis and ZA (100 µg/kg/day, s.c.) on intimal area of rabbit carotid arteries.**

Data are shown as mean±s.d. \*\*p<0.01 control vs. anastomosed artery (ANOVA), ++p<0.01 Placebo (PBS) vs. ZA group (ANOVA)

PBS - phosphate buffer saline, ZA - zoledronic acid



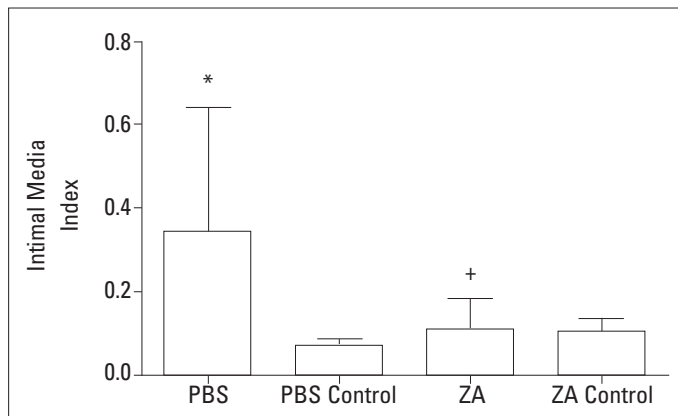
**Figure 3. Effects of anastomosis and ZA (100 µg/kg/day, s.c.) on medial area of rabbit carotid arteries.**

Data are shown as mean±s.d.

PBS - phosphate buffer saline, ZA - zoledronic acid

in the rabbit model of carotid anastomosis. Consistent with the previous evidence, we observed that gelatinase expression which is evaluated by using immunohistochemistry apparently increased in anastomosed arteries of the rabbits from placebo

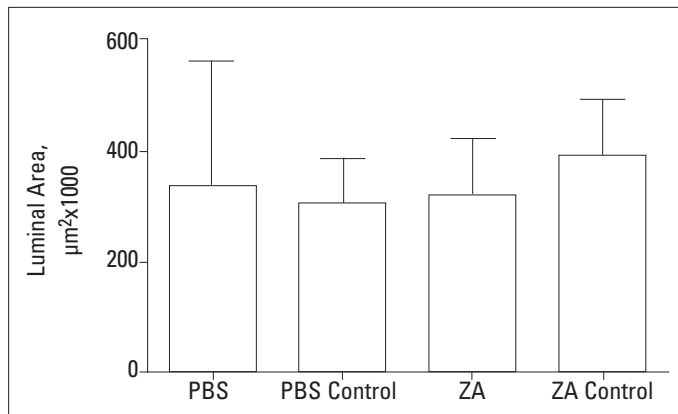
group. The increased expressions of MMP-2 and MMP-9 in these arteries suggest that MMP-2 and MMP-9 may have a regulatory role in SMC proliferation and migration even 28 days after vascular injury in the rabbit model of carotid anastomosis.



**Figure 4. Effects of anastomosis and ZA (100 µg/kg/day, s.c.) on intima/media index of rabbit carotid arteries.**

Data are shown as mean±s.d. \*\*p<0.05 control vs. anastomosed artery (ANOVA), ++p<0.05 Placebo (PBS) vs. ZA group (ANOVA)

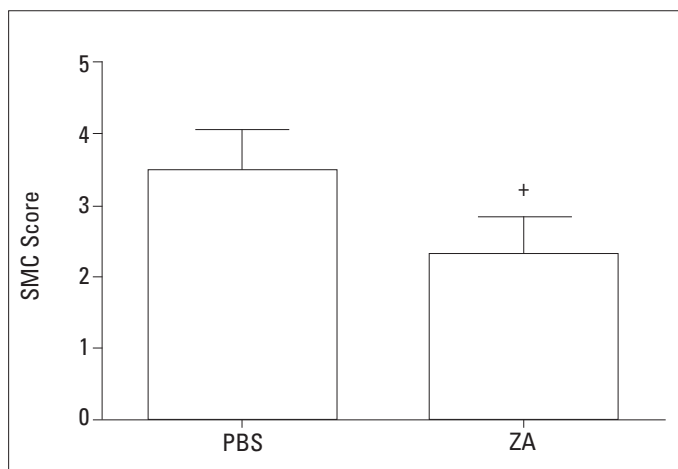
PBS - phosphate buffer saline, ZA - zoledronic acid



**Figure 5. Effects of anastomosis and ZA (100 µg/kg/day, s.c.) on luminal area of rabbit carotid arteries.**

Data are shown as mean±s.d.

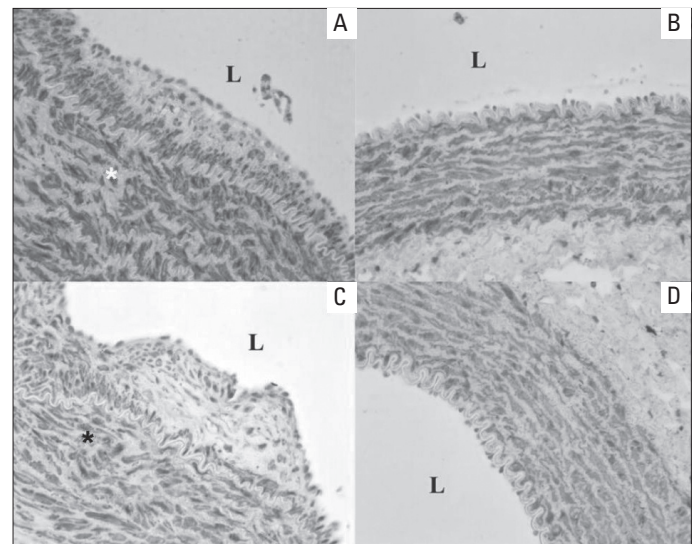
PBS - phosphate buffer saline, ZA - zoledronic acid



**Figure 6. Effect of ZA (100 µg/kg/day, s.c.) on smooth muscle cell (SMC) score of rabbit carotid arteries.**

Data are shown as mean±s.d. +p<0.05 Placebo (PBS) vs. ZA group, Chi-square test

PBS - phosphate buffer saline, ZA- zoledronic acid

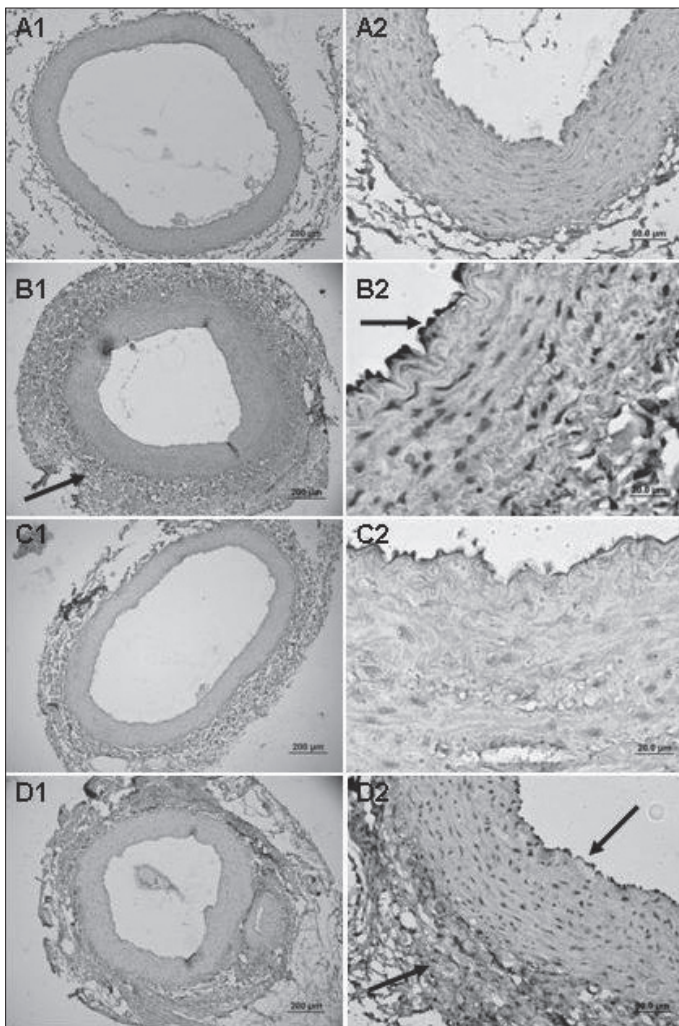


**Figure 7. Representative photomicrographs of paraffin transverse sections of carotid arteries stained with α-smooth muscle actin antibody immunohistochemically. A- placebo (PBS; phosphate buffer saline) group; B- placebo (PBS) control group; C- zoledronic acid (ZA) group; D- ZA control group; L- lumen (Original magnification x40)**

Indeed, it was shown that MMP-9 expression and activity increased at day 1 and decreased from day 7 after vascular injury in carotid arteries ligation model in mice and in carotid artery balloon injury model in pigs (9, 26). Similarly, in carotid artery ligation model in mice, MMP-2 expression apparently increased at day 7 and proceeds to increase even 4weeks after vascular injury (9). This evidences show that MMP-2 and MMP-9 have different expression patterns in at different time points (27). But, in our study we demonstrated that MMP-2 and MMP-9 expressions appear to be similar at day 28 after vascular injury in rabbit model of carotid anastomosis. However, we have not determined the levels of gelatinases by zymography. This point requires further investigation.

In this study, immunohistochemical stainings also demonstrated that MMP-2 was located in intima and adventitia, but MMP-9 was located in almost exclusively in adventitia. Unlikely, it was shown that MMP-9 immunoreactivity is massively expressed by intimal cells, but it is also expressed decreasingly by medial and adventitial cells in mouse carotid artery flow cessation model at day 28 (9). Moreover, it was demonstrated that MMP-2 was located throughout the intima, whereas MMP-9 was localized almost exclusively to the region of endothelium at day 28 in bilateral common carotid interposition vein graft model in rabbits (28). This discrepancy may result from the differences between experimental atherosclerosis models, although the immunoreactivities of gelatinases were investigated at the same time point in the related studies.

On the other hand, it was known that bisphosphonates reduce adhesion, invasion and proliferation and viability of tumor cells in tumor cell lines and some animal models (14, 15, 29). Accordingly, zoledronic acid, the most potent one in biphosphonates family was shown to inhibit tumor burden and prevent tumor cell metastasis (30).

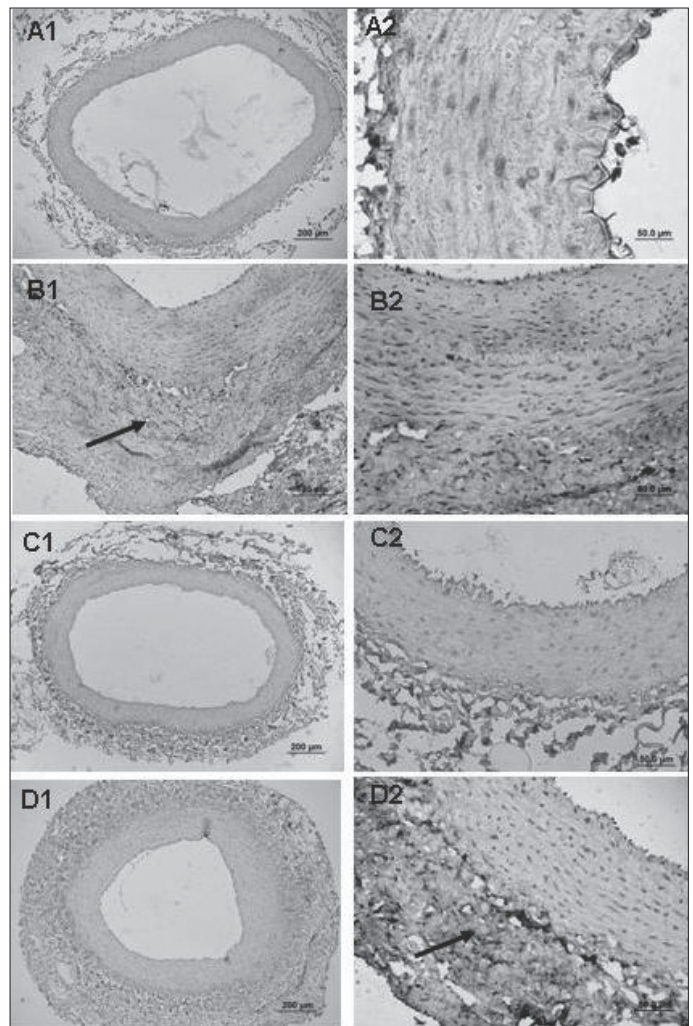


**Figure 8.** Representative photomicrographs of paraffin transverse sections of carotid arteries stained with MMP-2 antibody immunohistochemically. A1 and A2- placebo (PBS; phosphate buffer saline) control group; B1 and B2- placebo (PBS) group; C1 and C2- zoledronic acid (ZA) control group; D1 and D2- ZA group. (Original magnification x10, x40 and x100)

Furthermore, increasing studies have indicated that bisphosphonates could inhibit the development of experimental atherosclerosis (31, 32) and neointimal hyperplasia (33, 34). Although in most of the studies, bisphosphonates have been shown to have inhibitory effects on MMPs in tumor growth and invasion (16, 19), their possible inhibitory effects on intimal hyperplasia and MMPs remains unclear.

Thus, in this study we investigated the effects of ZA on neointimal hyperplasia and gelatinase expression in the rabbit model of carotid artery. We also firstly showed that ZA, the most potent bisphosphonate using in the treatment of osteoporosis and bone resorption, inhibited neointimal hyperplasia and decreased  $\alpha$ -smooth muscle actin immunopositivity and SMC intensity in anastomosed arteries of the rabbits from placebo group.

Our finding supports the view that bisphosphonates not only bind tightly to hydroxyapatite in the bone but they also concentrate in the arterial wall of both healthy and especially



**Figure 9.** Representative photomicrographs of paraffin transverse sections of carotid arteries stained with MMP-9 antibody immunohistochemically. A1 ve A2- placebo (PBS; phosphate buffer saline) control group; B1 ve B2- PBS group; C1 ve C2- zoledronic acid (ZA) control group; D1 and D2- ZA group. (Original magnification x10, x40 and x100)

atheromatous rabbits (20). Furthermore, the inhibitory effect of ZA on SMC score suggests that ZA might also have direct inhibitory effect on vascular SMCs. Indeed, Su et al. (35) reported that etidronate which is another bisphosphonate, inhibited the growth of vascular SMCs from spontaneous hypertensive rats. Similarly, Wu et al. (36) exerted that ZA concentration-dependently reduced proliferation, adhesion and migration of vascular SMCs in vitro.

We also reported for the first time that ZA inhibited increased gelatinase expression in anastomosed carotid arteries from placebo group. This result suggests that the inhibition of gelatinase enzyme contributes to the anti-atherosclerotic effects of ZA. Accordingly, Melani C et al. (18) showed that 0.1 mg/kg dose of ZA which we used in this study, inhibited increased MMP-9 expression and also decreased the levels of vascular endothelial growth factor (VEGF) in mammary tumor cells of mice. Besides, Giraudo et al. (37) reported that ZA significantly reduced MMP-9

expression by infiltrating macrophages and inhibited MMP-9 activity by reducing association of VEGF with its receptor on angiogenic endothelial cells in a mouse model of human cervical carcinogenesis. Additionally, ZA treatment was shown to decrease circulating levels of MMP-2, VEGF and basic fibroblast growth factor (bFGF) in metastatic breast cancer patients (38). Furthermore, alendronate which is another bisphosphonate was exerted to reduce the secretion of MMP-2 and MMP-9 by metastatic PC-3 ML cells in mice (39). Our findings related to the potential of MMP inhibitory effect of ZA on are consistent with all these evidence regarding its antitumor effects. The similarities between anti-atherosclerotic and antitumor effects of biphosphonates suggests that the similar underline mechanisms are responsible for these two proliferative process.

### Study limitations

In this preliminary study, we evaluated expressions of gelatinase enzymes by immunohistochemistry, but we have not been able to determine pro and active gelatinase levels by zymography, due to the limited amount of arterial tissues from animals.

### Conclusion

In conclusion, in the present study we demonstrated for the first time, that ZA which is the most potent member of the newest generation of bisphosphonates, inhibited neointimal hyperplasia and gelatinase upregulation in carotid artery anastomosis model in rabbits. This result suggests that the inhibition of gelatinase enzymes contributes to the anti-atherosclerotic effects of ZA.

Combined data from the present study point out that ZA, which is the most potent inhibitor of osteoclast-mediated bone resorption in clinical practice, might be a promising agent to prevent neointimal hyperplasia and to increase vascular patency after vascular interventions due to its MMP inhibitory effect.

**Conflict of interest:** None declared

### References

1. Donaldson MC, Mannick JA, Whittemore AD. Causes of primary graft failure after in situ saphenous vein bypass grafting. *J Vasc Surg* 1992; 15: 113-8.
2. Merz Kirch C, Davies N, Zilla P. Engineering of vascular in-growth matrices: are protein domains an alternative to peptides? *Anat Rec* 2001; 263: 379-87.
3. Mills JL. Mechanisms of vein graft failure: the location, distribution, and characteristics of lesions that predispose to graft failure. *Semin Vasc Surg* 1993; 6: 78-91.
4. De Meyer GR, Bult H. Mechanisms of neointima formation-lessons from experimental models. *Vasc Med* 1997; 2: 179-89.
5. Kuzuya M, Iguchi A. Role of matrix metalloproteinases in vascular remodeling. *J Atheroscler Thromb* 2003; 10: 275-82.
6. Garcia-Touchard A, Henry TD, Sangiorgi G, Spagnoli LG, Mauriello A, Conover C, et al. Extracellular proteases in atherosclerosis and restenosis. *Arterioscler Thromb Vasc Biol* 2005; 25: 1119-27.
7. Zempo N, Koyama N, Kenagy RD, Lea HJ, Clowes AW. Regulation of vascular smooth muscle cell migration and proliferation in vitro and in injured rat arteries by a synthetic matrix metalloproteinase inhibitor. *Arterioscler Thromb Vasc Biol* 1996; 16: 28-33.
8. Zaltsman AB, George SJ, Newby AC. Increased secretion of tissue inhibitors of metalloproteinases 1 and 2 from the aortas of cholesterol fed rabbits partially counterbalances increased metalloproteinase activity. *Arterioscler Thromb Vasc Biol* 1999; 19: 1700-7.
9. Godin D, Ivan E, Johnson C, Magid R, Galis ZS. Remodeling of carotid artery is associated with increased expression of matrix metalloproteinases in mouse blood flow cessation model. *Circulation* 2000; 102: 2861-6.
10. Baker AH, Edwards DR, Murphy G. Metalloproteinase inhibitors: biological actions and therapeutic opportunities. *J Cell Sci* 2002; 115: 3719-27.
11. Bendeck MP, Conte M, Zhang M, Nili N, Strauss BH, Farwell SM. Doxycycline modulates smooth muscle cell growth, migration, and matrix remodeling after arterial injury. *Am J Pathol* 2002; 160: 1089-95.
12. Li C, Cantor WJ, Nili N, Robinson R, Fenkell L, Tran YL, et al. Arterial repair after stenting and the effects of GM6001, a matrix metalloproteinase inhibitor. *J Am Coll Cardiol* 2002; 39: 1852-8.
13. Margolin L, Fishbein I, Banai S, Golomb G, Reich R, Perez LS, et al. Metalloproteinase inhibitor attenuates neointima formation and constrictive remodeling after angioplasty in rats: augmentative effect of alpha (v) beta (3) receptor blockade. *Atherosclerosis* 2002; 163: 269-77.
14. Catterall JB, Cawston TE. Drugs in development: bisphosphonates and metalloproteinase inhibitors. *Arthritis Res Ther* 2003; 5: 12-24.
15. Green JR. Bisphosphonates: preclinical review. *Oncologist* 2004; 9: 3-13.
16. Corey E, Brown LG, Quinn JE, Poot M, Roudier MP, Higano CS, et al. Zoledronic acid exhibits inhibitory effects on osteoblastic and osteolytic metastases of prostate cancer. *Clin Cancer Res* 2003; 9: 295-306.
17. Danenberg HD, Golomb G, Groothuis A, Gao J, Epstein H, Swaminathan RV, et al. Liposomal alendronate inhibits systemic innate immunity and reduces in-stent neointimal hyperplasia in rabbits. *Circulation* 2003; 108: 2798-804.
18. Melani C, Sangaletti S, Barazzetta FM, Werb Z, Colombo MP. Amino-bisphosphonate-mediated MMP-9 inhibition breaks the tumor-bone marrow axis responsible for myeloid-derived suppressor cell expansion and macrophage infiltration in tumor stroma. *Cancer Res* 2007; 67: 11438-46.
19. Tsagozis P, Eriksson F, Pisa P. Zoledronic acid modulates antitumoral responses of prostate cancer-tumor associated macrophages. *Cancer Immunol Immunother* 2008; 57: 1451-9.
20. Ylitalo R, Mönkkönen J, Urtti A, Ylitalo P. Accumulation of bisphosphonates in the aorta and some other tissues of healthy and atherosclerotic rabbits. *J Lab Clin Med* 1996; 127: 200-6.
21. Freire Cerqueira N, Hussni CA, Bonetti Yoshida W, Swain Müller S, Sequeira JL, Rodrigues AC, et al. Effect of diclofenac sodium on the healing process of end-to-end anastomosis in carotid arteries of rabbits. *Histopathological and biomechanical studies. Int Angiol* 2003; 22: 431-7.
22. Haque T, Mandu-Hrit M, Rauch F, Lauzier D, Tabrizian M, Hamdy RC. Immunohistochemical localization of bone morphogenetic protein-signaling Smads during long-bone distraction osteogenesis. *J Histochem Cytochem* 2006; 54: 407-15.
23. Shiao YH, Palli D, Caporaso NE, Alvord WG, Amorosi A, Nesi G, et al. Genetic and immunohistochemical analyses of p53 independently predict regional metastasis of gastric cancers. *Cancer Epidemiol Biomarkers Prev* 2000; 9: 631-3.



24. Newby AC. Matrix metalloproteinases regulate migration, proliferation, and death of vascular smooth muscle cells by degrading matrix and non-matrix substrates. *Cardiovasc Res* 2006; 69: 614-24.
25. Reel B, Oktay G, Özkal S, İşlekel H, Özer E, Özsarlak-Sözer G, et al. MMP-2 and MMP-9 alteration in response to collaring in rabbits: the effects of endothelin receptor antagonism. *J Cardiovasc Pharmacol Ther* 2009; 14: 292-301.
26. Southgate KM, Fisher M, Banning AP, Thurston VJ, Baker AH, Fabunmi RP, et al. Upregulation of basement membrane-degrading metalloproteinase secretion after balloon injury of pig carotid arteries. *Circ Res* 1996; 79: 1177-87.
27. Misra S, Fu AA, Misra KD, Glockner JF, Mukhopadhyay D. Evolution of shear stress, protein expression, and vessel area in an animal model of arterial dilatation in hemodialysis grafts. *J Vasc Interv Radiol* 2010; 21: 108-15.
28. Berceci SA, Jiang Z, Klingman NV, Pfahnl CL, Abouhamze ZS, Frase CD, et al. Differential expression and activity of matrix metalloproteinases during flow-modulated vein graft remodeling. *J Vasc Surg* 2004; 39: 1084-90.
29. Mook OR, Frederiks WM, Van Noorden CJ. The role of gelatinases in colorectal cancer progression and metastasis. *Biochim Biophys Acta* 2004; 1705: 69-89.
30. Clézardin P. Anti-tumour activity of zoledronic acid. *Cancer Treat Rev* 2005; 3: 1-8.
31. Daoud AS, Frank AS, Jarmolych J, Fritz KE. The effect of ethane-1-hydroxy-1,1-diphosphonate (EHDP) on necrosis of atherosclerotic lesions. *Atherosclerosis* 1987; 67: 41-8.
32. Ylitalo R, Kalliovalkama J, Wu X, Kankaanranta H, Salenius JP, Sisto T, et al. Accumulation of bisphosphonates in human artery and their effects on human and rat arterial function in vitro. *Pharmacol Toxicol* 1998; 83: 125-31.
33. Danenberg HD, Fishbein I, Gao J, Mönkkönen J, Reich R, Gati I, et al. Macrophage depletion by clodronate-containing liposomes reduces neointimal formation after balloon injury in rats and rabbits. *Circulation* 2002; 106: 599-605.
34. Hoch JR, Stark VK, van Rooijen N, Kim JL, Nutt MP, Warner TF. Macrophage depletion alters vein graft intimal hyperplasia. *Surgery* 1999; 126: 428-37.
35. Su JZ, Fukuda N, Kishioka H, Hu WY, Kanmatsuse K. Etidronate influences growth and phenotype of rat vascular smooth muscle cells. *Pharmacol Res* 2002; 46: 7-13.
36. Wu L, Zhu L, Shi WH, Zhang J, Ma D, Yu B. Zoledronate inhibits the proliferation, adhesion and migration of vascular smooth muscle cells. *Eur J Pharmacol* 2009; 602: 124-31.
37. Giraudo E, Inoue M, Hanahan D. An amino-bisphosphonate targets MMP-9-expressing macrophages and angiogenesis to impair cervical carcinogenesis. *J Clin Invest* 2004; 114: 623-33.
38. Ferretti G, Fabi A, Carlini P, Papaldo P, Cordiali Fei P, Di Cosimo S, et al. Zoledronic-acid-induced circulating level modifications of angiogenic factors, metalloproteinases and proinflammatory cytokines in metastatic breast cancer patients. *Oncology* 2005; 69: 35-43.
39. Stearns ME, Wang M. Alendronate blocks metalloproteinase secretion and bone collagen I release by PC-3 ML cells in SCID mice. *Clin Exp Metastasis* 1998; 16: 693-702.