

Metachronous primary cranial tumors: Temporal lobe oligodendroglioma and temporal bone epidermoid carcinoma

Metakronize Primer Kraniyal Tümörler: Temporal lob oligodendroglioması ve temporal kemik epidermoid karsinomu

Ercan Akbay¹, Tümay Özgür², Cengiz Çevik¹

ABSTRACT

A moderately differentiated squamous cell carcinoma has been detected at ipsilateral middle ear of a man aged 41 years old who underwent surgery with a diagnosis of oligodendroglioma at left temporal lobe of brain 5 years ago. It is an uncommon finding to detect more than one primary malignant tumor with distinct pathological features in the same patient. The aim of this report is to remind that there may be tumors with distinct pathological features in the presence of a primary tumor. *J Clin Exp Invest* 2013; 4 (1): 110-112

Key words: Oligodendroglioma, squamous cell carcinoma, metachronous

INTRODUCTION

The cases with association of two or more distinct malignancies are rarely encountered. Synchronous tumoral growth of two or more tissue at different localizations is known as multiple primary neoplasms.¹ These tumors may express either the same or different histological types while they may be at either the same or different localizations. These tumors can be classified into 2 groups: synchronous tumors which occur at the same time or within 2 months and metachronous tumors which developed at least 2 months after primary tumor.² However, in some studies, it has been suggested that the period after primary tumor should have to be at least 2 two years.³ In that study, being in distinct histological type or presence of a second cancer in a different location or absence of carcinoma in common lymphatic drainage pathway are considered as sufficient in the definition of metachronous tumors.³ In synchronous tumors, distant locations

ÖZET

Bein sol temporal lobunda oligodendroglioma tanısı ile 5 yıl önce opere edilen 41 yaşındaki erkek hastanın aynı taraf orta kulağında orta derecede diferansiye skuamöz hücreli karsinom tespit edilmiştir. Farklı patolojilerde birden fazla primer malign tümörün aynı hastada görülmesi sık rastlanılan bulgu değildir. Bu olgunun amacı primer bir tümörün varlığında farklı patolojideki tümörlerin de birlikte olabileceğini hatırlatmaktır.

Anahtar kelimeler: Oligodendroglioma, skuamöz karsinom, metakron

and different histological types of tumors are taken into consideration. It is emphasized that detection of tumor at level of carcinoma in situ, absence of carcinoma in common lymphatic pathways and lack of metastasis at the time of diagnosis should have to be considered, as differentiation between primary and metastatic tumors would be difficult in synchronous tumors with same histological type.³

In the literature, synchronous or metachronous tumors are reported particularly in relation to brain tumors. Predisposing factors includes postoperative radiotherapy and phacomatosis related to neurofibromatosis.^{4,5} Primary multiple brain tumors with distinct histopathological type unrelated to predisposing factors are extremely rare. However, there are studies reporting multiple tumors of brain and extra-cranial tissues. To best of our knowledge, there is no report in the literature on association of brain oligodendroglioma and middle ear epidermoid carcinoma so far.

¹ Department of Otorhinolaryngology, Mustafa Kemal University Medical Faculty, Hatay, Turkey

² Department of Patology, Mustafa Kemal University Medical Faculty, Hatay, Turkey

Correspondence: Ercan Akbay,

Mustafa Kemal Üniversitesi Tıp Fakültesi KBB Anabilim Dalı, Serinyol Hatay, Turkey Email: ercanakbay@yahoo.com

Received: 29.11.2012, Accepted: 22.12.2012

Copyright © JCEI / Journal of Clinical and Experimental Investigations 2013, All rights reserved

In this report, a case with metachronous temporal bone epidermoid carcinoma detected after treatment of temporal lobe oligodendroglioma will be presented.

CASE REPORT

A 41-years old man who underwent surgery with a diagnosis of left temporal lobe oligodendroglioma presented with pain and leakage at left ear. In the physical examination, a polypoid mass at external auditory canal and purulent secretion were detected in the patient who had no history of postoperative radiotherapy for the brain tumor. Tissue loss at left temporal lobe, encephalomalasic areas and craniotomy defects at left frontotemporal bone were observed on the contrasted MR imaging and CT scan (Figure 1). A soft tissue density with calcifications and exophytic extensions, which fills left external auditory canal and middle ear and causes loss of

aeration in middle ear was observed on temporal MR imaging and CT scan (Figure 2). In the patient without no abnormal finding on the examination for facial nerve and other cranial nerves, these findings in addition to leakage from ear suggested a chronic otitis media with polyp and an open cavity tympanomastoidectomy was performed under general anesthesia. However, pathological evaluation was reported as moderately differentiated squamous cell carcinoma (Figure 3). No vicinity or relation was detected between two tumors site in radiological evaluation. The diagnosis of epidermoid carcinoma was confirmed with re-evaluating preparations. Consequently, it was found that the secondary tumor developed independently from the primary tumor, which had distinct pathological characteristics. Given the presence of the primary tumor, penetration of the second tumor, comorbidity and general status of patient, radiotherapy was recommended to the patient instead of radical surgery.

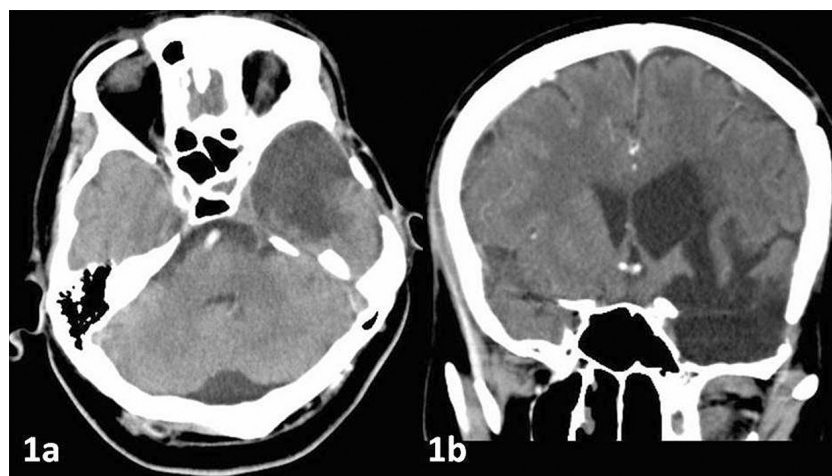


Figure 1. Tissue loss at the left temporal lobe, encephalomalasic areas and changes secondary to surgery as well as dilatation at the left lateral ventricle secondary to tissue loss are seen on CT scan (axial-a, coronal-b).

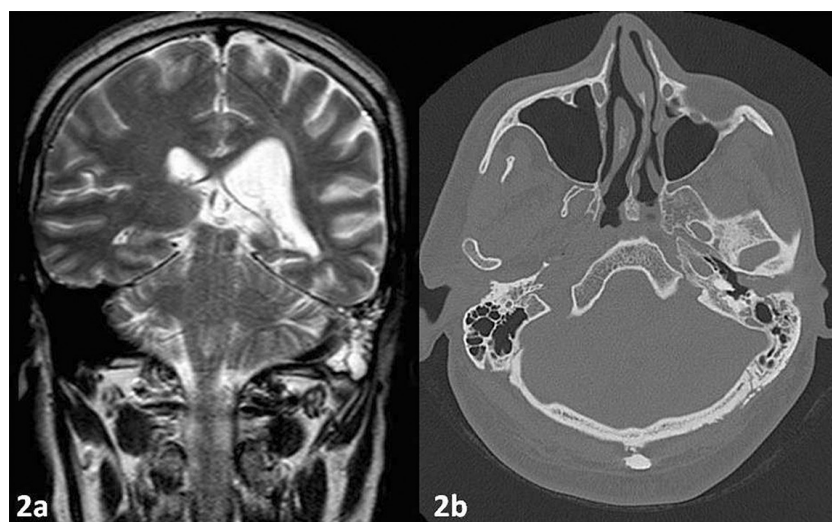


Figure 2. A soft tissue mass at left external auditory canal and middle ear cavity are seen on the temporal MRI (a); a soft tissue mass at external auditory canal extending up to the level of tympanic membrane and causing mild bone destruction at the inferior adjacent bone are observed on the CT scan (b).

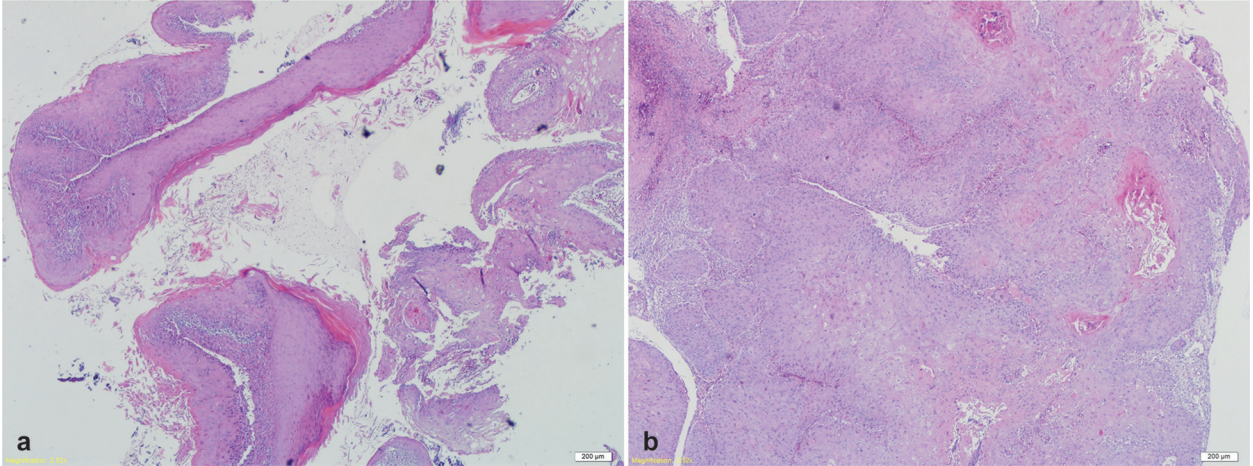


Figure 3 (a-b). Cholestoma residues and adjacent areas of epidermoid carcinoma consisted from atypical epithelial cells with large eosinophilic cytoplasm and oval, round nucleus and prominent nucleolus are observed (HE40).

DISCUSSION

Presence of two primary tumors in the same patient is an uncommon finding.⁶ Incidence of a second malignant tumor at different organs varies 1.7% and 3.9% in patients with a malignant tumor.⁷ Previously, the association of brain oligodendroglioma and meningioma was demonstrated in humans and dogs.^{4,8} In the literature, a case with an association of anaplastic oligodendroglioma at frontal lobe of brain and a squamous cell carcinoma at tongue was discussed.¹ However, best to our knowledge, the association of temporal lobe oligodendroglioma and temporal bone epidermoid carcinoma hasn't been demonstrated so far. A causative relationship was implied between tumor formation and radiation, phacomatosis or trauma exposure.^{4,5,9} Formations of multiple intracranial tumors are not uncommon and multiple gliomas are responsible from 4.3% of all intracranial tumors.⁴ However, these are multiple tumors, which may synchronously occur at several sites of brain, although they occur in the same individual and exhibit same histopathological pattern. The aim of this letter is to remind that there may be synchronous tumors with distinct pathological features in the presence of a primary tumor.

REFERENCES

1. Kumar V, Singh K, Tatke M, et al. Synchronous anaplastic oligodendroglioma and carcinoma tongue: a rare association. *J Cancer Res Ther* 2010;6:227-229.
2. Di Martino E, Sellhaus B, Hausmann R, et al. Survival in second primary malignancies of patients with head and neck cancer. *J Laryngol Otol* 2002;116:831-838.
3. Turhan K, Yoldas B, Çağırıcı U, et al. Senkron ve metakron akciğer kanserlerinde cerrahi tedavi sonuçları. *Ege Tıp Dergisi* 2009;48:85-88.
4. Solmaz İ, Pusat S, Kural C, et al. Simultaneously occurring oligodendroglioma and meningioma: a rare synchronous primary brain tumors case report and literature review. *Neurosurg Q* 2012;22:133-136.
5. Tanaka J, Garcia JH, Netsky MG, et al. Late appearance of meningioma at the site of partially removed oligodendroglioma. Case report. *J Neurosurg* 1975;43:80-85.
6. Lim SK, Sampson CC, Warner OG. Simultaneous primary carcinomas-a report of three cases. *J Natl Med Assoc* 1981;73:413-7.
7. Soylu L, Han S, Demirci S, Ataoğlu Ö. Metakron tümörde senkron metastaz: Olgu sunumu. *Türk Onkoloji Dergisi* 2009;24:36-38.
8. Stacy BA, Stevenson TL, Lipsitz D, et al. Simultaneously occurring oligodendroglioma and meningioma in a dog. *J Vet Intern Med* 2003;17:357-359.
9. Dağdaş S. İyonlaştırıcı radyasyonlar ve kanser. *Dicle Med J* 2010;37:177-185.