

**Ali Osman ÇERİBAŞI¹**
Mehmet GÜVENÇ²¹ Fırat Üniversitesi,
Veteriner Fakültesi, Patoloji
Anabilim Dalı,
Elazığ, TÜRKİYE² Mustafa Kemal
Üniversitesi,
Veteriner Fakültesi, Fizyoloji
Anabilim Dalı,
Hatay, TÜRKİYE**Protective Effects of Pomegranate Juice and Cinnamon
(*Cinnamomum Zeylanicum*) Bark Oil on Carbon
Tetrachloride-Induced Chronic Liver Damage in Rats ***

The aim of this study was to investigate the probable hepatoprotective effects of pomegranate juice (PJ) and cinnamon bark oil (CBO) ingestion on carbon tetrachloride (CCl₄)-induced chronic damages in liver tissues of rats. The study comprised of six treatment groups as control, PJ, CBO, CCl₄, CCl₄+PJ and CCl₄+CBO. All administrations were done by gavage. The administration doses of PJ, CBO and CCl₄ were 5 mL/kg/day, 100 mg/kg/day, and 0.25 mL/kg/week, respectively. CCl₄ treatment caused a significant increase in the liver malondialdehyde (MDA) level, apoptotic cell index, and a significant decrease in the antioxidant markers along with severe lesions. Both PJ and CBO administrations to the CCl₄-treated rats significantly increased the antioxidant markers, and significantly decreased the MDA level, apoptotic cell index and the severity of all hepatic lesions except bile duct hyperplasia, hydropic degeneration and periportal cell infiltrations. The results of this study demonstrate that PJ and CBO are effective for the prevention of CCl₄-induced hepatic damage in rats. The hepatoprotective effects of PJ and CBO are possibly due to the reductions in liver fibrogenesis and apoptosis associated with the prevention of CCl₄-induced oxidative stress.

Anahtar Kelimeler: Apoptosis, carbon tetrachloride, cinnamon bark oil, lipid peroxidation, pomegranate juice

Karbon Tetraklorür ile Kronik Karaciğer Hasarı Oluşturulan Ratlarda Nar Suyu ve Tarçın Kabuk Yağının Koruyucu Etkileri

Bu çalışma, Karbon tetra klorür (CCl₄) ile kronik karaciğer hasarı oluşturulan ratlarda nar suyu (PJ) ve tarçın kabuk yağının (CBO) muhtemel koruyucu etkilerinin incelenmesi amacıyla yapıldı. Çalışma kontrol, PJ, CBO, CCl₄, CCl₄+PJ ve CCl₄+CBO olmak üzere altı grup olarak gerçekleştirildi. Tüm uygulamalar gavaj yoluyla yapıldı. PJ, CBO ve CCl₄ uygulama dozları sırasıyla 5 mL/kg/gün, 100 mg/kg/gün, 0.25 mg/kg/gün şeklinde ayarlandı. CCl₄ uygulaması karaciğer malondialdehit (MDA) düzeyinde ve apoptotik hücre indeksinde belirgin bir yükselmeye neden olurken, şiddetli karaciğer harabiyeti nedeniyle antioksidan belirteçlerin düzeylerinde de belirgin bir azalmaya neden oldu. CCl₄ ile birlikte PJ ve CBO verilen gruplarda ise azalmış antioksidan belirteçlerde belirgin yükselme, artmış MDA düzeyleri, artmış apoptotik hücre indeksi ve safra kanal hiperplazisi, hidropik dejenerasyon ile periportal hücre infiltrasyonu dışında diğer tüm karaciğer lezyonlarının şiddetinde belirgin azalma tespit edildi. Sonuç olarak PJ ve CBO'nun ratlarda CCl₄ ile oluşturulan karaciğer harabiyetini önlemek için etkili olduğu gösterilmiştir. PJ ve CBO'nun karaciğer koruyucu etkileri muhtemelen CCl₄ ile oluşturulan karaciğerdeki oksidatif stresi engelleyerek apoptozis ve fibrojenезisi azaltmalarından kaynaklanmaktadır.

Key words: Apoptosis, karbon tetraklorür, lipid peroksidasyon, nar suyu, tarçın kabuk yağı

Introduction

Liver is an important organ that is responsible for the synthesis, secretion and metabolism of xenobiotics. Damaging of the hepatic parenchyma may negatively affect physiochemical functions of the liver (1). Many infectious and hepatotoxic etiological factors may cause damage to the liver. Carbon tetrachloride (CCl₄) is experimentally used hepatotoxins for inducing liver injury in laboratory animals (2). The metabolism of CCl₄ by the liver NAPDH-cytochrome P450 enzyme system causes oxidative stress by increasing free radical production that has been implicated in the pathogenesis of hepatic fibrosis (3). Many scientists have used the herbal products to protect liver against damaging effects of chemicals due to lack of radical medical treatment of both acute and chronic hepatic damages (4).

Nowadays, herbal products, especially their polyphenolic compounds, are intensely studied due to their high radical scavenging and antioxidant activities (5). Of them is the pomegranate. The juice and other compounds of pomegranate are the rich sources with respect to vitamin C, minerals, and polyphenols (6) that possess high antioxidant activity (7). The other herbal product, cinnamon, has been used as a spice and also treatment of many diseases for traditional medicine. *Cinnamomum zeylanicum*,

Geliş Tarihi : 25.09.2017
Kabul Tarihi : 03.10.2017**Yazışma Adresi
Correspondence****Ali Osman ÇERİBAŞI**
Fırat Üniversitesi,
Veteriner Fakültesi,
Patoloji Anabilim Dalı,
Elazığ - TÜRKİYE**aoceribasi@firat.edu.tr**

* This work was supported by the project number 2070 by Fırat University Scientific Research Projects (FÜBAP).

C. cassia and *C. camphora* are the most important species of cinnamon in terms of obtaining the volatile oils (8). Eugenol and cinnamaldehyde are the main chemical compounds of oils extracted from the leaves and barks of *C. zeylanicum*, respectively (8-9). High free radical scavenging and antioxidant activities of different cinnamon extracts have recently been demonstrated in many studies (10-15). The hepatoprotective effects of cinnamon on acute liver damage were reported by some investigators (12, 13, 16). However, there is no study regarding the protectiveness of cinnamon bark oil (CBO) on long term liver damage, apoptosis and tissue oxidative stress induced by CCl₄ in rats.

In this study, the probable hepatoprotective effects of pomegranate juice (PJ) and CBO consumption on CCl₄-induced chronic damages were investigated by examining the changes in histopathological structure, apoptotic cells and oxidant-antioxidant balance in liver tissues of rats.

Materials and Methods

1. Pomegranate juice, cinnamon bark oil and chemicals: Pasteurized PJ (100% pure, pasteurized pomegranate juice, 250 mL, Elite Natural Beverage Co., Ankara, Turkey) and CBO (Altinterim Co., Elazig, Turkey) were purchased from local store. PJ and CBO were kept at 4 °C until being used. The other chemicals were obtained from Sigma-Aldrich Chemical Co. (St Louis, MO, USA).

2. Animals and study design: The approval of Animal Experimentations Local Ethics Committee of Firat University (Elazig, Turkey) was taken for the animal use and study design. Forty-two healthy adult male Wistar albino rats, at the age of 5 months, were obtained from Firat University Experimental Research Centre (Elazig, Turkey) and the study was maintained therein. Standard laboratory conditions (12 h day / 12 h night, 24±3 °C temperature, 45% to 65% humidity) were provided. The balanced commercial diet (Elazig Food Company, Elazig, Turkey) and drinking water were given *ad libitum* during the study period.

The rats were randomly divided into six groups, 7 rats each. Control group received 0.5 mL pure olive oil + 1.5 mL distilled water daily; PJ group was administered with 5 mL/kg PJ (approximately 1.5 mL volume for each rat) + 0.5 mL pure olive oil daily; CBO group was given with 0.5 mL of olive oil containing 100 mg/kg CBO+1.5 mL distilled water daily; the rats in CCl₄ group were treated with 0.25 mL/kg CCl₄, which dissolved in 0.5 mL pure olive oil, weekly+1.5 mL distilled water daily; the rats in CCl₄+PJ group received weekly CCl₄ and daily PJ; and the rats in CCl₄+CBO group were administered weekly CCl₄ and daily CBO. All applications were done by intra-gastric tube and maintained for 10 weeks. CCl₄ was dissolved in olive oil because it is a water-insoluble chemical. The administration doses of CCl₄, PJ and CBO used in the present study were determined according to the earlier studies (15, 17). Each rat was weighed weekly and the amounts of CCl₄, CBO and PJ were adjusted based on the alterations observed in body weights during the study period.

3. Collection and preparation of liver tissues:

Ether anesthesia was used to sacrifice the rats at the end of the study. The liver samples were taken and protected against light. The half of tissue was fixed in formalin solution for histopathological examinations. The other half of tissue samples were washed three times in cold isotonic saline (0.9% v/w) and stored at -20 °C until being analyzed for oxidative stress indicators. For the determination of oxidative stress indicators, the liver tissues were minced on glass and homogenized by a glass-glass homogenizer in cold physiological saline on ice. Then, the tissues were diluted with a 9-fold volume of phosphate buffer (pH 7.4).

4. Measurement of liver oxidative stress indicators: The spectrophotometer (Shimadzu 2R/UV-visible, Tokyo, Japan) was used for the measurements of all oxidative stress indicators. Lipid peroxidation (LPO) level was measured according to the concentration of thiobarbituric acid reactive substances and the amount of malondialdehyde (MDA) produced was used as an index of LPO. The MDA level at 532 nm was expressed as nmol / g protein (18).

Reduced glutathione (GSH) level was measured using the method described by Sedlak and Lindsay (19). The level of GSH at 412 nm was expressed as nmol / g protein. Glutathione-peroxidase (GSH-Px, EC 1.11.1.9) activity was determined according to the method described by Lawrence and Burk (20). The GSH-Px activity at 340 nm was expressed as IU/g protein. Catalase (CAT, EC 1.11.1.6) activity was determined by measuring the decomposition of hydrogen peroxide (H₂O₂) at 240 nm and was expressed as k/g protein, where k is the first-order rate constant (21). Protein concentration was determined using the method of Lowry et al (22).

5. Histopathological examination: The liver specimens were embedded in paraffin for histopathological examination and taken 5 µ serial sections. The sections were stained with hematoxylin and eosin (HE) and Masson's trichrome stain (MT) for evaluation of the fibrosis. The histopathological analyses were performed unawares from group separations by light microscopy. The grading of liver damage was made four severity grades were used as: 0 (none), no fibrosis and normal liver architecture; + (mild), fatty degenerations around portal areas, increased fibrosis in portal areas and sinusoidal space, and regular liver architecture; ++ (moderate), thin fibrous septa seen frequently in connecting portal areas and pseudolobules; +++ (severe), thick fibrous septa and collagen bands accompanied by pseudolobules. Also ten different periportal sites in liver sections stained with MT in each animal were calculated with computer software as the percent ratio of fibrotic areas in liver parenchym.

6. Determination of apoptotic cells in the liver:

Apoptosis was detected by the terminal deoxynucleotidyl transferase (Tdt)-mediated biotinylated deoxyuridine triphosphates (dUTP) nick end-labeling (TUNEL) method by using an in situ cell death detection kit with horse radish peroxidase (POD) (Roche Diagnostics, Cat No: 11 684 817 910).

In order to determine the apoptotic index of hepatocytes; randomly selected ten different areas of seven sections per group were evaluated at x 400 magnification for the analysis of TUNEL staining. The apoptotic index of hepatocytes was determined as the percentage of TUNEL positive cells with respect to the total number of cells counted using the formula: Apoptotic index = (Number of positive cells/Total number of cells counted) x100 (23).

7. Statistical analysis: The SPSS/PC (Version 21.0; SPSS, Chicago, IL) program was used for the analysis of the all parameters. The values are presented as mean±SEM. $P < 0.05$ was accepted as significance. The differences between the groups with respect to all parameters were detected by using one-way analyses of variance (ANOVA). Tukey-HSD test was used for multiple comparisons.

Results

1. Findings related to the liver macroscopy: The liver weight and liver index are presented in Table 1. While there was no color change in livers of control, PJ and CBO groups, yellow colour changes and fibrosis were noted in CCl₄, CCl₄+PJ and CCl₄+CBO groups at necropsy. About 7 to 15 mL ascites fluid were also found in all rats of CCl₄ group but only in two rats in CCl₄+PJ group and only three rats in CCl₄+CBO group. There were no significant differences between the groups with respect to liver weight and liver index.

2. Changes in the liver tissue oxidative stress indicators: The values of oxidative stress indicators are given in Table 2. The liver MDA levels were significantly ($P < 0.01$) higher in CCl₄ group than the control, PJ and CBO groups. PJ and CBO administration to the CCl₄-treated rats significantly ($P < 0.01$) decreased the MDA levels in tissue when compared to the CCl₄ alone group. CCl₄ treatment caused significant ($P < 0.05$) decreases in the GSH-Px activities of liver in comparison to the control group. Administration of PJ and CBO to CCl₄-treated rats prevented the CCl₄-induced decreases in GSH-Px activities ($P < 0.05$). With respect to liver MDA level and GSH-Px activity, there was no significant difference among control, PJ and CBO groups. Liver GSH levels were significantly ($P < 0.05$) lower in the CCl₄ group than that in the control group. However, a significant ($P < 0.05$) increase was observed in the GSH level of CCl₄+PJ and CCl₄+CBO groups when compared to CCl₄ group. While the significant decreases were determined in the CAT activities of liver ($P < 0.001$) in CCl₄ group when compared to the control group, the administrations of PJ and CBO to CCl₄-treated rats significantly increased the decreased CAT activities in liver ($P < 0.001$). There was a significant difference between the CBO and the PJ groups in terms of CAT activity ($P < 0.001$). However, no statistical differences were observed in the CAT level of CCl₄+PJ group when compared to CCl₄+CBO group.

3. Histopathological findings in the liver: The histopathological changes observed in liver tissue are presented in Table 3. There was no abnormal

appearance or histological changes in the liver of control, PJ and CBO treated rats, of which hepatic cells well preserved with cytoplasm and had prominent nucleus, nucleolus and visible central veins (Figure 1A, B, C) Mild sinusoidal congestion was observed only in PJ- and CBO-treated groups. In addition, insignificant periportal cell infiltration and biliar duct proliferation were found only in CBO-treated group. However, marked hepatic damage was found in CCl₄ group. Periportal, periaciner and postnecrotic fibrosis, bile duct hyperplasia and oval cell proliferation, macrovesicular fatty change were the most frequent and distinctive findings in the liver samples in CCl₄-treated rats. Especially at periportal area, increasing fibrous connective tissue spread to liver parenchyma related to regenerative nodule formations in this group (Figure 1D). Mononuclear cell infiltrations in all fibrotic areas, especially in periportal areas, were present. In addition, significant Kupffer cell activations were observed in the periportal region. Along with hydropic degeneration, cellular necrosis, karyomegaly, intranuclear inclusion globules, and acini formations were noticed in hepatocytes. It was also observed that the periportal zone of hepatocytes contained two nuclei. Free or intracytoplasmic accumulation of dark yellow bile pigment was present in the periportal hepatocytes.

PJ or CBO consumption by CCl₄-treated rats was observed to decrease the CCl₄-induced the severity of all hepatic lesions except bile duct hyperplasia, hydropic degeneration in hepatocytes and periportal cell infiltrations (Figure 1E, F). Severity of periportal infiltrations was lesser in CCl₄+PJ, but not in CCl₄+CBO, when compared to alone CCl₄ group. Control (Figure 2A), PJ- (Figure 2B) and CBO-treated rat livers (Figure 2C) were similar, and they had also normal levels in terms of fibrous tissue in periportal areas when compared to CCl₄, CCl₄+PJ and CCl₄+CBO groups (Table 3). The fibrous tissue formations in periportal areas were determined as 71% in liver tissue stained with MT in CCl₄ group (Figure 2D). However, PJ and CBO consumption by CCl₄-treated rats significantly reduced ($P < 0.001$) the severity of periportal fibrosis at the rates of 43% and 51%, respectively when compared to alone CCl₄-treated rats (Figure 2E, F).

4. TUNEL findings: Apoptotic cell index in hepatocytes is presented in Table 3. Figures 3A, 3B and 3C illustrate apoptosis, demonstrated by TUNEL-staining, in the liver of control, alone PJ- and CBO-treated groups, respectively. No significant differences were detected among the control, PJ and CBO groups with respect to TUNEL positivity. The apoptotic cell index of CCl₄ group (Figure 3D) was significantly ($P < 0.001$) higher than that in the control, PJ and CBO groups. However, a significant ($P < 0.001$) decrease was observed in apoptotic cell index of CCl₄+PJ (Figure 3E) and CCl₄+CBO (Figure 3F) groups in comparison to only CCl₄ group. No significant difference was observed in TUNEL positivity between the CCl₄+PJ and CCl₄+CBO groups.

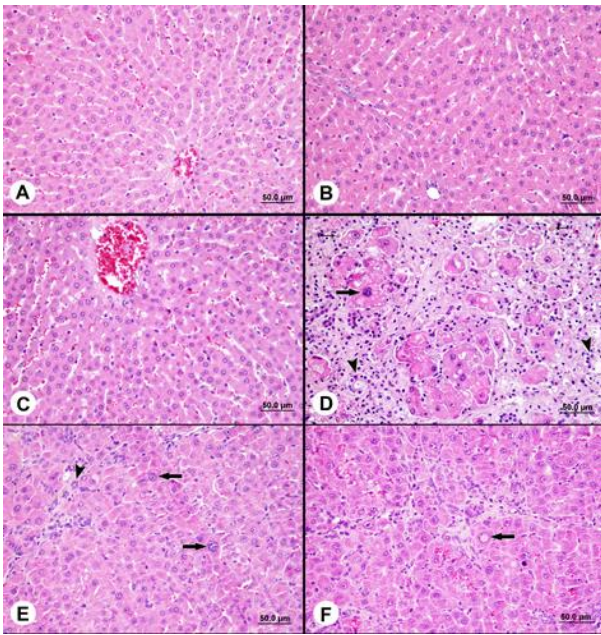


Figure1. Normal appearance of the livers in control (A), PJ (B) and CBO (C) groups, D. Appearance of postnecrotic fibrosis, bile duct hyperplasia (arrow heads), fatty degeneration, regenerative nodule formation, mononuclear cell infiltration, karyomegaly (thick arrow), accumulation of bile pigment (Thin arrows) in rat liver treated with CCl₄ for 10 weeks, E. Mild fibrosis, ovalocyte proliferation (arrow head) and karyomegaly (arrows) in CCl₄+PJ group F. Mild fibrosis, intranuclear inclusion globules (arrow) in CCl₄+CBO group (H&E x100).

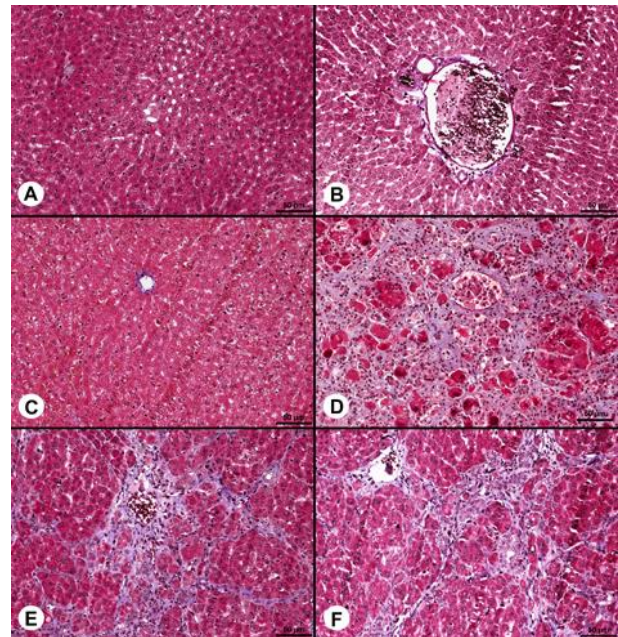


Figure2. Normal appearance of the livers in control (A), PJ (B) and CBO (C) groups, D. Appearance of severe fibrosis in rat liver in treated with CCl₄ for 10 weeks, E. Mild fibrosis in CCl₄+PJ group F. Mild fibrosis in CCl₄+CBO group (MT x50).

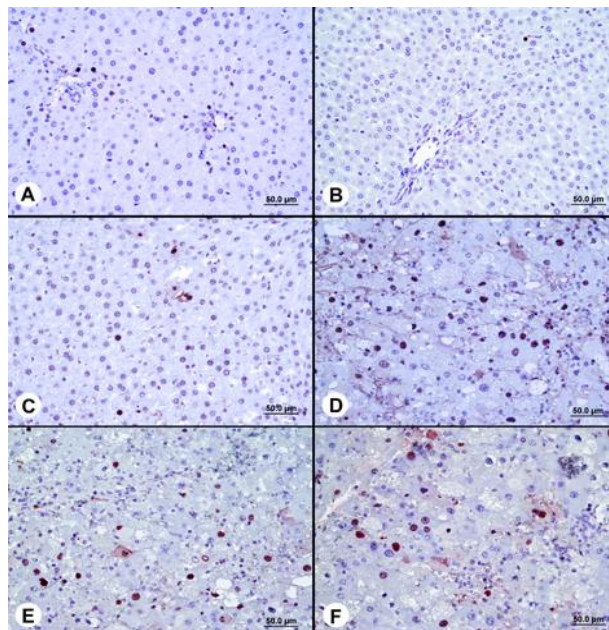


Figure3. TUNEL positivity in control (A), PJ (B) and CBO (C) groups, D. Marked increase in TUNEL+ staining in hepatocytes of CCl₄-treated group compared to the control, E. Decrease in TUNEL+ staining in hepatocytes of CCl₄+PJ group, F. Decrease in TUNEL+ staining in hepatocytes of CCl₄+CBO group (MT x200).

Table 1. Liver weight and liver index in control and treatment groups

	Groups						Significance
	Control	PJ	CBO	CCl ₄	CCl ₄ + PJ	CCl ₄ +CBO	
Liver weight (g)	10.57±0.79	10.00±0.42	11.00±0.34	9.04±0.95	8.86±1.40	9.57±0.41	NS
Liver index (liver weight/body weight x 100)	3.19±0.14	3.18±0.12	3.40±0.07	3.35±0.40	3.06±0.40	3.27±0.20	NS

PJ: pomegranate juice, CBO: cinnamon bark oil, CCl₄: carbon tetrachloride, NS: Non-significant.

Data are presented as mean ± SEM.

Table 2. Malondialdehyde (MDA) and reduced glutathione (GSH) levels, glutathione-peroxidase (GSH-Px) and catalase (CAT) activities in liver tissues of rats in control and treatment groups

	Groups						Significance
	Control	PJ	CBO	CCl ₄	CCl ₄ + PJ	CCl ₄ +CBO	
MDA (nmol/g protein)	9.57±0.52 ^a	9.36±1.81 ^a	10.30±0.36 ^a	21.15±1.01 ^b	7.66±0.62 ^a	8.93±0.74 ^a	P<0.01
GSH (nmol/g protein)	7.86±0.83 ^{ab}	9.57±2.06 ^a	6.66±0.21 ^{ab}	2.71±0.30 ^c	6.09±0.33 ^b	5.84±0.22 ^b	P<0.05
GSH-Px (IU/g protein)	2.90±0.30 ^a	3.62±0.61 ^a	2.94±0.34 ^a	0.55±0.12 ^b	2.13±0.46 ^a	2.49±0.82 ^a	P<0.05
CAT (k/g protein)	67.17±4.65 ^{ab}	88.41±8.88 ^a	61.72±7.54 ^b	20.43±5.75 ^c	54.93±8.63 ^b	43.38±7.39 ^b	P<0.001

PJ: Pomegranate juice, CBO: Cinnamon bark oil, CCl₄: Carbon tetrachloride. Data are presented as mean ± SEM.

a, b, c: The mean values having different superscripts within the same row significantly differ from each other.

Table 3. The existence and severity of some pathological lesions, percent of fibrotic areas in periportal region and apoptotic hepatocyte index in liver tissues of rats in control and treatment groups

Lesions	Groups						Significance
	Control	PJ	CBO	CCl ₄	CCl ₄ + PJ	CCl ₄ +CBO	
Karyomegaly	0.00±0.00 ^c	0.00±0.00 ^c	0.29±0.18 ^c	2.86±0.14 ^a	1.86±0.26 ^b	2.14±0.14 ^b	P<0.001
Binucleated hepatocytes	0.00±0.00 ^c	0.00±0.00 ^c	0.00±0.00 ^c	1.71±0.36 ^a	1.00±0.00 ^b	1.29±0.18 ^b	P<0.001
Oval cell proliferation	0.00±0.00 ^c	0.00±0.00 ^c	0.00±0.00 ^c	2.57±0.20 ^a	1.86±0.26 ^b	1.14±0.14 ^b	P<0.001
Kupffer cell activations	0.00±0.00 ^c	0.00±0.00 ^c	0.00±0.00 ^c	1.71±0.36 ^a	1.00±0.00 ^b	1.00±0.00 ^b	P<0.001
Periportal necrosis	0.00±0.00 ^b	0.00±0.00 ^c	0.00±0.00 ^b	0.86±0.34 ^a	0.0±0.00 ^b	0.00±0.00 ^b	P<0.001
Single cell necrosis	0.00±0.00 ^c	0.00±0.00 ^c	0.00±0.00 ^c	1.86±0.34 ^a	0.57±0.20 ^b	0.43±0.20 ^b	P<0.001
Sinusoidal congestion	0.00±0.00 ^d	0.57±0.20 ^c	0.71±0.18 ^b	1.71±0.36 ^a	1.00±0.00 ^b	1.00±0.00 ^b	P<0.001
Cloudy swelling	0.00±0.00 ^b	0.00±0.00 ^b	0.00±0.00 ^b	1.71±0.18 ^a	1.43±0.57 ^a	1.43±0.29 ^a	P<0.001
Fatty change	0.00±0.00 ^c	0.00±0.00 ^c	0.00±0.00 ^c	2.43±0.30 ^a	1.57±0.20 ^b	0.29±0.18 ^b	P<0.001
Periportal cell infiltration	0.00±0.00 ^c	0.00±0.00 ^c	0.14±0.14 ^c	1.43±0.20 ^a	0.71±0.18 ^b	1.29±0.18 ^a	P<0.001
Periportal fibrosis	0.00±0.00 ^c	0.00±0.00 ^c	0.00±0.00 ^c	2.14±0.14 ^a	1.29±0.36 ^b	1.14±0.40 ^b	P<0.001
Biliar duct proliferation	0.00±0.00 ^b	0.00±0.00 ^b	0.43±0.20 ^b	2.71±0.18 ^a	2.29±0.18 ^a	2.14±0.14 ^a	P<0.001
Periaciner fibrosis	0.00±0.00 ^c	0.00±0.00 ^c	0.00±0.00 ^c	0.86±0.20 ^a	0.57±0.14 ^b	0.57±0.20 ^b	P<0.001
Apoptotic body	0.00±0.00 ^c	0.00±0.00 ^c	0.00±0.00 ^c	2.14±0.14 ^a	0.86±0.14 ^b	0.86±0.26 ^b	P<0.001
Regenerative nodule formation	0.00±0.00 ^c	0.00±0.00 ^c	0.00±0.00 ^c	2.00±0.31 ^a	0.57±0.20 ^b	0.43±0.20 ^b	P<0.001
Intranuclear inclusion globules	0.00±0.00 ^c	0.00±0.00 ^c	0.00±0.00 ^c	1.14±0.14 ^a	0.57±0.20 ^b	0.43±0.20 ^b	P<0.001
Bile pigment accumulation	0.00±0.00 ^c	0.00±0.00 ^c	0.00±0.00 ^c	1.14±0.14 ^a	0.71±0.18 ^b	0.43±0.20 ^b	P<0.001
Postnecrotic fibrosis	0.00±0.00 ^c	0.00±0.00 ^c	0.00±0.00 ^c	1.43±0.20 ^a	0.71±0.18 ^b	0.86±0.14 ^b	P<0.001
Fibrotic areas in periportal region (%)	8.81±1.75 ^c	7.23±2.17 ^c	9.37±1.56 ^c	71.00±3.06 ^a	43.00±0.07 ^b	51.00±1.83 ^b	P<0.001
Apoptotic hepatocyte index (%)	2.57±0.20 ^c	3.29±0.64 ^c	3.14±0.80 ^c	29.14±1.74 ^a	12.57±0.92 ^b	13.86±0.74 ^b	P<0.001

PJ: Pomegranate juice, CBO: Cinnamon bark oil, CCl₄: Carbon tetrachloride. Data are presented as mean ± SEM.

a, b, c: The mean values having different superscripts within the same row significantly differ from each other.

Discussion

The present study demonstrates the protective and antioxidant effects of PJ and CBO against CCl₄-induced chronic liver damage in rats. The reaction between CCl₄ metabolites and polyunsaturated fatty acids causes formation of the covalent adducts with lipids and proteins that result in LPO and membrane damages with the consequent liver injury (24). The increase in liver MDA levels elicited by CCl₄ has been reported to overproduce LPO, leading to hepatic tissue damage and failure of antioxidant defense mechanisms to prevent formation of

excessive free radicals (25). In this study, elevated MDA levels observed in CCl₄ administered rats indicate hepatic damage, and also decreased MDA levels after PJ and CBO treatment suggest the free radical scavenging activity of these natural compounds. Previous studies have revealed that high antioxidant properties of pomegranate and its derivatives, such as juice, flower, peel and seeds on liver damage induced by various hepatotoxic chemicals (26-30). It has been also reported that the antioxidant effect of flavanoids that found in PJ improve the process of regeneration and accelerating the repair mechanism of damaged cell membrane (30).

Phytochemical screening of cinnamon bark has revealed the presence of flavonoids, glycosides, coumarins, alkaloids, anthraquinone, steroids, tannins and terpenoids (31). Phytoconstituents like the flavonoids (32), triterpenoids (33), saponins (34) and alkaloids (35) are known to possess hepatoprotective activity.

The main non-enzymatic antioxidant of cells is the GSH that involves in the metabolism of numerous toxic agents. GSH may block LPO by preventing free radical overproduction and by preserving cytochrome P450 (36). In this study, CCl₄ administration led to a significant decrease in the GSH level which can be an important factor in the CCl₄ toxicity. However, long-term PJ and CBO administration to CCl₄-treated rats significantly increased the hepatic GSH levels. It has been reported that the mechanism of hepatoprotection by PJ against CCl₄ toxicity might be due to restoration of the GSH level (30) which is an agreement with our findings. These findings were also supported by the histopathological and TUNEL analyses of liver tissues in groups treated with PJ and CBO in the present study.

CAT and GSH-Px are the other cellular antioxidants and they catalyse H₂O₂ to water. In this study, CCl₄ administration declined the activity of the antioxidant enzymes in liver, which is confirmed by previous study (37). PJ having different classes of polyphenols and flavonoids has been shown to prevent the reductions in GSH-Px and CAT activities by its positive effect on antioxidant enzyme activities in vivo (30,38). In addition, *C. zeylanicum* ethanolic extract (16) and *C. vernum* ethanolic or aqueous extract (13) consumption has been reported to improve significantly antioxidant enzyme activities in CCl₄-treated rats. Treatment of rats with CCl₄ significantly reduced the activities of liver GSH-Px and CAT at the rates of 81% and 70%, respectively in this study. However, treatment of the rats with the PJ and CBO prevented the CCl₄-induced decreases in GSH-Px and CAT activities, which are comparable with the control values in the present study. This shows the protection provided by PJ and CBO consumption by rats depending on maintaining the levels of these enzymes even after CCl₄ treatment.

It has been reported that oxidative stress is one of the pathologic mechanisms of hepatic fibrosis (39). The increased MDA levels result from the reaction between free radicals and polyunsaturated fatty acids under high oxidative stress (40) increase the collagen synthesis (39, 41, 42). The excessive levels of reactive oxygen species generated by CCl₄-damaged liver cells have been reported to affect stellate cell activation and to enhance the production of the extracellular matrix, containing collagen (43). The antioxidant substances within the PJ have been alleged to decline the amount of connective tissue in liver by means of their positive effects on down-regulation of excessive expression of fibrogenic cytokines and collagenes (44). Flavonoids have counteractive effect on collagen accumulation that is the

early stage of the fibrotic process (45), and they increase the activity of protective enzymes (46, 47). It has been postulated that the beneficial strategies are the activation of antioxidant and the inhibition of LPO for preventing of early stage hepatic fibrogenesis (48). CCl₄ has been reported to cause necrosis (28), fibrosis (30), inflammatory cell infiltration (49), fatty accumulation and degeneration of hepatocytes (16, 49), increases in mitotic activity (50) and cirrhosis (51) in liver. Aforementioned histopathological lesions determined by different researchers are exactly similar to our findings found in the liver tissue after CCl₄ treatment. Besides, in the present study, the CCl₄-induced histopathological findings were significantly decreased by PJ and CBO treatment. The protective effect exerted by the PJ (28, 30) and CBO (16) against CCl₄-induced liver damage was confirmed by conventional histological examination. In the present study, CCl₄ treatment caused ~8-fold increase in periportal fibrosis as compared to control. However, hepatic tissues of CCl₄+PJ and CCl₄+CBO groups showed consistent reduction in the liver fibrosis and the cirrhotic process. Especially, Masson's trichrome staining showed more regular liver architecture, in which only thin fibrous bands connecting portal areas were seen in CCl₄+PJ and CCl₄+CBO treatment groups compared to alone CCl₄ group.

It has been reported that CCl₄ causes apoptosis in liver (30, 50, 52). Apoptosis is the first step lesion observed in the hepatic tissue. Apoptosis and proinflammatory cytokine genes, which are inhibited during the engulfing of apoptotic bodies by macrophages (53), have been suggested to involve in liver fibrosis induced by CCl₄ (54, 55). It has been reported that CCl₄ substantially affect the cytokine-related genes (56). In addition, DNA fragmentation along with oxidative stress has been reported to play a crucial role in CCl₄-induced hepatotoxicity leading increased apoptotic liver cells (57). There was an about 12-fold increase in apoptosis in CCl₄ group in comparison to the control group in this study. However, we found that PJ and CBO consumption markedly decreased the number of TUNEL-positive cells in rats treated with CCl₄. In the present study, increased LPO induced by decreased CYP activity after CCl₄ administration might have possibly caused the liver histopathological damages and increase in the liver apoptotic index.

It was concluded that two herbal antioxidants, PJ and CBO, have ability to prevent the CCl₄ damages in liver tissue rats. The hepatoprotective effects of PJ and CBO are possibly due to the reductions in liver fibrogenesis and apoptosis associated with the prevention of CCl₄-induced oxidative stress. These actions of PJ and CBO are of significant clinical importance in the prevention of alcohol abusing- or other xenobiotics-induced liver damages show similarity to the CCl₄-intoxication model.

References

1. Wolf PL. Biochemical diagnosis of liver disease. *Indian J Clin Biochem* 1999; 14: 59-65.
2. Johnston DE, Kroening C. Mechanism of early carbon tetrachloride toxicity in cultured rat hepatocytes. *Pharmacol Toxicol* 1998; 83: 231-239.
3. Bruck R, Schey R, Aeed H, et al. A protective effect of pyrrolidine dithiocarbamate in a rat model of liver cirrhosis. *Liver Int* 2004; 24: 169-176.
4. Subramoniam A, Pushpangadan P. Development of phytomedicines for liver disease. *Indian J Pharmacol* 1999; 31: 166-175.
5. Nichols JA, Katiyar SK. Skin photoprotection by natural polyphenols: anti-inflammatory, antioxidant and DNA repair mechanisms. *Arch Dermatol Res* 2010; 302: 71-83.
6. Viuda-Martos M, Fernández-López J, Pérez-Álvarez JA. Pomegranate and its many functional components as related to human health: A review. *Compr Rev Food Sci F* 2010; 9: 635-654.
7. Johanningsmeier SD, Harris GK. Pomegranate as a functional food and nutraceutical source. *Annu Rev Food Sci Technol* 2011; 2: 181-201.
8. Jayaprakasha GK, Rao LJM. Chemistry, biogenesis, and biological activities of *Cinnamomum zeylanicum*. *Crit Rev Food Sci Nutr* 2011; 51: 547-562.
9. Gruenwald J, Freder J, Armbruster N. Cinnamon and health. *Crit Rev Food Sci Nutr* 2010; 50: 822-834.
10. Azab KS, Mostafa AHA, Ali EMM, Abdel-Aziz MAS. Cinnamon extract ameliorates ionizing radiation-induced cellular injury in rats. *Ecotoxicol Environ Saf* 2011; 74: 2324-2329.
11. Jayaprakasha GK, Ohnishi-Kameyama M, Ono H, Yoshida M, Rao LJ. Phenolic constituents in the fruits of *Cinnamomum zeylanicum* and their antioxidant activity. *J Agric Food Chem* 2006; 54: 1672-1979.
12. Lamfon NA. Cinnamon aqueous extract ameliorates deltamethrin-induced hepatotoxicity in albino rats. *RJPBCS* 2014; 5: 898-905.
13. Moselhy SS, Ali HH. Hepatoprotective effect of cinnamon extracts against carbon tetrachloride induced oxidative stress and liver injury in rats. *Biol Res* 2009; 42: 93-98.
14. Prasad KN, Yang B, Dong X, et al. Flavonoid contents and antioxidant activities from *Cinnamomum* species. *Innov Food Sci Emerg Tech* 2009; 10: 627-632.
15. Yüce A, Türk G, Çeribaşı S, et al. Effectiveness of cinnamon (*Cinnamomum zeylanicum*) bark oil in the prevention of carbon tetrachloride-induced damages on male reproductive system. *Andrologia* 2014; 46: 263-272.
16. Eidi A, Mortazavi P, Bazargan M, Zaringhalam J. Hepatoprotective activity of cinnamon ethanolic extract against CCl₄-induced liver injury in rats. *EXCLI Journal* 2012; 11: 495-507.
17. Türk G, Çeribaşı S, Sönmez M, et al. Ameliorating effect of pomegranate juice consumption on carbon tetrachloride-induced sperm damages, lipid peroxidation and testicular apoptosis. *Toxicol Ind Health* 2016; 32: 126-137.
18. Placer ZA, Cushman LL, Johnson BC. Estimation of product of lipid peroxidation (malonyl dialdehyde) in biochemical systems. *Anal Biochem* 1966; 16: 359-364.
19. Sedlak J, Lindsay RH. Estimation of total, protein-bound and nonprotein sulfhydryl groups in tissue with Ellman's reagent. *Anal Biochem* 1968; 25: 192-205.
20. Lawrence RA, Burk RF. Glutathione peroxidase activity in selenium-deficient rat liver. *Biochem Biophys Res Commun* 1976; 71: 952-958.
21. Aebi H. Catalase. In: Bergmeyer HU, (Editor). *Methods in Enzymatic Analysis*. 3rd Edition, New York, USA: Academic Press; 1983: 276-286.
22. Lowry OH, Rosebrough NJ, Farr AL, Randall RJ. Protein measurement with folin phenol reagent. *J Biol Chem* 1951; 193: 265-275.
23. Das RK, Hossain U, Bhattacharya S. Protective effect of diphenylmethyl selenocyanate against CCl₄ induced hepatic injury. *J Appl Toxicol* 2007; 27: 527-537.
24. Szymonik-Lesiuk S, Czechowska G, Stryjecka-Zimmer M, et al. Catalase, superoxide dismutase, and glutathione peroxidase activities in various rat tissues after carbon tetrachloride intoxication. *J Hepatobiliary Pancreat Surg* 2003; 10: 309-315.
25. Souza MF, Rao VSN, Silveira ER. Inhibition of lipid peroxidation by ternatin, a tetramethoxyflavone from *Egletes viscosa* L. *Phytomedicine* 1997; 4: 25-29.
26. Celik I, Temur A, Isik I. Hepatoprotective role and antioxidant capacity of pomegranate (*Punica granatum*) flowers infusion against trichloroacetic acid-exposed rats. *Food Chem Toxicol* 2009; 47: 145-149.
27. Faria A, Monteiro R, Mateus N, Azevedo I, Calhau C. Effect of pomegranate (*Punica granatum*) juice intake on hepatic oxidative stress. *Eur J Nutr* 2007; 46: 271-278.
28. Pirinccioglu M, Kizil G, Kizil M, Kanay Z, Ketani A. The protective role of pomegranate juice against carbon tetrachloride-induced oxidative stress in rats. *Toxicol Ind Health* 2012; 30: 910-918.
29. Singh RP, Chidambara MKN, Jayaprakasha GK. Studies on the antioxidant activity of pomegranate (*Punica granatum*) peel and seed extracts using in vitro models. *J Agric Food Chem* 2002; 50: 81-86.
30. Yehia HM, Al-Olayan EM, Elkhadragey MF. Hepatoprotective role of the pomegranate (*Punica Granatum*) juice on carbon tetrachloride-induced oxidative stress in rats. *Life Sci* 2013; 10: 1534-1544.
31. Shihabudeen MS, Priscilla H, Thirumurugan K. Cinnamon extract inhibits α -glucosidase activity and dampens postprandial glucose excursion in diabetic rats. *Nutr Metab* 2011; 8: 1-11.
32. Baek NL, Kim YS, Kyung JS, Park KH. Isolation of anti-hepatotoxic agents from the roots of *Astragalus membranaceus*. *Korean J Pharmacog* 1996; 27: 111-116.
33. Xiong X, Chen W, Cui J, et al. Effects of ursolic acid on liver protection and bile secretion. *Zhong Yao Cai* 2003; 26: 578-581.
34. Tran QI, Adnyana IK, Tezuka Y, et al. Triterpene saponins from *Vietnamese ginseng (Panax*

- vietnamensis*) and their hepatocyte protective activity. *J Nat Prod* 2001; 64: 456-461.
35. Vijayan P, Prashanth HC, Dhanraj SA, Badami S, Suresh B. Hepatoprotective effect of total alkaloid fraction of *Solanum pseudocapsicum* leaves. *Pharmaceut Biol* 2003; 41: 443-448.
 36. Levin W, Lu AY, Jacobson M, et al. Lipid peroxidation and the degradation of cytochrome P-450 heme. *Arch Biochem Biophys* 1973; 158: 842-852.
 37. Shahjahan M, Sabitha KE, Jainu M, Shyamala C, Devi S. Effect of *Solanum trilobatum* against carbon tetrachloride induced hepatic damage in albino rats. *Indian J Med Res* 2004; 120: 194-198.
 38. Yuan LP, Chen FH, Ling L, et al. Protective effects of total flavonoids of *Bidens bipinnata* L. against carbon tetrachloride induced liver fibrosis in rats. *J Pharm Pharmacol* 2008; 60: 1393-1402.
 39. Parola M, Robino G. Oxidative stress-related molecules and liver fibrosis. *J Hepatol* 2001; 35: 297-306.
 40. de Zwart LL, Meerman JH, Commandeur JN, Vermeulen NP. Biomarkers of free radical damage applications in experimental animals and in humans. *Free Radic Biol Med* 1999; 26: 202-226.
 41. Biasi F, Tessitore L, Zanetti D, et al. Associated changes of lipid peroxidation and transforming growth factor beta1 levels in human colon cancer during tumour progression. *Gut* 2002; 50: 361-367.
 42. Ghezzi P, Bonetto V. Redox proteomics: identification of oxidatively modified proteins. *Proteomics* 2003; 3: 1145-1153.
 43. Nieto N, Friedman SL, Cederbaum AI. Stimulation and proliferation of primary rat hepatic stellate cells by cytochrome P450 2E1-derived reactive oxygen species. *Hepatology* 2002; 35: 62-73.
 44. Poli G, Parola M. Oxidative damage and fibrogenesis. *Free Radic Biol Med* 1997; 22: 287-305.
 45. Iszard MC, Liu J, Klaassen CD. Effect of several metallothionein inducers on oxidative stress defense mechanisms in rats. *Toxicology* 1995; 104: 25-33.
 46. Myhrstad MCW, Carlsen H, Nordström O, Blomhoff R, Moskaug JO. Flavonoids increase the intracellular glutathione level by transactivation of the γ -glutamylcysteine synthetase catalytical subunit promoter. *Free Radic Biol Med* 2002; 32: 386-393.
 47. Wang BJ, Liu CT, Tseng CY, Wu CP, Yu ZR. Hepatoprotective and antioxidant effects of *Bupleurum kaoli* Liu (Chao et Chuang) extract and its fractions fractionated using supercritical CO₂ on CCl₄-induced liver damage. *Food Chem Toxicol* 2004; 42: 609-617.
 48. Friedman SL. Liver fibrosis-from bench to bedside. *J Hepatol* 2003; 38: 38-53.
 49. Vuda M, D'souza R, Upadhyaya S, et al. Hepatoprotective and antioxidant activity of aqueous extract of *Hybanthus enneaspermus* against CCl₄-induced liver injury in rats. *Exp Toxicol Pathol* 2012; 64: 855-859.
 50. Kükner A, Töre F, Fırat T, et al. The preventive effect of low molecular weight heparin on CCl₄-induced necrosis and apoptosis in rat liver. *Ann Hepatol* 2010; 9: 445-454.
 51. Zalatnai A, Sarosi I, Rot A, Lapis K. Inhibitory and promoting effects of carbon tetrachloride-induced liver cirrhosis on the diethylnitrosamine hepatocarcinogenesis in rats. *Cancer Lett* 1991; 57: 67-73.
 52. Shi J, Aisaki K, Ikawa Y, Wake K. Evidence of hepatocyte apoptosis in rat liver after the administration of carbon tetrachloride. *Am J Pathol* 1998; 153: 515-525.
 53. Fadok VA, Bratton DL, Konowal A, et al. Macrophages that have ingested apoptotic cells in vitro inhibit proinflammatory cytokine production through autocrine/paracrine mechanisms involving TGF- β , PGE₂, and PAF. *J Clin Invest* 1998; 101: 890-898.
 54. Lee JI, Lee KS, Paik YH, et al. Apoptosis of hepatic stellate cells in carbon tetrachloride induced acute liver injury of the rat: analysis of isolated hepatic stellate cells. *J Hepatol* 2003; 39: 960-966.
 55. Oakley F, Meso M, Iredale JP, et al. Inhibition of inhibitor of kappa B kinases stimulates hepatic stellate cell apoptosis and accelerated recovery from rat liver fibrosis. *Gastroenterology* 2005; 128: 108-120.
 56. Wang T, Li-Jun Z, Ping L, et al. Hepatoprotective effects and mechanisms of dehydrocavidine in rats with carbon tetrachloride-induced hepatic fibrosis. *J Ethnopharmacol* 2011; 138: 76-84.
 57. Kamel HH, Azza HA, Walaa MSA, Amira HM. Protective Effect of some Antioxidants against CCl₄-Induced Toxicity in Liver Cells from BRL3A Cell Line. *J American Sci* 2010; 6: 992-1003.