

See discussions, stats, and author profiles for this publication at: <https://www.researchgate.net/publication/280308449>

A New Surgical Technique for the Repair of the Achilles Tendon Rupture: Repair of the Achill Tendon Rupture by Implant without Immobilization and Compared with Traditional Suture T...

Article in *Kafkas Üniversitesi Veteriner Fakültesi Dergisi* - January 2010

CITATIONS

4

READS

305

8 authors, including:



Akgun Alsaran

Anadolu University

55 PUBLICATIONS 1,252 CITATIONS

SEE PROFILE



Onur Hapa

Dokuz Eylul University

80 PUBLICATIONS 927 CITATIONS

SEE PROFILE



Kenan Koca

Healt Sience University, Gulhane Hospital, Turkey

7 PUBLICATIONS 29 CITATIONS

SEE PROFILE



Mahmut Sozmen

Ondokuz Mayıs Üniversitesi

92 PUBLICATIONS 668 CITATIONS

SEE PROFILE

Some of the authors of this publication are also working on these related projects:



Bare area on the trochanter and its correlations to gluteal tendon insertion dimensions [View project](#)



The Effects of Periostin in a Rat Model of Isoproterenol - Mediated Cardiotoxicity [View project](#)

A New Surgical Technique for the Repair of the Achilles Tendon Rupture: Repair of the Achill Tendon Rupture by Implant without Immobilization and Compared with Traditional Suture Techniques in Rabbits ^[1]

Hayati AYGÜN *  Engin KILIÇ ** Ülfettin HÜSEYİNOĞLU *** İsa ÖZAYDIN ** C. Şahin ERMUTLU **
Akgün ALSARAN **** Onur HAPA ***** Kenan KOCA ***** Mahmut SÖZMEN *****

[1] *This study was presented in 11th National Veterinary Surgery Congress, 19th-22nd May 2010, Belek - Antalya, Turkey*

* Department of Orthopaedic Surgery, Faculty of Medicine, Kafkas University, TR-36100 Kars - TURKEY

** Department of Surgery, Faculty of Veterinary Medicine, Kafkas University, TR-36100 Kars - TURKEY

*** Department of Anesthesiology, Faculty of Medicine, Kafkas University, TR-36100 Kars - TURKEY

**** Department of Mechanical Engineering, Faculty of Engineering, Atatürk University TR-25100 Erzurum - TURKEY

***** Department of Orthopaedic Surgery, Faculty of Medicine, M. Kemal University TR-31115 Hatay - TURKEY

***** Department of Orthopaedic Surgery, Gulhane Military Medicine Academy TR-06010 Ankara - TURKEY

***** Department of Pathology, Faculty of Veterinary Medicine, Kafkas University, TR-36100 Kars - TURKEY

Makale Kodu (Article Code): KVFD-2010-1546

Summary

Purpose of this study was to repair achilles tendon rupture with protection of the integrity of the tendon without the need for the joint immobilization and prevent the complications reported with other techniques. For this purpose, mostly used techniques, Krackow, Modified Kessler, Bunnell techniques were compared with the newly developed technique using the objective histologic and biomechanic criteria. Depending on the preliminary results of the pull-out tests, 6 tendons were included at each group, consisting of four groups totally. Operations were performed under the anesthesia of xylazine hydrochlorur, bupivacain HCl. At group 1, imlant prepared from the flexible polyethylene material was used. Krackow technique at group 2, Modified Kessler technique at group 3, Bunnell technique at group 4 were utilized. Rabbits were euthanised at 6th week postoperatively by use of overdose of sodium pentobarbital (50 mg/kg). While there was no difference between groups at histological analysis, at biomechanical analysis ultimate load to failure was found to be higher than all other techniques. Depending on these results, newly described technique can be applied clinically and may help to solve this orthopaedic problem.

Keywords: *Achilles tendon, Rupture, Surgical treatment, Rabbit, Calcaneal tendon, Biomechanic, Immobilisation*

Aşıl Tendon Ruptürlerinde Yeni Bir Cerrahi Yöntem: Tavşan Aşıl Tendon Ruptürlerinin İmmobilizasyon Yapılmaksızın İmplant İle Onarımı ve Geleneksel Dikiş Yöntemleriyle Karşılaştırılması

Özet

Bu çalışmayla eklemleri immobilize etme gereği olmadan ve tendon bütünlüğü mümkün olduğunca korunarak aşıl tendon ruptürlerinin onarılması ve diğer tekniklerde bildirilen komplikasyonların önemli bir bölümünün önlenmesi amaçlandı. Bunun için günümüzde en sık kullanılan Krackow, Modifiye Kessler ve Bunnell sütün tekniklerinin uygulandığı üç ayrı kontrol grubu ve geliştirilen tekniğe ait sonuçlar biyomekanik objektif kriterlere göre karşılaştırılması yapıldı. Demonstrasyon olgularından elde edilen çekme deneylerinin sonuçları dikkate alınarak her grupta 6 denek olacak şekilde 4 ayrı grup oluşturuldu. Operasyonlar xylazine hidroklorür (Rompun 2% -Bayer) sedasyonunu izleyerek bupivacain HCl (Marcaine 0,05- Eczacıbaşı) ile elde edilen spinal anestezi altında gerçekleştirildi. I. Grupta üzerinde delikler açılarak önceden hazırlanan fleksibl polietilen materyalden hazırlanmış implant kullanıldı. II. grupta Krackow, III. grupta Modifiye Kessler, IV. grupta ise Bunnell dikiş teknikleri uygulanarak ruptür onarıldı. Denekler postoperatif 6.haftada overdose sodium pentobarbital (50 mg/kg) kullanılarak ötenazi edildi. Histopatolojik açıdan gruplar arasında önemli bir fark saptanamazken, biyomekanik test sonuçları dikkate alındığında geliştirilen tekniğe göre hem tendonun maksimum dayanacağı yük hem de uzama miktarı literatürdeki bütün tekniklere göre oldukça yüksek bulundu. Bu sonuç geliştirilen tekniğin maksimum dayanım sınırından sonra bile belirli bir süre daha yük taşımaya devam ettiğini göstermektedir. Buradan elde edilen sonuçlardan aynı tekniğin insan modellerinde de uygulanabileceği kanısına varılırken, tekniğin insan modellerinde başarılı olması durumunda bu alanda çok önemli bir ortopedik problemin sorunsuz bir şekilde çözüme kavuşturulabileceği söylenebilir.

Anahtar sözcükler: *Aşıl tendon, Ruptür, Cerrahi yöntem, Tavşan, Kalkaneal tendon, Biyomekanik, İmmobilizasyon*



İletişim (Correspondence)



+90 474 2426800



haygun2002@yahoo.com & drenginkilic@hotmail.com

INTRODUCTION

Tendons transmitting the tension forces between muscle-bone units are formed from the parallel fibrils located at the extracellular matrix. Achilles tendon is the broadest, strongest tendon in the human body and exposed to higher stresses and trauma leading to more frequent ruptures^{1,2}. Ruptures are mostly seen on area 3-6 cm proximal to the calcaneal insertion due to decreased intravascular volume. Mostly middle aged men dealing with tennis, football, badminton requiring sudden acceleration, deceleration suffer from the ruptures.

Although many surgical techniques are described in the literature, these are insufficient for ideal healing due to insufficiency of the technique itself or requirement of long term postoperative immobilization. There is no total consensus about the technique, incision line, suture material, postoperative procedures, and patient follow-up³⁻⁷. Purpose of the surgery is to maintain appropriate healing area for normal tendon structure anatomically as well as histologically.

Tendon repair must withstand the early biomechanical load. Ideally tendon repair permits early mobilization while being strong and reliable^{8,9}. Present surgical techniques lead to complications like skin necrosis, delayed wound healing, early, late tendon adhesions, painful scar formation. Additionally sutures may slip through the tendon and loosen due to parallel orientation of tendon fibers or may cause local ischemia due to wrap by sutures all around of the tendon^{3,6,7,8}.

Aim of the present study is to prevent the complications reported for other techniques in Achilles tendon repair preserving as much as possible blood circulation of the tendon without any immobilization of the joints. At the present study, common used suture techniques consist of Modified Kessler, Krackow, Bunnel were compared with the newly described technique using histological, biomechanical parameters.

MATERIAL and METHODS

Thirty-six healthy male White New Zealand rabbits 12 to 18 months old, 2.5 to 3.1 kg in body weight were used in the study. Four groups were created nine animals in each group. New described suture technique was applied to first group, Krackow suture was applied to second group, Modified Kessler suture was applied to third group, and Bunnel suture was applied to fourth group.

Firstly, three rabbits from each groups were euthanized

by an over dose of sodium phenobarbital (50 mg/kg) and both of Achilles tendons were removed with bony and muscular components. The tendon were ruptured at mild part that was repaired using sutures techniques in this study. Then, biomechanical tests were performed over these tendons.

Remaining rabbits in each group were observed than applied sutures techniques.

Rabbits were for fasted 12 h prior to the operation and they were sedated with Xylazine HCl (Rompun® 2% - Bayer) at a dose of 5 mg/kg of body weight. IM. Following, 10 min of sedation, spinal anesthesia was induced into the intrathecal space by administration of Bupivacain HCl (Marcaine® Heavy %0.5 - Astra Zeneca) at a dose of 1 mg/kg of body weight.

The Achilles tendon was exposed after median skin incision. A rupture was created at the area of 2 cm proximal to the calcaneal insertion site. At Group 1 implant prepared from the flexible polyethylen material, having holes at each side with 12 holes totally, was utilized. Tendon stumps were approximated by two simple sutures and then graft was fixed to repair site with three pairs of 3.0 polyglactin 910 (Vicryl-Ethicon) sutures having 0.5 cm of tissue bridge in between, proximally and distally. Implant was centralized; sutures were passed through the middle part of the tendon, so the edges of tendon were not affected (*Fig. 1,2*).

Same procedures were applied to other groups. Krackow technique (control I), Modified Kessler (control II), Bunnel technique (control III) were utilized for control groups (*Fig. 3*).

We did not apply any joint immobilization and external support postoperatively. After full recovery from spinal anesthesia all rabbit were mobilized freely.

Postoperatively the rabbits received procaine penicillin (40.000 IU/kg body weight) for 7 days intramuscularly. All rabbits were euthanized 6 weeks after operation by an overdose of sodium penthobarbital (50 mg/kg).

After macroscopic examination, the tendon parts were removed and fixed in the 10% neutral buffered formalin. The specimens embedded in paraffin, sectioned and stained with hematoxylin and eosin. All tissues were assessed under light microscope at 5, 10 and 40x powers.

RESULTS

Clinical Findings

At postoperative 10, 20, 30, 42 days on physical




Fig 1. a- İmplant, b- Approximation sutures, c- use of implant for the tendon repair

Şekil 1. a- Çalışmada kullanılan implant, b- Yaklaştırma sutureleri, c- İmplantın tamir için kullanılması

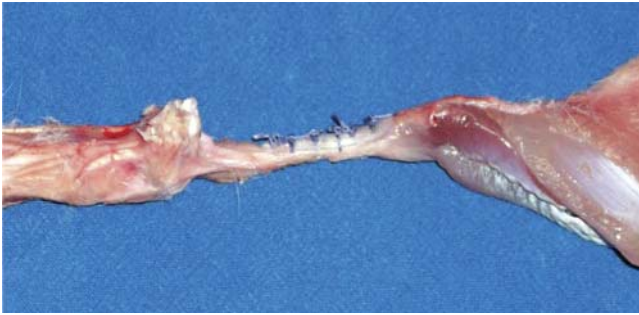

Fig 2. Postoperative appearance of the implant used new suture technique

Şekil 2. İmplant kullanılarak gerçekleştirilen yeni suture tekniğinin görünümü

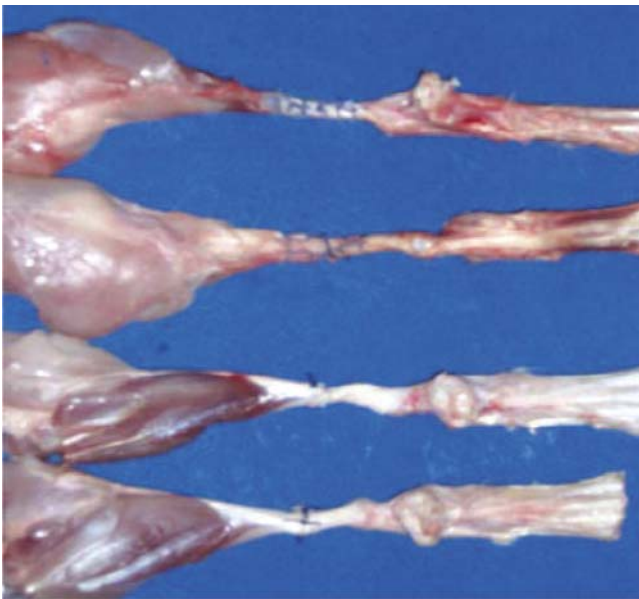


Fig 3. Suture techniques using tenorrhaphy (top-down): New technique, Krackow, Bunnell, and Kesler

Şekil 3. Çalışmada kullanılan tendon tamir teknikleri (yukarıdan aşağıya): Yeni teknik, Krackow, Bunnell ve Kessler

examination of the operation area revealed mild mass effect due to graft material without any inflammatory signs in group I.

At first day of postoperation, rabbits were limping mildly in study group, but lost of Achilles tendon function were observed at two rabbits in group two (in control group 1). At second day lost of Achilles tendon function all of rabbits in group 2, four rabbits in group 3 and four rabbits in group 4 were observed.

At three days, rabbits in all groups except for the study groups had been observed to lose Achilles tendon function. Lost of Achilles tendon function was considered as Achilles tendon ruptures.

Macroscopic Findings

In group 1 tendon ends were so regular and graft material was surrounded by a thin layer of tissue. In other groups, three tendons demonstrated tissue thickening with adhesion at repair zone to the surrounding tissues (Fig. 4 A,B).

Biomechanical Test Results

Pull-out tests were performed using Shimadzu testing machine (AG-50kNG Shimadzu Autograph) (Fig. 5 A,B). Results of the groups with pullout test for the suture used are summarized in Fig. 6. Highest Ultimate load was in the study group (mean 77 ± 11.9 N). Other groups' values were as follows: Krackow was 67.5 ± 13.4 N, Modified Kessler was 29.5 ± 5.78 N, and Bunnell was 35 ± 8.2 N. Suture had the mean value of 15 N. After the maximum load is reached, tendon lengthening was found to be the highest in the study group. In Krackow group, there was a sudden decrease of the load values after reaching the maximum load with separation of the tendon ends (Fig. 6). Additionally heterogeneous deformation area, the amount of lengthening of the tendon after

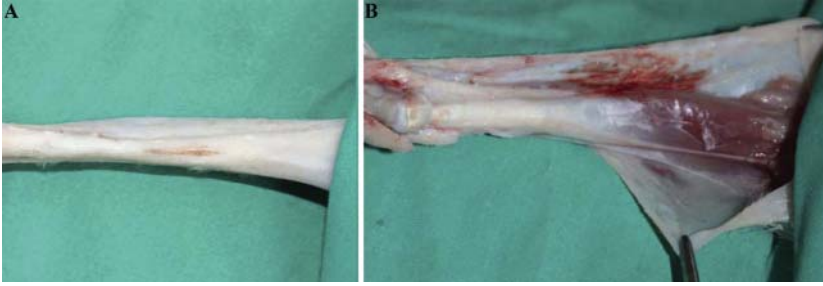


Fig 4. A. Macroscopic appearance of repaired tendon ruptures with implant, **B.** tendon and implant were wrapped by paratenon

Şekil 4. A. Deneklerin ötenazi edilmesinden sonra implant ile tamir edilmiş tendonların makroskopik görünümü **B.** İmplant ile birlikte paratenon tarafından çok iyi sarılan tamir edilmiş tendon

Fig 5. Biomechanical testing of new technique (**A, B**)

Şekil 5. Yeni tekniğin biyomekanik testi (**A, B**)

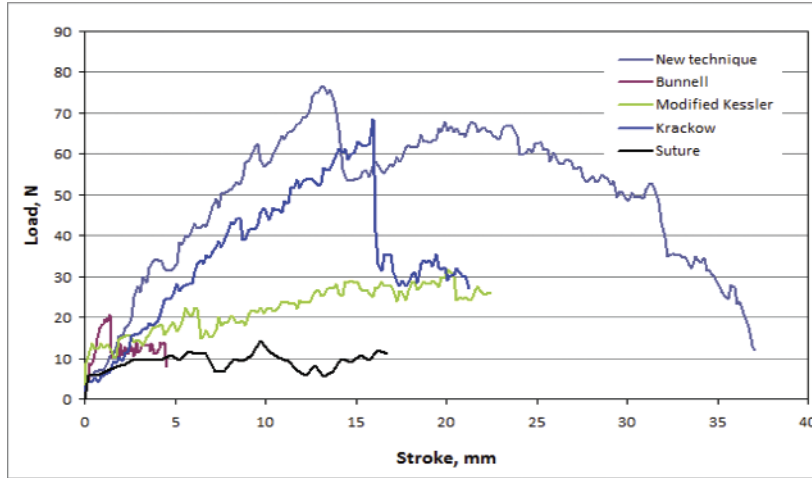
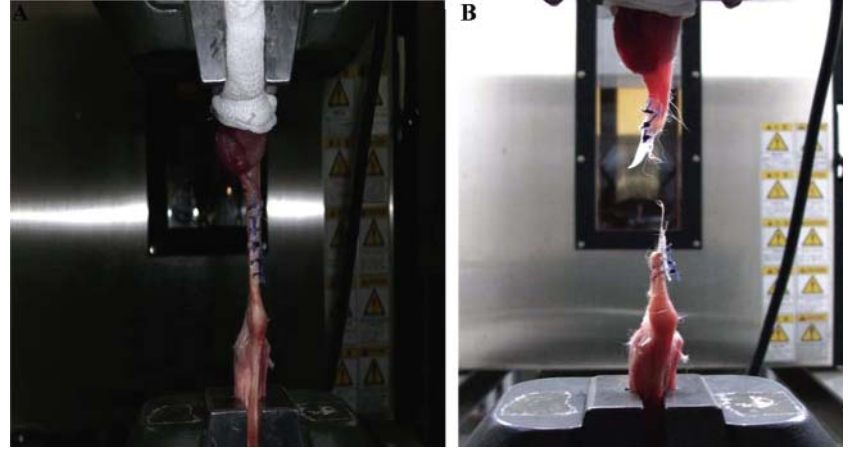


Fig 6. Biomechanical data of all the techniques used in the study

Şekil 6. Çalışmada yer alan tüm tekniklerin biyomekanik verileri

maximum load, was detected to be almost two times the lengthening until the maximum load in study group.

In statistical analysis, there was significant difference between groups for maximum load to failure ($P < 0.001$, Kruskal- Wallis test). When groups were analyzed separately, maximum load to failure values of study, Krackow groups were higher than Bunnell, Modified Kessler groups while there was no significant difference between Krackow, study groups ($P < 0.008$, Mann-Whitney U Test).

Histopathological Findings

There was no difference between groups regarding the histopathologic analysis. Microscopic examination

of tendons showed that union of the tendon ends filled by proliferating tissue originating from tendon sheath (*Fig. 7*). The gap measured between cut surfaces of tendon ends filled by granulation tissue was approximately 4.75 mm. The granulation tissue originating from the tendon sheath penetrating the gap was partly immature showing moderate cellularity and vascularity. The collagen fibers in the connective tissue tended to be oriented longitudinally as in mature counterparts. In the immature parts, the nuclei of the fibroblasts were plumb, larger with no sign of mitosis. Early co-crimping of tendon fiber bundles indicating elastin formation was seen on longitudinal sections. In study group there was no foreign body reaction at any of the specimens.

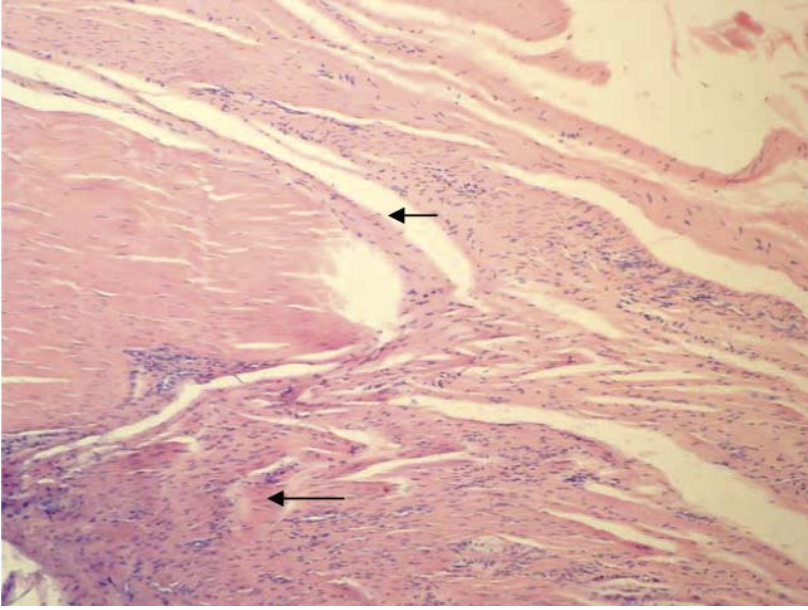


Fig 7. Longitudinal section of tendon showing growth of granulation tissue from the sheath (short arrow). Some fibrocytes are tended to be arranged parallel to the newly formed collagen fibers (long arrow), a pattern similar to that of normal tendon healing. (H&E, x10)

Şekil 7. Uzunlamasına kesitte tendo kılıfından gelişen granulasyon dokusu (kısa ok). Bazı fibrositlerin, normal tendo iyileşmesine benzer şekilde, yeni şekillenen kollajen liflerine paralel olarak geliştiği görülmekte (uzun ok). (H&E, x10)

DISCUSSION

Primary purpose of the tendon repair is early mobilization, usage of the involved extremity ^{3,4,6,8}. Most studies support that immobilization affect negatively tendon repair while early mobilization increasing tendon revascularization increasing speed of the physiologic healing ^{8,10,11}. To provide this, repair technique chosen must not cause tissue damage, increase nutrition problems and support repair zone mechanically.

Success of techniques reported in the literature depend on the suture material itself ^{6,12,13}. Rupture or lengthening of the suture result in separation at the anastomosis site or slippage of the suture through the tendon and failure of the treatment ^{5,6,8,10,12,14}. Additionally tendon tissue has poor healing properties ². Depending on these, a technique providing necessary biomechanical support, permitting early active movements, prevents all above mentioned problems, preventing adhesions, increasing intrinsic healing ^{6,15-18}. Like other tendons, Achilles tendon is also exposed to cyclic loading that an ideal repair must stand along. However recently described techniques do not support enough. In the present study, for safe end to end anastomosis, a bridging implant was used so tension forces were transmitted to proximal, distal areas of the repair zone while minimizing these forces at the anastomosis area, preventing the detachment.

During biomechanical testing, at 17 mm of lengthening, detachment started to occur at Krackow group while in study group detachment started after 28 mm of tendon lengthening. In this technique sutures are placed vertical to the fibrils providing safe implant-tendon relation, better holding of the fibrils, preventing suture

slippage ^{6,13,19-22}. Additionally tendon is not compassed totally, permitting passage of the sutures at the safe areas, protecting the blood supply of the tendon. Actual suture repair techniques include passage of the sutures from all sections of the tendon, damaging blood supply, integrity of the tendon. In Krackow group after 30 N, in Modified Kessler group after 25 N, and in Bunnell group after 20 N tendon holding capacity of the sutures weakened and detachment started. In new technique, detachment started after lengthening of the implant.

Actual tendon repair methods mostly depend on the suture material ^{2,6,12} and especially when length of the suture used increases this dependency more unlike newly described technique in this study. Lesser amount of the suture usage decreases the lengthening due to suture and dependence on the suture so actual techniques need postoperative immobilization ^{13,19,23-26}. Implant used in the present study did not cause any mass effect or skin or joint problems due to flexible nature.

Highest load to failure, amount of lengthening were detected in newly described technique compared to other techniques described in the literature. Heterogeneous deformation area that is the amount of lengthening after ultimate load was determined to be approximately double of the precedent lengthening.

In Krackow technique there was a sudden decrease of the load value after ultimate load with separation of the tendon ends. Ultimate load values were lower in Modified Kessler and Bunnell techniques. In the newly described technique, maximum load and the degree of tendon lengthening was found to be highest proving that this technique continued to carry load after reaching ultimate load.

Krackow technique had higher ultimate load than other techniques tested however preserving this load carrying capacity is more important than all tendons ruptured in Krackow group at 2nd and 3rd day post-operatively unlike new technique. This helped to mobilize freely and safely for study group.

This study proves that implant usage in Achilles tendon ruptures is detected to be superior to other actual repair techniques. However we believe that reproduction of the implant with taking the modulus, tension values of the tendon into account, will increase success^{6,21,22}. This newly described technique is suitable for every kind of tendon transfer^{23,24}.

However fate of the implant is not totally understood. Production of the implant from absorbable materials, keeping the friction as low as possible with implanted sutures may be second stage of production. Our study is an intermediate stage for developing safer, stronger tendon repair techniques.

REFERENCES

1. Wren TAL, Yerby SA, Beaupre GS, Dennis RC: Mechanical properties of the human achilles tendon. *Clinical Biomechanics*, 16, 245-251, 2001.
2. Lin CT, An KN, Amadio PC: Biomechanical studies of running suture for flexor tendon repair in dogs. *J Hand Surg Am*, 13, 553-558, 1988.
3. Molloy A, Wood EV: Complications of the treatment of achilles tendon ruptures. *Foot and Ankle Clinics of North America*, 14 (4): 745-759, 2009.
4. Lin TW, Cardenas L, Soslowky LJ: Biomechanics of tendon injury and repair. *J Biomech*, 37, 865- 877 2004.
5. Greenwald DP, Hang ZH, May JW Jr.: Mechanical analysis of tendon suture techniques. *J Hand Surg Am*, 19 (4): 641-647, 1994.
6. Erol B, Kocaoğlu B, Esemeli T: Spiral shaped metallic implant in the treatment of achilles tendon ruptures: An experimental study on the achilles tendon of sheep. *J Foot Ankle Surg*, 46, 155-161, 2007.
7. Chan KB, Lui TH, Chan LK: Endoscopic-assisted repair of acute Achilles tendon rupture with Krackow suture: An anatomic study. *Foot Ankle Surg*, 15 (4): 183-186, 2009.
8. Palmes D, Spiegel HV, Schneider TO, Langer M, Stratmann U, Budny T, Probst A: Achilles tendon healing: long term biomechanical effects of postoperative mobilization and immobilization in a new mouse model. *J Orthop Res*, 20, 939-946, 2002.
9. Archambault J, Tsuzaki M, Herzog W, Banes AJ: Stretch and interleukin 1 beta induce matrix metalloproteinases in rabbit tendon cells in vitro. *J Orthop Res*, 20, 36-39, 2002.
10. Kuwata S, Mori R, Yatsumoto T, Uchio Y: Flexor tendon repair using two-strand side locking loop technique to tolerate aggressive active mobilization immediately after surgery. *J Clin Biomech*, 22 (10): 1083-1087, 2007.
11. Strom AC, Casillas MM: Achilles tendon rehabilitation. *Foot and Ankle Clinics of North America*, 14 (4): 773-782, 2009.
12. Mc Comis GP, Nawoczinski DA, DeHaven KE: Functional bracing for rupture of the achilles tendon. Clinical result and analysis of ground reaction forces and temporal data. *J Bone Joint Surg*, 79A, 1799-1808, 1997.
13. Huffard B, O'Loughlin PF, Wright T, Deland J, Kennedy JG: Achilles tendon repair: Achillon system vs. Krackow suture: An anatomic in vitro biomechanical study. *J Clin Biomech*, 23 (9): 1158-1164, 2008.
14. Davies MS, Solan M: Minimal incision techniques for acute achilles repair. *Foot and Ankle Clinics of North America*, 14 (4): 685-697, 2009.
15. Nister L: Surgical and nonsurgical treatment achilles tendon ruptures. A prospective randomised study. *J Bone Joint Surg*, 63A, 394-399, 1981.
16. Gullies H, Charners J: The management of fresh ruptures of the tendo achillis. *J Bone Joint Surg*, 52A, 337-343, 1970.
17. Jaakkola JI, Hutton WC, Beksin JK, Lee GP: Achilles tendon rupture repair: Biomechanical comparison of the triple bundle technique versus the Krackow locking loop technique. *Foot Ankle Int*, 21, 14-17, 2000.
18. Mann RA, Holmes GB Jr, Seale KS, Collins DN: Chronic rupture of the achilles tendon a new technique of repair. *J Bone Joint Surg*, 73A, 214-219, 1991.
19. Nyssoner T, Sarkovski H, Kaukonen JP, Luthie P, Hakovirta H: Simple end-to-end suture versus augmented repair in acute achilles tendon ruptures, a retrospective comparison in 98 patients. *J Acta Orthop Scand*, 74, 206-208, 2003.
20. Wagner WF, Carroll C, Strickland JW: A biomechanical comparison of techniques of flexor tendon repair. *J Hand Surg Am*, 19, 979-983, 1994.
21. Lieberman JR, Lozman J, Dougerty J: Repair of achilles tendon ruptures with dacron vascular graft. *J Clin Orthop*, 234, 204-208, 1988.
22. Khazen GE, Wilson AN, Ashfaq S, Parks BG, Schon LC: Fixation of calcaneal avulsion fractures using screws with and without suture anchors: A biomechanical investigation. *Foot Ankle Int*, 28 (11): 1183-1186, 2007.
23. Lin JL: Tendon transfers for achilles reconstruction. *Foot and Ankle Clinics of North America*, 14 (4): 729-744, 2009.
24. Chalmers R, Tare M, Niranjan N: Vascularised Achilles tendon graft reconstruction - By the tendon for the tendon. *J Plast Reconstr Aesthet Surg*, 63 (3): 273-276, 2010.
25. Kılıç E, Akoy Ö, Özaydın İ, Öztürk S, Kamiloğlu K, Yayla S, Sözmen M: Köpeklerde ön çapraz bağ ruptürlerinin intraartiküler fibula başı ve lateral kollateral ligament transpozisyonu ile sağaltımı. *Kafkas Univ Vet Fak Derg*, 14 (2): 243-248, 2008.
26. Kılıç E, Özaydın İ, Akoy Ö, Öztürk S: Buzağılarda karşılaşılan doğmasal bilateral lateral patellar tendon ve M. vastus lateralis transpozisyonu ile sağaltımı. *Kafkas Univ Vet Fak Derg*, 14 (2): 185-190, 2009.