



## Primary Pulmonary Adenoid Cystic Carcinoma Located at the end of the Terminal Bronchiolus: Case Report

### Terminal Bronşiyol Distaline Yerleşen Primer Pulmonar Adenoid Kistik Karsinoma: Olgu Sunumu

Adenoid Kistik Karsinom / Adenoid Cystic Carcinoma

Tülin Durgun Yetim<sup>1</sup>, Suna Cokmert<sup>2</sup>, Fadime Bahadır<sup>3</sup>, Ramazan Davran<sup>4</sup>, Ersin Şükrü Erdem<sup>5</sup>

<sup>1</sup>Department of Thoracic Surgery Mustafa Kemal University School of Medicine,

<sup>2</sup>Department of Medical Oncology, Antakya State Hospital, <sup>3</sup>Department of Pathology, Antakya State Hospital, <sup>4</sup>Department of Radiology, Mustafa Kemal University School of Medicine, <sup>5</sup>Department of Thoracic disease, Mustafa Kemal University School of Medicine, Hatay, Turkey

5. Türk Göğüs Cerrahi Kongresinde Poster olarak Sunulmuştur

#### Özet

Pulmonar adenoid kistik karsinoma genellikle trakea ve ana bronş gibi merkezi hava yollarında yerleşik, tükürük bezi tipinde, nadir bir malign solunum yolu tümörüdür. Periferik akciğerden kaynaklanan adenoid kistik karsinoma oldukça enderdir. Burada, 52 yaşında bir kadının sağ akciğer alt lobu terminal bronşiyol distalinde gelişmiş adenoid kistik karsinomayı rapor ettik.

#### Anahtar Kelimeler

Adenoid Kistik Karsinom; Akciğer

#### Abstract

Pulmonary adenoid cystic carcinoma is a rare salivary gland-type malignant neoplasm of respiratory tract that is usually located in the central airways such as trachea and main bronchus. Adenoid cystic carcinoma arising from the peripheral lung is quite rare. Here, we report adenoid cystic carcinoma that developed at the end of the terminal bronchiol of the right lung lower lobe of a 52-year-old woman.

#### Keywords

Adenoid Cystic Carcinoma; Lung

DOI: 10.4328/JCAM.551

Received: 20.12.2010 Accepted: 02.01.2011 Printed: 01.07.2012 J Clin Anal Med 2012;3(3): 361-3

Corresponding Author: Tülin Durgun Yetim, Department of Thoracic Surgery, Mustafa Kemal University School of Medicine, 31100 Antioch, Turkey.

T.: +90 3262291000 F.:+903262144977 E-Mail: tulinyetim@gmail.com

## Introduction

Adenoid cystic carcinoma (ACC), known as “cylindroma” in the past, is a distinct type of malignant epithelial tumors. ACC commonly arises in major and minor salivary glands, but also it may occur in breast, skin, esophagus, uterus and lung<sup>1</sup>. Primary lung ACC occurs within the primary lung cancer in 0.2%, and commonly arises from central extra-pulmonary airways such as trachea and main bronchus . Peripheral lung ACC is very rare and represents approximately 10% of primary lung ACC<sup>2</sup>. Here, we describe a rare case of primary lung ACC arising in the terminal-respiratuar bronchiol junction.

## Case Report

A 52-year-old woman was admitted to the hospital with complaints of chest pain that existing approximately one year duration. A chest X-ray showed a mass shadow 5-6 cm in diameter in the right lower lobe (Figure 1). On the chest computerized scan, a lung mass that measured 6 cm and adjacent to the chest wall was detected at the right lower lobe (Figure 2). Fiberoptic bronchoscopy revealed no tumor in the bronchial lumen of the right lung. At the time of thoracotomy a smooth sided, solid, grayish-white colored mass was found attached to the thorax wall from anterior in the middle lobe of right lung. Resection of the middle lobe was performed. Examination of the specimen revealed a tumor measuring 6X6 cm which appeared to arise from the area of peripheral in the middle lobe. The lesion presented as peripheral parenchymatous nodules unrelated to a bronchus; macroscopically, well circumscribed light tan mass (Figure 3), does not grossly infiltrate the underlying lung parenchyma .Microscopically, small cells with dark stained nuclei were arranged either in a cylindromatous (predominant pattern) or in tubular patterns, embedded in an abundant hyaline stroma. Histologic grades were established as grade I and the neoplasm itself was characteristic of adenoid cystic carcinoma Tumor was histologically benign. Histochemical studies showed strong positive of myxoid matrix with PAS and of the cells in

therapy, with a total dose of 50 Gy, was delivered in 25 fractions. The patient is alive and well, with no evidence of recurrent or metastatic disease 12 months after surgery.

## Discussion

Adenoid cystic carcinoma is a relatively rare salivary gland-type lung carcinoma [1]. Submucosal tracheobronchial glands are considered the pulmonary counterpart of the minor salivary glands of the head and neck and are present from the first to the fourth order bronchi [2]. Additionally they are found in 79% of the fifth order bronchi (as named lobulary bronchi), but in only 11% of the sixth order bronchi (as named terminal bronchi) [4]. Therefore, primary pulmonary ACC is commonly arise from central extra-pulmonary airways such as trachea and main bronchus [2,3]. Peripheral lung ACC is represents approximately 10% of primary lung ACC. Peripheral lung ACC arises from bronchi smaller than the segmental bronchus which are named as lobular and terminal bronchi [3,7]. Our presented case is rather different from those presented in previous reports. Because, in our case the tumour had been derived from the terminal-respiratory bronchiol junction. This location is far most peripheral than usually presented. Pulmonary adenoid ctycic carcinoma relatively low biologic activity manifests itself in long term survival but it tends to metastasize to distant sites and often recurs after a long interval [5]. ACC spreads commonly by direct extension, submucous or perineural invasion or hematogenous metastasis. Although metastases to brain, bone, liver, skin, kidney, abdomen and heart have been reported, pulmonary metastasis is the most common [6]. The prognosis was generally poor with overall survival of 10-20% at 2 years in the past [5]. However, with the improvement of surgical techniques, the 5 year survival rates of the resected cases have been reported to be 60-100%<sup>7</sup>. Surgery is the primary management of pulmonary ACC. Adjuvant radiation therapy is used when there is a high risk of local relapse, or when residual disease persists after surgery [8]. Also, in our case, postoperative radiotiotherapy was performed, due

to proximity to the chest wall of mass. For the patients with unresectable tumors, primary radiotherapy (RT) or RT after Nd-YAG laser ablation may provide satisfactory results. However, the role of chemotherapy in ACC patients remains controversial, and no effective chemotherapy regimen for pulmonary ACC has yet been established [5]. Therefore, new therapeutic approaches such as ACC-targeting drugs are needed. C-kit expression appears as a common feature in 80% to 100% of adenoid cystic carcinoma of the salivary glands arising from the head and neck. Tracheobronchial ACCs consistently showed CD117 expression, as do ACCs of the salivary gland. Therewithal, CD117 positivity has been proposed as a useful marker for distinguishing ACC from polymorphous low-grade adenocarcinoma. In our case, tu-

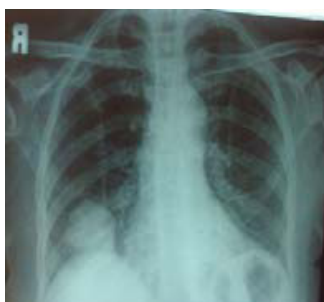

Figure 1. Chest X-ray imagine of the case shows a solitary mass shadow in the right lower lobe.

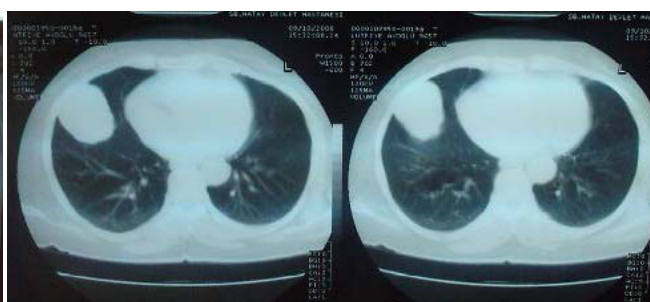


Figure 2. Chest CT scan of the case.

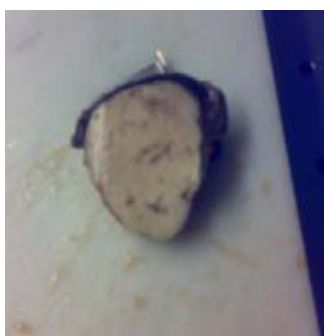

Figure 3. Macroscopically appearance of the mass.

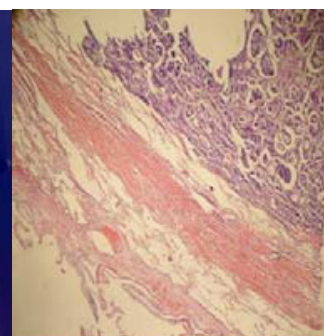


Figure 4. Immunohistochemical finding of the case; SMA positivity (SMAx400).

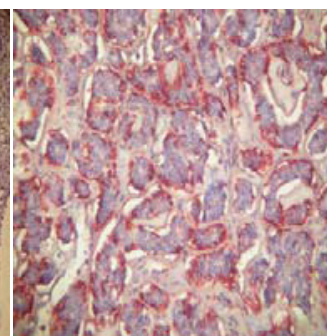


Figure 5. The tumor arose from the mucosa of the terminal bronchiolus and a respiratory bronchiolus (arrow) (HEx400).

mor was staining with CD117 but CD 117 expression was low..

#### References

1. Moran CA, Suster S, Koss MN. Primary adenoid cystic carcinoma of the lung: a clinicopathologic and immunohistochemical study of 16 cases. *Cancer*, 73:1390-1397, 1994.
2. Moran CA: Primary salivary gland-type tumors of the lung. *Semin Diagn Pathol* 12:106-122,1995.
3. Yokouchi H, Otsuka Y, Otoguro Y, et al. Primary peripheral adenoid cystic carcinoma of the lung and literature comparison of features. *Intern Med*, 46:1799-1803, 2007.
4. Azukari K, Yoshioka K, Seto S, et al. Adenoid cystic carcinoma arising in the intrapulmonary bronchus. *Int Med*, 35:407-409, 1996.
5. Suemitsu R, Okamoto T, Maruyama R, et al. A long-term survivor after aggressive treatment for tracheal adenoid cystic carcinoma: A case report. *Ann Thorac Cardiovasc Surg*, 13:335-337, 2007.
6. Chih-Ming Lina, Anna Fen-Yau Lib, Li-Hwa Wuc, et al. Adenoid cystic carcinoma of the trachea and bronchus – a clinicopathologic study with DNA flow cytometric analysis and oncogene expression. *European Journal of Cardio-thoracic Surgery* 22:621-625, 2002.
7. BoKyong Kim. Palliative Radiotherapy in a Patient with Pulmonary Adenoid Cystic Carcinoma. *Res. Treat.* 39(4):185-188, 2007
8. Müller A, Stockamp B, Schnabel T. Successful primary radiation therapy of adenoid cystic carcinoma of the Lung. *Oncology*, 58:15-17.