

## OBSERVATION

# Exonic Deletions of *FXN* and Early-Onset Friedreich Ataxia

Mathieu Anheim, MD, PhD; Louise-Laure Mariani, MD; Patrick Calvas, MD, PhD; Emmanuel Cheuret, MD; Fabien Zagnoli, MD; Sylvie Odent, MD; Claire Seguela, BS; Cecilia Marelli, MD; Marlène Fritsch, BS; Jean-Pierre Delaunoy, PhD; Alexis Brice, MD, PhD; Alexandra Dürr, MD, PhD; Michel Koenig, MD, PhD

**Background:** Friedreich ataxia (FA) is the most frequent type of autosomal recessive cerebellar ataxia, occurring at a mean age of 16 years. Nearly 98% of patients with FA present with homozygous GAA expansions in the *FXN* gene. The remaining patients are compound heterozygous for an expansion and a point mutation. Patients who are compound heterozygous for an exonic deletion and an expansion are exquisitely rare.

**Objectives:** To describe 6 patients affected with FA due to an exonic deletion mutation (FAexdel) and to compare these 6 patients with FAexdel with 46 patients consecutively diagnosed with typical FA due to homozygous GAA expansion and whose small expansions were within the same range as that of the expansions of the patients with FAexdel.

**Design:** Description of a series.

**Setting:** Academic research.

**Patients:** Six patients with FAexdel and 46 patients with typical FA.

**Intervention:** *FXN* gene analysis, including assessments of GAA expansion and exon sequencing and determination of exonic copy numbers using multiplex ligation-dependent probe amplification.

**Results:** We identified 6 patients with FA who presented with the combination of 1 GAA expansion and 1 *FXN* exonic deletion. The mean (SD) age at onset of the disease was earlier for patients with FAexdel (7 [4] years [range, 3-12 years]) than for patients with typical FA (15 [5] years [range, 6-30 years]) ( $P = .001$ ), and the median time to confinement to wheelchair was shorter for patients with FAexdel (20 years) than for patients with typi-

cal FA (28 years) ( $P = .002$ ). There was no difference between the mean (SD) size of the expansion for the patients with FAexdel (780 [256] GAA triplet repeat sequences [range, 340-1070 GAA triplet repeat sequences]) and the mean (SD) size of the short expansion for the patients with typical FA (634 [163] GAA triplet repeat sequences [range, 367-1000 GAA triplet repeat sequences]) ( $P = .10$ ). The mean disease duration before becoming wheelchair bound was shorter for patients with FAexdel (9 years) than for patients with typical FA (13 years), and the incidence of cardiomyopathy was higher for patients with FAexdel (84%) than for patients with typical FA (68%). However, these differences were not significant, probably owing to the small size of the FAexdel group. The other extraneurological signs, such as scoliosis or diabetes mellitus, were particularly frequently observed in the FAexdel group. One patient presented at 9 years of age with severe angina and marked cardiomyopathy that confined her to a wheelchair. Three patients had disabling autonomic disturbances. It appears that exonic deletion significantly contributes to the clinical picture of patients with FA.

**Conclusions:** Friedreich ataxia due to an exonic deletion mutation corresponds to an early onset and severe variant of FA. *FXN* should be investigated for exonic deletion in patients with early-onset FA in which only 1 GAA expansion without a point mutation is found. Patients with FAexdel have to be carefully observed using cardiological, orthopaedic, endocrinological, gastroenterological, and ophthalmological data. Friedreich ataxia due to an exonic deletion mutation should be suspected in young patients presenting with severe scoliosis.

*Arch Neurol.* 2012;69(7):912-916. Published online March 12, 2012. doi:10.1001/archneurol.2011.834

Author Affiliations are listed at the end of this article.

**F**RIEDREICH ATAXIA (FA) IS THE most frequent type of autosomal recessive cerebellar ataxia. First signs usually occur at a mean age of 16 years old (mostly between 10 and 25 years).<sup>1</sup> Friedreich ataxia is clinically character-

ized by the combination of both cerebellar and proprioceptive ataxia, sensory neuropathy with loss of deep tendon reflexes, extensor plantar responses, scoliosis, hypertrophic cardiomyopathy, and, less frequently, diabetes mellitus.<sup>1-3</sup> Nearly 98% of patients with FA present with ho-

**Table 1. Main Clinical, Molecular, Morphological, and Electrophysiological Features of 6 Patients With Friedreich Ataxia Due to an Exonic Deletion Mutation**

Feature	Patient 1	Patient 2	Patient 3	Patient 4	Patient 5	Patient 6
Age at onset of ataxia, y	3	3	7	5	12	12
First sign	Unsteadiness	Scoliosis	Unsteadiness	Unsteadiness	Unsteadiness	Unsteadiness
Spinocerebellar degeneration functional score <sup>a</sup>	3/7 at 4 y, 6/7 at 12 and 14 y	6/7 at 9 and 30 y	6/7 at 24 y, 7/7 at 64 y, deceased at 69 y	2/7 at 9 y (ICARS score, 19/100)	4/7 at 19 and 22 y, 5/7 at 27 y, 6/7 at 29 y	6/7 at 20 and 46 y
SARA score	28 at 14 y	36 at 30 y	Unknown	12 at 9 y	27 at 29 y	34 at 46 y
Disease duration before becoming wheelchair bound, y	9	6	17	NA	17	8
<i>FXN</i> molecular analysis	1070 GAA triplet repeat sequences (exons 4 and 5 deleted)	800 GAA triplet repeat sequences (exons 4 and 5 deleted)	970 GAA triplet repeat sequences (exons 4 and 5 deleted)	670 GAA triplet repeat sequences (exons 2 and 3 deleted)	340 GAA triplet repeat sequences (exons 4 and 5 deleted)	830 GAA triplet repeat sequences (exon 4 deleted)
Cerebellar ataxia?	Yes	Yes	Yes	Yes	Yes	Yes
Extensor plantar response?	Yes	Yes	Yes	No	No	Yes
Areflexia and/or vibration sense loss?	Yes	Yes	Yes	Yes	Yes	Yes
Motor deficit? <sup>b</sup>	Severe hypotonia	Yes (LL, amyotrophy)	Yes (UL and LL, amyotrophy)	No	No	Yes (LL, amyotrophy)
Dysarthria?	Yes	Yes	Yes	No	Yes	Yes
Diabetes (age at diagnosis)?	Yes (11 y)	No	Yes (48 y)	No	No	Yes (31 y)
Cardiomyopathy (age at diagnosis)?	Yes (4 y)	Yes (at 9 y) and severe angor	Yes (48 y)	Yes (9 y)	No	Yes
Pes cavus (age at diagnosis)?	Yes (4 y)	Yes (and equinovarus)	Yes	No	Yes	NA
Scoliosis?	Yes, arthrodesis at 14 y	Yes, operated on at 13 y	Yes	NA	Yes	No
Loss of visual acuity?	Myopia, optic atrophy	No	No	No	No	NA
Hearing loss?	No	No	Yes (bilateral 10- to 20-dB sensorineural hearing loss)	No	No	Yes
Movement disorder?	Yes (cerebellar tremor)	Yes (cerebellar tremor)	No	Yes (head tremor)	No	No
Autonomic disturbance?	Repeated ileus at 11 y	No	Ileus	No	No	Ileus at 49 y
Fundus examination findings (age at diagnosis)	Optic neuropathy (24 y)	Asymptomatic optic neuropathy suspected	NA	Normal	Normal	NA
EMG findings (age at diagnosis)	Sensory neuronopathy (4 y)	Sensory neuronopathy (10 y)	NA	Sensory neuronopathy	Sensory neuronopathy	Sensory neuronopathy
MRI findings of the brain	Normal	Normal	NA	Normal	Normal	NA
MRI findings of the medulla oblongata	NA	Spinal cord atrophy	NA	NA	Syringomyelic cavity T7-T9	NA
Treatment with idebenone?	Yes (10 mg/kg/d)	NA	NA	Yes (mg/kg/d)	No	No

Abbreviations: EMG, electroneuromyography; ICARS, International Cooperative Ataxia Rating Scale; LL, lower limbs; MRI, magnetic resonance imaging; NA, not available; SARA, Scale for the Assessment and Rating of Ataxia; UL, upper limbs.

<sup>a</sup>Score from 0 (no cerebellar sign) to 7 (bedridden), with 6/7 indicating that the patient is wheelchair bound.

<sup>b</sup>Motor deficit was defined by a score of 3/5 or less in muscle strength from the Oxford scale.

mozygous GAA expansions in the *FXN* gene encoding the frataxin protein.<sup>4</sup> About 2% of these patients have both 1 GAA expansion and 1 point mutation in *FXN*. Patients compound heterozygous for an exonic deletion and an expansion are exquisitely rare.<sup>5</sup> Although the clinical phenotype of FA due to GAA expansion<sup>1</sup> or point mutations<sup>6</sup> has been well described, the clinical spectrum of patients with FA due to an exonic deletion mutation (FA<sub>exdel</sub>) remains unknown. We report 6 patients with FA<sub>exdel</sub> who presented with the combination of 1 GAA expansion and 1 *FXN* exonic deletion responsible for

early-onset FA with precocious neurological disability and cardiomyopathy.

## METHODS

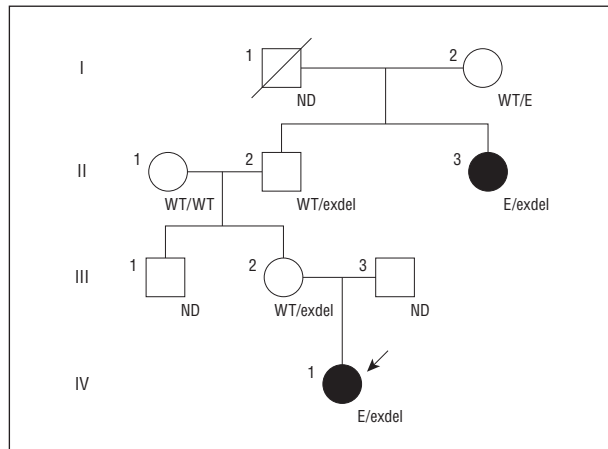
Approximately 600 patients, recruited from French centers during the period from 1988 to 2010, received a diagnosis of FA, which was determined by use of a genetic test. The DNA samples of 13 ataxic patients whose clinical phenotypes were compatible with FA but who were heterozygous for a GAA expansion<sup>4</sup> and had no point mutation<sup>6</sup> were assessed for large *FXN*

deletion or duplication using a multiplex ligation-dependent probe amplification kit (SALSA MLPA kit P316-A1 Recessive Ataxias; MRC-Holland) according to the manufacturer's recommendations. We retrospectively reviewed the clinical, molecular, electrophysiological, and morphological data of the patients with FAexdel and of 46 patients consecutively diagnosed with typical FA due to homozygous GAA expansion and whose small expansions were within the same range as that of the expansions of the patients with FAexdel.

Data, reported as mean (SD) values along with minimum and maximum values (ie, range), were analyzed by use of the Mann-Whitney test. When percentages were compared, the Fisher exact test was used. For the median time to confinement to a wheelchair and for the median disease duration before confinement to a wheelchair, the Kaplan-Meier method was performed.

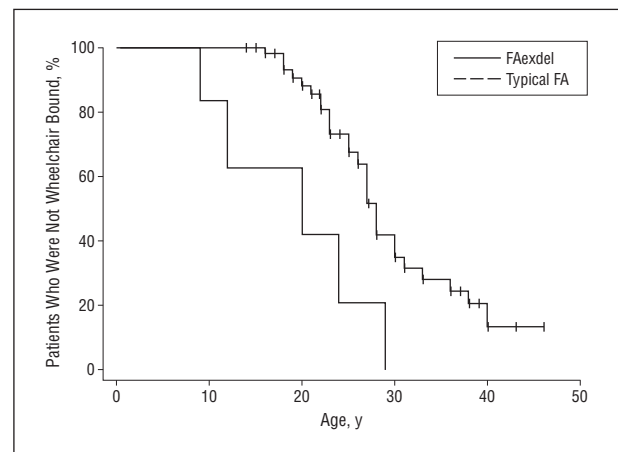
## RESULTS

Seven patients had a normal *FXN* exonic copy number dosage, excluding the diagnosis of FA. These patients, whose molecular diagnosis remains unknown, presented with late-onset ataxia (ranging from 30 to 58 years of age) and had large expansions (from 700 to 1100 GAA



**Figure 1.** Pedigree showing 4 generations of a family that included patient 2 (IV1) and patient 3 (II3) with pseudodominant inheritance of Friedreich ataxia. The squares represent male individuals; circles, female individuals; filled circles, affected female individuals; diagonal line, deceased individual; arrow, proband. Genotypes are indicated as follows: E, GAA expansion; exdel, exonic deletion; WT, wild type. ND indicates analysis was not done.

triplet repeat sequences). Some had atypical presentation because they had cerebellar atrophy and/or a lack of sensory neuropathy. They were assumed to be heterozygous carriers of the expansion by chance, given the high frequency of the GAA expansion in the European population ( $\approx 1$  in 90 individuals).<sup>7,8</sup> The remaining 6 patients were found to be affected with FA due to heterozygous *FXN* exonic deletion. Three of them (patients 1, 2, and 3) were previously reported in a series of patients with an FA-like disease who presented with only 1 GAA repeat expansion and no point mutation.<sup>6</sup> The main findings are summarized in **Table 1** and **Figure 1**, and the comparison between patients with FAexdel and patients with typical FA are presented in **Table 2** and **Figure 2**. Cardiomyopathy was diagnosed at 4 years of age in patient 1 but was particularly stable until the patients turned 24 years of age. Patient 2 presented with severe angina and cardiomyopathy with a left ventricular ejection fraction of 52% at 9 years of age that confined her to a wheelchair. Interestingly, patient 3 was the grandaunt of patient 2 (Figure 1); therefore, autosomal dominant cerebellar ataxia was first suspected in this family. The high frequency of GAA expansion in heterozygous carriers led to a pseudodominant inheritance of FA in this family because the expansion of the 2 patients was transmitted by 2 unrelated individuals (Figure 1). The 6



**Figure 2.** Data on patients with Friedreich ataxia due to an exonic deletion mutation (FAexdel) and patients with typical FA who were not wheelchair bound (determined by use of the Kaplan-Meier method).

**Table 2. Comparison Between Patients With FAexdel and Patients With Typical FA**

Parameter	Typical FA (n = 46)	FA exdel (n = 6)	P Value
Age at onset, mean (SD) [range], y	15.4 (5) [6-30]	7 (4) [3-12]	.001
Time to confinement to wheelchair, median, y	28	20	.002
DD before confinement to wheelchair, median, y	13	9	.42
Age at last follow-up, mean (SD) [range], y	31 (10) [14-57]	33 (22) [9-69]	.92
SARA score-to-DD ratio at last follow-up, <sup>a</sup> mean (SD) [range]	1.5 (0.6) [0.5-3]	1.9 (0.8) [1-3]	.33
Cardiomyopathy, % of patients	68	84	.66
GAA triplet repeat sequences, mean (SD) [range], No.	634 (163) [367-1000], <sup>b</sup> 878 (220) [367-1667] <sup>c</sup>	780 (256) [340-1070]	.10, <sup>b</sup> .34 <sup>c</sup>

Abbreviations: DD, disease duration; FA, Friedreich ataxia; FAexdel, FA due to an exonic deletion mutation; SARA, Scale for the Assessment and Rating of Ataxia.

<sup>a</sup>This ratio calculation gives a good indication of the severity of the disease progression.

<sup>b</sup>Short expansion vs 780 (256) [340-1070].

<sup>c</sup>Large expansion vs 780 (256) [340-1070].

patients with FAexdel in our series are all of French ancestry: 2 patients are from southern France, and the other 4 patients, with a deletion of exons 4 and 5, were originally from Brittany, which suggests that the multiple occurrence of this deletion is the consequence of a founder effect.

## COMMENT

To our knowledge, we report the first series of 6 patients affected with FAexdel, which is characterized by a particularly young age at onset in comparison with the age at onset of typical FA. This comparison holds true because there is no difference between the 2 groups regarding the size of GAA expansion (Table 2). The disease is more severe in patients with FAexdel, mainly because of the early onset of the disease and the early age at which the patients become confined to a wheelchair but also because there appears to be a trend toward a faster progression of disability and a higher incidence of cardiomyopathy in FAexdel. So far, only 1 patient with FAexdel (with a deletion surrounding exon 5a) had been reported with the disease at 9 years, sensory axonal neuropathy, foot deformity, loss of independent walking at 15 years, and cardiomyopathy at 21 years.<sup>5</sup> Early-onset FA is a rare variant of FA, and patients whose age at onset is younger than 7 years represent approximately 12% of all patients.<sup>1</sup> We found that FAexdel is exquisitely rare and accounts for approximately 1% of cases of FA diagnosed in France.

It appears that extensor plantar reflexes are an optional finding in FAexdel. Moreover, the incidence of extraneurological signs is particularly high in such patients. All but 1 of our 6 patients were affected with hypertrophic cardiomyopathy, albeit this is not significantly different from the 60% of patients with typical FA who have cardiomyopathy.<sup>1,7,9,10</sup> However, the cardiomyopathy may be particularly disabling in FAexdel, as it lead to severe angina and early loss of ambulation in patient 2. The incidence of diabetes mellitus was higher in our patients with FAexdel (half of our patients were affected) than in previously reported series of patients with FA (about 30%).<sup>1,7</sup> The incidence of scoliosis in our patients with FAexdel seems to be the same as in patients with typical FA, but the severity of scoliosis could be higher in FAexdel because 2 patients needed spine surgery only a few years after onset of the disease. Moreover, scoliosis may reveal FAexdel (patient 2). Interestingly, 3 patients had autonomic disturbances, especially repeated ileus, which is an unusual finding in FA.<sup>11</sup> The severe phenotype associated with exonic deletion mutation is in agreement with the predicted absence of functional frataxin made from the deleted allele.

It appears that exonic deletion significantly contributes to the clinical picture of patients with FA, especially to the young age at onset of the disease, whereas the FA phenotype and the age at onset are usually conditioned by the size of the smaller GAA expansion (in case of homozygous expansions).<sup>1,6,7,12</sup> For instance, patients with a short size of the smaller expansion may present with an FA variant such as late-onset FA<sup>1,13,14</sup> or

very-late-onset FA,<sup>1,15,16</sup> defined by an age at onset of the disease of older than 25 and 40 years, respectively. Within our series, it seems that the size of the GAA expansion also contributes to the phenotype. Indeed, the 3 patients with the larger expansions (patients 1, 3, and 6, presenting with 1070, 970, and 830 GAA triplet repeat sequences, respectively) are those affected with both diabetes mellitus and autonomic disturbances, and patient 2 (800 GAA triplet repeat sequences) had had the first signs at 2 years of age, a severe cardiomyopathy at 4 years with angina at 9 years, and the shorter disease duration before becoming wheelchair bound. Moreover, patient 5, with the shortest expansion (340 GAA triplet repeat sequences) and deletion of exons 4 and 5, does not show symptoms of an extensor plantar response, cardiomyopathy, or diabetes mellitus.

FXN should be investigated for exonic deletion in patients with early-onset FA in which only 1 GAA expansion without a point mutation is found. In clinical practice, patients with FAexdel have to be carefully observed using cardiological, orthopaedic, endocrinological, gastroenterological, and ophthalmological data. Moreover, FAexdel should be suspected in young patients presenting with severe scoliosis.

**Accepted for Publication:** August 10, 2011.

**Published Online:** March 12, 2012. doi:10.1001/archneur.2011.834

**Author Affiliations:** Université Pierre et Marie Curie, Centre de Recherche de l'Institut du Cerveau et de la Moelle épinière, Institut National de la Santé et de la Recherche Médicale (INSERM), and Centre National de la Recherche Scientifique (CNRS) (Drs Anheim, Marelli, Brice, and Dürr), Assistance publique-Hôpitaux de Paris, Pitié-Salpêtrière Hospital, Department of Genetics and Cytogenetics (Drs Anheim, Mariani, Marelli, Brice, and Dürr), and Centre de Référence des Maladies Neurogénétiques de l'Enfant et de l'Adulte (Drs Anheim, Marelli, Brice, and Dürr), Paris, Service de Génétique Médicale, Université de Toulouse, Hôpital Purpan (Dr Calvas), and Service de neuropédiatrie, Hôpital des enfants (Dr Cheuret), Toulouse, Neurologie Hôpital d'Instruction des Armées Clermont-Tonnerre, Brest (Dr Zagnoli), Service de Génétique clinique CHU de Rennes, Université Rennes 1, CNRS (Dr Odent), Laboratoire de Diagnostic Génétique, Nouvel Hôpital Civil, Strasbourg (Mesdames Seguela and Fritsch and Drs Delaunoy and Koenig), and Institut de Génétique et de Biologie Moléculaire et Cellulaire, CNRS, Université de Strasbourg, INSERM, Illkirch (Dr Koenig), France.

**Correspondence:** Mathieu Anheim, MD, Assistance publique-Hôpitaux de Paris, Pitié-Salpêtrière Hospital, Department of Genetics and Cytogenetics, Bâtiment Pinel, Groupe Hospitalier de la Pitié-Salpêtrière, 47-83, bd de l'Hôpital, 75651 Paris, France (mathieu.anheim@psl.aphp.fr).

**Author Contributions:** Dr Anheim had full access to all the data in the study and takes responsibility for the integrity of the data and the accuracy of the data analysis. *Study concept and design:* Anheim, Mariani, and Koenig. *Acquisition of data:* Anheim, Mariani, Calvas, Cheuret, Zagnoli, Odent, Seguela, Marelli, Fritsch, Delaunoy, Brice,

and Dürr. *Analysis and interpretation of data*: Anheim, Mariani, Seguela, Delaunoy, and Koenig. *Drafting of the manuscript*: Anheim, Mariani, Calvas, Cheuret, Zagnoli, Odent, Seguela, Fritsch, Delaunoy, and Koenig. *Critical revision of the manuscript for important intellectual content*: Anheim, Mariani, Marelli, Brice, Dürr, and Koenig. *Statistical analysis*: Anheim and Mariani. *Obtained funding*: Koenig. *Administrative, technical, and material support*: Anheim, Seguela, and Fritsch. *Study supervision*: Anheim and Koenig.

**Financial Disclosure**: None reported.

**Previous Presentation**: Presented in part at the Journées de Neurologie de Langue Française; April 28, 2011; Paris, France (abstract and poster).

## REFERENCES

1. Dürr A, Cossée M, Agid Y, et al. Clinical and genetic abnormalities in patients with Friedreich's ataxia. *N Engl J Med*. 1996;335(16):1169-1175.
2. Pandolfo M. Friedreich ataxia. *Arch Neurol*. 2008;65(10):1296-1303.
3. Schulz JB, Boesch S, Bürk K, et al. Diagnosis and treatment of Friedreich ataxia: a European perspective. *Nat Rev Neurol*. 2009;5(4):222-234.
4. Campuzano V, Montermini L, Moltò MD, et al. Friedreich's ataxia: autosomal recessive disease caused by an intronic GAA triplet repeat expansion. *Science*. 1996; 271(5254):1423-1427.
5. Zühlke CH, Dalski A, Habeck M, et al. Extension of the mutation spectrum in Friedreich's ataxia: detection of an exon deletion and novel missense mutations. *Eur J Hum Genet*. 2004;12(11):979-982.
6. Cossée M, Dürr A, Schmitt M, et al. Friedreich's ataxia: point mutations and clinical presentation of compound heterozygotes. *Ann Neurol*. 1999;45(2):200-206.
7. Anheim M, Fleury M, Monga B, et al. Epidemiological, clinical, paraclinical and molecular study of a cohort of 102 patients affected with autosomal recessive progressive cerebellar ataxia from Alsace, Eastern France: implications for clinical management. *Neurogenetics*. 2010;11(1):1-12.
8. Cossée M, Schmitt M, Campuzano V, et al. Evolution of the Friedreich's ataxia trinucleotide repeat expansion: founder effect and premutations. *Proc Natl Acad Sci U S A*. 1997;94(14):7452-7457.
9. Ribai P, Pousset F, Tanguy ML, et al. Neurological, cardiological, and oculomotor progression in 104 patients with Friedreich ataxia during long-term follow-up. *Arch Neurol*. 2007;64(4):558-564.
10. Casazza F, Morpurgo M. The varying evolution of Friedreich's ataxia cardiomyopathy. *Am J Cardiol*. 1996;77(10):895-898.
11. Ingall TJ, McLeod JG. Autonomic function in Friedreich's ataxia. *J Neurol Neurosurg Psychiatry*. 1991;54(2):162-164.
12. Filla A, De Michele G, Cavalcanti F, et al. The relationship between trinucleotide (GAA) repeat length and clinical features in Friedreich ataxia. *Am J Hum Genet*. 1996;59(3):554-560.
13. Bhidayasiri R, Perlman SL, Pulst SM, Geschwind DH. Late-onset Friedreich ataxia: phenotypic analysis, magnetic resonance imaging findings, and review of the literature. *Arch Neurol*. 2005;62(12):1865-1869.
14. Schöls L, Amoiridis G, Przuntek H, Frank G, Epplen JT, Epplen C. Friedreich's ataxia. Revision of the phenotype according to molecular genetics. *Brain*. 1997; 120(pt 12):2131-2140.
15. Berciano J, Infante J, García A, Polo JM, Volpini V, Combarros O. Very late-onset Friedreich's ataxia with minimal GAA1 expansion mimicking multiple system atrophy of cerebellar type. *Mov Disord*. 2005;20(12):1643-1645.
16. Gellera C, Pareyson D, Castellotti B, et al. Very late onset Friedreich's ataxia without cardiomyopathy is associated with limited GAA expansion in the X25 gene. *Neurology*. 1997;49(4):1153-1155.