

Case Report/Case Series

Dermatologic Findings in 16 Patients With Cockayne Syndrome and Cerebro-Oculo-Facial-Skeletal Syndrome


Eric Frouin, MD; Vincent Laugel, MD, PhD; Myriam Durand, MSc; H el ene Dollfus, MD, PhD; Dan Lipsker, MD, PhD

IMPORTANCE Cockayne syndrome (CS) and cerebro-oculo-facial-skeletal (COFS) syndrome are autosomal recessive diseases that belong to the family of nucleotide excision repair disorders. Our aim was to describe the cutaneous phenotype of patients with these rare diseases.

OBSERVATIONS A systematic dermatologic examination of 16 patients included in a European study of CS was performed. The patients were aged 1 to 28 years. Six patients (38%) had mutations in the Cockayne syndrome A (CSA) gene, and the remaining had Cockayne syndrome B (CSB) gene mutations. Fourteen patients were classified clinically as having CS and 2 as having COFS syndrome. Photosensitivity was present in 75% of the patients and was characterized by sunburn after brief sun exposure. Six patients developed symptoms after short sun exposure through a windshield. Six patients had pigmented macules on sun-exposed skin, but none developed a skin neoplasm. Twelve patients (75%) displayed cyanotic acral edema of the extremities. Eight patients had nail dystrophies and 7 had hair anomalies.

CONCLUSIONS AND RELEVANCE The dermatologic findings of 16 cases of CS and COFS syndrome highlight the high prevalence of photosensitivity and hair and nail disorders. Cyanotic acral edema was present in 75% of our patients, a finding not previously reported in CS.

JAMA Dermatol. 2013;149(12):1414-1418. doi:10.1001/jamadermatol.2013.6683
Published online October 23, 2013.

 Supplemental content at jamadermatology.com

Author Affiliations: Author affiliations are listed at the end of this article.

Corresponding Author: Eric Frouin, MD, Service d'Anatomie et Cytologie Pathologiques, Universit e de Montpellier, 80 Avenue Augustin Fliche, 34295 Montpellier CEDEX, France (e-frouin@chu-montpellier.fr).

Cockayne syndrome (CS) is a rare autosomal recessive disease described by Cockayne¹ in 1936 that belongs to the family of nucleotide excision repair disorders together with xeroderma pigmentosum (XP) (*xeroderma pigmentosum, complementation group A* [XPA; OMIM 278700], *xeroderma pigmentosum, complementation group B* [XPB; OMIM 610651], *xeroderma pigmentosum, complementation group C* [XPC; OMIM 278720], *xeroderma pigmentosum, complementation group D* [XPD; OMIM 278730], *xeroderma pigmentosum, complementation group E* [XPE; OMIM 278740], *xeroderma pigmentosum, complementation group F* [XPF; OMIM 278760], *xeroderma pigmentosum, complementation group G* [XPG; OMIM 278780], and *xeroderma pigmentosum, variant type* [XPV; OMIM 278750]) and trichothiodystrophy (*trichothiodystrophy photosensitive* [TTDP; OMIM 601675]). The incidence of CS is estimated at 1 per 360 000 births in Western Europe. The disease is defined by progressive postnatal growth failure, microcephaly, mental retardation, retinal degeneration, sensorineural deafness, and photosensitivity.² Patients share a characteristic facial appearance, with enophthalmia. A defective recovery of RNA synthesis in fibroblasts after UV light exposure is required to confirm the diagnosis.³ All CS cases reported so far were due to mutations of the Cockayne syn-

drome A (CSA; OMIM 216400) gene located on chromosome 5 or mutations of the Cockayne syndrome B (CSB; OMIM 133540) gene on chromosome 10q and were identified in 1992⁴ and 1995,⁵ respectively.

The cerebro-oculo-facial-skeletal (COFS) syndrome (*cerebro-oculo-facial-skeletal 1* [COFS1; OMIM 214150]) is an autosomal recessive disorder that was first reported⁶ within the Manitoba aboriginal population in 1971. Microcephaly, cataracts, microphthalmia, facial dysmorphism, and arthrogryposis are the clinical hallmarks of COFS syndrome. Since publication of the first cases, clinical reports have underlined clinical similarities between COFS syndrome and CS, and mutations in the CSB gene were recently reported in this syndrome^{7,8}; COFS syndrome and CS are now considered to be related allelic disorders.⁸

Cutaneous manifestations constitute one of the major symptoms leading to clinical suspicion of nucleotide excision repair disorders. In CS, parents usually report photosensitivity during early childhood but, unlike patients with xeroderma pigmentosum, those with CS do not develop sun-induced skin cancers. Therefore, in their comprehensive review of 140 patients with CS, Nance and Berry² highlighted photosensitivity as a cardinal symptom and noticed dry and thin

skin, dry hair, and anhidrosis as other dermatologic findings. In COFS syndrome, photosensitivity is an inconstant feature that was rarely reported.⁸

To our knowledge, this is the first prospective study focusing on dermatologic symptoms in those 2 rare disorders. A systematic dermatologic examination of 16 patients with genetically and biochemically ascertained CS and COFS syndrome was performed to update dermatologic knowledge of these rare diseases and to inform their differential diagnoses.

Report of Cases

Patient Population

Between September 1, 2006, and May 31, 2009, 16 patients (10 males and 6 females) were examined by 2 dermatologists (E.F., D.L.). Patients came from different European countries and participated in a prospective study on CS. The patients were aged 1 to 28 years (mean, 8.8 years). Four patients were brothers, but there were no twins among them. All patients had been characterized genetically before inclusion: 6 had mutations in the *CSA* gene, and *CSB* mutations were found in 10. All but 2 patients had a diagnosis of CS and were classified as CS1 (classical or moderate), CS2 (severe or early onset), or CS3 (mild or late onset) according to criteria defined by Nance and Berry²; 2 patients had a diagnosis of COFS syndrome. Demographic, clinical, and genetic data are reported in the Supplement (eTable). All but 2 patients (patients 5 and 7) were previously reported on in a large molecular study.⁹

The study was approved by the Comité de Protection des Personnes, the French equivalent of an ethics committee. Informed written consent was provided by the patients' parents or legal guardians.

Dermatologic Examination

Two dermatologists (E.F., D.L.) performed a complete skin examination. A predefined questionnaire and checklist were completed for each patient. The following items were reported for each patient: age at onset of the dermatologic symptoms; history of photosensitivity; existence of pigmented macules or nevi, as well as hair and nail dystrophies; and signs of cutaneous aging. Photosensitivity was defined by an erythematous eruption following minor solar exposure. Sunburns were classified as mild (slight erythema), moderate (marked erythema), or severe (erythema with pain for several days and/or bullae). Occurrence of sunburn while behind a windshield reflects a significant photosensitivity and was also recorded. Sunburn scars and solar lentigines were recorded. The parents and caregivers of the patients were interviewed on their provision of solar protection, with type of photoprotection (eg, clothes and sunscreen) specified.

Pigmented macules and nevi were counted and classified as small (<3 mm) or large (≥3 mm) lesions, and distribution according to sun-exposed areas (face, neck, neckline, and exposed parts of the limbs) and nonexposed areas was recorded.

Alopecia, dermo-epidermal atrophy ("cigarette paper" skin), thin transparent skin, stellar scars, telangiectasis, Bate-man purpura, and other signs suggestive of cutaneous aging

were recorded. Hair color; hair dystrophies, such as thin hair, dry hair, and brittle hair; and nail disorders were assessed. Any other cutaneous finding was also noted, and the face (profile and front view) and skin lesions were photographed.

Photobiologic Explorations

When possible, a photobiologic exploration was performed. First, phototype was determined following the Fitzpatrick criteria.¹⁰ Minimal erythema dose was determined after irradiation (Dermolum UMW; Fa Müller). The protocol consisted of irradiation from 200 to 1000 mJ/cm² with broad-spectrum light on the left buttock and from 2 to 10 J/cm² with UV-A on the right buttock.

Results

Clinical Findings

There were 10 male and 6 female patients in the study (mean age, 8.8 years). Demographic and genetic data, as well as dermatologic findings, are summarized in the Supplement (eTable).

Photosensitivity

For 12 patients, parents reported photosensitivity, which were mostly acute symptoms. Sunburns were classified as mild in 2, moderate in 7, and severe with bullae in 2 patients. The symptoms appeared before a mean age of 8.4 months (median, 1 month). Six patients developed a photosensitive eruption after short exposure through a windshield. Four patients did not have a history of photosensitivity; their parents had used intensive photoprotection with clothes and sunscreen since their birth.

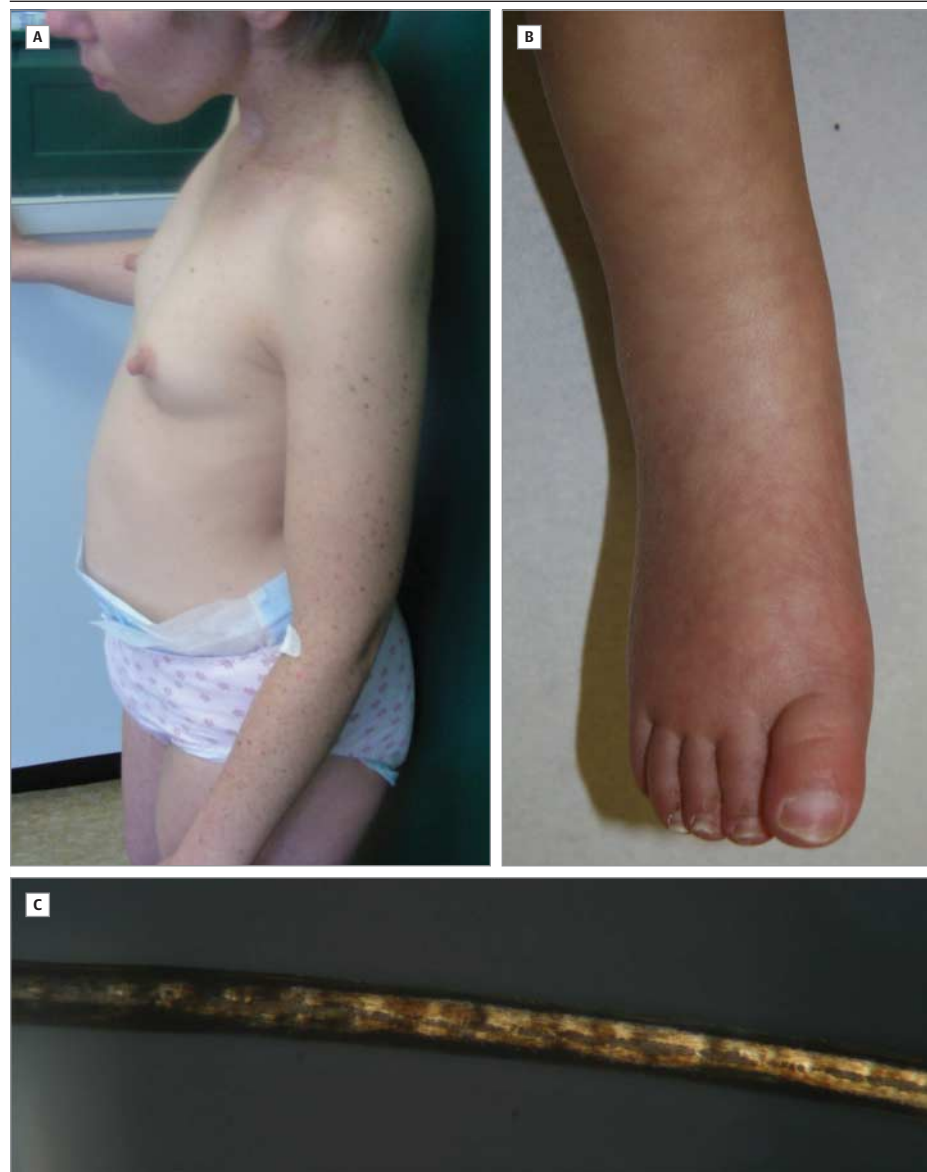Seven patients developed skin lesions on sun-exposed skin: more than 5 pigmented macules in 7 patients and stellate scars in 1 patient. We noticed pigmented macules and stellate scars in 1 patient. These lesions were more prevalent in older patients (Figure, A). Three patients had more than 20 pigmented macules, and 3 patients had more than 5 pigmented macules on non-sun-exposed skin. The number of pigmented lesions is summarized in Table 1 and the Supplement (eTable).

At the time of the present study, none of the patients had developed a skin neoplasm. Parents used photoprotection in 16 patients: sunscreen alone was used in 3 children and clothing with sunscreen in the remaining 13.

Other Dermatologic Findings

Twelve patients displayed an acral cyanotic livedo and edema of the extremities (Figure, B). Most lesions were on the feet. Investigations did not reveal any general cause that could explain edema, and albumin level and renal function were normal. Six patients had skin atrophy with abnormal visibility of veins. This atrophy predominated in the temporal areas and on the dorsal part of the hands. Eight patients had nail dystrophies. For 5 children, the dystrophy consisted of an exaggerated curvature of the nail plate; for 2, accelerated growth of the nail; and for 2, distal onycholysis with hyperkeratosis.

Figure. Dermatologic and Hair Findings of 3 Patients With Cockayne Syndrome



A, A 28-year-old woman with pigmented macules on sun-exposed area (left arm). B, Cyanotic edema of the right leg in a 3-year-old child. C, Pseudo "tiger-tail" appearance of 1 hair shaft (polarized microscopic examination; original magnification $\times 400$).

The parents of 7 patients reported hair anomalies that were characterized by exaggerated hair loss in 5 children that was not related to fever or infection. We did not observe alopecia. All but 3 patients, including those with COFS syndrome, displayed loss of subcutaneous orbital fat leading to enophthalmia. Other rare dermatologic findings are summarized in Table 2.

Photobiologic Exploration

Photobiologic exploration was performed in 10 children. Three had normal minimal erythema dose, whereas 4 had lowered minimal erythema dose (≤ 400 mJ/cm²). After 24 hours, an iterative phototest was erythematous in 4 patients and became bullous in 2 children after 6 days. All children recovered after 13 days.

Hair Findings

Atypical alternating dark and light bands were observed in 14 patients on microscopic examination with polarized light (Figure, C). This pseudo "tiger-tail" appearance was not constant in each hair and was not localized in the distal part but rather was distributed randomly within the hair shaft. There was no trichoschisis. Amino acid analysis was not performed.

Discussion

In this study of 16 patients with genetically characterized CS and COFS syndrome, the high prevalence of photosensitivity was confirmed as an early sign of the disease. Acral cyanosis

Table 1. Number of Pigmented Lesions Measuring Less Than 3 mm

No. of Lesions	No. of Patients ^a
Sun-exposed areas	
<5	9
5-10	3
11-20	0
>20	3
Sun-unexposed areas	
<5	12
5-10	1
11-20	1
>20	0

^a Data reported only as yes or no in some categories.

with slight peripheral edema, which to our knowledge has not been previously reported, was present in 75% of the patients with CS. To our knowledge, this report is the first extensive description of skin findings in a cohort of patients with genetically ascertained CS and COFS syndrome.

Photosensitivity was the major dermatologic symptom and occurred in 12 of our patients, but the 4 remaining children were never sun exposed. In 1992, Nance and Berry² proposed criteria for clinical diagnosis of CS, and photosensitivity was classified as a minor criterion. In a review of the literature, they found 72% of patients with a history of sun damage. Later, photosensitivity was reported¹¹ in 24 (96%) patients with CS confirmed by defective post-UV RNA synthesis, and photosensitivity was then cited as the most frequent symptom in CS. For 6 of the patients (50%), sunburn appeared when the patient was behind a windshield, which is an indicator of high skin sensitivity to UV light.

Cockayne syndrome usually is not associated with sun-induced pigmentation, and this absence is considered as a cardinal sign for differentiation with xeroderma pigmentosum.^{2,12} Among our patients, 7 had pigmented lesions on sun-exposed areas, but only 3 of these individuals had more than 20 lesions. An explanation for this paucity of pigmented lesions could be that, because children with CS develop severe sunburns even during a short time of exposure, their parents provide protection beginning at a very young age. This hypothesis is supported by the intensive photoprotection reported by the parents in this population.

Acral edema was the second most frequent dermatologic symptom, occurring in 75% of our patients. To our knowledge, it has never been reported in CS. Ozdirim et al¹³ described large feet and hands in 14 of 25 patients (56%) but did not mention edema. In the present study, edema was cyanotic with increased visibility of veins because of skin atrophy. It predominated in the feet and was more apparent with low temperatures. A neurologic cause was suspected because vascular complications of paralyzing neurologic disorders are well known to practitioners, although they have been rarely reported.¹⁴ These vascular complications consist of cold and edematous feet with acrocyanosis, as we observed in our patients. However, we also observed hand edema in one patient, a situation that is not common in neurologic paralyzing diseases.

Table 2. Rare Dermatologic Findings in 16 Patients With Cockayne Syndrome

Symptom	No. of Patients
Nails	
Hyperlongitudinal curvature of the fingernails	5
Accelerated nail growth	2
Distal onycholysis	2
Ungual hyperkeratosis	2
Hair and body hair	
Exaggerated hair loss	5
Accelerated hair growth	1
Hypertrichosis of the lower limbs	1
Mouth and tongue	
Geographic tongue	2
Cheilitis	1
Small mouth	1
Pigmented and achromic lesions	
Multiple large non-blaschko-linear pigmented macules	1
Cafe-au-lait spot	1
Mongolian spot of the lumbar area	1
Achromic macule localized on the trunk or buttock	2
Angioma and vascular disorders	
Acral edema	12
Stellate angioma of the right cheek	1
Tuberous angioma (present at birth)	1
Telangiectasia of the cheek	2
Atrophic skin and scars	
Atrophic skin	6
Scars on the dorsal hands and nose	1
Other symptoms	
Atopic eczema	1
Xerosis	2
Pilonidal sinus	1
Bradymetacarpia of the fifth fingers	1
Pityriasis versicolor on the trunk	2
Facial acne	2

Cockayne syndrome belongs to the progeroid syndromes. When patients with CS grow older, the fat surrounding their eyes is progressively reduced, leading to sunken eyes, and the skin becomes thin. Thin skin predominates on temporal areas, with abnormal visualization of veins. Thin skin was one of the major skin symptoms in a large review, and it is also observed in trichothiodystrophy.²

In our cohort, exaggerated hair loss was found in 5 patients (31%), a smaller percentage than that reported in individuals with trichothiodystrophy, for whom sparse hair occurred in 48% and alopecia was mentioned in 39%.¹⁵ Nails of our patients had abnormal longitudinal curvature (clubbing) in 5 cases (31%), abnormal growth in 2 cases (12%), and distal onycholysis with distal hyperkeratosis in 2 cases. To our knowledge, nail disorders were not reported in patients with CS or xeroderma pigmentosum. Dysplasia, splitting (onychoschizia), koilonychias, ridging, thickening (onychogryphosis), yellow discoloration, brittle nails, hypoplasia,

and unguis inflexus were noted in large reviews of trichothiodystrophy and occurred in 63% of the patients,¹⁵ but no patients had nail clubbing. Clubbing was thought to be secondary to nail hypervascularization and cyanosis.¹⁶ In our patients, hypertransverse curvature and acral edema might be related to these conditions.

Nance and Berry² noticed dry and sometimes scaly skin as dermatologic signs of CS. They related these signs to anhi-

dro-sis secondary to hypoplasia of the eccrine sweat glands. Xerosis constituted a dermatologic finding in only 2 of our patients.

In conclusion, in addition to the known dermatologic findings of a high prevalence of photosensitivity as well as hair and nail disorders, these 16 cases of CS and COFS syndrome exhibited cyanotic acral edema. To our knowledge, this finding has not been previously reported in CS.

ARTICLE INFORMATION

Accepted for Publication: July 7, 2013.

Published Online: October 23, 2013.

doi:10.1001/jamadermatol.2013.6683.

Author Affiliations: Service d'Anatomie et Cytologie Pathologiques, Centre Hospitalier Universitaire de Montpellier, Montpellier, France (Frouin); Service d'Anatomie et Cytologie Pathologiques, Université de Montpellier, Montpellier, France (Frouin); Service de Dermatologie, Hôpital Civil, Hôpitaux Universitaires de Strasbourg, Strasbourg, France (Frouin, Lipsker); Faculté de Médecine, Université de Strasbourg, Strasbourg, France (Frouin, Laugel, Dollfus, Lipsker); Service de Pédiatrie 1, Hôpital de Hautepierre, Hôpitaux Universitaires de Strasbourg, Strasbourg, France (Laugel, Durand); Service de Génétique Médicale, Hôpital de Hautepierre, Hôpitaux Universitaires de Strasbourg, Strasbourg, France (Durand, Dollfus).

Author Contributions: Drs Frouin and Lipsker had full access to all the data in the study and take responsibility for the integrity of the data and the accuracy of the data analysis.

Study concept and design: Laugel, Dollfus, Lipsker.

Acquisition of data: Frouin, Laugel, Durand, Lipsker.

Analysis and interpretation of data: Frouin, Laugel, Lipsker.

Drafting of the manuscript: Frouin, Laugel, Durand, Lipsker.

Critical revision of the manuscript for important intellectual content: Laugel, Dollfus.

Obtained funding: Laugel, Dollfus.

Administrative, technical, and material support: Laugel, Durand.

Study supervision: Laugel, Lipsker.

Conflict of Interest Disclosures: None reported.

Funding/Support: This work was supported by grants from the French Ministry of Health (National Program for Clinical Research) and from the Institut des Maladies Rares.

Role of the Sponsor: The French Ministry of Health and the Institut des Maladies Rares had no role in the design and conduct of the study; collection, management, analysis, and interpretation of the data; preparation, review, or approval of the manuscript; and decision to submit the manuscript for publication.

Additional Contributions: We thank all patients and families who collaborated in this work, the support groups Amy and Friends and Les P'tits Bouts, and all physicians in charge of the care for these patients who helped to collect relevant clinical information. No financial compensation was given for these services.

REFERENCES

- Cockayne EA. Dwarfism with retinal atrophy and deafness. *Arch Dis Child.* 1936;11(61):1-8.
- Nance MA, Berry SA. Cockayne syndrome: review of 140 cases. *Am J Med Genet.* 1992;42(1):68-84.
- Sarasin A, Blanchet-Bardon C, Renault G, Lehmann A, Arlett C, Dumez Y. Prenatal diagnosis in a subset of trichothiodystrophy patients defective in DNA repair. *Br J Dermatol.* 1992;127(5):485-491.
- Troelstra C, van Gool A, de Wit J, Vermeulen W, Bootsma D, Hoeijmakers JH. ERCC6, a member of a subfamily of putative helicases, is involved in Cockayne's syndrome and preferential repair of active genes. *Cell.* 1992;71(6):939-953.
- Henning KA, Li L, Iyer N, et al. The Cockayne syndrome group A gene encodes a WD repeat protein that interacts with CSB protein and a subunit of RNA polymerase II TFIIH. *Cell.* 1995;82(4):555-564.
- Lowry RB, MacLean R, McLean DM, Tischler B. Cataracts, microcephaly, kyphosis, and limited joint movement in two siblings: a new syndrome. *J Pediatr.* 1971;79(2):282-284.
- Meira LB, Graham JM Jr, Greenberg CR, et al. Manitoba aboriginal kindred with original cerebro-oculo-facio-skeletal syndrome has a mutation in the Cockayne syndrome group B (CSB) gene. *Am J Hum Genet.* 2000;66(4):1221-1228.
- Laugel V, Dalloz C, Tobias ES, et al. Cerebro-oculo-facio-skeletal syndrome: three additional cases with CSB mutations, new diagnostic criteria and an approach to investigation. *J Med Genet.* 2008;45(9):564-571.
- Laugel V, Dalloz C, Durand M, et al. Mutation update for the CSB/ERCC6 and CSA/ERCC8 genes involved in Cockayne syndrome. *Hum Mutat.* 2010;31(2):113-126.
- Fitzpatrick TB. Sun and skin [in French]. *J Med Esthet.* 1975;2:33-34.
- Lehmann AR, Thompson AF, Harcourt SA, Stefanini M, Norris PG. Cockayne's syndrome: correlation of clinical features with cellular sensitivity of RNA synthesis to UV irradiation. *J Med Genet.* 1993;30(8):679-682.
- Kraemer KH, Patronas NJ, Schiffmann R, Brooks BP, Tamura D, DiGiovanna JJ. Xeroderma pigmentosum, trichothiodystrophy and Cockayne syndrome: a complex genotype-phenotype relationship. *Neuroscience.* 2007;145(4):1388-1396.
- Ozdirim E, Topcu M, Ozon A, Cila A. Cockayne syndrome: review of 25 cases. *Pediatr Neurol.* 1996;15(4):312-316.
- Piera JB. The phlebologist confronted with the neurologic foot: phlebologic aspects of the neurologic foot [in French]. *Phlebologie.* 1987;40(2):365-370.
- Faghri S, Tamura D, Kraemer KH, DiGiovanna JJ. Trichothiodystrophy: a systematic review of 112 published cases characterises a wide spectrum of clinical manifestations. *J Med Genet.* 2008;45(10):609-621.
- Spicknall KE, Zirwas MJ, English JC III. Clubbing: an update on diagnosis, differential diagnosis, pathophysiology, and clinical relevance. *J Am Acad Dermatol.* 2005;52(6):1020-1028.