



Oleogranulomatous Mastitis: A Topical Subject

Cherif Akladios, MD, PhD*
Vaneesa Kadoch, MD†
Frederic Bodin, MD, PhD†
Catherine Bruant-Rodier,
MD, PhD†
Astride Wilk, MD, PhD†
Carole Mathelin, MD, PhD‡

Summary: Paraffin and petrolatum have been known for more than 100 years as volumizing products. Certain countries still use them despite important complications. The authors report the case of a 39-year-old patient presenting a bilateral oleogranulomatous mastitis. An injection of petrolatum had been realized 2 years ago in Chechnya for cosmetic reasons. Clinically, she presented dense, erythemic, and painful breasts. The radiological examination found diffuse oily cysts. After first abdominal expansion, a bilateral mastectomy with immediate reconstruction was performed. The authors present a literature review about the clinical and radiological data and the possible treatments, and underline the numerous risks of this procedure, which should be strictly forbidden. (*Plast Reconstr Surg Glob Open* 2015;3:e536; doi: 10.1097/GOX.0000000000000513; Published online 14 October 2015.)

Petroleum jelly—a semisolid form of paraffin—was used for the first time in 1899. Then, because of its relatively low melting point (40°C), it has been replaced by more solid paraffin as a filler of tissue defects, wrinkles, and breasts. The immediate satisfactory results on a cosmetic level, the low cost, and the painless character have encouraged its rapid diffusion.

After a decade, however, complications like tissue necrosis, fat embolism, skin ulceration, infection, etc. were reported. In Kolle's¹ book, entitled *Plastic and Cosmetic Surgery*, a whole chapter was devoted to complications of paraffin injection into breast tissue. These complications ranged from cosmetic failure to death, and most of them required mastectomy. In 1926, Lyons and Hunt² described the paraffin injections as an “inexcusable practice.”

Two decades later, the use of petrolatum and paraffin has been abandoned for breast augmentation

in Western countries. In other countries, however, its use has continued into the fifties and beyond, despite the ongoing publications of serious complications.^{3,4} Finally, the medical profession abandoned the use of paraffin for breast augmentation after 1975. Some observations indicate, however, that patients themselves performed these injections.⁵ Surprisingly, we report a very recent case of paraffin injections by a physician, attesting to the persistence of this practice in some countries.

OBSERVATION

A 39-year-old patient consulted in 2011 in the University Hospital of Strasbourg for tense and painful breasts after an injection of petrolatum in Chechnya 2 years ago to increase her breast size. The patient gradually developed bilateral edema and erythema. In addition, the patient described fever episodes evolving repeatedly and associated with a major weakness. The clinical breast examination found erythematous plates in the upper and internal regions without ulceration or fistula consequences (Fig. 1A).

The mammogram showed multiple rounded masses of fat density, confluent and disseminated over dense breasts (Fig. 1B). At the ultrasound, there were multiple thin-walled cystic formations of anechoic content. The fine-needle aspiration confirmed the presence of an oily liquid. The

From the *Strasbourg University Hospital: Pole of Obstetrics and Gynecology, Hautepierre Hospital, Strasbourg, France; †Department of Plastic and Reconstructive Surgery, Civil Hospital, Strasbourg, France; and ‡Breast Diseases Center, Pole of Obstetrics and Gynecology, Hautepierre Hospital, Strasbourg, France.

Received for publication November 26, 2014; accepted October 18, 2015.

Copyright © 2015 The Authors. Published by Wolters Kluwer Health, Inc. on behalf of The American Society of Plastic Surgeons. All rights reserved. This is an open-access article distributed under the terms of the Creative Commons Attribution-Non Commercial-No Derivatives License 4.0 (CCBY-NC-ND), where it is permissible to download and share the work provided it is properly cited. The work cannot be changed in any way or used commercially.

DOI: 10.1097/GOX.0000000000000513

Disclosure: The authors have no financial interest to declare in relation to the content of this article. The Article Processing Charge was paid for by the authors.

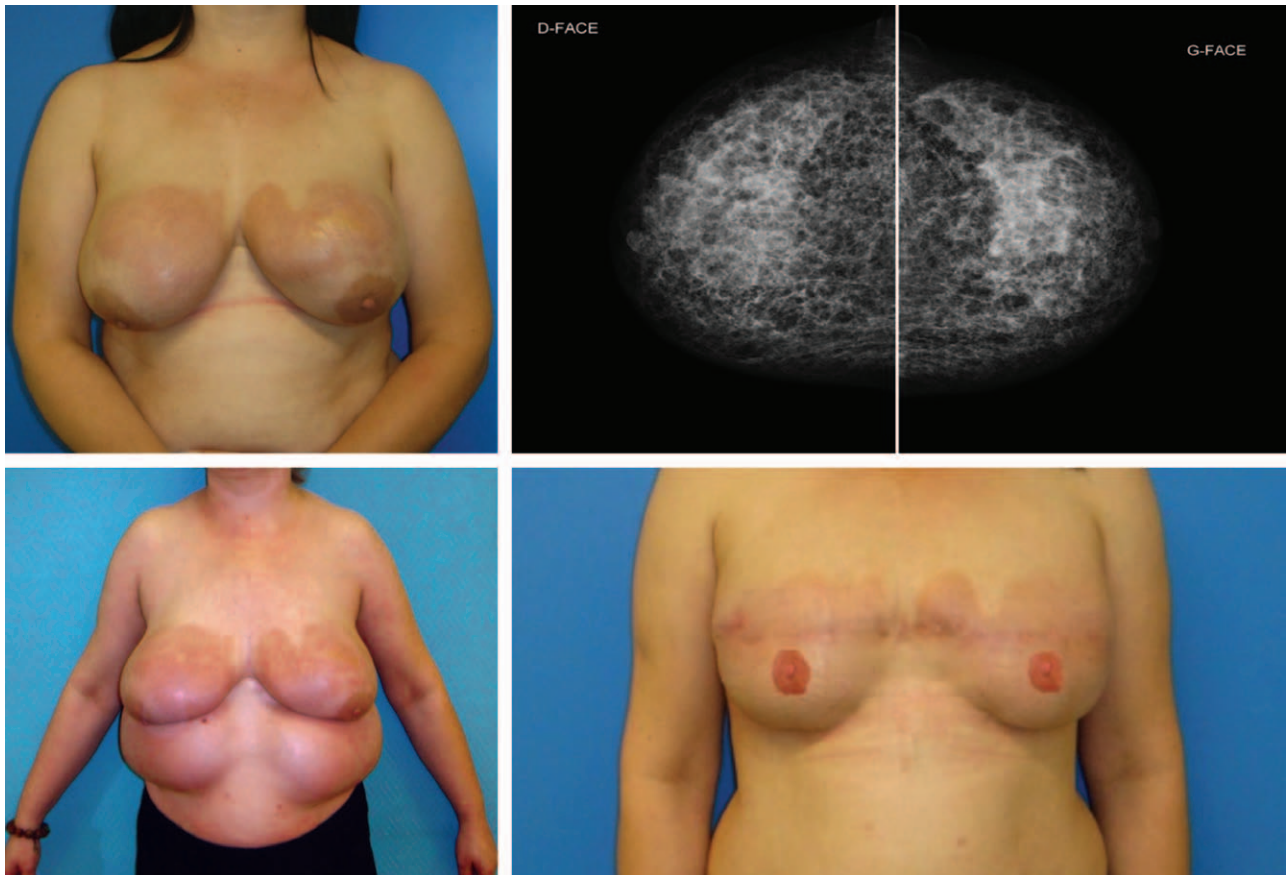


Fig. 1. A, Preoperative clinical appearance of both breasts. Bilateral erythematous plates of the upper and internal regions are found without ulcers or fistula sequelae. Breasts are very tense. B, Mammographic appearance of both breasts viewed from the front showing multiple small lights scattered throughout the mammary gland, although limited and noncalcified with a predilection for retro grandular and prepectoral regions. C, An abdominal expansion by saline inflatable implants was performed (prostheses volume: 1 L per side) and left in place for 3 and a half months. D, Front final aspect and after reconstruction of nipple-areolar plates. There remains an erythematous area in the upper pole of the breast.

magnetic resonance imaging showed diffusely infiltrated breasts with multiple cysts. The images were enhanced after gadolinium injection.

Aspiration followed by liposuction was tried to eliminate petrolatum, but without any result, the breasts being too fibrous and petrolatum too diffuse. After prolonged anti-inflammatory and antibiotic treatment, the patient agreed to a bilateral mastectomy. Given the extent of resection, immediate breast reconstruction was impossible without prior tissue expansion. Abdominal expansion by saline inflatable implants was performed (Fig. 1C). The prostheses volume was 1 L per side. Inflation was performed once a week. The prostheses were overinflated and left in place for 3 and a half months. The second intervention consisted of a bilateral mastectomy without preservation of the nipple-areolar plates, which were too adherent and inflammatory. The gland and the pectoralis major muscle were infiltrated, fibrous, and altered. The removed mammary glands

weighed 930–950 g. Histological examination of the breasts confirmed the diagnosis of oleogranulomatous mastitis (OM). Immediate breast reconstruction was obtained by expansion and advancement of abdominal flap. To avoid excessive skin tension, inflatable breast expanders were introduced at the retro pectoral level. Three months later, expanders were removed and replaced by permanent silicone prostheses with an anatomical shape of 520 g.

The nipple-areolar complex was reconstructed later by transplantation of the earlobe and tattoo. The postoperative course was uneventful. Today, the patient has no longer pain or inflammation or fever. The cosmetic result is satisfactory, despite a persistent erythematous area in the upper pole of the breasts (Fig. 1D).

DISCUSSION

Our observation is consistent with a recent injection of paraffin, as evidenced by history and radio-

graphic appearance of the breasts. Indeed, recent injections result in multiple small lights scattered throughout the mammary gland, although limited and noncalcified.⁶ In contrast, former injections are characterized by dense masses with semicircular or “soap–bubble-like” calcifications.⁷

Considering the fact that paraffin injections were recent, we tried to avoid in the first-place mastectomy, using liposuction of oily masses. But, because of the inflammatory and hypervascular nature of the tissue on the one hand and of the small oily masses and their diffuse nature on the other hand, the attempt was unsuccessful.

For many authors, mastectomy is the only curative treatment. In Alagaratnam and Ng's⁸ series of 43 patients, where the injections were recent or very old (realized between 3 and 41 years ago), 30 mastectomies had to be performed because of the importance of the masses and chronic ulcerations. Ho et al⁹ reported 8 patients cared for OM (injections performed between 11 and 30 years ago). In one case, the injection of paraffin was followed by destructive ulceration of the anterior chest wall, with damage to both pectoral muscles and the ribs. The author also concluded that the only possible treatment for OM was mastectomy, which might be associated with first-stage reconstruction by rectus abdominal musculocutaneous flap. Ortiz-Monasterio and Trigos¹⁰ propose second-stage breast reconstruction due to the risk of bleeding and infections.

In our case, mastectomy with conservation of the skin would have resulted in a thin skin covering the implant, with increased risk of exposure of the prosthesis. To reduce the risk of complications, we performed an original method for abdominal expansion to provide healthy skin to the implant. Reconstruction is cosmetically satisfactory, but a rash persists in the upper quadrants.

CONCLUSION

OM is a challenge for surgeons. Therapeutic problems are indeed encountered because patients

attach great importance to the cosmetic result, and paraffin injections have been devised for aesthetic reasons. Patients also pose psychological difficulties because they do not understand the seriousness of the problem and do not accept mutilation for a benign lesion. No treatment is able to modify the course of the OM, which may be accompanied by skin ulceration or parietal necrosis. We have shown that liposuction of paraffin is impossible. Mastectomy is the only treatment, possibly associated with immediate breast reconstruction or delayed. The injection of paraffin or petrolatum leads to real dilapidations, and for that reason must be firmly prohibited.

Dr. Cherif Akladios, MD, PhD

Strasbourg University Hospital

Department of Obstetrics and Gynecology

1 Avenue Molière

67000 Strasbourg, France

Email: cherif.akladios@gmail.com

REFERENCES

1. Kolle F. *Plastic and Cosmetic Surgery*. D Appleton and Co: New York; 1911.
2. Lyons H, Hunt M. *Plastic Surgery of the Head, Face and Neck*. Philadelphia, Pa: Lea & Febiger; 1926.
3. Tinckler LF, Stock FE. Paraffinoma of the breast. *Aust N Z J Surg*. 1955;25:142–144.
4. Pang TC. Death following injection of paraffin into the breast. *Br Med J*. 1957;1:992.
5. Peters W, Fornasier V. Complications from injectable materials used for breast augmentation. *Can J Plast Surg*. 2009;17:89–96.
6. Erguvan-Dogan B, Yang WT. Direct injection of paraffin into the breast: mammographic, sonographic, and MRI features of early complications. *AJR Am J Roentgenol*. 2006;186:888–894.
7. Sinclair DS, Freedy L, Spigos DG. Case 3. Altered breast: paraffin injection with development of paraffinomas. *AJR Am J Roentgenol*. 2000;175:861; 864–865.
8. Alagaratnam TT, Ng WF. Paraffinomas of the breast: an oriental curiosity. *Aust N Z J Surg*. 1996;66:138–140.
9. Ho WS, Chan AC, Law BK. Management of paraffinoma of the breast: 10 years' experience. *Br J Plast Surg*. 2001;54:232–234.
10. Ortiz-Monasterio F, Trigos I. Management of patients with complications from injections of foreign materials into the breasts. *Plast Reconstr Surg*. 1972;50:42–47.