

BIOMECHANICS OF THE HUMAN HAND*Łukasz Jaworski¹, Robert Karpiński²*

¹ Poznan University of Technology, Faculty of Mechanical Engineering and Management, Piotrowo 3 Str., 60-965 Poznań, Poland, email: lukasz.m.jaworski@student.put.poznan.pl

² Lublin University of Technology, Faculty of Mechanical Engineering, Biomedical Engineering Department, Nadbystrzycka 36 Str., 20-618 Lublin, Poland, orcid.org/0000-0003-4063-8503, email: robert.karpinski@pollub.edu.pl

Submitted: 2017-06-09 / Accepted: 2017-06-22 / Published: 2017-06-30

ABSTRACT

The paper provides basic information on human hand's anatomical structure with the location of joints and consequent types of achievable movements. The biomechanics of the human hand is described using two different kinematic models of the hand. The differences between the models are described. The Schlesinger's classification of movements of the human hand is introduced.

KEYWORDS: biomechanics, hand, kinematic model, anatomy, joint

BIOMECHANIKA DŁONI LUDZKIEJ**STRESZCZENIE**

Praca zawiera podstawowe informacje o budowie anatomicznej dłoni ludzkiej, włącznie z lokalizacją stawów i wynikających z nich rodzajów osiągniętych ruchów. Opisano biomechanikę dłoni ludzkiej używając jej dwóch różnych modeli kinematycznych. Przedstawiono różnice między modelami. Zaprezentowano klasyfikację typów chwytów dłoni według Schlesingera.

SŁOWA KLUCZOWE: biomechanika, dłoń, model kinematyczny, anatomia, staw

1. Introduction

The human hand is one of the most extraordinary parts of the entire human body. Thanks to its remarkable precision people can perform a wide set of various, sometimes complicated tasks – from using a needle to playing an instrument. This ability comes from hand's complex physiology – complicated anatomy merged with advanced muscular system and ligaments.

2. Basic anatomy of the human hand

Due to its structure, the human hand is considered as one of the most complicated and fascinating part of the human body [1]. It consists of 29 bones connected via numerous joint. The simplest division distinguishes three main parts of the hand:

- the wrist (Latin: carpus),
- the palm (Latin: metacarpus),
- fingers (Latin: digiti manus).

The wrist is composed of eight small carpal bones – scaphoid, lunate, triquetrum, pisiform, trapezium, trapezoid, capitate and hamate, arranged in three columns: the radial scaphoid, the lunate and ulnar triquetral column. Their main function is to connect the hand with the forearm.

Metacarpal bones, thanks to their structure, are classified as long bones. Each bone consists of the base articulating with the carpal bones, the body and the head connected to corresponding finger [2, 3]. Fingers comprise of phalanges – from second (index) to fifth (little) they have three phalanges – proximal, intermediate and distal, while the thumb is an exception and lacks the intermediate phalanx [3]. The anatomical structure of most of the phalanges is similar to the metacarpal bones, with only the distal phalanges of every finger ending in two condyles (knuckles) [2].

With reference to the aforementioned issues, there are several joints articulating human hand. Starting from the wrist, there is the radiocarpal joint between the radius bone and carpal bones. The carpal bones form two types of joints: the midcarpal and intercarpal joints. Midcarpal joints, along with the radiocarpal joint, enable the hand to perform movements of flexion/extension (towards the palm or the back of the hand) and radial/ulnar flexion (or deviation – towards the thumb or the little finger) as shown in the Fig. 1.

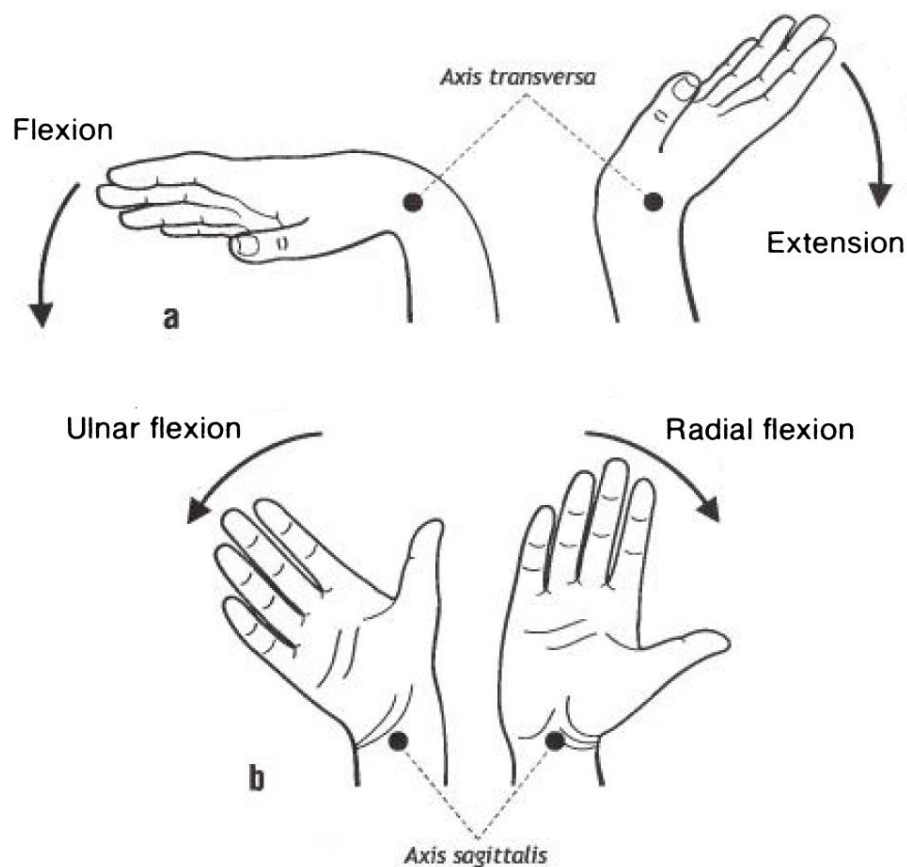


Fig. 1. Movements on the human wrist [1]

Between the carpal and metacarpal bones there are five carpometacarpal (CMC) joints and only one of them, the CMC of the thumb, has a wide range of movements, including flexion and extension, abduction and adduction, circumduction, and opposition. The movements in other CMC joints are significantly limited [2, 3].

At the base of each proximal phalanx there is the metacarpophalangeal joint, allowing the movements of flexion, extension, abduction, adduction and circumduction. The joints between phalanges are called interphalangeal joints. Each finger from the second to the fifth has two

interphalangeal joints – proximal (between proximal and intermediate phalanx) and distal (between intermediate and distal phalanx), while in the thumb the articulation occurs only between proximal and distal, as it lacks the intermediate phalanx. These joints facilitate the movements of flexion and extension of the phalanges [2, 3].

3. Biomechanics of the human hand

3.1. Kinematic models of the human hand

In terms of kinematics, the hand is an open kinematic chain starting in the wrist joint and ending in finger joints. Due to the specific structure of human joints, only rotational motions are possible. In case of structural analysis of the hand as the biomechanism, individual bones are considered as movable parts, and their joints as kinematic pairs of different classes (class III – 3 degrees of freedom, class IV – 2DoF, class V – 1 DoF) [4]. It is said that every group of scientists approaching the topic of the biomechanics of the human hand and its kinematic analysis, depending on the amount of simplifications and assumed application of the study, presents results and descriptions varying mostly on the number of the degrees of freedom of the model. In 2008, Sobos et al. presented the model depicting the human fingers in reference to the wrist comprised of 19 links imitating the corresponding human bones, and 24 degrees of freedom representing the joints [5].

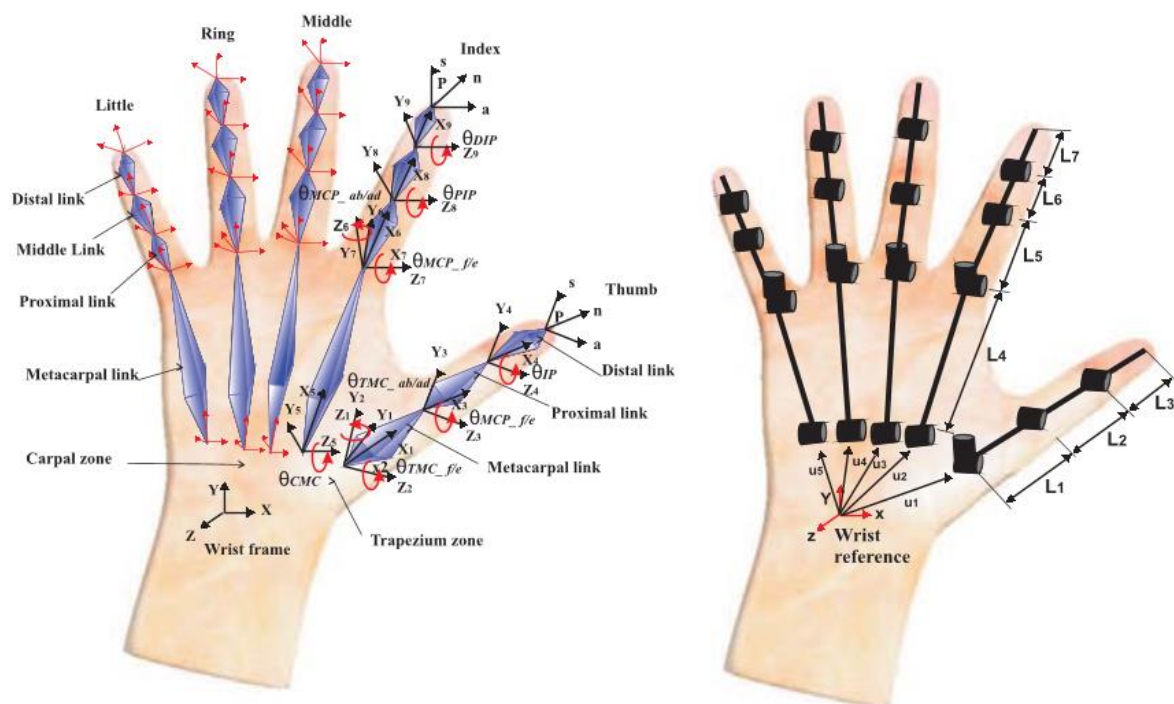


Fig. 2. The kinematic chains of the human fingers [5]

Morecki et al. [6] developed a similar solution, having 22 degrees of freedom in the palm and fingers with additional 3 DoFs for the wrist and its connection to the forearm, as shown in the Fig. 3. Morecki made some simplifications based on the statement, that the joint, where the angular range of motion was less than 5 degrees (or 2mm in the linear RoM), was considered as a slack and the motion relatively linear or angular could be ignored. Compared to the Sobos' model, Morecki disabled the motion in the second and third CMC, as it was insignificant to the motion of second and third finger, while leaving the ability to rotate fourth and fifth metacarpal bones towards the wrist in corresponding CMCs (elements 15 and 19 in the Fig. 3). Both models considered both flexion/extension and abduction/adduction movements of the fingers in all metacarpophalangeal joints [5, 6].

3.2. Range of motion of the hand and types of grasp

Due to an extensive research with the use of specialised equipment it was possible to approximately delimit the range of motion in each joint of the human hand, as shown in Tables 1 and 2. Certainly, the value may vary depending on the subject, thus it is crucial to examine every case individually.

Table 1. Range of motion in finger joint [5]

Finger	Flexion	Extension	Abduction/adduction
Thumb			
Trapeziometacarpal	50° - 90°	15°	45° - 60°
Metacarpophalangeal(MCM)	75° - 80°	0°	0°
Interphalangeal (IP)	75° - 80°	5° - 10°	0°
Index			
Carpometacarpal (CMC)	5°	0°	0°
MCP	90°	30° - 40°	60°
Proximal interphalangeal (PIP)	110°	0°	0°
Distal interphalangeal (DIP)	80° - 90°	5°	0°
Middle			
CMC	5°	0°	0°
MCP	90°	30° - 40°	45°
PIP	110°	0°	0°
DIP	80° - 90°	5°	0°
Ring			
CMC	10°	0°	0°
MCP	90°	30° - 40°	45°
PIP	120°	0°	0°
DIP	80° - 90°	5°	0°
Little			
CMC	15°	0°	0°
MCP	90°	30° - 40°	50°
PIP	135°	0°	0°
DIP	90°	5°	0°

Table 2. Range of motion in the wrist [7]

Wrist	Value
flexion	65° - 70°
Extension	70° - 80°
Radial flexion (deviation)	15° - 25°
Ulnar flexion (deviation)	40° - 45°

The large number of joints and muscles, as well as the size of areas of cerebral cortex responsible for motor and sensory control of the hand, provides the ability to perform a series of various complicated movements, necessary in daily activities [1]. In 1919, Schlesinger determined six types of moves representing most of hand's functions: a cylindrical grasp, a tip or precision pinch, a hook (or snap), a palmar grasp (also known as an opposition pinch, a spherical (span) grasp and a lateral (key) pinch, as shown in the Fig. 4 [1, 8].

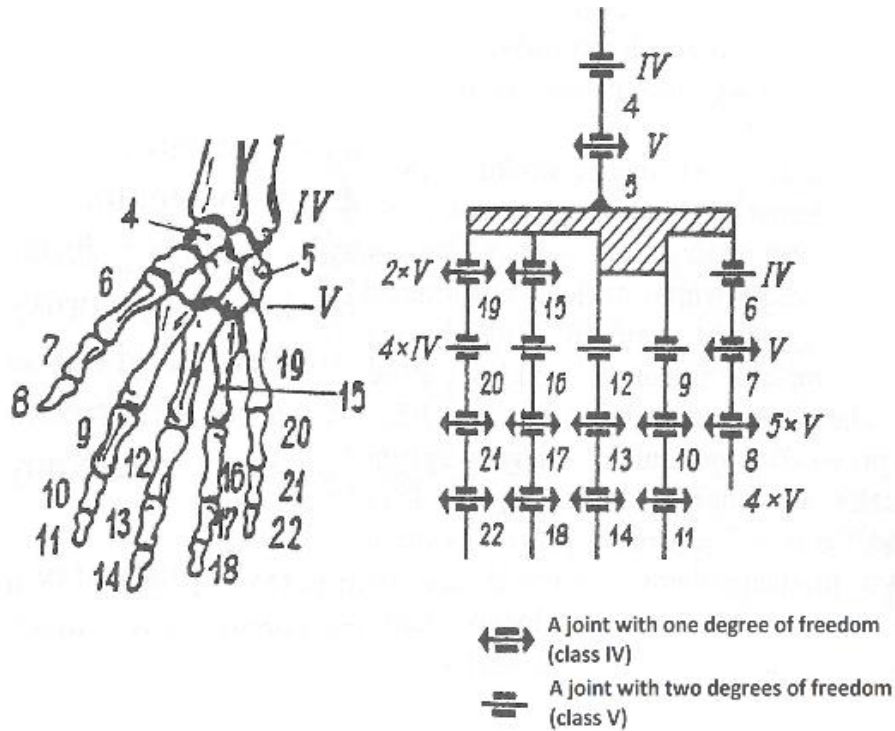


Fig. 3. Morecki's kinematic model of human hand [6]

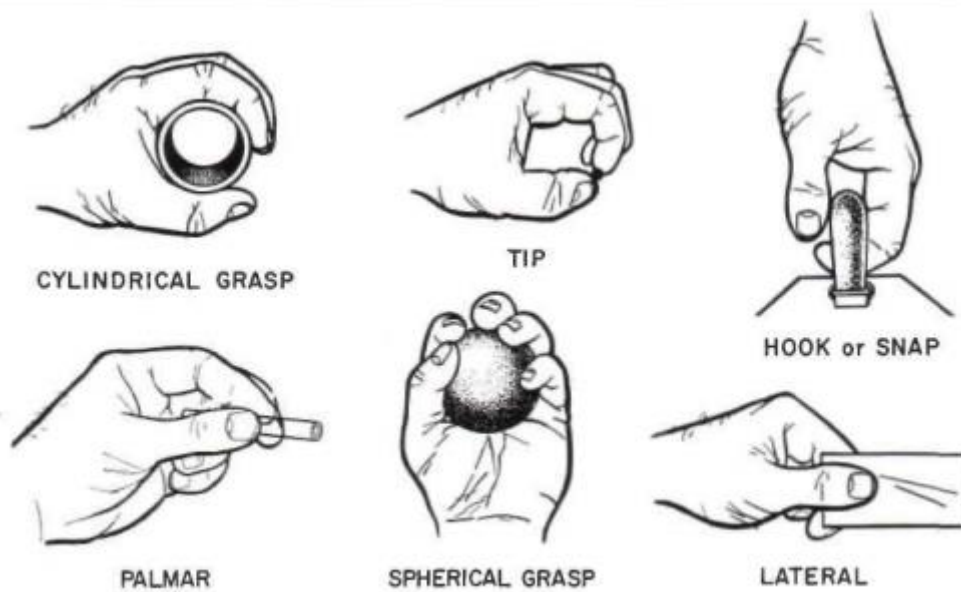


Fig. 4. Types of grasp [8]

4. Conclusion

The human hand is an extremely complicated manipulator, capable of performing many different activities. Every injury may effect in losing a part of hand's functionality, which could take its toll on affected person. In order to minimise the time and effort essential in the process of the rehabilitation of the hand it is crucial to understand its biomechanics, apply the knowledge to design more efficient equipment and in extreme cases involving amputations – even to replace a damaged hand with an advanced prosthesis, reinstating some of hand's functionality.

5. References

- [1] R. J. Schwarz, C. L. Taylor, *"The anatomy and mechanics of the human hand"*, *Artificial Limbs*, vol. 2, no. 2, pp. 22 – 35, 1955.
- [2] W. Woźniak, Ed., Wrocław, *Anatomia człowieka. Podręcznik dla studentów i lekarzy*, Poland: Elsevier Urban & Partner, 2003.
- [3] Z. Ignasiak, *Anatomia układu ruchu*, Wrocław, Poland: Elsevier Urban & Partner, 2007.
- [4] Ł. Jaworski *et al.*, "Biomechanics of the upper limb", *J. Technol. Exploit. Mech. Eng.*, vol. 2, no. 1, pp. 53 – 59, 2016.
- [5] S. Cobos *et al.*, "Efficient human hand kinematics for manipulation tasks", *2008 IEEE/RSJ International Conference on Intelligent Robots and Systems*, Nice, 2008, pp. 2246-2251.
- [6] A. Morecki *et al.*, *Teoria mechanizmów i manipulatorów*, Warsaw, Poland: Wydawnictwo Naukowo-Techniczne, 2002.
- [7] M. M. Marshall *et al.*, "The Effects of complex wrist and forearm posture on wrist range of motion", *Human Factors*, vol. 41, no. 2, pp. 205 – 213, 1999.
- [8] G. Schlesinger, *Der mechanische Aufbau der kunstlichen Glieder, Ersatzglieder und Arbeitshilfen*, Berlin, Germany: Springer, 1919, pp. 321-661.