



International Journal of Sciences: Basic and Applied Research (IJSBAR)

ISSN 2307-4531
(Print & Online)

<http://gssrr.org/index.php?journal=JournalOfBasicAndApplied>



Disseminated Fungal Infections in a Kidney Graft Transplant Recipient: Case Report and Literature Review

Dr. Samuel Kabinga^{a*}, Dr. Marybeth Maritim^b, Dr. Daniel Zuriel^c, Dr. John Ngigi^d, Prof. Seth McLigeyo^e

^a *University of Nairobi, College Of Health Sciences, School of Medicine, P.O. BOX 30197 Postcode 00100
Nairobi, Kenya*

^b *Kenyatta National Hospital, P.O. BOX 20723 Postcode 00202 Nairobi, Kenya*

Abstract

We present a 61-year-old male, retired driver and a farmer from rural Kenya, East Africa, who had end-stage renal disease for 2 years with a background of diabetes mellitus and hypertension. He was on haemodialysis since September 2011. He got kidney graft transplant from a living-related donor in October 2013. Six months later, presented with subcutaneous swellings on lower limb and trunk, for 2 months which were identified to be Aspergillosis and Mucormycosis. The history, clinico-laboratory picture and brief management are given. A review of literature on fungal infections in kidney graft recipients is also presented.

Fungal infections are an important cause of morbidity and mortality in renal transplant recipients. The risk factors and the causative agents differ depending on the period after the kidney transplant and the incidence varies depending with the geographical area. The emerging fungal infections and paucity of data regarding their management pose a challenge to the transplant physicians.

Keywords: Aspergillosis; Mucormycosis; kidney transplant recipient.

* Corresponding author.

1. Introduction

In this paper we are going to describe the case of J.G.M, he is 61 year-old male, retired driver, farmer from rural Kenya, known with diabetes mellitus for 17 years, hypertensive for six years, with subsequent end-stage kidney failure and was on renal replacement therapy for 2 years. During this time, he suffered from cytomegalovirus disease (twice) and hepatitis B virus infection. He got kidney graft transplantation from living-related donor in October 2013. Since transplantation, he had been on oral mycophenolic acid 720 mg twice daily, cyclosporin 200mg twice daily, prednisone 20mg once daily, pantoprazole 40mg once daily, isoniazid 300 mg daily, cotrimoxazole 960 mg daily, pyridoxine 25 mg daily, lamivudine 150 mg orally daily, hydrallazine 50mg thrice daily, metoprolol 100mg daily, mixed insulin (30/70) 24 units in morning, 12 units in the evening with soluble insulin 12 units lunch time.

He presented with subcutaneous swellings on left thigh, left anterior abdominal wall, left parasternal and right anterior cervical region swelling for 2 months and lower limbs swelling, more on the left than right. Examination revealed an elderly, sick-looking man, not pale, not icteric, not cyanosed, no oral thrush, right posterior cervical triangle lymph node enlargement, bilateral distal legs and asymmetrical bipedal oedema.

Blood pressure : 140/70 mmHg

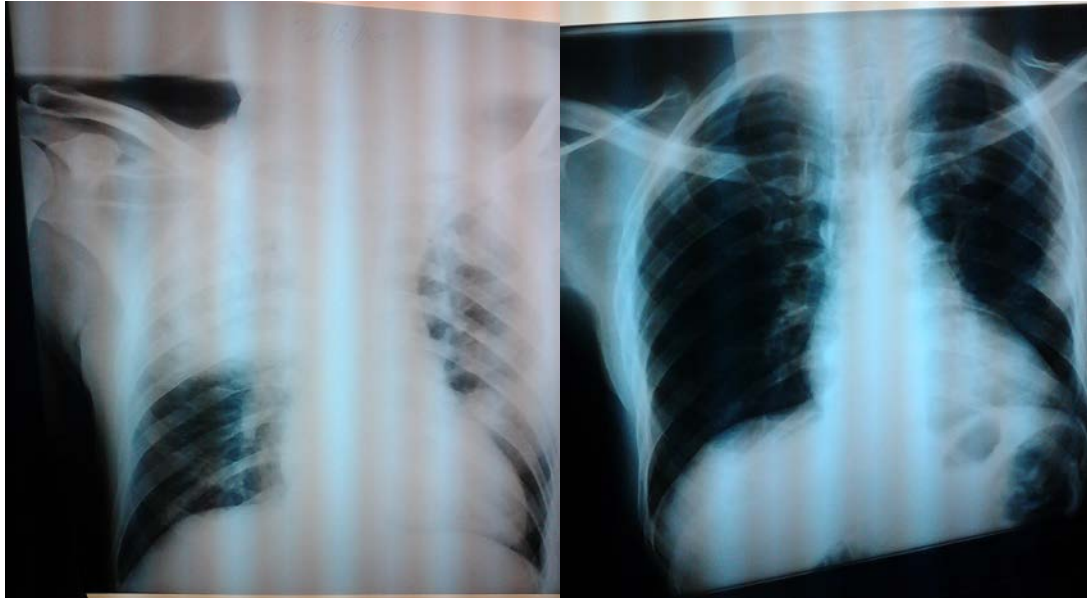Pulse rate: 88 beats/minute

Respiratory rate: 14breaths/minute

Temperature:36.8°C.

Respiratory system examination revealed a mid left sternal healing surgical incision, others findings were unremarkable. Abdominal examination revealed healed surgical scar at the right iliac. Three subcutaneous nodular swellings, largest measures about 4cm in diameter. Mobile, non-tender with no skin colour changes. No palpable liver of spleen abdominally. No bruits. Cardiovascular system findings were unremarkable. Musculoskeletal examination revealed healing surgical incision on the anterior mid thigh on the left, three nodular swellings on the lateral aspect of mid thigh, largest about 2 cm in diameter. Non tender, mobile, no skin changes. Femoral, popliteal, posterior tibial pulses present, right dorsalis pedis present. Left not dorsalis pedis not assessed. Asymmetric mild oedema of the feet, hyperpigmented patched over the sole of left foot and toes. Very tender left foot. Mr. J.G.M was admitted and management started. He however developed progressive renal dysfunction and, with progressive anaemia and respiratory problems.

Figure 1: Left thigh nodular swellings



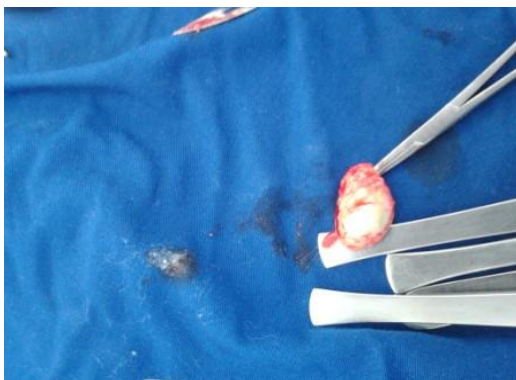
A

B

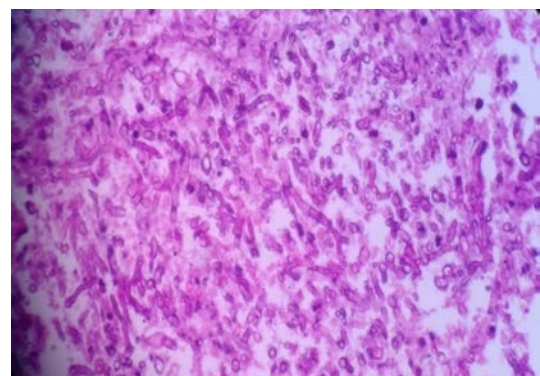
Figure 2: Chest radiographs at admission and a month later (**A** at admission, **B** 3 weeks later)

He had several complete blood counts tests, whose results ranged from leucocytosis with neutrophilia and normal lymphocyte counts to normal total white blood cells counts with mild to moderate anaemia. (Leucocytes $8.79 - 25.4 \times 10^9/L$ (4 - 11), Neutrophils 75.1 - 92.0% (40-70), Lymphocytes 3.24 - 20% (20-40), Platelets $65.5 - 470 \times 10^9/L$ (150 -450), haemoglobin 6.88 - 10.7 g/dL (14 -18)). Kidney function tests results ranged from hyponatraemia to normal sodium level, normal potassium levels and high urea and creatinine. (119 - 140 (135-145 mmol/L), Potassium 3.92 - 6.02 (3.5 - 5.0 mmol/L), Urea 8.1 - 38.9 (6.0 - 7.2 mmol/L) Creatinine, 125 - 408 (60 -110 $\mu\text{m/L}$))

Cyclosporine plasma trough levels during the hospital stay were between 101.5 -141.5 ng/mL(100 - 400ng/mL)



A



B

Figure 3: Gross appearance (**A**) and histology of the excisional biopsy from the neck lesion (**B**)

2. Microbiologic and histologic findings

2.1 Abdominal wall tissue and pus

The wet preparation was negative for organisms and negative Ziel Neelsen staining for acid-alcohol fast bacillus. Fungal culture grew *Aspergillus* spp with no bacterial growth obtained. Histology revealed non-septate hyphae and yeast form reminiscent of Mucormycosis

2.2 Right cervical node and pus

The gram stain was negative for organisms. Ziel Neelsen stain was negative for acid-alcohol fast bacillus and no bacterial growth was obtained on culture. Histology revealed septate fungal hyphae, with acute branching consistent with *Aspergillus* spp.

2.3 Sternal and Left thigh lesion biopsies

Histology : large septate fungal hyphae with spores among the necrotic debris consistent with Mucormycosis.

He was planned to receive liposomal amphotericin B 300mg intravenous infusion once daily for 4 weeks, then, step down treatment with posaconazole 400mg orally twice daily for 8 weeks. Amoxycillin-clavulanate 1g orally twice daily for 7 days. Tramadol 50 mg orally thrice daily. Plasma level of cyclosporin after every 2 days while on the above, serum calcium, phosphate, magnesium, urea, electrolytes and creatinine, and Urinalysis assays on alternate day while on amphotericin B.

He was to continue with mycophenolic acid 720 mg PO BD, cyclosporine 100mg PO BD, Prednisone 10mg PO OD, pantoprazole 40mg PO BD, co-trimoxazole 960 mg PO OD, pyridoxine 50 mg PO OD, lamivudine 150 mg PO OD, hydrallazine 50mg PO TID, metoprolol 50mg PO OD, mixed insulin 24 u AM/22 u PM and soluble insulin 12 u lunch time.

3. Discussion and Literature Review

Fungal infections can be classified as endemic or opportunistic. The endemic mycoses are infections caused by fungal organisms that are not part of the normal human microbial flora and are acquired from environmental sources. Opportunistic mycoses are caused by organisms that commonly are components of the normal human flora and whose ubiquity in nature renders them easily acquired by the immunocompromised host. For clinical discussions, fungal infections can be classified as yeast, mold, and dimorphic fungus.

Tissue invasion by fungi occurs most frequently in the setting of immunosuppression associated with therapy for hematologic malignancies, hematopoietic cell transplantation, or solid organ transplantation. Invasive fungal infections are a major complication and an important cause of morbidity and mortality among solid organ transplant recipients. Their diagnosis is difficult and their prognosis is often pejorative. In organ transplant recipients, infections can result from net state of immunosuppression. Cytomegalovirus infection appears to be a

predisposition [1]. Inhibition of phagocyte nicotinamide adenine dinucleotide phosphate (NADPH) oxidase activation, a key component in host defense against filamentous fungi, inhibit macrophage phagocytosis and killing and suppressed functional T-cell responses are factors which render the host susceptible to the infection and dissemination of established infection.

Mucormycosis is a fungal infection owing to organisms in the order Mucorales and belonging to the general class of Zygomycetes. It is the third most-common invasive, fungal infection; after aspergillosis and candidiasis. It is usually found in soil, bread molds, decayed fruits, and vegetables, and also can be cultured from the nasal cavity, the throat, the oral cavity, and the stools of healthy patients. Everybody is exposed to this infection and inhales the spores; the nasal ciliary system transports these spores down in the pharynx where it is finally cleared in the gastrointestinal tract. The spores inhaled by the lungs are cleared by the phagocytes [2]. Aspergillosis is the collective term used to describe all disease entities caused by any one of ~35 pathogenic and allergenic species of *Aspergillus*. Mucormycosis most often occurs late, >3 months after transplantation, although cases occurring early have been observed [3].

Zygomycosis (mucormycosis) is an invasive opportunistic fungal infection. It is an angio-invasive mycosis with high morbidity and mortality rates which mainly affects immunocompromised patients. Disease may manifest as rhino-orbital-cerebral, pulmonary, cutaneous, gastrointestinal, or disseminated forms [1]. Diabetes mellitus, immunodeficiency, neutropenia, and malignancy are the main underlying conditions. Predisposition of patients with diabetic ketoacidosis to mucormycosis is caused in part by increased free serum iron in the setting of acidaemia [4]. Predisposition to mucormycosis of patients treated with deferoxamine [5] is due to deferoxamine's role as a siderophore, which specifically delivers iron to the aetiological fungi [6].

Invasive fungal infections in renal transplant recipients have been reported months after transplantation. The prolonged corticosteroid and immunosuppressive therapy are the main risk factors. Renal failure, graft rejection, broad spectrum antibiotics, cytomegalovirus infection, neutropenia and dialysis [7] are other predispositions.

In the Transplant-Associated Infection Surveillance Network (TRANSNET), a consortium of 23 USA transplant centers, Pappas et al. reported a prevalence of 2.3% of invasive fungal diseases in solid organ transplantation, with a mortality rate approaching 50% [8]. Among kidney transplant recipients Petrikos *et al.* found a prevalence range between 0.2% to 1.3% [9].

Mr J.G.M. had diabetes, was on immunosuppressive treatment with prednisone, mycophenolate mofetil, and cyclosporine which are risk factors for mucormycosis and aspergillosis. He had also had suffered from CMV disease which put him at risk for the invasive mycoses.

Conventional histopathology depends on abundance and morphology of the fungi as well as on the skills of the personnel, and usually shows an accuracy of 80%. Polymerase Chain Reaction assays targeting fungal ribosomal genes to identify Mucorales at least at genus level increase sensitivity, allow a rapid identification as well as detection of double mold infections [10]. For Mr. J.G.M, histology and culture revealed both Mucormycosis and Aspergillosis.

Invasive mucormycosis in patients with acute leukemia and allogeneic stem cell transplant recipients treated with antifungal monotherapy is associated with high mortality rates of 44-49%. [11,12,13]. Among the available antifungals, amphotericin B (AmB) formulations and posaconazole demonstrated the most promising *in vitro* activities against Mucorales [14,15] and their combination displays synergistic *in vitro* activity [16,17].

According to the American Thoracic Society (ATS) and the Infectious Diseases Society of America (IDSA) three classes of antifungal agents are available for the treatment of aspergillosis: polyenes, azoles, and echinocandins. Historically, amphotericin B deoxycholate was the major antifungal drug used in patients with invasive aspergillosis [18]. Currently, the drug of choice for invasive aspergillosis is voriconazole [19]. Lipid formulations of amphotericin B are also used [20]. Echinocandins have activity against *Aspergillus* spp, but have a limited role because they have not been studied adequately for initial treatment of invasive aspergillosis. Posaconazole has comparable efficacy to voriconazole against *Aspergillus* species [21]. *Aspergillus* resistant to voriconazole and failure of posaconazole in kidney transplant recipients with invasive infection with resultant mortality has been reported in a centre in the Netherlands [22].

Mucorales are not susceptible to voriconazole and echinocandins, and as mucormycosis often mimics aspergillosis, it is extremely important to have a precise diagnostic to correctly manage the patient. The reversed halo sign on chest computed tomography has been associated to mucormycosis in neutropenic patients, but is not pathognomonic. Direct fungal identification is crucial. Treatments include lipid formulations of amphotericin B, and especially liposomal amphotericin B at high doses (5-10mg/kg/day), are the standard treatment, combined with surgery and control of favoring factors. The prognosis is poor, and any delay in the initiation of therapy may impact on outcome. [23]. The treatment of mucormycosis consists of surgical debridement, use of antifungal drugs with amphotericin B and posaconazole, and reversal of underlying risk factors, when possible. Mortality rates, although lower than in other forms of the disease, are significant, ranging from 4% to 10% when the infection is localized [24]. In renal transplant recipients, early diagnosis and combined surgical debridement and parenteral liposomal amphotericin-B along with reduction of immunosuppression improve the patient survival [25]. For Mr. J.G.M, reduction of immunosuppression would have resulted to graft loss by rejection while treatment with amphotericin B would have resulted in graft dysfunction. Concerns with treatment with amphotericin B and posaconazole for Mr. J.G.M. included drugs interactions, drugs toxicity especially nephrotoxicity, and cost for less toxic liposomal amphotericin B. Reduction of immunosuppressants would have led to rejection of the kidney graft, and return to dialysis.

Hyperbaric oxygen is a potentially significant adjunct in the treatment of invasive fungal infections. Evidence on its usefulness as a standard of care in these infections is still lacking. The value of HBO in patients should be considered on an individual basis [26].

4. Conclusion

Cutaneous mucormycosis should be considered in the differential diagnosis when a kidney transplant recipient develops erythema-nodosum-like lesions with panniculitis. Treatment of invasive fungal infections is a difficult balancing act in this group of patients.

Acknowledgement

We thank J.G.M. family who gave us a chance to care for him. Many thanks to the staff of the KNH renal unit.

References

- [1] Keskar, V.S., et al., Subcutaneous hyalohyphomycosis caused by *Fusarium* in a kidney transplant recipient. *Ren Fail*, 2014 Aug. **36**(7): p. 1129-32.
- [2] Roden, M.M., T.E. Zaoutis, and W.L. Buchanan, Epidemiology and outcome of zygomycosis: a review of 929 reported cases. *Clin Infect Dis*, 2005. **41**(5): p. 634-53.
- [3] Lanternier, F., et al., Mucormycosis in Organ and Stem Cell Transplant Recipients. *Clinical Infectious Diseases*, 2012. **54**(11): p. 1629-36.
- [4] Liu, M., B. Spellberg, and Q.T. Phan, The endothelial cell receptor GRP78 is required for mucormycosis pathogenesis in diabetic mice. *J Clin Invest*, 2010. **120**: p. 1914 - 24.
- [5] Windus, D.W., T.J. Stokes, and B.A. Julian, Fatal *Rhizopus* infections in hemodialysis patients receiving deferoxamine. *Ann Intern Med*, 1987. **107**: p. 678 - 80.
- [6] Boelaert, J.R., M. deLocht, and J. VanCutsem, Mucormycosis during deferoxamine therapy is a siderophore-mediated infection. In vitro and in vivo animal studies. *J Clin Invest*, 1993. **91**: p. 1979 - 86.
- [8] Trabelsi, H., et al., Invasive fungal infections in renal transplant recipients: about 11 cases. *J Mycol Med*, 2013 Dec. **23**(4): p. 255-60.
- [9] Pappas, P.G., et al., Invasive Fungal Infections among Organ Transplant Recipients: Results of the Transplant-Associated Infection Surveillance Network (TRANSNET). *Clin Infect Dis*, 2010. **50** p. 1101-11.
- [10] Petrikos, G., et al., Epidemiology and Clinical Manifestations of Mucormycosis. *Clin Infect Dis*, 2012. **54**(Suppl 1): p. S23-34.
- [11] Bialek, R. and U.E. Zelck, PCR-based diagnosis of mucormycosis in tissue samples. *Pathologie*, 2013 Nov. **34**(6): p. 511-18.
- [12] Lanternier, F., et al., A global analysis of mucormycosis in France: the RetroZygo Study (2005-2007). *Clin Infect Dis*, 2012. **54**(1 Suppl): p. S35-43.
- [13] Ruping, M.J., et al., Forty-one recent cases of invasive zygomycosis from a global clinical registry. *J Antimicrob Chemother*, 2010. **65**(2): p. 296-302.
- [14] Skiada, A., et al., Zygomycosis in Europe: analysis of 230 cases accrued by the registry of the European

Confederation of Medical Mycology (ECMM) Working Group on Zygomycosis between 2005 and 2007. *Clin. Microbiol Infect*, 2011. **17**(12): p. 1859-67.

[15] Almyroudis, N.G., et al., Invitro susceptibilities of 217 clinical isolates of zygomycetes to conventional and new antifungal agents. *Antimicrob Agents Chemother.*, 2007. **51**(7): p. 2587-90.

[16] Sabatelli, F., et al., In vitro activities of posaconazole, fluconazole, itraconazole, voriconazole, and amphotericin B against a large collection of clinically important molds and yeasts. *Antimicrob Agents Chemother.*, 2006. **50**(6): p. 2009-15.

[17] Ballester, F., F.J. Pastor, and J. Guarro, Ballester F, Pastor FJ, Guarro J. In vitro activities of combinations of amphotericin B, posaconazole and four other agents against *Rhizopus*. *J Antimicrob Chemother*, 2008. **61**(3): p. 755-7.

[18] Perkhofer, S., et al., Posaconazole enhances the activity of amphotericin B against hyphae of zygomycetes in vitro. *Antimicrob Agents Chemother.*, 2008. **52**(7): p. 2636-8.

[19] Walsh, T.J., E.J. Anaissie, and D.W. Denning, Treatment of aspergillosis: clinical practice guidelines of the Infectious Diseases Society of America. *Clin Infect Dis*, 2008. **46**: p. 327.

[20] Upton, A., K.A. Kirby, and P. Carpenter, Invasive aspergillosis following hematopoietic cell transplantation: outcomes and prognostic factors associated with mortality. *Clin Infect Dis*, 2007. **44**: p. 531.

[21] Cornely, O.A., J. Maertens, and M. Bresnik, Liposomal amphotericin B as initial therapy for invasive mold infection: a randomized trial comparing a high-loading dose regimen with standard dosing (AmBiLoad trial). *Clin Infect Dis*, 2007. **44**: p. 1289.

[22] Diekema, D.J., S.A. Messer, and R.J. Hollis, Activities of caspofungin, itraconazole, posaconazole, ravuconazole, voriconazole, and amphotericin B against 448 recent clinical isolates of filamentous fungi *J Clin Microbiol* 2003. **41**: p. 3623.

[23] Kuipers, S., et al., Failure of Posaconazole Therapy in a Renal Transplant Patient with Invasive Aspergillosis Due to *Aspergillus fumigatus* with Attenuated Susceptibility to Posaconazole. *Antimicrob. Agents Chemother*, 2011. **55**(7): p. 3564–3566.

[24] Robin, C., A. Alanio, and C. Cordonnier, Mucormycosis: a new concern in the transplant ward? *Curr Opin Hematol*, 2014 Nov. **21**(6): p. 482-90.

[25] Skiada, A. and G. Petrikos, Cutaneous mucormycosis. *Skinmed*, 2013 May-Jun. **11**(3): p. 155-9.

[26] Godara, S.M., et al., Mucormycosis in renal transplant recipients: predictors and outcome. *Saudi J Kidney Dis Transpl*, 2011 Jul. **22**(4): p. 751-6.

[27] Segal, E., J.M.J. Menhusen, and S. Simmons, Hyperbaric Oxygen in the Treatment of Invasive Fungal Infections:A Single-Center Experience. IMAJ, 2007. **9**: p. 355-7.