



International Journal of Sciences: Basic and Applied Research (IJSBAR)

ISSN 2307-4531
(Print & Online)

<http://gssrr.org/index.php?journal=JournalOfBasicAndApplied>



Accurate Determination of the Sites of the Distal Hole of the Humeral Interlocking Intramedullary Nail Using Monofilament Solid Core Optical Fiber

Bassem Darwish^{a*}, Abdelmoez Lotfy^b, Sameh Younes^c

^a M.D., Orthopedic consultant & head of the orthopedic department, Al-Rafie hospital, Holly Makkah, postal code: 21955, Saudi Arabia

^{b,c} M.D., Orthopedic consultant, Al-Helal hospital, Cairo, Egypt.

^a Email: bassem-darwish@live.com

Abstract

This prospective study was conducted in order to evaluate the results of using the monofilament solid core optical fiber for the accurate determination of the site of the distal hole of the humeral interlocking intramedullary nail. Seven patients with fresh humeral fractures treated with humeral interlocking intramedullary nailing from April 2005 to May 2007 were evaluated. The minimum follow-up period was 12 months. We analyzed type of humeral fracture, time of technique, length of the incision, and Radiation exposure. All cases were treated with one distal locking screw during interlocking intramedullary nailing. The technique is based on the semitransparency of the bone tissue. The system is composed of 2 parts: light source and monofilament solid core optical fiber. Description of the technique: After reduction of the fracture and assembly of the nail, a mechanical measure is taken to determine the expected site of the distal locking holes of the interlocking nail and site of skin incision, then a longitudinal skin incision is made and the soft tissue is dissected until the bone is reached, then the optical fiber is introduced until its tip reaches the distal hole and adjusted to concentrate the light on the nail hole.

* Corresponding author.

E-mail address: bassem-darwish@live.com.

At this time an illuminated ellipse appears on the anterior cortex of the bone. The drill bit is adjusted to the center of this ellipse then the drilling is started. After piercing of the nearby cortex a 3.5 mm suction handle is introduced in the bone hole to suck the blood then physical and mechanical checks are done after which the far cortex is drilled. The results show that the site of the distal hole of the humeral interlocking intramedullary nail could be detected successfully in all cases with no radiation exposure. As a conclusion; we can say that Monofilament solid core optical fiber can be used successfully for the accurate determination of the site of the distal hole of the humeral interlocking intramedullary nail. For satisfactory results, accurate technique and experience of the operator were required.

Keywords: humerus; fracture; interlocking intramedullary nail; distal hole; optical fiber

1. Introduction

The enthusiasm for closed intramedullary nailing, the problems of distal locking, and the need to avoid irradiation aroused the imagination of surgeons and engineers world-wide.

A target device mounted on the image intensifier was devised by Lafforgue and Grosse. Its use minimizes the amount of irradiation exposure to the operating team and allows distal locking, even with bent and twisted nails, but it needs an experienced X-ray technician. Some hand-held, radiolucent targeting devices, like Pennig's and Biomet's, are designed for "universal" use, but have not achieved wide acceptance.

Some mechanical devices were tested but never reached the market others are in full use. Parallel to these investigations, efforts were also applied in other directions. Why not design nails with distal fixation capability but without the need for screws? Some systems, with poor control of the fracture or problems related to insertion or removal, never had great acceptance, while others are widely used. Examples of various techniques for distal locking nail, a modified Küntscher nail with distal fixation by means of "wings" deployed from within through a slot in each side of the nail a system first described by the author in [1], Seidel's humeral and Lefèvre's radial nails - with a distal locking system via the expansion of fins by an internal screw driven by a long screwdriver inserted in the proximal end of the nail. More recently, the inflatable nail (Fixion) - in which the nail self-locks to the cortices by expansion, making any type of interlocking unnecessary - claims good results; but it is expensive and data are still insufficient [2].

With closed nails with high bending and torsional rigidity, the practical use of mechanical jigs for distal locking becomes possible despite the risk for slight bending that can occur during insertion which needs small adjustments of the jig. These are not one-piece jigs. Instead their design allows some movement to find the distal nail holes intraoperatively, even without the use of an image intensifier.

Free hand technique remains the most popular method for distal interlocking screw insertion but recent studies have shown that surgeons operating 12 inches(30.5 cm) from the beam (such as would be required with the free hand placement of interlocking screws) receive significant radiation exposure, the highest of any in the operating staff. In addition, although some theorize that threshold limits are required to induce radiation associated problems, nonthreshold theory advocates suggest that each dose of radiation carries a

risk. Although radiation dose and effect curves and the presence or lack of threshold are controversial, radiation exposure should be decreased when possible.

The average total fluoroscopy time for femoral nailing with distal locking screws using free hand technique ranges from 6.3 minutes and 14.8 minutes, 31-57% of which was for distal locking screws insertion using the free hand technique [3].

The average total fluoroscopy time for tibial nailing with distal locking screws using free hand technique ranges from 3.4 minutes and 6 minutes, 45-53% of which was for distal locking screws insertion using the free hand technique [4].

It is obvious that placement of distal interlocking screws accounted for the greatest percentage of total fluoroscopy time in different studies [3].

This prospective study was conducted in order to evaluate the results of using the monofilament solid core optical fiber for the accurate determination of the site of the distal hole of the humeral interlocking intramedullary nail with the resultant reduction of radiation exposure.

2. Material & Method

This study was conducted in the period from April 2005 to May 2007. It is a prospective multi-center study on the accurate determination of the sites of the distal holes of the humeral interlocking intramedullary nails using monofilament solid core optical fiber; 7 patients who had different types of fresh fractures of the humerus were treated by humeral interlocking intramedullary nail using this technique

Total number of patients: 7 patients

Patients' distribution according to age:

Age range: from 20 years to 74 years

Mean age: 33.71 years

Patient distribution according to sex:-

5 male (71.4%)

2 female (28.5%)

All cases (7 cases) were recent closed fractures:

5 non comminuted fractures (4 Rt. & 1 Lt)

2 comminuted fractures (1 Rt. & 1 Lt)

Type of nail used:-

7 Russel Taylor interlocking intramedullary humeral nail (Smith & Nephew production)

2.1. Method

The accurate determination of the sites of the distal holes of the humeral interlocking intramedullary nail using monofilament solid core optical fiber is based on the ability of the light to pass through bone tissue (bone tissue

is semitransparent).

The system is composed of 2 parts:

(1) Light source:

It is a xenon light source, 150 watt, with an ordinary electric circuit, and light concentration system composed of 3 convex lenses. The light source could be used for other purposes like arthroscopy and microscopy but the light sources of these systems could not be used for our technique because the optical fiber cable we use could not withstand temperature more than 80 °c. The expected life span of the light source is about 7000 working hours. see Figure 1& 2.



Figure 1: front view of the light source



Figure 2: light exit and intensity control unit of the light source

(2) Monofilament solid core optical fiber:

It is a plastic, monofilament, solid core, optical fiber, 3 mm in diameter, 260 cm long. The spectrophotometric studies of the light transmitted by this type of optical fiber show that it acts as a filter transmitting only visible light spectrum from 400-800 nm, it absorbs the ultraviolet and permits traces of the infrared spectrum. The thermal emission from the tip of the optical fiber is minimal not exceeding 39.9° c. The optical fiber could be of single use or reusable. See Figure 3.

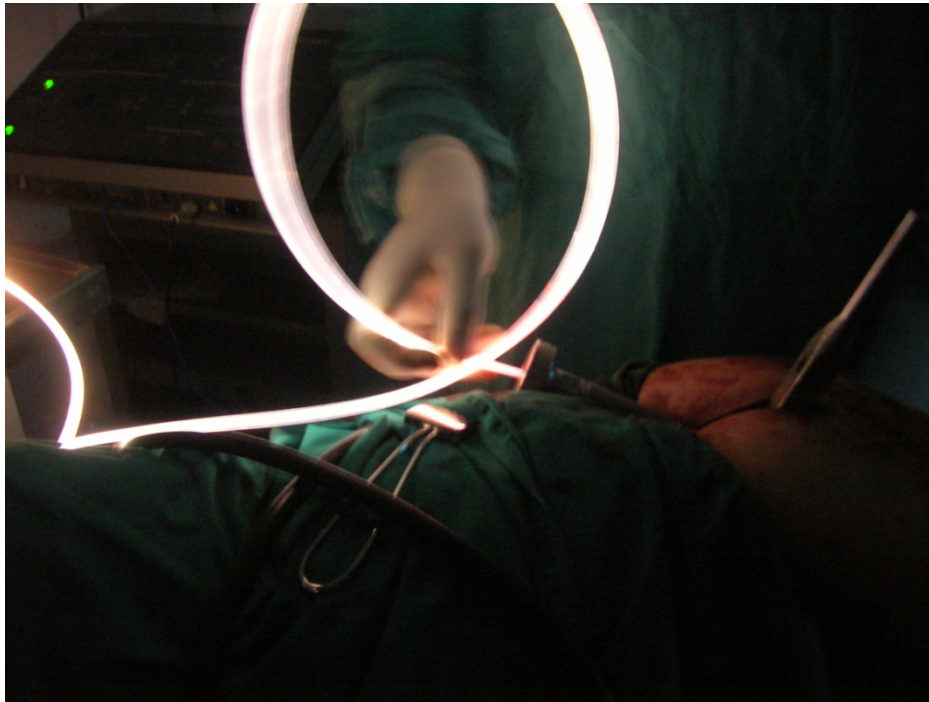


Figure 3: Mono filament solid core optical fiber while connected to light source and introduced inside the nail

Sterilization is done by Ethylene oxide gas chamber or glutaraldehyde oxide (cidex) solution, but heat sterilization is impossible because the cable could not withstand more than 80 °c and the cable could not withstand ionized radiation sterilization also.

Usually, optical fiber transmit light parallel to its long axis but we have modified our optical fiber so that the light exit of the optical fiber transmits light perpendicular to its long axis so light will be concentrated on the interlocking intramedullary nail hole and could pass through the anterior cortex of the bone.

2. 2. Description of the technique:-

(According to Patent number 22644, Egyptian patent office) [5] Figure 4.

After reduction of the fracture and assembly of the nail, a mechanical measure is taken to determine the expected site of the distal locking holes of the interlocking intramedullary nail.

A longitudinal single incision is done using the mechanical measure then the soft tissue is dissected until the bone is reached and the periostium is incised and 2 bone levers are applied. . See Figure 5.



Figure 4: Official extract of patent number 22644, Egytian patent office.

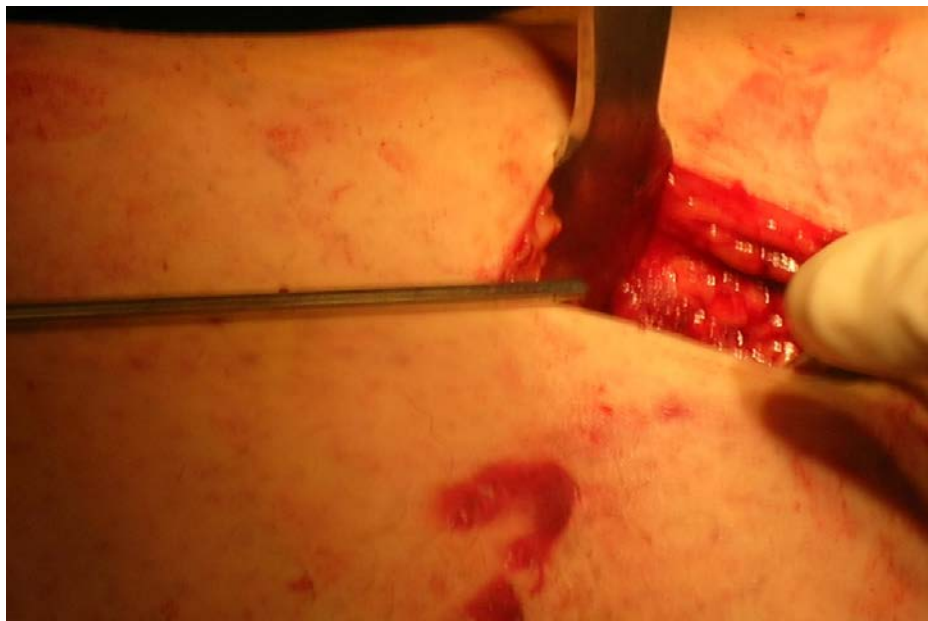

Figure 5: incision of skin over the distal part of the arm according to the mechanical mark

A mark over the supposed site of the nail distal locking hole is taken on the bone by the diathermy or by a straight awel midway between the medial and lateral borders of the humerus. See Figure 6.

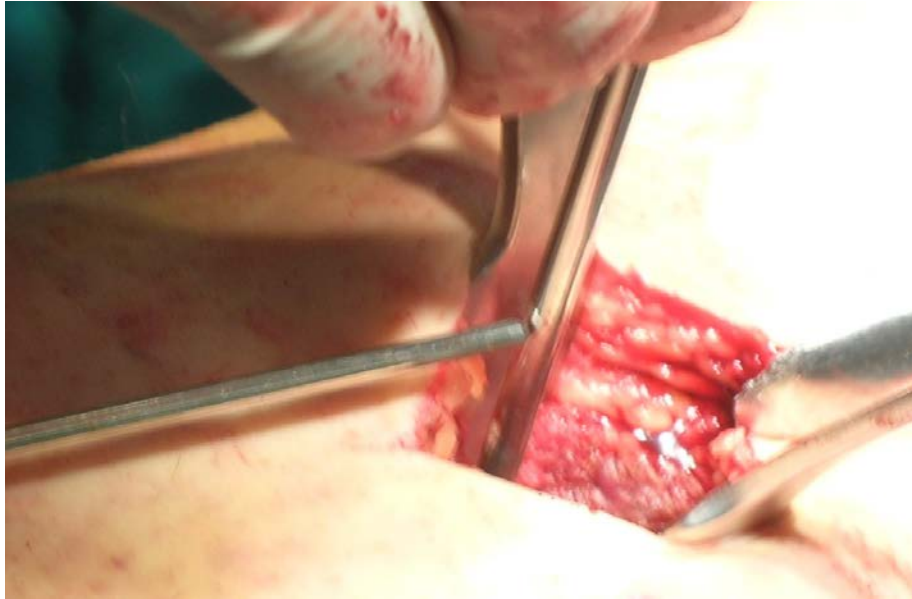

Figure 6: exposure of the distal part of the humerus and taking a mechanical mark over the bone

During the skin marking and dissection a negative pressure is applied to the hollow of the bolt by the suction tube to withdraw any blood from the interior of the nail then the optical fiber is introduced inside the nail and pushed until its tip reaches the distal hole and the optical fiber is adjusted in such a way that the concavity of the optical fiber faces the locking surface of the bone to concentrate the light on the nail hole. At this time an illuminated ellipse appears on the anterior cortex of the bone. See Figure 7.

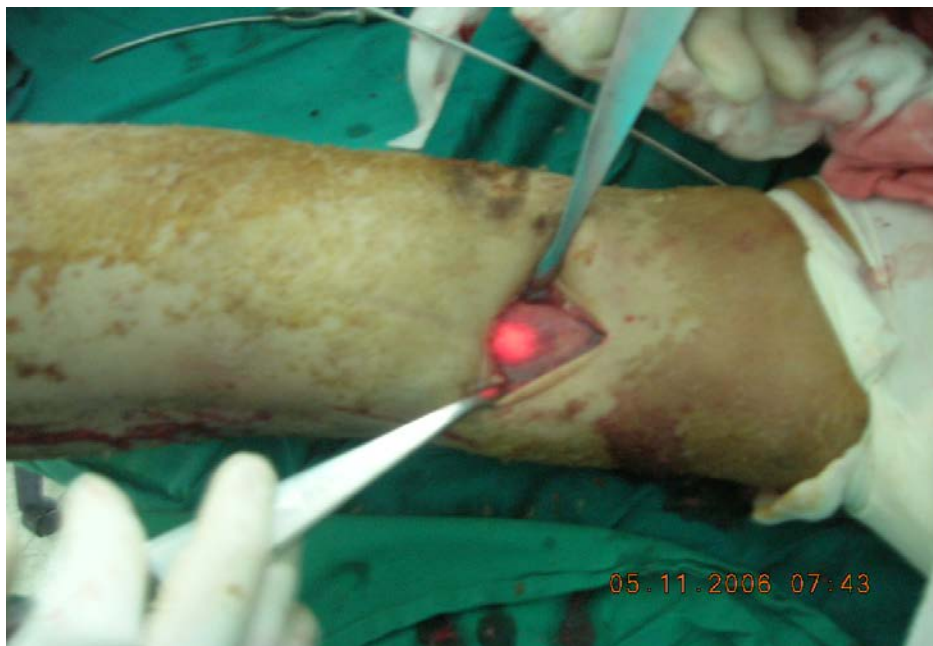


Figure 7: The illuminated anterior cortex of the humerus over the site of the distal locking hole

The drill bit is adjusted to the center of this ellipse and the drill is perpendicular to the introduction handle of the nail in both coronal and sagittal planes then the drilling is started. Before the surgeon feels that the bone is going to be pierced the optical fiber is withdrawn for 0.5 cm to avoid destruction of its tip by the drill bit. After piercing of the nearby cortex a 3.5 mm suction handle is introduced in the bone hole to suck the blood after which the whitish xenon light appears evidently through the bone hole (physical check). See Figure 8.

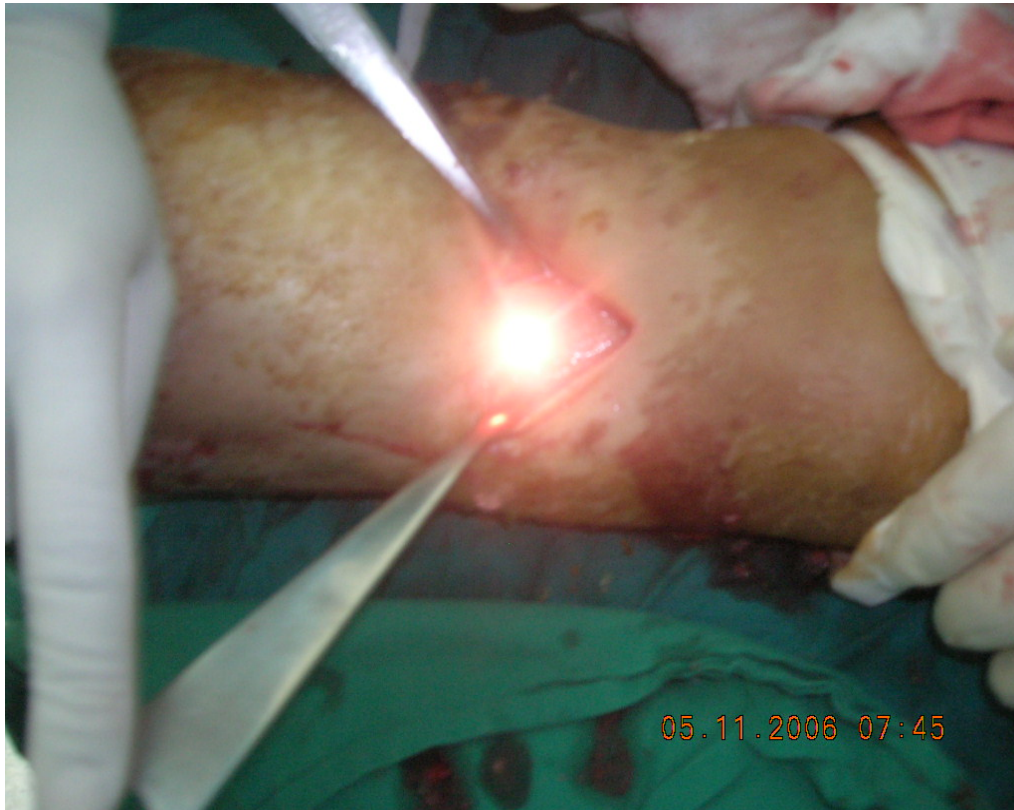

Figure 8: the site of the distal locking hole of the interlocking intramedullary humeral nail after drilling the anterior cortex and suction of the blood (the physical check)

Another check (mechanical) could be done by introducing the depth gauge into the bone hole then the optical fiber is withdrawn and introduced alternatively, when the depth gauge move there is no doubt that the depth gauge is inside the nearby hole of the nail and the bone hole is in the right point. See Figure 9.

After doing the 2 checks successfully the far cortex (posterior cortex) is drilled.

If the illuminated ellipse does not appear (either due to eccentricity of the nail in the medulla far away from the locking surface, thick opaque cortex, inadequate reaming, and inability to dime the operation room to make contrast for the light) the drill bit is adjusted to the mechanical mark over the bone and after drilling the nearby cortex and suction the optical fiber is introduced where the light could be detected through the bone hole and according to the position of the light, the hole could be adjusted in such a way that it is over the locking hole of the nail in this series I have find that the mistake rate of the mechanical mark does not exceed 3-4 mm. After finishing the distal hole the locking screw is inserted.

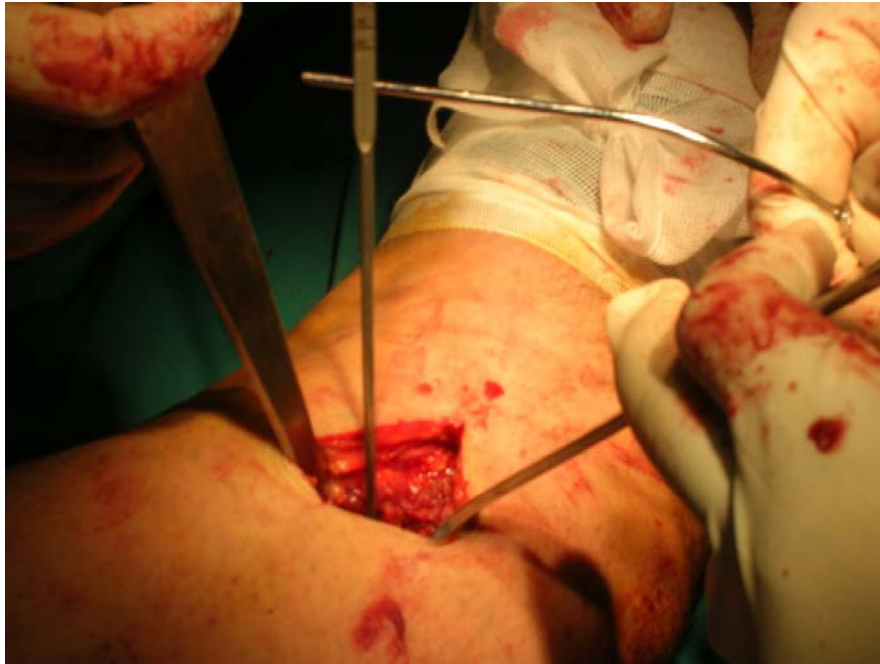

Figure 9: introduction of the depth gauge inside the drilled hole in the anterior cortex of the humerus and its motion when it is hit by the tip of the optical fiber which is moved forward and backward inside the nail (the mechanical check)

3. Results

Time of technique: 3-10 minutes

Mean time of the technique per surgery: 5.85 minutes

Length of incision range from: 3-3.5 cm

Mean incision length: 3.07cm

Radiation exposure: 0 second

Mean radiation exposure: 0 second / surgery

This study is a prospective multi-center study, on a new technique for the accurate determination of the sites of

The distal holes of the interlocking intramedullary nail using monofilament solid core optical fiber, conducted in the period from April 2005 to May 2007. See Table 1.

It is a prospective multi-center study; 7 patients who had different types of fresh fractures of humerus were treated by humeral interlocking intramedullary nail using this technique.

The image intensifier has not been used in any case except for the last confirmatory shot.

Table 1: The distal holes of the interlocking intramedullary nail using monofilament solid core optical fiber, conducted in the period from April 2005 to May 2007

Se	H. No	Sex	Age	Hospital Name	Diagnosis	Operation	Nail	T	Incision	X-ray
1	48880	Male	22	Electricity H.	# P 1/3 L.t humerus	IL L.t humerus	R.T	4	3	0
2	100213944	Male	20	Ain-Shams S.H	C # M R.t humerus	IL R.t humerus	R.T	3	3	0
3	25367	Female	35	Al-Gomhoria H.	C # M L.t humerus	IL R.t humerus	R.T	4	3	0
4	100226617	Male	33	Ain-Shams S.H	# D 1/3 L.t humerus	IL L.t humerus	R.T	4	3	0
5	100269036	Male	74	Ain-Shams S.H	# L.t humerus	IL L.t humerus	R.T	6	3	0
6	7850	Male	25	Agouza Po.H	# R.t humerus	IL R.t humerus	R.T	10	3	0
7	16907	Female	27	Cairo S.H	# L.t humerus	IL L.t humerus	R.T	10	3.5	0

Table 1: details of the prospective multicenter study

Table 1 Abbreviations:

H.No: hospital number

H.: hospital

SH: specialized hospital

Po: Police

#: fracture

P: proximal

D: distal

C: comminuted

Rt. : right

Lt. : left

IL: interlocking

RT: Russel Taylor

T: time of the technique application in minutes

incision: length of the skin incision in cm

X-ray: X-ray exposure in seconds

4. Discussion

The problems of the mechanical target device are either related to design of the jigs themselves and these are usually fully corrected. Others are related to practice of the surgeon so the following items should be taken into consideration;

-The surgeon must ensure tight fit between the nail-holding device and the end of the jig.

-The surgeon must begin with the proximal screw, leave the sleeve in situ, and then proceed to the next one because the greater the distance between the connection point and the screw holes, the easier the miss can

occur.

-The surgeon must release the tension of the soft tissue to avoid displacement of the guide sleeve medially or laterally and some companies recommend a single incision 4-5 cm in length.

-The surgeon must use "pilot-tipped" drill which makes a small puncture on the bone before the helix of the drill completes the perforation, and without pushing too hard, so it can find its own way through the bone and the holes particularly if the position of the screws is going to fall on a more arched surface of the bone that can cause the drill to slide over that surface.

- The surgeon must ream the medulla in a manner such that the nail enters the medullary canal easily, thus avoiding unnecessary stresses to the bone and making the use of a jig more warranted (endosteal fit that was necessary in Küntscher's technique is dispensable, because control of the fracture is achieved by proximal and distal screws).

Free hand technique remains the most popular method for distal interlocking screw insertion but recent studies have shown that surgeons operating 30.5 cm from the beam (such as would be required with the free hand placement of interlocking screws) receive significant radiation exposure, the highest of any in the operating staff. In addition, although some theorize that threshold limits are required to induce radiation associated problems, nonthreshold theory advocates suggest that each dose of radiation carries a risk. Although radiation dose and effect curves and the presence or lack of threshold are controversial, radiation exposure should be decreased when possible.

The average total fluoroscopy time for femoral nailing with distal locking screws using free hand technique ranges from 6.3 minutes and 14.8 minutes, 31-57% of which was for distal locking screws insertion using the free hand technique.

The average total fluoroscopy time for tibial nailing with distal locking screws using free hand technique ranges from 3.4 minutes and 6 minutes, 45-53% of which was for distal locking screws insertion using the free hand technique.

It is obvious that placement of distal interlocking screws accounted for the greatest percentage of total fluoroscopy time in different studies.

This study is a prospective multi-center study, on a new technique for the accurate determination of the sites of the distal holes of the humeral interlocking intramedullary nail using monofilament solid core optical fiber, conducted in the period from April 2005 to May 2007.

It is a prospective multi-center study; 7 patients who had different types of fresh fractures of humerus were treated by humeral interlocking intramedullary nails using this technique.

Time of technique: 3-10 minutes

Mean time of the technique per surgery: 5.85 minutes

Length of incision range from: 3-3.5 cm

Mean incision length: 3.07cm

Radiation exposure: 0 second

Mean radiation exposure: 0 second / surgery

The image intensifier has not been used in any case and some cases have been operated upon in hospitals having no image intensifier at all or their image intensifier is not working.

5. Conclusion

The results of this study show that the distal locking screws can be placed accurately using monofilament solid core optical fiber with no need for image intensifier and if the surgeon is going to do an open reduction and to use templates to determine diameter and length of the interlocking nail preoperatively, there will be no need for image intensifier at all.

As regard cost efficiency the optical fiber technique success rate is nearly 100% and its cost is much lower than the cost of the Navigator, image intensifier or mechanical target device.

Acknowledgment

We would like to express our appreciation to Prof. Mohamed Abdel Harith, vice dean of the national institute of laser in Cairo & Prof. Arafa Kamal Qasem, national institute of laser in Cairo.

References

- [1] De Camargo FP : Osteosfítese intramedular de Kuntscher: Contribuição à técnica e estudo crítico baseado em 240 casos. São Paulo1952.
- [2] Lepore L, Lepore S, Maffuly N: "Intramedullary nailing of the femur with an inflatable self-locking nail: comparison with locked nailing." J Orthop Sci, vol. 8(6), pp. 796-801, 2003.
- [3] Christian Krettek, Bernd Könemann, Theodore Miclau, Reto Kölbl, Thomas Machreich, and Harald Tscherne: "A Mechanical Distal Aiming Device for distal Locking in Femoral Nails." Clinical Orthopaedics and related research, vol. 364, pp. 256-275, 1999.
- [4] Christian Krettek, Bernd Könemann, Osama Farouk, Theodore Miclau, Alexander Kromm, and Harald Tscherne: "Experimental Study of Distal Interlocking of a Solid Tibial Nail: Radiation – Independent Distal Aiming Device (DAD) Versus Freehand Technique(FHT)." J Orthop Trauma, vol. 12(6), pp. 373-378, 1998.
- [5] Bassem Darwish "The use of the fiberoptics as an aiming method for the distal locking screws of the interlocking nail." Egypt Patent 22644, July 31, 2000.