



International Journal of Sciences: Basic and Applied Research (IJSBAR)

ISSN 2307-4531
(Print & Online)

<http://gssrr.org/index.php?journal=JournalOfBasicAndApplied>



Challenges in the Perioperative Localization in Secondary Hyperparathyroidism, a Case Report

Haj Hamad M^a, Suhaimi S^{b*}, Latar N^c, Aini A^d, Rohaizak M^e

^{a,b,c,e} *Endocrine and Breast Surgery Unit, Department of Surgery, UKM Medical Center, JalanYaacobLatif, Bandar TunRazak, Cheras, 56000, Kuala Lumpur, Malaysia.*

^d *Nuclear Medicine Unit, Department of Radiology, UKM Medical Center, JalanYaacobLatif, Bandar TunRazak, Cheras, 56000, Kuala Lumpur, Malaysia.*

^a *email: hahamad@hotmail.com*

^b *email: shahrn72.sn@gmail.com*

Abstract

To detect hyperfunctioning glands, noninvasive procedures such as ultrasound, sestamibi scan, and magnetic resonance imaging (MRI) are widely available. Preoperative localization studies give important information and enable unilateral exploration or minimal invasive parathyroidectomy. Localization studies and parathyroid hormone assays have not clearly modified the conventional surgical approach of the disease. Controversy regarding the surgery to be favored, between subtotal parathyroidectomy and total parathyroidectomy with autotransplantation, continues against the background of relevant recurrence rates, persistent SHPT, and markedly increased complication rates in reoperation. We are presenting a case of 54-year-old male, on regular hemodialysis (HD) referred by his nephrologist for symptomatic hyperphosphatemia and osteoporosis. Phosphate binders and vitamin D failed to control the disease. Patient underwent neck exploration aiming for total parathyroidectomy, but during surgery we were able to find only the left inferior parathyroid gland. For the few months after the surgery, patient phosphate, iPTH and alkaline phosphatase still deranged. So, the decision was made to do preoperative localization study to confirm the presence and location of the remaining 3 parathyroid gland before re-exploration of the neck. Ultrasonography, computerized tomography of the neck and thorax as well as sestamibi scan done. The results were inconclusive.

* Corresponding author.

E-mail address: shahrn72.sn@gmail.com.

Re-exploration was performed only right and left superior parathyroid glands. Still unable to localize right inferior gland. Postoperatively, biochemical derangement started to improve slowly. In conclusion; we can say that Noninvasive methods, such as ultrasound, sestamibi scan or MRI, are not always successful in localizing the hyperfunctioning parathyroid gland. Selective venous sampling (SVS) of PTH is an invasive method of localization that is used only rarely in comparison to noninvasive methods. Ultrasonography is an important, cost-effective diagnostic tool that is frequently used in combination with a sestamibi scan.

Keywords: Secondary hyperparathyroidism; localization; neck exploration; parathyroidectomy.

1. Introduction

Hyperparathyroidism (HPT) is a clinical problem resulting in elevated levels of serum parathyroid hormone, and elevated levels of serum and urine calcium. Renal hyperparathyroidism, including secondary and tertiary forms, can be caused by renal failure. Supernumerary parathyroid glands in renal hyperparathyroidism are described in about 30% of the operated cases [1].

To detect hyperfunctioning glands, noninvasive procedures such as ultrasound, sestamibi scan, and magnetic resonance imaging (MRI) are widely available. Preoperative localization studies give important information and enable unilateral exploration or minimal invasive parathyroidectomy [2].

Localization studies and parathyroid hormone assays have not clearly modified the conventional surgical approach of the disease. Controversy regarding the surgery to be favored, between subtotal parathyroidectomy and total parathyroidectomy with autotransplantation, continues against the background of relevant recurrence rates, persistent SHPT, and markedly increased complication rates in reoperation [3].

Localization diagnosis often is considered unnecessary in secondary and 3HPT because patients will undergo a bilateral neck exploration. However, the treatment of SHPT consists of the removal of all hyperfunctioning parathyroid tissue; knowing that 15% of patients who receive continuous dialysis have an increased incidence of supernumerary (fifth or sixth) and ectopic glands, and aside from the fact that successful surgery will mainly depend on the availability of a highly skilled surgeons experienced in parathyroid surgery, clinicians are using more of these new localizations studies with improved accuracy to decrease the risk of missing some hyperfunctioning glands [4].

Localization options includes ultrasonography, screening and follow-up contribute to indication for surgery by estimating the size of enlarged glands. It has a reported sensitivity of 45-70%.^[3] CT and MRI Indicated when large glands are not found by US. Superior mediastinum, behind the trachea or esophagus or deep in the neck. Scintigraphy is a more accurate method. Its sensitivity with thallium and technetium is only 75-80% [5].

¹²³I/^{99m}Tc-Sestamibi subtraction with single photon- emission computed tomography (SPECT) have sensitivity up to 95% when double tracer ^{99m}Tc-pertechnetate/tetrofosmin and SPECT are combined. The sensitivity of sestamibiscintigraphy ranges from 64% to 88% for a single adenoma, but is just 44% for hyperplasia and 30% for double adenoma; the rate of false positives is about 15% [6].

For Intra-operative localization: intravenous iPTH sampling, but it's invasive and require rapid PTH assay. Also, intraoperative techniques (US, gamma-camera) also can be used [7].

2. Case summary

We are presenting a case of 54-year-old male, who had been on regular hemodialysis (HD) for more than 9 years for his ESRF. He was referred by his nephrologist for symptomatic Hyperphosphatemia, as he has generalized bone pain. Phosphate binders and vitamin D failed to control the disease. At time of presentation, there was evidence of bone turnover, with elevated alkaline phosphatase 365 U/L (normal 32 – 104 U/L) and generalized osteoporosis diagnosed by skeletal survey. His intact parathyroid hormone iPTH was 114.0 pmol/L (normal 1.3 - 7.6 pmol/L). Patient underwent neck exploration aiming for total parathyroidectomy, but during surgery we were able to find only the left inferior parathyroid gland, which was confirmed by histological examination later on. For the few months after the surgery, patient phosphate, iPTH and alkaline phosphatase still deranged. So, the decision was made to do preoperative localization study to confirm the presence and location of the remaining 3 parathyroid gland before re-exploration of the neck. Ultrasonography, computerized tomography of the neck and thorax as well as sestamibi scan done. The results were not concomitant to each other (Figure 1).

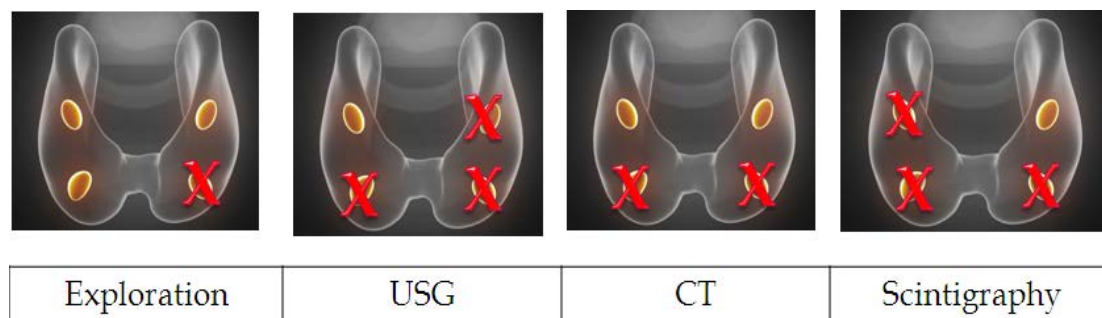


Fig. 1. Summary of preoperative localization studies.

In view of persistent biochemical derangement, despite inconclusive preoperative localization studies, a re-exploration was performed, during which we was able to identify and remove both right and left superior parathyroid glands. Still unable to localize right inferior gland. However, iatrogenic injury to the left recurrent laryngeal nerve occurred. Postoperatively, biochemical derangement started to improve slowly.

3. Discussion

Parathyroidectomy is unsuccessful in 10–30% of uraemic patients operated on for secondary hyperparathyroidism. The main cause of surgical failure is incomplete identification of all parathyroid tissue. The total rate of surgical failure is much higher than that reported for primary hyperparathyroidism, which is less than 8% in experienced hands. Surgical morbidity and mortality rates are also higher in patients with renal failure than in patients operated on for primary hyperparathyroidism [1].

Few surgeons believe that preoperative imaging can improve the success rate of first surgery in uraemic patients, in whom all parathyroid glands should be searched for. A few investigators have routinely combined computed tomography, thallium-201 scanning, and ultrasonography, but the sensitivity for enlarged parathyroid glands was only 70% [8].

In renal HPT, parathyroidectomy may reduce bone pain and pruritus. In pHPT, bilateral neck exploration is associated with a cure rate in greater than 95% of patients, depending largely on the experience of the surgeon. Despite intraoperative measurement of intact parathyroid hormone (PTH) and excellent surgical results in experienced centers, there are still a certain number of patients who will require reoperation due to persistent or recurrent HPT after primary surgery [9].

These operations are technically challenging due to distortion and scarring in tissue planes after previous cervical operation, with a markedly higher complication rate and risk for injury of the recurrent laryngeal nerve. Localizing the remaining hyperfunctioning parathyroid glands in patients with previous cervical operations is helpful in minimizing surgical effort and complication rates during reoperation.

4. Conclusion

However, noninvasive methods, such as ultrasound, sestamibi scan or MRI, are not always successful in localizing the hyperfunctioning parathyroid gland. Selective venous sampling (SVS) of PTH is an invasive method of localization that is used only rarely in comparison to noninvasive methods. Ultrasonography is an important, cost-effective diagnostic tool that is frequently used in combination with a sestamibi scan.

References

- [1] ElifHindie, Pablo Urena, Christian Jeanguillaume, Didier Melliere, Jean-Michel Berthelot et al. “Preoperative imaging of parathyroid glands with technetium- 99m-labelled sestamibi and iodine-123 subtraction scanning in secondary hyperparathyroidism”. *Lancet*, vol. 353, pp. 2200 – 04. 1999
- [2] Parfitt AM. “The hyperparathyroidism of chronic renal failure: a disorder of growth”. *Kidney Int*vol.5, pp.3 – 9 . 1997
- [3] Thierry Defechereux and Michel Meurisse. « Renal hyperparathyroidism: Current therapeutic approaches and future directions”. *Operative Techniques in Otolaryngology*. Vol. 20, pp. 71-78. 2009.
- [4] Youssef Y, Richards WO, Sekhar N, Kaiser J, Spagnoli A, Abumrad N, Torquati A.” Risk of secondary hyperparathyroidism after laparoscopic gastric bypass surgery in obese women. *SurgEndosc*. Vol. 21, pp. 1393-6. Feb 2007
- [5] Cunningham J, Locatelli F, Rodriguez M.” Secondary hyperparathyroidism: pathogenesis, disease progression, and therapeutic options.” *Clin J Am SocNephrol*. Vol. 6, pp. 913-21. Mar 2011.
- [6] Prades JM, Gavid M, Timoshenko AT, Richard C, Martin C. “Endoscopic surgery of the parathyroid glands: methods and principles.” *Eur Ann Otorhinolaryngol Head Neck Dis*. Vol. 130, pp. 157-60. Apr 2013
- [7] Mariani G, Gulec SA, Rubello D, Boni G, Puccini M. “Preoperative localization and radioguided

parathyroid surgery.” *J Nucl Med*. Vol. 44, pp. 1443-58. Sep 2003

[8] Charles Brunnicardi, E. DeBakey Dana K. Andersen,.”*Scwartz’s manual of surgery*”. 8th edition. McGraw Hill. International edition.2009.

[9] Takagi H, Tominaga Y, Uchida K, Yamada N, Kawai M. “Evaluation of image-diagnosing methods of enlarged parathyroid glands in chronic renal failure.” *World J Surg*. Vol. 10, pp. 605-11