



International Journal of Sciences: Basic and Applied Research (IJSBAR)

ISSN 2307-4531
(Print & Online)

<http://gssrr.org/index.php?journal=JournalOfBasicAndApplied>



The Protective Effects of *Urtica Dioica* against CCl₄ Induced Hepatotoxicity in Rats

Lubna Naz^{a*}, Tabassum Mahboob^b

^a Assistant Professor, Department of Physiology, University of Karachi, Karachi, Pakistan

^b Department of Biochemistry, University of Karachi, Karachi, Pakistan

^aEmail: lunasaf@yahoo.com

^bEmail: tab60@hotmail.com

Abstract

The present study was designed to investigate the preventing effects of *Urtica dioica* (UD) against liver fibrosis and cirrhosis induced by carbon tetrachloride in male wistar rats. Cirrhosis is the final stage of chronic liver disease and leading cause of death worldwide. *Urtica dioica* is a medicinal plant with anti-inflammatory, anti-allergic and anti-carcinogenic activities. The healthy age matched male wistar albino rats were used in the study. In this study 24 male albino wistar rats were divided in to four groups (n=6). Group I remained healthy control rats, group II, received CCl₄ (0.8 ml/Kg b.w, s.c, for 8 weeks, twice a week), group III received CCl₄ (0.8 ml/Kg b.w, s.c, for 8 weeks, twice a week) together with UD(2 ml/kg UD extract i.p daily for 8 weeks), group IV received UD(2 ml/kg UD extract i.p daily for 8 weeks). Biochemical analysis included total bilirubin, liver enzymes, antioxidant enzymes & MDA. The sixty day treatment of rats with CCl₄ induced hepatotoxicity as indicated by enhanced liver enzymes, lipid peroxidation and decreased antioxidant enzyme levels in CCl₄ treated group compared with the control group. *Urtica Dioica* treatment for sixty days decreased hepatotoxic effects of CCl₄ by significantly reducing the elevated liver enzyme, lipid peroxidation and raised the decreased antioxidant levels. The body weights of Group II, III & IV groups were reduced whereas maintained in group I.

* Corresponding author.

E-mail address: lunasaf@yahoo.com.

The histologic findings indicated portal and periportal fibrosis in CCl₄ treated rats with 40% degenerative hepatocytes whereas UD treatment together with CCl₄ indicated slight periportal fibrosis, fatty changes with no degenerative hepatocytes.

Keywords: : *Urtica dioica*; hepatotoxicity; CCl₄; cirrhosis; antioxidant

1. Introduction

Urtica Dioica (UD) or common nettle is a perennial herbaceous plant well known for stinging hair and belongs to family Urticaceae. It is abundant in northern Europe and much of Asia. *Urtica Dioica* is divided into six sub species almost with trichomes on the stem and leaves. Plant is consumed as a source of food, fiber and medicines in many countries especially in Turkey and China. Different parts of plant have been used traditionally for the treatment of arthritis, eczema, hemorrhoids, hyperthyroidism, bronchitis and cancer [1] Disorders of kidneys, urinary tract, GIT, locomotors system, CVS, Hemorrhage, flu, rheumatism and gout [2] A number of products such as steroids, terpenoids, and lectins and seven flavanol glycosides (Kaempferol-3-O-glucoside and -3-O-rutinoside; quercetin -3-O-glucoside, and -3-O-rutinoside, isorhamnetin-3-O-glucoside, -3-O-rutinoside and -3-Oneohesperidoside) have been isolated from different parts of plant. Various immunostimulatory, anti-carcinogenic, anti-inflammatory, antioxidant and anti-allergic properties of Flavonoid glycoside have been reported [3] Herbal Extracts of *Urtica dioica* are used as laxative, diuretic, and vermifuge conventionally in some countries. It is also used in antidandruff shampoo. The active ingredients of nettle leaf reduce TNF- α and inflammatory cytokines via inhibiting transcription factor required for the activation of TNF- α and IL-1- β in the synovial tissue that lives the joint therefore used as an adjuvant remedy in arthritis patients [4,5,6] *Urtica Dioica* treatment has also been shown to provide symptomatic relief in benign prostrate hyperplasia [7,8] One of the active components of extract 3,4 divanillyl tetrahydrofuran has been shown to bind with sex hormone binding globulin thereby increasing free T₂ concentration, hence used by many body builders [9].

Liver Cirrhosis is a chief health issue especially in underdeveloped countries with low socio-economic range due to endemic hepatitis viral infections. It is also a major health problem in developed countries due to alcohol consumption. Hepatocytes carcinoma is the 5th most common cancer worldwide [10]. Carbon tetrachloride (CCl₄) has been widely used to experimentally induce liver injury rodents. Carbon tetrachloride is oxidized to the trichloromethyl free radical, which ensures alkylation of proteins and DNA along with lipid peroxidation. Depletion of ATP precedes acute cytotoxicity. Carcinogenicity is observed on long-term, low dose exposure. Hepatic and renal toxicity are due to biotransformation of CCl₄ to toxic metabolites. The toxic metabolites of CCl₄ block formation and release of low-density lipoproteins and deplete hepatic stores of glutathione. In addition, a dramatic increase in calcium concentration occurs in hepatic mitochondria, accompanied by alterations in electrolyte distribution with swelling of hepatic cells and depletion of liver glycogen. Chronic exposure may result in fibrosis or cirrhosis.

Use of herbal therapies have gained a lot of attention during these days and a number of herbs have been identified and used traditionally in different localities. Therefore this study was aimed to investigate the

hepatoprotective properties of *Urtica dioica* in the prevention of liver fibrosis and cirrhosis induced by CCl₄ in rats.

2. Materials & Methods

24 male Albino wistar rats weighing 190-250g were purchased from the animal house of ICCBS (International center for chemical and biological sciences, Karachi, Pakistan) for the study. Animals were acclimatized to the laboratory conditions prior to the initiation of the experiment and caged in a quiet temperature controlled animal room (23±4°C). Rats had free access to water and standard rat diet.

2.1 Materials and extraction procedure

UD seeds were purchased from a local herb store of Karachi, Pakistan. The seeds were powdered in a mixer and fixed oil of UD was extracted with the help of a rotary evaporator using diethyl ether as solvent.

2.2 Ethical guidelines

The experiments were conducted with ethical guidelines of institutional ERB (Ethical Review Board) and internationally accepted principles for laboratory use and care in animal research (Health Research Extension Act of 1985)

2.3 Study design

The rats were randomly divided in to four experimental groups, each of six rats. The experimental phase lasted for 60 days. CCl₄ and other chemicals used in the present study were purchased from BDH laboratory supplies, Fisher Scientific UK limited and Fluka AG.

Group I: Untreated control

Group II: CCl₄ treated

Group III: CCl₄ + UD treated

Group IV: UD treated

Group I served as control and received only 2 mL/kg normal saline solution for 60 days. Group II(CCl₄ treated) & III(CCl₄+UDtreated) received CCl₄, 0.8 ml/kg of body weight, subcutaneously, twice a week for 60 days. Group III (CCl₄ + UD treated) & IV(UD treated) received daily intra-peritoneal injections of 2 mL/kg UD extract for 60 days. At 60th day rats of all groups were decapitated. The blood was collected from the neck wound in the lithium heparin coated tubes and centrifuged to collect plasma. Liver was excised, trimmed of connective tissues, rinsed with saline to eliminate blood contamination, dried by blotting with filter paper and weighed. The tissues then kept in freezer at -70 °C until analysis.

2.4 Assessment of AST, ALT, ALP & Bilirubin

Plasma ALT [11], AST[12], ALP [13] and total and direct bilirubin [14] were analyzed using commercially prepared reagent kits from Randox.

2.5 Preparation of post mitochondrial supernatant

Liver homogenate was prepared by taking 1gm of tissue in 10 ml of 5 mM potassium phosphate buffer (pH 7.8) by using a homogenizer. The homogenates then centrifuged at 800 g for 5minutes at 4°C to separate the nuclear debris. The supernatant so obtained was centrifuged at 10,500g for 20 minutes at 4°C to get post mitochondrial supernatant which was used to assay SOD, Catalase, MDA & glutathione reductase activity.

2.6 Estimation of thiobarbituric acid substances:

The malondialdehyde (MDA) content, a measure of lipid peroxidation, was assayed in in the form of thiobarbituric acid reacting substances (TBARS) by the lipid peroxidation method [15]. Briefly, the reaction mixture consisted of 0.2 ml of 8.1% sodium dodecyl sulphate, 1.5 ml of 20% acetic acid solution adjusted to pH 3.5 with sodium hydroxide and 1.5 ml of 0.8% aqueous solution of thiobarbituric acid was added to 0.2 ml of 10% (w/v) of PMS. The mixture was brought up to 4.0 ml with distilled water and heated at 95°C for 60 minutes. After cooling with tap water, 1.0 ml distilled water and 5.0 ml of the mixture of n-butanol and pyridine (15:1 v/v) was added and centrifuged. The organic layer was taken out and its absorbance was measured at 532 nm and compared with those obtained from MDA standards. The concentration values were calculated from absorption measurements as standard absorption.

2.7 Estimation of catalase:

Catalase activity was assayed by the method of Sinha [16]. Briefly the assay mixture consisted of 1.96 ml phosphate buffer (0.01M, pH 7.0), 1.0 ml hydrogen peroxide (0.2M) and 0.04 ml PMS (10% w/v) in a final volume of 3.0 ml. Then 2 ml dichromate acetic acid reagent was added in 1 ml reaction mixture, boiled for 10 minutes & cooled. Changes in absorbance was recorded at 570nm.

2.8 Estimation of superoxide dismutase:

Superoxide Dismutase Levels in the cell free supernatant were measured by the method of [17]. Briefly 1.3 ml of solution A (0.1 ml EDTA containing 50 mM Na₂CO₃, pH 10.0), 0.5 ml of solution B (90 µM NBT nitro blue tetra zoliumdye) and 0.1 ml of solution C (0.6% Triton X-100 in solution A), 0.1 ml of solution D (20 mM Hydroxylamine hydrochloride, pH6.0) were mixed and the rate of NBT reduction was recorded for one minute at 560 nm. 0.1 ml of the supernatant was added to the test cuvette as well as reference cuvette, which do not contain solution D. Finally, the percentage inhibition in the rate of reduction of NBT was recorded as described above. One enzyme unit was expressed as inverse of the amount of protein (mg) require in one minute.

2.9 Estimation of glutathione reductase:

GSH activity was determined by continuous spectrophotometric rate determination [18]. In a clean glass test tube, 0.3 ml of 10% BSA, 1.5 ml of 50 mM potassium phosphate buffer (pH 7.6), 0.35 ml of 0.8 mM β NADPH and 0.1 ml of 30 mM oxidized glutathione was taken and finally added 0.1 ml of homogenate, mixed well by inversion. Absorbance was recorded at 340 nm at 25°C for 5 minutes on kinetic spectrophotometer PRIM 500 (Germany) with automatic aspiration and thermostat. The activity was calculated using the molar coefficient for NADPH of $6.22 \mu\text{mol}^{-1} \times \text{cm}^{-1}$ and expressed in unit/gram tissue.

2.10 Histopathological examination

Liver tissue samples were fixed with formalin and embedded in paraffin blocks, tissue then sectioned at 4 μ m and stained with eosine and hematoxylin for microscopic examination. The degree of hepatic injury was evaluated from the histologic sections via gradings and numerical scores according to French. [19]

Score 0 = no visible damage

Score 1 = focal hepatocyte damage on less than 25% of the tissue

Score 2 = focal hepatocyte damage on 25-50% of the tissue

Score 3 = extensive, but focal hepatocyte lesion

Score 4 = global hepatocyte necrosis

2.11 Statistical analysis

Results are presented as mean \pm standard deviation. Statistical significance and difference from control and test values were evaluated by Student's t-test. Statistical probability of a= P<0.05, b= P<0.01, c= P<0.001 were considered to be significant.

Table 1: Comparison of body weight, liver weight and relative liver weight in Control, CCl4 treated, CCl4 +Urtica Dioica treated & Urtica Dioica treated groups

	CONTROL (n=6)	CCL4 treated¹ (n=6)	CCl4 + UD^{1,2} (n=6)	UD^{1,2,3} (n=6)
INITIAL BODY WEIGHT	214.66 \pm 4.50925	212.67 \pm 2.5166	209 \pm 3.605	200.33 \pm 0.5774
FINAL BODY WEIGHT	237.33 \pm 11.1505	121.667 \pm 7.63 ^d	186.33 \pm 2.0816 ^{b,c}	191 \pm 3.605 ^{b, c, n}
LIVER WEIGHT	4.85 \pm 0.6403	7.42 \pm 1.4056 ^a	4.4 \pm 0.1 ^{n,a}	5.36 \pm 1.006 ^{n,a,n}

RELATIVE LIVER WEIGHT (G LIVER/100 G BODY)	2.119±0.2444	6.486±1.411 ^b	2.3611±0.0292 ^{b, a}	2.806±0.4946 ^{n, b, n}
---	--------------	--------------------------	-------------------------------	---------------------------------

The data is expressed as mean ± standard deviation.

1= As compared with control

2= As compared with CCl4

3= As compared with CCl4+UD

a= P<0.05, b= P<0.01, c= P<0.001, d=P<0.0001, n= P>0.05(Non-significant)

Table 2: Comparison of serum enzymes & Bilirubin levels in Control, CCl4 treated, CCl4 +Urtica Dioica treated & Urtica Dioica treated groups

	CONTROL (n=6)	CCL4 treated¹ (n=6)	CCl4 + UD^{1, 2} (n=6)	UD^{1, 2, 3} (n=6)
AST (U/l)	8.5±0.212	25.16±5.48 ^c	21.2±12.47 ^{a, n}	13.8±2.03 ^{b, n, n}
ALT (U/l)	17.5±3.27	24.62±3.68 ^b	18.33±4.31 ^{n, a}	10.01±1.73 ^{b, d, b}
ALP (U/l)	290.70±111.43	683.56±219.52 ^b	281.13±87.18 ^{n, b}	295.006± 45.13 ^{n, b, n}
BILIRUBIN (mg/dl)	0.4±0.0967	2.03±0.53 ^c	0.55±0.306 ^{n, b}	1.08±0.38 ^{b, b, a}

The data is expressed as mean ± standard deviation.

1= As compared with control

2= As compared with CCl4

3= As compared with CCl4+UD

a= P<0.05, b= P<0.01, c= P<0.001, n= P>0.05(Non-significant)

Table 3: Comparison of liver antioxidant enzymes and MDA activity in control, CCl4 treated, CCl4 + Urtica Dioica treated & Urtica Dioica treated groups

	CONTROL	CCl4¹	CCl4 + UD^{1,2}	UD^{1,2,3}
Catalase (µmol/g tissue)	17.31±2.18	4.831±0.68 ^b	14.432±9.60 ^{n,b}	9.379±4.13 ^{b,c,n}
SOD (Unit/g tissue)	1.436±0.63	0.422±0.25 ^a	1.473±0.61 ^{n,b}	1.219±0.46 ^{n,b,n}
GSH (Unit/g tissue)	0.811±0.08	0.0214±0.0015 ^d	0.037±0.01 ^{d,a}	0.03±0.005 ^{d,b,n}
MDA (µmol/g tissue)	0.906±0.32	1.710±0.71 ^a	1.35±0.18 ^{a,a}	0.98±0.14 ^{n,a,b}

The data is expressed as mean ± standard deviation.

1= As compared with control

2= As compared with CCl4

3= As compared with CCl4+UD

a= P<0.05, b= P<0.01, c= P<0.001, n= P>0.05(Non-significant)

Table 4: Histopathological features in Control, CCl4 treated, CCl4 +Urtica dioica treated & Urtica dioica treated groups

Histopathological findings	CONTROL	CCl4	CCl4 + UD	UD
<i>Enlargement</i>	0	0	0	0
<i>Paleness</i>	0	0	0	0
<i>Fatty change</i>	0	0	1	0
<i>Hydropic degeneration</i>	0	0	0	0
<i>Portal inflammation</i>	0	2	0	0
<i>Periportal inflammation</i>	0	2	0	0
<i>portal fibrosis</i>	0	2	0	0
<i>Periportal fibrosis</i>	0	2	1	1
<i>Focal lobulitis</i>	0	2	0	0
Total Score	0	10	2	1
<i>Intracellular pigment deposition</i>	<i>absent</i>	<i>present</i>	<i>absent</i>	<i>absent</i>
<i>Sinusoidal expansion</i>	<i>absent</i>	<i>absent</i>	<i>absent</i>	<i>absent</i>
<i>Degenerative hepatocytes</i>	<i>absent</i>	30-40-%	<i>absent</i>	<i>absent</i>
<i>Ballooning degeneration</i>	<i>absent</i>	<i>absent</i>	<i>absent</i>	<i>absent</i>
<i>Bile duct proliferation</i>	<i>absent</i>	<i>absent</i>	<i>present</i>	<i>absent</i>

Degree of hepatic injury is expressed as scores observed via light microscopy. Score 0 = no visible damage; Score 1 = focal hepatocyte damage on less than 25% of the tissue; Score 2 = focal hepatocyte damage on 25-50% of the tissue; Score 3 = extensive, but focal hepatocyte lesion; Score 4 = global hepatocyte necrosis

3. Results

3.1 Effects of CCl₄ and UD treatment on body & liver weight in control and treated rats

Reduction in body weight and organ weight is a prominent feature of injury. Table-I compares the effects of *Urtica dioica* among control, CCl₄ treated, CCl₄ + U.D treated & UD treated rats and shows that CCl₄

administration significantly decreased body weight of animals as compared with control ($P < 0.0001$). *Urtica dioica* treatment has shown to increase body weight significantly in U.D +CCl₄ treated group as compared with CCl₄ treated group ($P < 0.001$). A significant increase in Liver weight ($P < 0.05$) and relative liver weight ($P < 0.01$) was observed in CCl₄ treated group as compared with control whereas a significant reduction in liver weight ($P < 0.05$) and relative liver weight ($P < 0.05$) was noted in CCl₄ + U.D treated rats as compared with CCl₄. There is no significant change in liver weight ($P > 0.05$) and relative liver ($P > 0.05$) weight in UD treated rats and control.

3.2 Effects of CCl₄ and UD treatment on liver enzymes (ALT, AST, ALP) & Bilirubin in control and treated rats

Table-II shows that levels of hepatic enzymes AST($P < 0.001$), ALT($P < 0.01$) & ALP($P < 0.01$) were raised significantly in CCl₄ treated rats as compared with control. UD treatment has significantly reduced the enzymes ALT ($P < 0.05$) & ALP($P < 0.01$) in CCl₄ + U.D treated group as compared with CCl₄ treated group whereas no significant change was observed in AST ($P > 0.05$) in UD treated rats as compared with control. Activities of AST, ALT & ALP were nearly similar in control group and UD treated group ($P > 0.05$). Table-II shows that CCl₄ treatment has significantly raised bilirubin level in rats as compared with control ($P < 0.001$). Bilirubin concentration was reduced significantly ($P < 0.01$) in CCl₄ + U.D treated group as compared with CCl₄ treated group. Bilirubin was significantly increased ($P < 0.01$) in UD treated rats as compared with control.

3.3 Effects of CCl₄ and UD treatment on hepatic concentration of catalase in control and treated rats

Table 3 shows significantly lower activities of catalase ($P < 0.0001$) in CCl₄ treated rats as compared with control. UD treatment along with CCl₄ has been shown to increase significantly the reduced activity of Catalase ($P < 0.01$) in CCl₄ + UD treated rats as compared to CCl₄ treated group. Activity of catalase was significantly reduced in UD treated group ($P < 0.01$) as compared with control.

3.4 Effects of CCl₄ and UD treatment on hepatic concentration of SOD in control and treated rats

Activity of SOD was significantly reduced in CCl₄ treated rats ($P < 0.05$) as compared with control. Activity of SOD enhanced significantly in CCl₄ + UD treated rats ($P < 0.01$) as compared with CCl₄ treated group. SOD activity was nearly similar in UD treated rats and control and no significant change was observed ($P > 0.05$) (Table 3).

3.5 Effects of CCl₄ and UD treatment on hepatic concentration of GSH in control and treated rats

Activity of antioxidant enzyme Glutathione peroxidase was reduced significantly ($P < 0.0001$) in CCl₄ treated rats as compared with control (Table 3). UD treatment along with CCl₄ has been shown to increase significantly the reduced glutathione peroxidase activity ($P < 0.05$) in CCl₄ + UD treated rats as compared to CCl₄ treated group. Activity of Glutathione peroxidase was significantly reduced in UD treated group ($P < 0.0001$) as compared with control group (Table 3).

3.6 Effects of CCl₄ and UD treatment on hepatic concentration of MDA in control and treated rats

Table 3 shows that level of MDA was raised significantly ($P < 0.05$) in CCl₄ treated group as compared with control. UD treatment along with CCl₄ has been shown to decrease significantly MDA level in CCl₄ + UD treated ($P < 0.05$) rats as compared with CCl₄ treated group. MDA was not significantly changed in UD treated group ($P > 0.05$) as compared with control.

3.7 Histopathological findings

Liver morphological changes were scored, described and summarized in Control, CCl₄ treated, CCl₄ + *Urtica dioica* treated & *Urtica dioica* treated groups (Table 1). No evident histological changes were observed in liver tissues of control group (Figure 1). Severe histopathological changes in CCl₄ treated rat liver tissues were noted. The prominent changes include portal and periportal inflammation, portal and periportal fibrosis, focal lobulitis and intracellular pigment deposition. Degeneration of hepatocytes was also noted and degenerative hepatocytes constitute for 30-40% (Figure 2). Our experimental results showed that *Urtica dioica* treatment along with CCl₄ has partly improved and reversed the liver histological changes induced by CCl₄ and slight and focal indications of periportal fibrosis, fatty changes and bile duct proliferation were found with apparently no degenerative hepatocytes (Figure 3). However enlargement, paleness, hydropic degeneration & dysplasia were absent in rat liver lobules of both CCl₄ treated & CCl₄ + *Urtica dioica* treated groups. Hepatic architecture in UD treated group is similar to control group with no necrosis & degeneration. Only slight periportal fibrosis was noted in UD treated rat liver tissues (Figure 4)

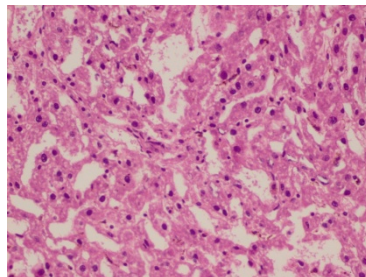


Figure 1: Control

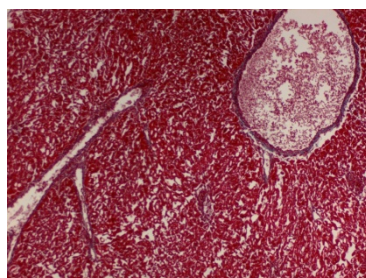


Figure 2: CCl₄ treated

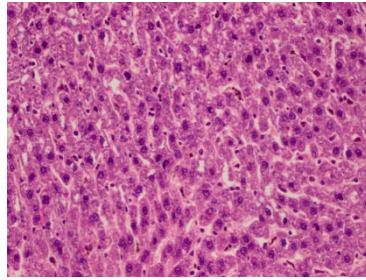


Figure 3: CCl4 +Urtica treated

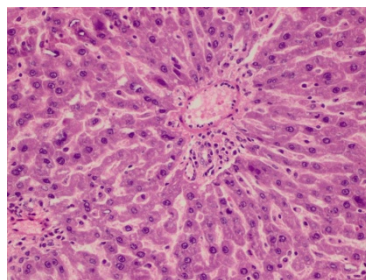


Figure 4: Urtica treated

4. Discussion

In our study protective effects of *Urtica dioica* were investigated against hepatotoxicity induced by CCl₄ in rats. CCl₄ treatment has been shown to increase lipid peroxidation, liver enzymes and decrease antioxidant level (Table 2&3). CCl₄ induces hepatotoxicity by altering permeability of plasma, mitochondrial and lysosomal membranes of hepatocytes that leads to cell damage as well as via production of reactive free radicals that further leads to cell destruction. In the present study hepatic enzymes AST, ALT, ALP and bilirubin were raised dramatically after CCl₄ treatment (Table 2). Activities of hepatic metabolic enzymes in plasma are indicators of liver functions and their elevated levels reflects liver dysfunction as enzymes leak in to blood upon cell damage. On the other hand elevated serum bilirubin levels are indicative of potentially serious liver damage and loss of liver function. UD treatment along with CCl₄ has been shown to decrease ALT, ALP & bilirubin concentration thereby suggesting its protective effects against liver damage (Table 2). AST level was not reduced significantly in our study (Table 2), as AST is found in most tissues of the body so is not a precise indicator of liver damage. Similar results are reported by other studies [20].

In our study activities of hepatic antioxidant enzymes catalase, superoxide dismutase and glutathione peroxidase were reduced in CCl₄ treated rats (Table 3) this is because CCl₄ causes production of reactive free radicals that induce damage through covalent binding to the membrane proteins and lipid peroxidation that further leads to oxidative destruction of cellular membranes [21]. Our experimental results showed that UD treatment

successively enhanced the hepatic antioxidant enzymes catalase, superoxide dismutase and glutathione peroxidase in CCl₄ treated rats (Table 3). As oxidative stress plays a major role in tissue injury in a broad range of human diseases and antioxidants play key role in reducing, neutralizing and interfering with reactive oxygen species thereby reducing oxidative stress, thus it is reasonable to think that antioxidant properties of *Urtica dioica* are beneficial against hepatotoxicity created by CCl₄ thereby preventing severe hepatic injury. Some studies also reported that UD has a powerful antioxidant activity [22]. Similarly one study reported that UD is effective against iron promoted oxidation of phospholipids, linoleic acids and deoxyribose. In the present study MDA concentration was greatly increased after CCl₄ treatment in rats. MDA is a specific indicator of lipid peroxidation formed via degradation of polyunsaturated lipids by reactive oxygen species that readily attack polyunsaturated fatty acids of cell membrane thereby initiating a self-propagating chain reaction that ends at destruction of membrane lipids. In our study UD treatment reduced hepatic MDA level suggesting its preventive potential against lipid peroxidation and subsequent cellular degradation. Our results are confirmed by other studies which reported that *Urtica dioica* prevent damage of rat liver tissue structure. The histological findings reported in this study are in accordance with the biochemical results. Hepatotoxicity induced by CCl₄ is confirmed by histological changes in liver tissues which indicated portal and periportal inflammation and fibrosis with intracellular pigment deposition and hepatocyte degeneration. Similar changes in liver tissues were noted by [8]. Our experimental results showed that *Urtica dioica* treatment along with CCl₄ has partly improved and reversed the liver histological changes induced by CCl₄ and slight and focal indications of periportal fibrosis, fatty changes and bile duct proliferation were found with apparently no degenerative hepatocytes. Similar histological features were reported by [23].

5. Conclusion

Liver cirrhosis is a major health problem with increased morbidity and mortality. Use of herbal therapies is a current matter of interest among researchers for the prevention and treatment of diseases including liver cirrhosis. This study suggests that herbal extract of *Urtica Dioica* can be beneficial in the prevention and treatment of hepatotoxicity created by CCl₄ thus more research work is required to elaborate the medicinal properties of *Urtica dioica* and on the other hand awareness about the usefulness of this herb should be disseminated among people.

Acknowledgements

We would like to thank Dean, Faculty of Science, University of Karachi for financial support of the project.

References

- [1] Kavalali, G.; Tuncel, H.; Göksel, S. & Hatemi, H. H. "Hypoglycemic activity of *Urtica pilulifera* in streptozotocin-diabetic rats." in *J. Ethnopharmacol*, 84(2-3): 241-5, 2003
- [2] Vogel, K.J., Brown, M.R., Strand, M.R. (2013). "Phylogenetic investigation of Peptide hormone and growth factor receptors in five dipteran genomes." in *Front. Endocrinol*, 4: 193.

- [3] Akbay P, "In vitro Immunomodulatory Activity of Flavonoid Glycosides from *Urtica dioica* L," in *phytotherapy Research*, 17: 34-7, 2003
- [4] Obertreis, B.; Giller, K.; Teucher, T.; Behnke, B. & Schmitz, H. "Anti-inflammatory effect of *Urtica dioica* folia extractin comparison to caffeic malic acid," in *Arzneimittelforschung*, 46(1): 52-6. 1996
- [5] Teucher T, Obertreis B, Ruttkowski T. "Ex-vivo in-vitro inhibition of lipopolysaccharide stimulated tumor necrosis factor-alpha and interleukin-1 beta secretion in human whole blood by extractum *Urticae dioicae* foliorum," *Arzneimittelforschung*; 46, 389-394. 1996
- [6] Riehemann, K.; Behnke, B. & Schulze-Osthoff, K. "Plant extracts from stinging nettle (*Urtica dioica*), an antirheumatic remedy, inhibit the proinflammatory transcription factor NF-kappaB," in *FEBS Lett.*, 442(1), 89-94. 1999
- [7] Safarinejad MR. J Herb. "*Urtica dioica* for treatment of benign prostatic hyperplasia: a prospective, randomized, double-blind, placebo-controlled, crossover study." in *Pharmacother*, 5(4), 1-11, 2005
- [8] Akram Eidi, Pejman Mortazavi, Masoud EbrahimTehrani, AliHaeri Rohani, Shahabaldin Safi. "Hepatoprotective effects of Pantothenic acid on carbon tetra chloride-Induced toxicity in rats," in *EXCLI Journal*, 11: 748-759-ISSN 1611-2156 , 2012
- [9] Schottner M, Gansser D, Spiteller G. "Lignans from the roots of *Urtica dioica* and their metabolites bind to human sex hormone binding globulin (SHBG)" in *Planta Med*, 63: 529-532, 1997
- [10] Siraj AK, Bavi P, Abubaker J, Jehan Z, Sultana M, Al-Dayel F, Al-Nuaim A, Alzahrani A, Ahmed M, Al-Sanea O, Uddin S, Al-Kuraya KS, "Genome-wide expression analysis of Middle Eastern papillary thyroid cancer reveals c-MET as a novel target for cancer therapy," in *J Pathol*, 213(2), 190-9. , Oct 2007
- [11] Reitman S, Frankel S. "A colorimetric method for the determination of serum glutamic oxaloacetic and glutamic pyruvic transaminases," in *Am.J Clin. Pathol*, 28 (1), 56-63,1957
- [12] Wilkinson, S. P., Arroyo, V. A., Gazzard, B. G., Moodie, H., and Williams, R. (1974a). "Relation of renal impairment and haemorrhagic diathesis to endotoxaemia in fulminant hepatic failure," in *Lancet*, 1, pp. 521-524.
- [13] Tietz NW, Burtis CA, Duncan P, Ervin K, Petittclerc CJ, Rinker AD, Shuey D, ZygowicsER. "A reference method for measurement of alkaline phosphatase activity in human serum," in *Clin Chem*, 29(5), 751-61, 1983
- [14] Dangerfield WG and Finlayson R. "Estimation of bilirubin in serum." in *J. Clin. Path*, 6, pp.173, 1953
- [15] Ohkawa H, Ohishi N, Yagi K. "Assay for lipid peroxides in animal tissues by thiobarbituric acid reaction." In *Analytical biochemistry*, 95, 351-358, 1979
- [16] Sinha KA. "Colorimetric assay of Catalase," in *Anal Biochem*, 47, pp. 389-394, 1972
- [17] Kono Y. "Generation of superoxide radical during autoxidation of hydroxylamine and an assay for superoxide dismutase," in *Arch Biochem biophys*, 186: pp.189-195.1978
- [18] Carlberg R & Mannervik. "Glutathione Reductase," in *Methods Enzymol*, 113, 484-490, 1985
- [19] French SW, Miyamoto K, Ohta Y, Geofrion Y. "Pathogenesis of experimental alcoholic liver disease in the rat," in *Methods Achiev Exp Pathol*, vol.13, 181-207, 2000
- [20] Kanter M, Coskun O, Budancamanak M. "Hepatoprotective effects of *Nigella sativa* L and *Urtica dioica* L on lipid peroxidation, antioxidant enzyme systems and liver enzymes in carbon tetrachloride-treated rats." in *World J Gastroenterol*, pp.14;11(42):6684-8, Nov 2005

- [21] Cheeseman. "Mechanisms and effects of lipid peroxidation Molecular Aspects of Medicine," in *Elsevier*, vol 14, Issue 3, pp. 191-197 , 1993
- [22] Gülçin Iİ, Küfrevioğlu Oİ, Oktay M, Büyükkuroğlu ME. "Antioxidant, antimicrobial, antiulcer and analgesic activities of nettle (*Urtica dioica* L.)" in *Journal of Ethnopharmacology*, vol. 90, Issues 2–3, pp. 205–215, Feb 2004
- [23] Oguz S. Kanter M, Erboğa M, Cem İbis. "Protective effect of *Urtica dioica* on liver damage induced by biliary obstruction in rats," in *Toxicol Ind Health*, pp. 29: 838-845, Oct 2013